• THE BIG PICTURE •

GROSS ANATOMY

MEDICAL COURSE & STEP 1 REVIEW

SECOND EDITION

Includes online video lectures!

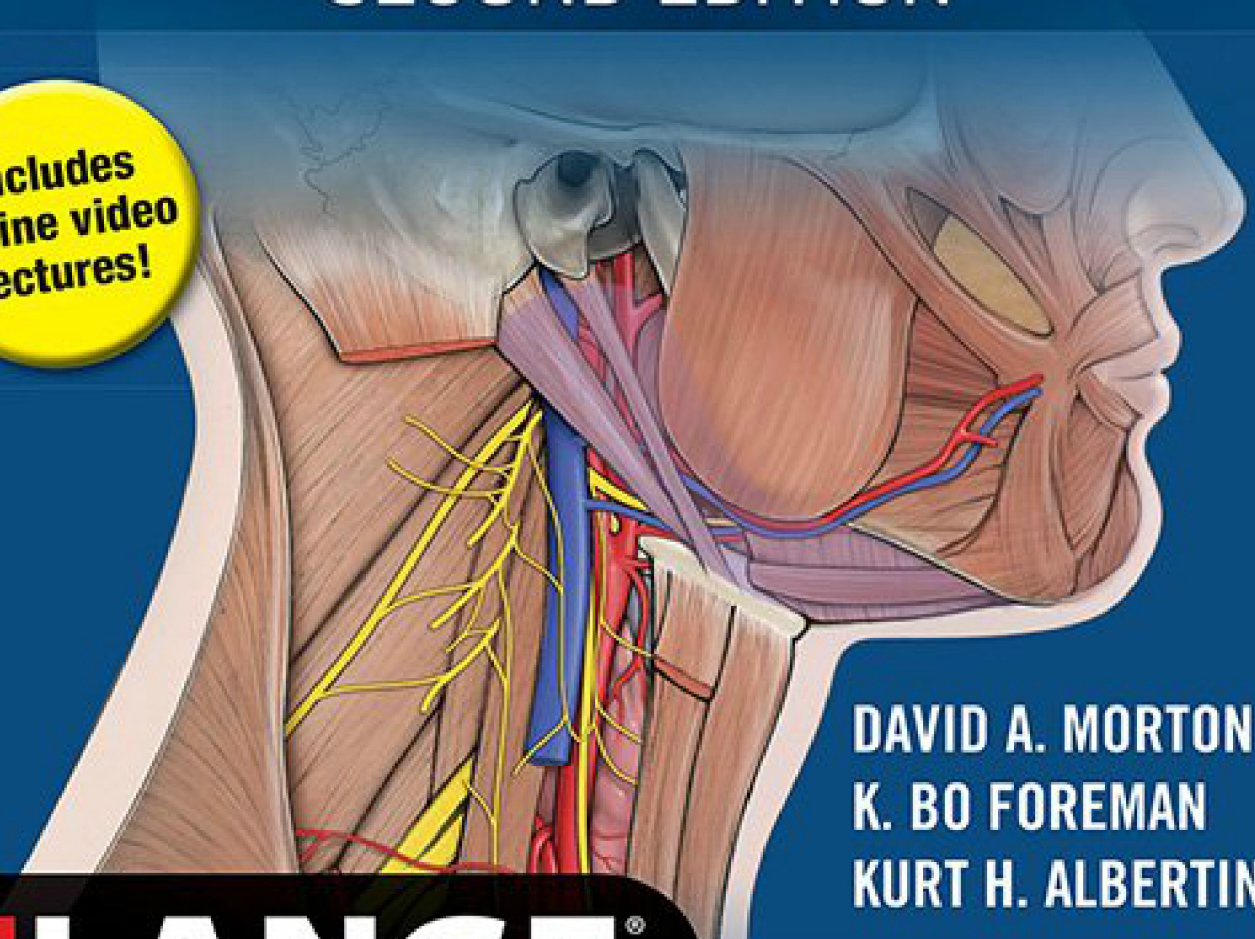

DAVID A. MORTON
K. BO FOREMAN
KURT H. ALBERTINE

Mc Graw Hill Education
LANGE®

THE BIG PICTURE

GROSS ANATOMY, MEDICAL COURSE AND STEP 1 REVIEW

SECOND EDITION

David A. Morton, PhD
Professor
Anatomy Director
Vice-Chair of Medical and Dental Education
Department of Neurobiology and Anatomy
University of Utah School of Medicine
Salt Lake City, Utah

K. Bo Foreman, PhD, PT
Associate Professor
Anatomy Director
Department of Physical Therapy and Athletic Training
University of Utah College of Health
Associate Editor, The Anatomical Record
Salt Lake City, Utah

Kurt H. Albertine, PhD, FAAAS, FAAA
Professor of Pediatrics, Medicine (Adjunct), and Neurobiology and Anatomy (Adjunct)
Edward B. Clark Endowed Chair IV of Pediatrics
Editor-In-Chief, *The Anatomical Record*
University of Utah School of Medicine
Salt Lake City, Utah

Mc Graw Hill Education

New York Chicago San Francisco Athens London Madrid Mexico City
Milan New Delhi Singapore Sydney Toronto

Copyright © 2019 by McGraw-Hill Education. All rights reserved. Except as permitted under the United States Copyright Act of 1976, no part of this publication may be reproduced or distributed in any form or by any means, or stored in a database or retrieval system, without the prior written permission of the publisher.

ISBN: 978-1-25-986264-9
MHID: 1-25-986264-X

The material in this eBook also appears in the print version of this title: ISBN: 978-1-25-986263-2,
MHID: 1-25-986263-1.

eBook conversion by codeMantra
Version 1.0

All trademarks are trademarks of their respective owners. Rather than put a trademark symbol after every occurrence of a trademarked name, we use names in an editorial fashion only, and to the benefit of the trademark owner, with no intention of infringement of the trademark. Where such designations appear in this book, they have been printed with initial caps.

McGraw-Hill Education eBooks are available at special quantity discounts to use as premiums and sales promotions or for use in corporate training programs. To contact a representative, please visit the Contact Us page at www.mhprofessional.com.

TERMS OF USE

This is a copyrighted work and McGraw-Hill Education and its licensors reserve all rights in and to the work. Use of this work is subject to these terms. Except as permitted under the Copyright Act of 1976 and the right to store and retrieve one copy of the work, you may not decompile, disassemble, reverse engineer, reproduce, modify, create derivative works based upon, transmit, distribute, disseminate, sell, publish or sublicense the work or any part of it without McGraw-Hill Education's prior consent. You may use the work for your own noncommercial and personal use; any other use of the work is strictly prohibited. Your right to use the work may be terminated if you fail to comply with these terms.

THE WORK IS PROVIDED "AS IS." McGRAW-HILL EDUCATION AND ITS LICENSORS MAKE NO GUARANTEES OR WARRANTIES AS TO THE ACCURACY, ADEQUACY OR COMPLETENESS OF OR RESULTS TO BE OBTAINED FROM USING THE WORK, INCLUDING ANY INFORMATION THAT CAN BE ACCESSED THROUGH THE WORK VIA HYPERLINK OR OTHERWISE, AND EXPRESSLY DISCLAIM ANY WARRANTY, EXPRESS OR IMPLIED, INCLUDING BUT NOT LIMITED TO IMPLIED WARRANTIES OF MERCHANTABILITY OR FITNESS FOR A PARTICULAR PURPOSE. McGraw-Hill Education and its licensors do not warrant or guarantee that the functions contained in the work will meet your requirements or that its operation will be uninterrupted or error free. Neither McGraw-Hill Education nor its licensors shall be liable to you or anyone else for any inaccuracy, error or omission, regardless of cause, in the work or for any damages resulting therefrom. McGraw-Hill Education has no responsibility for the content of any information accessed through the work. Under no circumstances shall McGraw-Hill Education and/or its licensors be liable for any indirect, incidental, special, punitive, consequential or similar damages that result from the use of or inability to use the work, even if any of them has been advised of the possibility of such damages. This limitation of liability shall apply to any claim or cause whatsoever whether such claim or cause arises in contract, tort or otherwise.

DEDICATION

To my wife Celine and our children Jared, Ireland, Gabriel, Max, and Jack; and their cousins Lia, Sophia, Joshua, Cayden, Ethan, Nathan, Kelsey, Robert, Stefani, Ella, Reid, Roman, Marcus, Jared, Hannah, Tanner, Liam, Maia, Riley, Sydney, Luke, Cole, Desiree, Celeste, Connlan, Isabelle, Nathan, Simon, Thomas, James, Alexandre, Lyla, Logan, William, Lincoln, Emmett, Andilynn, Greyson, Kennedy, Davis, Caleb, Charlotte, Adeline, and Penny.
I could not ask for a better family.

—David A. Morton

To my devoted family: my wife, Cindy, and our two daughters Hannah and Kaia. I would also like to posthumously dedicate this second edition to Dr. Carolee Moncur, without her mentorship and inspiration this book would not have been possible.

—K. Bo Foreman

To David and Bo, co-authoring this book (both editions) with you completes a mentoring circle for me. I am proud to have you as my colleagues and friends. To my wife, Laura Lake, and our adult children Erik and Kristin. Thank you for your patience with and understanding of my efforts to contribute to biomedical education and research. A delight for me is that the topic of human anatomy is enjoyed by our four grandchildren Breneé, Marlee, Callan, and Emery, each of whom leafs through the first edition of the *Big Picture Gross Anatomy* book. Hopefully, they will do the same with this, the second, edition.

—Kurt H. Albertine

CONTENTS

Preface xi

Acknowledgments xii

About the Authors xiv

SECTION 1: BACK

CHAPTER 1 Back Anatomy 3
- Superficial Back Muscles 4
- Deep Back Muscles 6
- Vertebral Column 8
- Vertebrae 10
- Spinal Meninges 12
- Spinal Cord 14
- Spinal Nerves 16
- Study Questions 22
- Answers 23

SECTION 2: THORAX

CHAPTER 2 Anterior Thoracic Wall 27
- The Breast 28
- Thoracic Muscles 30
- Thoracic Skeleton 32
- Nerves of the Thoracic Wall 34
- Vasculature of the Thoracic Wall 36
- Diaphragm 38

CHAPTER 3 Lungs 41
- Pleura 42
- Anatomy of the Lung 44
- Hilum of the Lung 46
- Ventilation 48

CHAPTER 4 Heart 51
- Pericardium 52
- Overview of the Heart 52
- Coronary Circulation 54
- Chambers of the Heart 56
- Heart Valves 58
- Cardiac Cycle 58
- Innervation of the Heart 60

CHAPTER 5 Superior and Posterior Mediastinum 63
- Divisions of the Mediastinum 64
- Sympathetic Trunk and Associated Branches 66
- Azygos Veins, Thoracic Duct, and Thoracic Aorta 68
- Posterior and Superior Mediastinum 70
- Study Questions 72
- Answers 74

SECTION 3: ABDOMEN, PELVIS, AND PERINEUM

CHAPTER 6 Overview of the Abdomen, Pelvis, and Perineum 77
- Osteologic Overview 78
- Gut Tube 80

CHAPTER 7 Anterior Abdominal Wall 83
- Partitioning of the Abdominal Region 84
- Superficial Layers of the Anterior Abdominal Wall 84
- Anterior Abdominal Wall Muscles 86
- Vascular Supply and Innervation of the Anterior Abdominal Wall 88
- Inguinal Canal 90
- Scrotum and Spermatic Cord 92

CHAPTER 8 Serous Membranes of the Abdominal Cavity 95
- The Peritoneum 96

CHAPTER 9 Foregut 99
- GI Portion of the Foregut 100
- Liver and Gallbladder 102
- Pancreas and Spleen 104
- Vascular Supply of the Foregut 106

To access your complimentary online lecture videos, visit http://mhprofessional.com/usmle-anatomy-review.

CHAPTER 10 Midgut, Hindgut, and GI Vascular Supply and Innervation 109
Midgut 110
Hindgut 112
Innervation of the GI Tract 114
Hepatic Portal System 116

CHAPTER 11 Posterior Abdominal Wall 119
Posterior Abdominal Wall Muscles and Nerves 120
Posterior Abdominal Wall Vessels 122
Posterior Abdominal Wall Autonomics 124
Adrenal Glands, Kidneys, and Ureters 126

CHAPTER 12 Perineum and Pelvis 129
Perineum 130
Pelvic Floor 132
Pelvic Vasculature 134
Pelvic Innervation 136
Rectum and Anal Canal 138
Ureters and Urinary Bladder 140

CHAPTER 13 Male Reproductive System 143
Male Reproductive System 144
The Male Sexual Responses 148

CHAPTER 14 Female Reproductive System 151
Female Reproductive System 152
The Female Sexual Responses 156
Study Questions 157
Answers 160

SECTION 4: HEAD

CHAPTER 15 Scalp, Skull, and Meninges 165
Anatomy of the Scalp 166
Skull 168
Cranial Fossae 170
Meninges 172

CHAPTER 16 Brain 177
Anatomy of the Brain 178
Ventricular System of the Brain 180
Blood Supply to the Brain 182

CHAPTER 17 Cranial Nerves 185
Overview of the Cranial Nerves 186
CN I: Olfactory Nerve 188
CN II: Optic Nerve 188
CN III: Oculomotor Nerve 190
CN IV: Trochlear Nerve 190
CN VI: Abducens Nerve 190
CN V: Trigeminal Nerve 192
CN VII: Facial Nerve 194
CN VIII: Vestibulocochlear Nerve 194
CN IX: Glossopharyngeal Nerve 196
CN X: Vagus Nerve 198
CN XI: Spinal Accessory Nerve 200
CN XII: Hypoglossal Nerve 200
Autonomic Innervation of the Head 202

CHAPTER 18 Orbit 207
Orbital Region 208
The Eye 210
Extraocular Muscle Movement 212
Innervation of the Orbit 216

CHAPTER 19 Ear 219
The Ear 220

CHAPTER 20 Superficial Face 225
Cutaneous Innervation and Vasculature of the Face 226
Muscles and Innervation of the Face 228

CHAPTER 21 Infratemporal Fossa 231
Overview of the Infratemporal Fossa 232
Innervation and Vascular Supply of the Infratemporal Fossa 234

CHAPTER 22 Pterygopalatine Fossa 237
Overview of the Pterygopalatine Fossa 238

CHAPTER 23 Nasal Cavity 241
Overview of the Nasal Cavity 242
Paranasal Sinuses 246

CHAPTER 24 Oral Cavity 249
Palate 250
Tongue 252
Salivation 252
Teeth and Gingivae 254
Study Questions 256
Answers 260

SECTION 5: NECK

CHAPTER 25 Overview of the Neck 265
- Fascia of the Neck 266
- Muscles of the Neck 268
- Vessels of the Neck 272
- Innervation of the Neck 274

CHAPTER 26 Viscera of the Neck 277
- Visceral Layers of the Neck 278

CHAPTER 27 Pharynx 281
- Overview of the Pharynx 282
- Functions of the Pharynx 284
- Neurovascular Supply of the Pharynx 286

CHAPTER 28 Larynx 289
- Laryngeal Framework 290
- Function of the Larynx 292
- Vascular Supply and Innervation of the Larynx 294
- Study Questions 296
- Answers 298

SECTION 6: UPPER LIMB

CHAPTER 29 Overview of the Upper Limb 301
- Bones of the Shoulder and Arm 302
- Bones of the Forearm and Hand 304
- Fascial Planes and Muscles 306
- Innervation of the Upper Limb by the Brachial Plexus 308
- Sensation of the Upper Limb 310
- Vascularization of the Upper Limb 312

CHAPTER 30 Shoulder and Axilla 315
- Shoulder Complex 316
- Muscles of the Shoulder Complex 318
- Brachial Plexus of the Shoulder 322
- Vascularization of the Shoulder and Axilla 324
- Glenohumeral Joint 326

CHAPTER 31 Arm 331
- Arm 332
- Muscles of the Arm 332
- Terminal Branches of the Brachial Plexus in the Arm 334
- Vascularization of the Arm 334
- Joints Connecting the Arm and Forearm 336

CHAPTER 32 Forearm 339
- Muscles of the Forearm 340
- Terminal Branches of the Brachial Plexus in the Forearm 344
- Vascularization of the Forearm 346
- Joints Connecting the Forearm and Hand 348

CHAPTER 33 Hand 353
- Organization of the Fascia of the Hand 354
- Actions of the Fingers and Thumb 356
- Muscles of the Hand 358
- Terminal Branches of the Brachial Plexus in the Hand 360
- Vascularization of the Hand 362
- Joints of the Hand 364
- Study Questions 367
- Answers 370

SECTION 7: LOWER LIMB

CHAPTER 34 Overview of the Lower Limb 375
- Bones of the Pelvic Region and Thigh 376
- Bones of the Leg and Foot 378
- Fascial Planes and Muscles 380
- Innervation of the Lower Limb 382
- Sensation of the Lower Limb 384
- Vascularization of the Lower Limb 386

CHAPTER 35 Gluteal Region and Hip 389
- Gluteal Region 390
- Muscles of the Gluteal Region 390
- Sacral Plexus 392
- Vascularization of the Gluteal Region 394
- Joints of the Gluteal Region 394

CHAPTER 36 Thigh 397
- Thigh 398
- Muscles of the Thigh 398
- Femoral Triangle 402
- Lumbar Plexus 402
- Vascularization of the Thigh 404
- Knee Complex 406

CHAPTER 37 Leg 411
Muscles of the Leg 412
Innervation of the Leg 418
Vascularization of the Leg 418
Joints of the Leg and Ankle 420

CHAPTER 38 Foot 423
Joints of the Digits and Fascia of the Foot 424
Muscles of the Foot 426
Innervation of the Foot 428
Vascularization of the Foot 428
Study Questions 431
Answers 434

SECTION 8: FINAL EXAMINATION

CHAPTER 39 Study Questions and Answers 439
Directions 439
Answers 451

Index 457

PREFACE

If you were asked to give a friend directions from your office to a restaurant down the street, your instructions may sound something like this—turn right at the office door, walk to the exit at the end of the hall, walk to the bottom of the stairs, take a left, exit out of the front of the building, walk across the bridge, continue straight for two blocks passing the post office and library, and you will see the restaurant on your right. If you pass the gas station, you have gone too far. The task is to get to the restaurant. The landmarks guide your friend along the way to complete the task.

Now, imagine if an anatomist were to give directions from the office to the restaurant in the same way most anatomy textbooks are written. Details would be relayed on the dimensions of the office, paint color, carpet thread count, position and dimensions of the desk in relation to the book shelf along the wall, including the number, types, and sizes of books lining the shelves, and door dimensions and office door material in relation to the other doors in the same building. This would occur over the course of 10 pages—and the friend still would not have left the office. The difference between you giving a friend directions to a restaurant and the anatomist giving directions to the same restaurant may be compared with the difference between many anatomy textbooks and this Big Picture textbook—taking a long time to get to the restaurant or possibly not finding it, versus succinct relevant directions that take you directly to the restaurant, respectively.

The purpose of this textbook, therefore, is to provide students with the necessary landmarks to accomplish their task—to understand the big picture of human anatomy in the context of health care—while bypassing the minutia. The landmarks used to accomplish this task are text and illustrations. They are complete, yet concise and both figuratively and literally provide the "Big Picture" of human anatomy.

The format of the book is simple. Each page-spread consists of text on the left-hand page and associated illustrations on the right-hand page. In this way, students are able to grasp the big picture of individual anatomy principles in bite-sized pieces, a concept at a time.

- Key structures are highlighted in bold when first mentioned.
- Bullets and numbers are used to break down important concepts.
- Approximately 450 full-color figures illustrate the essential anatomy.
- High-yield clinically relevant concepts throughout the text are indicated by an icon.
- Study questions and answers follow each section.
- A final examination is provided at the end of the text.

We hope you enjoy this text as much as we enjoyed writing it.

—David A. Morton

—K. Bo Foreman

—Kurt H. Albertine

ACKNOWLEDGMENTS

Early in his life my father, Gordon Morton, went to an art school. He purchased a copy of *Gray's Anatomy* to help him draw the human form. That book sat on our family's bookshelf all throughout my life and I would continually look through its pages in wonder of the complexity and miracle of the human body. After I completed high school my father gave me that book which I have kept in my office ever since. I acknowledge and thank my father and my mother (Gabriella) for their influence in my life. Thank you to my co-authors, Dr. Foreman and Dr. Albertine—they are a joy to work with and I look forward to many years of collaborating with them.

I express a warm thank you to Michael Weitz. His dedication, help, encouragement, vision, leadership, and friendship were key to the successful completion of this title. I also express great thanks to Susan Kelly. She was a joy to work with through rain, shine, snow, tennis competitions, and life in general—I thank her for her eagle eye and encouraging telephone conversations and e-mails. Thank you to Karen Davis, Armen Ovsepyan, Brian Kearns, John Williams, and to the folks at Dragonfly Media Group for the care and attention they provided in creating the images for this title. Finally, a warm thank you to my wife and best friend Celine. Her unyielding support and encouragement through long nights of writing were always there to cheer me on. I adore her.

—*David A. Morton*

I thank my parents, Ken Foreman and Lynn Christensen, as well as my mentor and friend, Dr. Albertine. A special thank you to Cyndi Schluender and my students for their contributions to my educational endeavors. I also express a great thanks to Dr. Morton for his continued encouragement and support in writing this textbook.

—*K. Bo Foreman*

Many medical educators and biomedical scientists contributed to my training that helped lead to writing medical education textbooks such as this one. Notable mentors are C.C.C. O'Morchoe, S. Zitzlsperger, and N.C. Staub. For this textbook, however, I offer my thanks to my co-authors Dr. Morton and Dr. Foreman. Co-authoring this textbook with them has been and continues to be a thrill because now my once doctoral degree students are my colleagues in original educational scholarship. What better emblem of success could a mentor ask for? So, to David and Bo, thank you! I enjoy watching your academic success as your careers flourish as medical educators and scholars.

—*Kurt H. Albertine*



Aerial view of University of Utah campus, Salt Lake City, Utah. Photo taken by Kurt Albertine, educator and author.

ABOUT THE AUTHORS

David A. Morton completed his undergraduate degree at Brigham Young University, Provo, Utah, and his graduate degrees at the University of Utah School of Medicine, Salt Lake City. He currently serves as Vice-Chair of Medical and Dental Education and is a member of the Curriculum Committee at the University of Utah School of Medicine. Dr. Morton has been awarded the Early Career Teaching Award, Preclinical Teaching Awards, Leonard W. Jarcho, M.D. Distinguished Teaching Award, and the University of Utah Distinguished Teaching Award. Dr. Morton is an adjunct professor in the Physical Therapy Department and the Department of Family and Preventive Medicine. He also serves as a visiting professor at Kwame Nkrumah University of Science and Technology, Kumasi, Ghana, West Africa.

K. Bo Foreman completed his undergraduate degree in physical therapy at the University of Utah and his graduate degree at the University of Utah School of Medicine. Currently, he is an Associate Professor at the University of Utah in the Department of Physical Therapy and Athletic Training where he teaches gross anatomy and neuroanatomy. In addition to his teaching responsibilities, Dr. Foreman also serves as the Director of the Motion Analysis Core Facility and has an active research program in biomechanics. Furthermore, he is an adjunct Associate Professor in the Departments of Mechanical Engineering, Neurobiology and Anatomy, Orthopaedics, and Plastic Surgery. Dr. Foreman has been awarded the Early Career Teaching Award from the University of Utah and the Basmajian Award from the American Association of Anatomists.

Kurt H. Albertine completed his undergraduate studies in biology at Lawrence University, Appleton, Wisconsin, and his graduate studies in human anatomy at Loyola University of Chicago, Stritch School of Medicine. He completed postdoctoral training at the University of California, San Francisco, Cardiovascular Research Institute. He has taught human gross anatomy for 40 years. Dr. Albertine established the Human Anatomy Teacher-Scholar Training Program in the Department of Neurobiology & Anatomy at the University of Utah School of Medicine. The goal of this training program is to develop teacher-scholars of human anatomy to become leaders of anatomy teachers on a national level, contribute teaching innovations, and design and perform teaching outcomes research for upcoming generations of medical students. Graduates of this training program include Dr. Morton and Dr. Foreman.

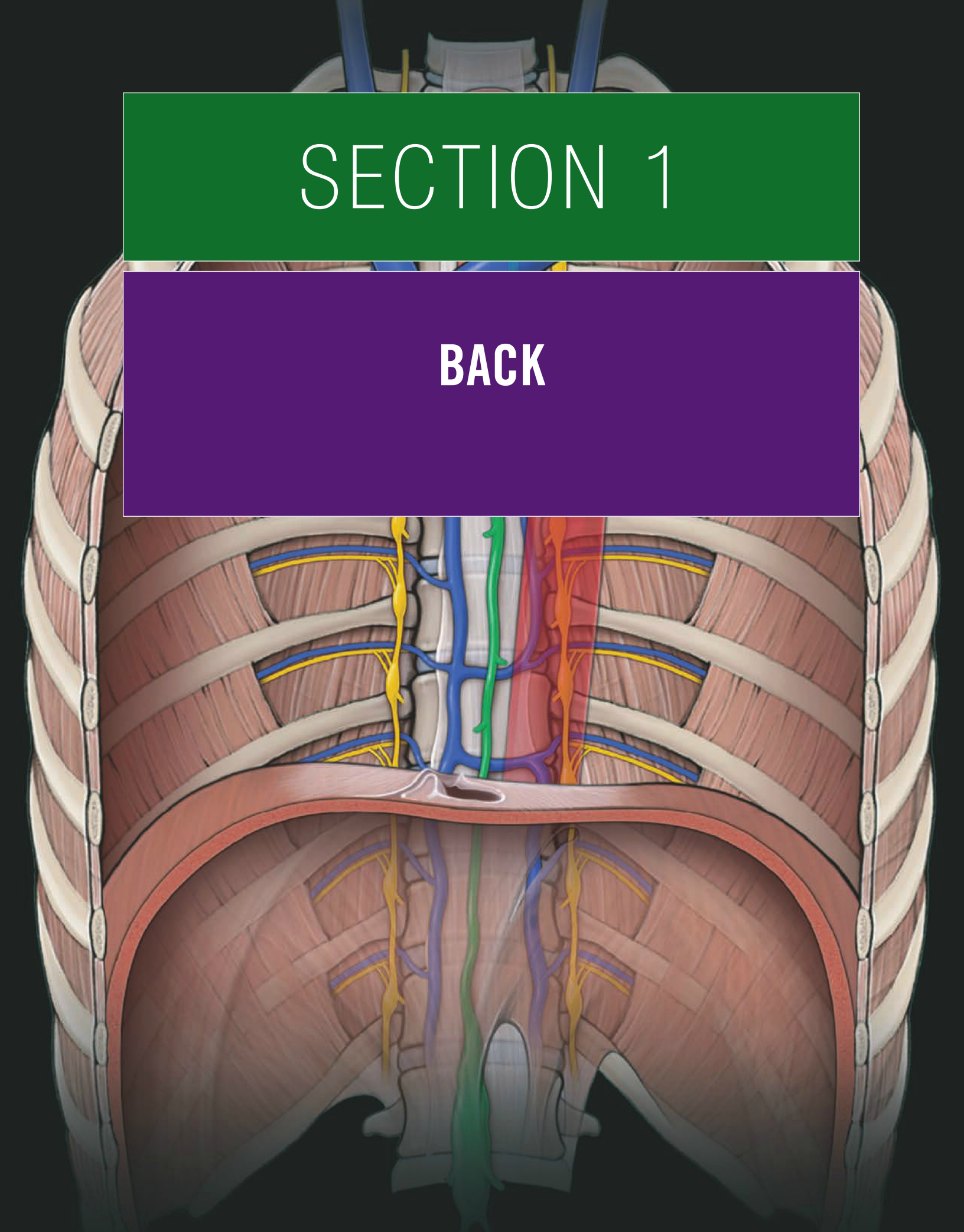

SECTION 1

BACK

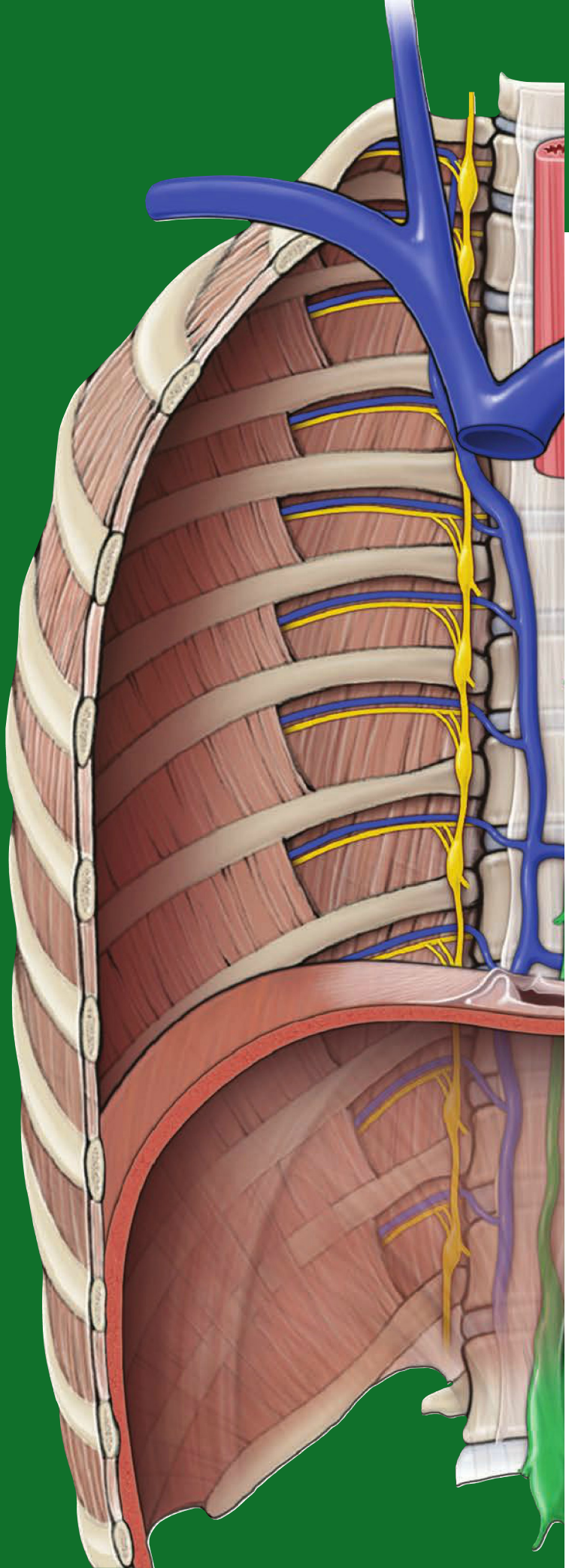

CHAPTER 1

BACK ANATOMY

Superficial Back Muscles 4
Deep Back Muscles 6
Vertebral Column 8
Vertebrae 10
Spinal Meninges 12
Spinal Cord 14
Spinal Nerves 16
Study Questions 22
Answers 23

SUPERFICIAL BACK MUSCLES

BIG PICTURE

The superficial back muscles consist of the trapezius, levator scapulae, rhomboid major, rhomboid minor, and latissimus dorsi muscles (Figure 1-1A; Table 1-1). Although these muscles are located in the back, they are considered to be muscles of the upper limbs because they connect the upper limbs to the trunk and assist in upper limb movements via the scapula and humerus. Because these are upper limb muscles, they are innervated by the ventral rami of spinal nerves (brachial plexus branches), with the exception of the trapezius muscle (which is innervated by CN XI). These muscles are discussed in greater detail in Section VI, Upper Limb, but are included here because these muscles overly the deep back muscles.

TRAPEZIUS MUSCLE

- **Topography.** The most superficial back muscle; has a triangular shape, with three unique fiber orientations giving rise to multiple actions.
- **Proximal attachment(s).** Occipital bone, nuchal ligament, spinous processes of C7–T12.
- **Distal attachment(s).** Scapular spine, acromion, and clavicle.
- **Action(s).** Scapular elevation (superior fibers); scapular retraction (middle fibers), and scapular depression (lower fibers); upward rotation (all fibers working together).
- **Innervation.** Spinal accessory nerve (CN XI), which arises from the spinal cord, ascends through the foramen magnum into the skull and descends through the jugular foramen along the deep surface of the trapezius.

LEVATOR SCAPULAE MUSCLE

- **Topography.** Located deep to the trapezius muscle and superior to the rhomboids.
- **Proximal attachment(s).** Transverse processes of upper cervical vertebrae.
- **Distal attachment(s).** Superior angle of the scapula.
- **Action(s).** Elevation and downward rotation of the scapula.
- **Innervation.** Dorsal scapular nerve (C5); branches from C4–C5 ventral rami.

RHOMBOID MAJOR AND MINOR MUSCLES

- **Topography.** Located deep to the trapezius and inferior to the levator scapulae muscles.
- **Proximal attachment(s).** Spinous processes of C7–T1 (minor) and T2–T5 (major).
- **Distal attachment(s).** Medial border of the scapula.
- **Action(s).** Retraction of the scapula.
- **Innervation.** Dorsal scapular nerve (C5).

LATISSIMUS DORSI MUSCLE

- **Topography.** A broad, flat muscle in the lower region of the back.
- **Proximal attachment(s).** Spinous processes of T7 to the sacrum via the thoracolumbar fascia.
- **Distal attachment(s).** Intertubercular groove of the humerus.
- **Action(s).** Adduction, extension, and medial rotation of the humerus at the glenohumeral joint.
- **Innervation.** Thoracodorsal nerve (C6–C8).

SCAPULAR MOVEMENTS

Muscles move the scapula in the following directions (Figure 1-1B):

- **Elevation.** Scapula moves superiorly (as in shrugging the shoulders).
- **Depression.** Scapula moves inferiorly.
- **Protraction (abduction).** Scapula moves away from the midline.
- **Retraction (adduction).** Scapula moves away toward the midline.
- **Rotation.** Rotation of the scapula is defined by the direction that the glenoid fossa faces (glenoid fossa faces superiorly for upward rotation and inferiorly for downward rotation).

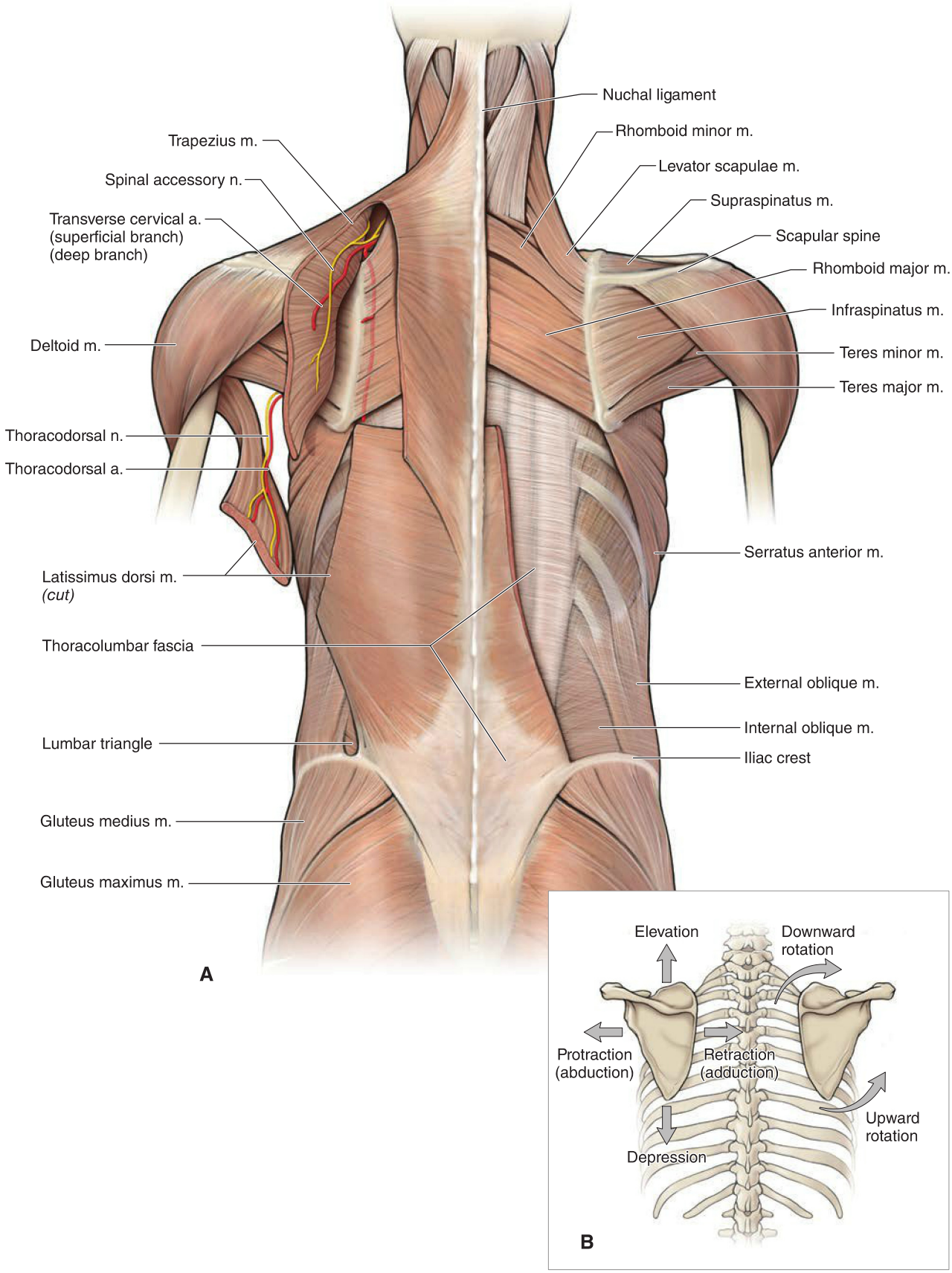

Figure 1-1: **A**. Superficial muscles of the back. **B**. Movements of the scapula.

DEEP BACK MUSCLES

BIG PICTURE

The deep back muscles are the true back muscles because they primarily act on the vertebral column. They are also referred to as intrinsic back muscles, epaxial muscles, and paraspinal muscles. The deep back muscles consist of the splenius capitis and cervicis, erector spinae, transversospinalis, and suboccipital muscles (Table 1-2). These deep back muscles are segmentally innervated by the dorsal rami of spinal nerves at each vertebral level where they attach. It is not important to know every detailed attachment for the deep back muscles; however, you should realize that these muscles are responsible for maintaining posture and are in constant use during body movements.

SPLENIUS CAPITIS AND CERVICIS MUSCLES

- **Topography.** Located deep to levator scapulae and rhomboid muscles, and superficial to erector spinae muscles (Figure 1-2A and B).
- **Action(s).** Bilateral contraction: extension of head and neck; unilateral contraction: lateral flexion and rotation of head and neck.
- **Innervation.** Segmentally innervated by dorsal rami.

ERECTOR SPINAE MUSCLES

- **Topography.** The erector spinae muscles consist of three separate muscles (from lateral to medial): iliocostalis, longissimus, and spinalis (Figure 1-2A and B).
- **Attachment(s).** The erector spinae muscles ascend throughout the length of the back as rope-like series of fascicles, with various bundles arising as others are inserting; each fascicle spans from 6 to 10 segments between bony attachments.
- **Action(s).** Bilateral contraction: extension of the vertebral column and control of posture; unilateral contraction: lateral flexion of vertebral column.
- **Innervation.** Segmentally innervated by dorsal rami.

TRANSVERSOSPINALIS MUSCLES

- **Topography.** Located deep to the erector spinae muscles. From superficial to deep, the transversospinalis muscles include the semispinalis, multifidus, and rotatores (Figure 1-2A and B).
- **Attachment(s).** Muscle fibers arise from a transverse process and ascend between one to six vertebral levels to attach to the spinous process of neighboring vertebrae.
- **Action(s).** Bilateral contraction: extension of the vertebral column; unilateral contraction: rotation of vertebral column to the contralateral side of the contracting transversospinalis muscle.
- **Innervation.** Segmentally innervated by dorsal rami.

SUBOCCIPITAL MUSCLES

- **Topography.** Located inferior to the occipital bone and deep to the semispinalis capitis muscle (Figure 1-2C). The suboccipital muscle group consists of the rectus capitis posterior major and minor and obliquus capitis superior and inferior.
- **Attachment(s).** Occipital bone, C1 and C2 vertebrae.
- **Action(s).** Mainly postural muscles, but may contribute to extension and rotation of the head.
- **Innervation.** Dorsal ramus of C1 spinal nerve (also known as the suboccipital nerve).

SUBOCCIPITAL TRIANGLE

- **Borders.** A triangle formed by the rectus capitis posterior major, obliquus capitis superior, and obliquus capitis inferior muscles.
- **Contents.** Structures associated with the suboccipital triangle are the following:
  - **Vertebral artery.** Exits the transverse foramen of the C1 vertebra, courses across the floor of the suboccipital triangle, ascends through the foramen magnum, and supplies the posterior region of the brain.
  - **Suboccipital nerve** (dorsal ramus of C1). Emerges between the occipital bone and C1 vertebra; innervates the suboccipital muscles.
  - **Greater occipital nerve** (dorsal ramus of C2). Emerges below the obliquus capitis inferior muscle; supplies sensory innervation to the back of the scalp.

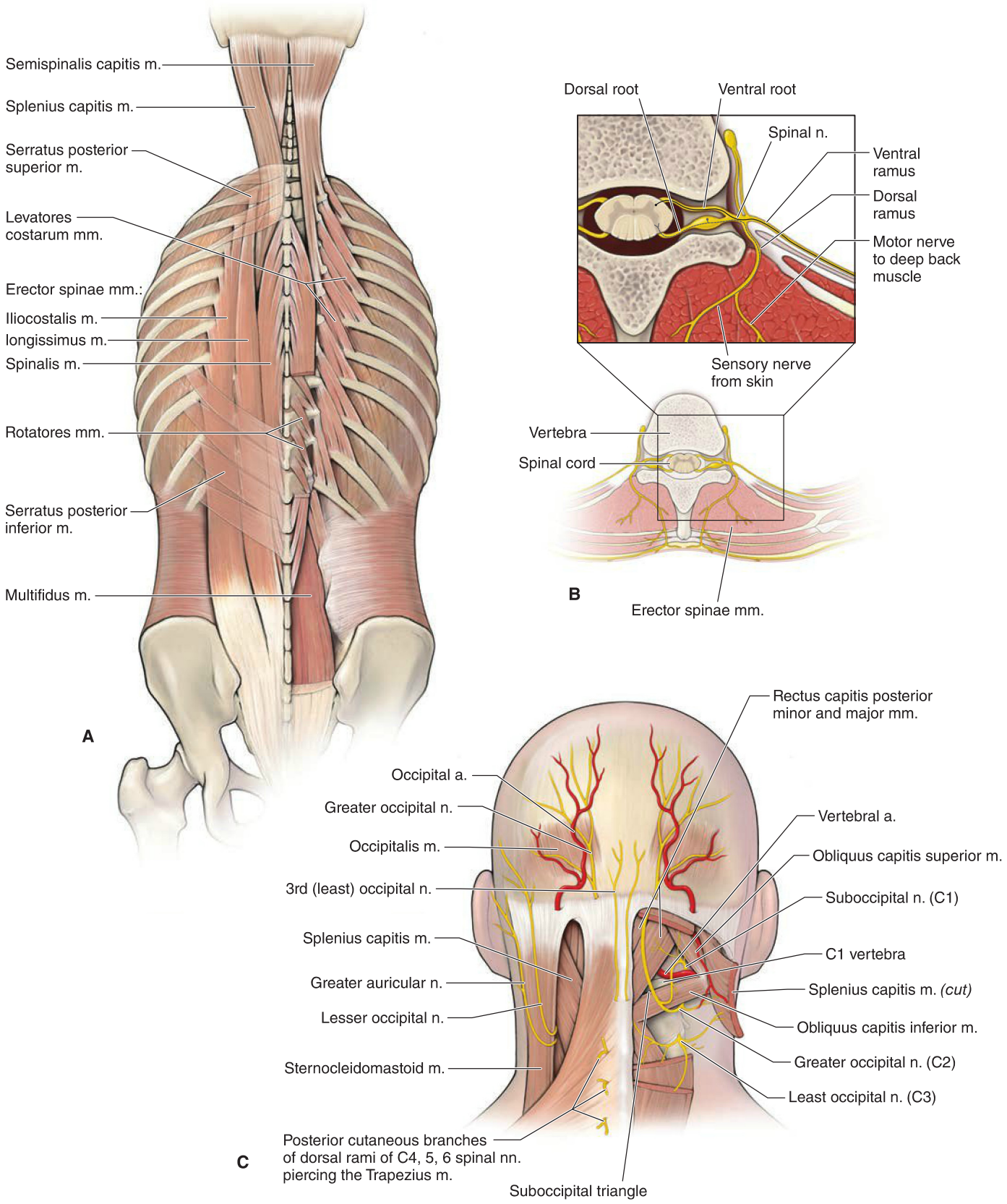

Figure 1-2: **A**. Deep back muscles with erector spinae muscles on the left and deeper transversospinalis muscles on the right. **B**. Axial section of the back showing the dorsal rami. **C**. Suboccipital region on the right side.

VERTEBRAL COLUMN

BIG PICTURE

The vertebral column is approximately 75 cm in length and consists of 33 vertebrae (7 cervical, 12 thoracic, 5 lumbar, 5 sacral, and 3–4 coccygeal). These vertebrae, along with their ligaments and intervertebral discs, form the flexible, protective, and supportive vertebral column that maintains posture, supports the body and head, and protects the spinal cord. The vertebral column is versatile in that it is rigid to provide protection and stability and yet flexible to enable movement.

VERTEBRAL COLUMN OVERVIEW

The vertebral column consists of cervical (C), thoracic (T), lumbar (L), sacral (S), and coccygeal (Co) vertebrae (Figure 1-3A; Table 1-3). To simplify their descriptions, the first letter of its region refers to each vertebra. For example, the "fourth cervical vertebra" is simply referred to as the "C4 vertebra."

- **Cervical vertebrae.** Located in the neck (cervical region); the **ligamentum nuchae**, a large ligament that courses down the back of the neck, connects the skull to the spinous processes of C1–C6. The first spinous process that is palpable deep to the skin is C7 and is called the **vertebral prominens**.
- **Thoracic vertebrae.** Located in the thoracic region and articulate with the 12 pairs of ribs.
- **Lumbar vertebrae.** Located in the lower back and are distinguished by their massive vertebral bodies.
- **Sacral vertebrae.** There are five fused sacral vertebrae (S1–S5), which form a single bone (sacrum).
- **Coccygeal vertebrae.** There are three to four fused coccygeal vertebrae (Co1–Co4), which form the coccyx bone ("tail bone").

VERTEBRAL CURVATURES

The adult spine is curved in four parts due to fetal and postnatal development of the vertebral column (Figure 1-3B and C).

- **Primary (kyphotic) curvatures.** Develop during the fetal period in relation to the flexed fetal position.
  - Primary curvatures are concave anteriorly and are located in the thoracic regions (optimize space for heart and lungs) and sacral regions (optimize space in pelvic cavity for a developing fetus).
- **Secondary (lordotic) curvatures.** Develop during the postnatal period.
  - Secondary curvatures are concave posteriorly and are located in the cervical region (develops when the infant holds its head upright while sitting) and lumbar region (develops when the infant begins to stand and walk).

▼ Abnormal primary curvatures are referred to as **kyphosis (excessive kyphosis)**, whereas abnormal secondary curvatures are referred to as **lordosis (excessive lordosis)**. Patients may present with abnormal lateral curvatures (**scoliosis**), which may be due to muscular dominance of one side over the other or to poor posture or congenital problems. To diagnose scoliosis, the physician may ask the patient to bend forward to determine if one side of the thorax is higher than the other due to asymmetry of the spine. ▼

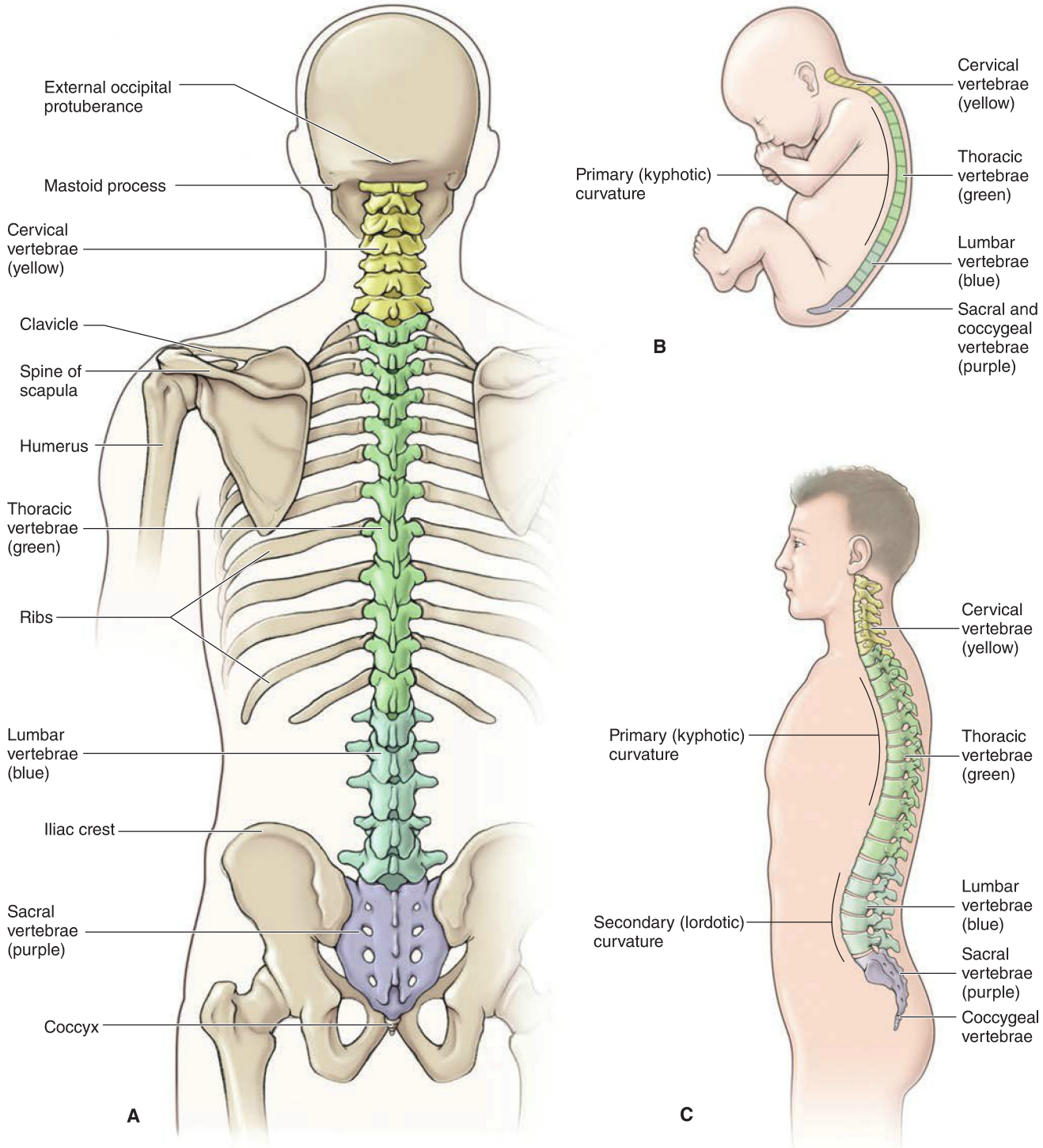

Figure 1-3: **A**. Posterior view of the vertebral column. **B.** Primary curvature of newborn. **C.** Normal curvatures of an adult.

VERTEBRAE

BIG PICTURE

The 33 vertebrae from each region of the vertebral column have some common vertebral structures. Additionally, each vertebral region has unique modifications and characteristics.

COMMON VERTEBRAL STRUCTURES

The 33 vertebrae have the following common structures (Figure 1-4A and C):

- **Body.** Anterior vertebral region; primary weight-bearing component of the vertebra.
- **Vertebral arch.** Posterior vertebral region; formed by the pedicles and laminae.
- **Pedicles.** Join the vertebral body to the transverse processes.
- **Transverse processes.** Lateral bony processes arising from the vertebral arch.
- **Superior and inferior articular facets.** Bony projections that form synovial zygapophyseal (facet) joints with the vertebrae above and below.
- **Zygapophyseal (facet) joints.** Synovial joints located between adjacent superior and inferior articular facets; they enable vertebral flexion and extension and limit rotation.
- **Laminae.** Connect transverse and spinous processes.
- **Spinous process.** Posteriorly projecting tip of the vertebral arch; easily palpated beneath the skin.
- **Vertebral foramen.** Hole in the vertebra that contains the spinal cord; the series of vertebral foramina form the **vertebral canal.**
- **Intervertebral (neural) foramina.** Bilateral foramina that form the space between pedicles of adjacent vertebrae for the passage of spinal nerves.
- **Pars interarticularis (pars).** Region of the vertebra between the superior and inferior articular facets and the pedicle and lamina.
- **Intervertebral (IV) discs.** Located between adjacent vertebral bodies; composed of an **anulus fibrosus** (tough fibrocartilaginous rim), and a **nucleus pulposus** (softer fibrocartilaginous core) (Figure 1-4C). The IV discs absorb shock and bear weight because the spread of the nucleus pulposus is constrained by the anulus fibrosus. Approximately 25% of the height of the vertebral column is from the IV discs.

▽ **Herniated disc.** Damage to the anulus fibrosus may allow the softer nucleus pulposus to bulge or herniate posterolaterally (referred to as a "**slipped disc**"). The herniated disc may compress and irritate adjacent nerve roots, giving rise to symptoms typically associated with radicular pain (nerve root compression). Symptoms may include sensory disruptions along the associated dermatomal level (i.e., numbness, paresthesia, and pain from the neck down the arm or lower back down the leg). Occasionally motor disruptions, such as muscle weakness and hyporeflexia, may also be present. ▼

VERTEBRAL MODIFICATIONS

Each class of vertebrae has its own unique modifications:

- **Cervical vertebrae.**
  - **C1 (atlas) vertebra.** Articulates with the skull (occipital condyles), enabling the skull to nod up and down.
  - **C2 (axis) vertebra.** Has the odontoid process (dens), which through its articulation with C1 provides rotational movement (i.e., head movement indicating "no").
  - **Transverse foramen.** The transverse processes on C1–C6 have a foramen for the transmission of the vertebral arteries (branch from the subclavian arteries) to supply the brain.
  - **Bifid spinous process.** Short, forked spinous process.
- **Thoracic vertebrae.**
  - **Costal facets.** Twelve pairs of ribs articulate with 12 thoracic vertebrae at the costal facets.
  - **Spinous processes.** Project inferiorly to the level of the infra-adjacent vertebral body.
- **Lumbar vertebrae.** Massive vertebral bodies that support the pressure on the lower back.
  - **Mammillary processes.** Posteriorly located on superior articular facets; attachment site for multifidus muscle.
- **Sacral vertebrae.** Five fused vertebrae that are called the **sacrum**.
  - **Sacral foramina.** On the ventral and dorsal surface for the exit of ventral and dorsal rami; homologous with intervertebral foramina.
- **Coccygeal vertebrae.** Three to four fused vertebrae are called the **coccyx** or "tailbone."

VERTEBRAL LIGAMENTS

The vertebral column is stabilized by the following ligaments (Figure 1-4B):

- **Ligamentum flavum.** Connects paired laminae of adjacent vertebrae.
- **Supraspinous ligament.** Connects the apices of the spinous processes.
- **Interspinous ligament.** Connects adjoining spinous processes.
- **Nuchal ligament.** Extends from the external occipital protuberance along the spinous processes of C1–C7.
- **Posterior longitudinal ligament.** Courses longitudinally, down the posterior surface of the vertebral bodies within the vertebral canal. This ligament supports the intervertebral disc posteriorly, thus reducing the incidence of herniations that may compress the spinal cord and cauda equina.
- **Anterior longitudinal ligament**. Courses longitudinally along the anterior surface of the vertebral bodies limiting vertebral extension.

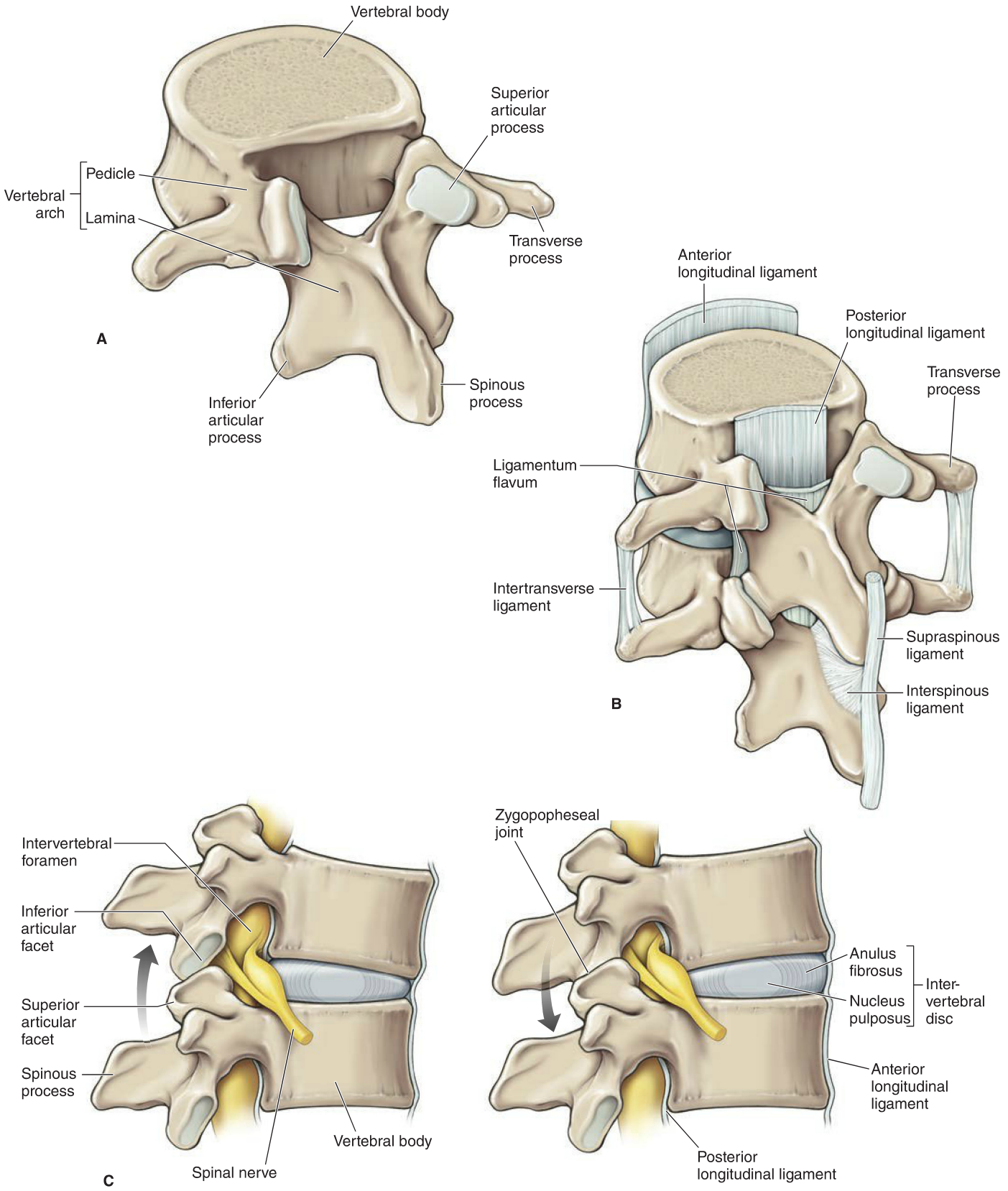

Figure 1-4: **A**. Posterolateral view of a typical vertebra. **B**. Vertebrae ligaments. **C**. Lateral view of two vertebrae and intervertebral (IV) discs; observe the IV discs and facet joints during vertebral flexion and extension.

SPINAL MENINGES

BIG PICTURE

The brain and spinal cord are surrounded and protected by three layers of connective tissue meninges called the dura mater, arachnoid mater, and pia mater (Figure 1-5A and B).

DURA MATER

Forms the superficial meningeal layer and defines the epidural and subdural spaces.

- Consists of dense fibrous connective tissue and surrounds the brain and spinal cord.
- The dura mater evaginates into each intervertebral foramen, becoming continuous with the epineurium around each spinal nerve; nerve roots in the subarachnoid space lack dura mater and are therefore more fragile than spinal nerves.
- Spinal cord dura mater receives general sensory innervation from **recurrent meningeal nerves** from each spinal nerve segment.

Epidural space. The epidural space is the region between the dura mater and vertebral canal. An anesthetic agent injected into the epidural space anesthetizes the spinal nerve roots exiting the vertebral canal in that region. Epidural blocks are particularly useful for procedures involving the pelvis and perineum, such as during childbirth.

Meningitis. The sensory neurons in the dura mater may be involved in referred pain characteristics of spinal disorders and become irritated when the meninges are inflamed as in meningitis. For example, if a patient with meningitis tries to touch her chin to her chest, she may experience pain due to the stretching of the meninges surrounding the cervical spinal cord.

ARACHNOID MATER

Forms the intermediate meningeal layer and attaches to the underlying pia mater via arachnoid trabeculae.

- **Subarachnoid space.** The space between the arachnoid and pial layers, which contains **cerebrospinal fluid (CSF)** (suspends and protects the spinal cord, brain, nerve roots, and large vessels); the inferior portion of the subarachnoid space between the conus medullaris and S2 vertebral level contains only spinal roots and the filum terminale (Figure 1-5C).

Lumbar puncture. The spinal cord terminates in an adult at the L1–L2 vertebral level, whereas the subarachnoid space containing CSF extends to the S2 vertebral level. Therefore, CSF can be obtained inferior to the L2 vertebral level without danger of injuring the spinal cord. To perform a lumbar puncture, the patient typically is asked to lie on his/her side or is placed in a sitting position so that the spine is fully flexed to open up the intervertebral spaces.

PIA MATER

Forms the deepest meningeal layer, is inseparably attached to the spinal cord, and contains a small plexus of small blood vessels.

- **Denticulate ligaments.** Located in the coronal plane as a series of sawtooth projections of the pia mater that separate ventral and dorsal rootlets; the ligaments anchor the spinal cord laterally to the dura mater maintaining the centralized location of the spinal cord.
- **Filum terminale.** An inferior extension of pia mater beyond the conus medullaris that anchors the spinal cord to the coccyx.

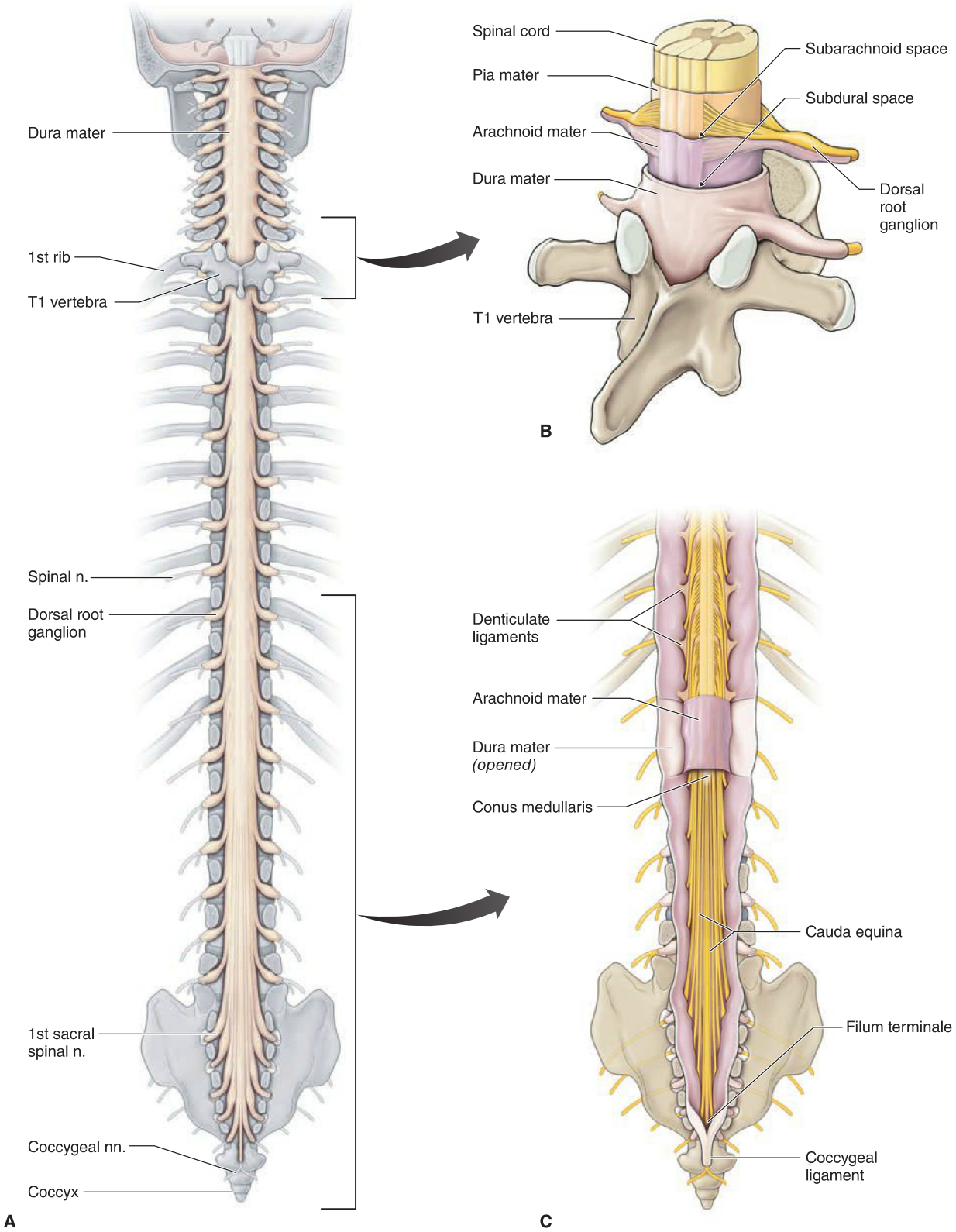

Figure 1-5: A. Coronal section of the vertebral column through the pedicles from a posterior view revealing the dura mater surrounding the spinal cord. **B.** T1 segment of the spinal cord showing step dissection of the spinal meninges. **C.** Caudal spinal cord (filum terminale is difficult to see).

SPINAL CORD

BIG PICTURE

The spinal cord is a part of the central nervous system (CNS) and consists of ~100 million neurons and ~500 million glial cells. The spinal cord resides in the vertebral canal where it is surrounded and protected by the meninges (dura mater, arachnoid mater, and pia mater). Spinal nerves transport sensory input from body tissues to the spinal cord; the CNS processes these messages and sends appropriate motor responses to muscles and glands by way of spinal nerves. The spinal cord consists of white matter (longitudinal tracts of myelinated axons) and gray matter (neuronal cell bodies).

TOPOGRAPHY AND OVERVIEW

- The spinal cord extends from the medulla to the **conus medullaris** at the L1 and L2 vertebral levels (Figure 1-6A). In a term newborn, the spinal cord terminates at the L3 and L4 vertebral levels.
- The spinal cord is segmentally organized into the following 31 segments (Table 1-3):
  - 8 cervical spinal cord segments corresponding to the 8 cervical spinal nerves.
  - 12 thoracic spinal cord segments corresponding to the 12 thoracic spinal nerves.
  - 5 lumbar spinal cord segments corresponding to the 5 lumbar spinal nerves.
  - 5 sacral spinal cord segments corresponding to the 5 sacral spinal nerves.
  - 1 coccygeal spinal cord segment corresponding to the 1 coccygeal spinal nerve.
- There are eight cervical spinal cord and spinal nerve levels but only seven cervical vertebrae. This discrepancy results because the basiooccipital bone is a cervical vertebra. However, early anatomists did not recognize this. Therefore, we actually have eight cervical vertebrae, but the most superior one is fused to the base of the occipital bone.
- In cross-section, the spinal cord consists of white matter surrounding gray matter, and a central canal (Figure 1-6B).

WHITE MATTER OF THE SPINAL CORD

- Consists of vertical columns of myelinated axons that surround a central core of gray matter (the white color is a result of the myelin that surrounds the axons).
- Collections of axons that perform similar functions and travel to and from the same areas are referred to as **tracts**.
- Ascending axonal tracts transport sensory information from the dorsal roots and horns to the brain; descending axonal tracts transport efferent information from the brain to the ventral horn gray matter.
- The volume of white matter increases at each successively higher spinal cord segment and decreases at each lower spinal cord segment (compare Figures 1-6B–E). For example:
  - Cervical spinal cord levels have the most white matter due to the highest number of ascending and descending axons coming from and going to the rest of the spinal cord.
  - Sacral spinal cord levels have the least white matter because the majority of ascending axons arise above the sacral spinal cord and most descending axons have already synapsed in a more superior spinal cord segment.

GRAY MATTER OF THE SPINAL CORD

- Consists primarily of neuronal cell bodies and short interneurons (the gray color is a result of a lack of myelin).
- In cross-section, the spinal cord gray matter forms the letter "H" and consists of ventral, lateral, and dorsal horns.
- **Ventral horn.** Contains cell bodies of motor neurons whose axons exit the ventral root to innervate deep back muscles (via dorsal rami) and body wall and limb muscles (via ventral rami); the ventral horn is not uniform in size along the length of the spinal cord.
  - **Cervical spinal enlargement.** Ventral horn gray matter in the C5–T1 spinal cord levels contains a large number of motor neuron cell bodies to innervate the upper limb muscles. This results in the expanded width (enlargement) of this spinal cord region.
  - **Lumbosacral spinal enlargement.** Ventral horn gray matter in the L2–S3 spinal cord levels contains a large number of motor neuron cell bodies to innervate the lower limb muscles. This results in the expanded width (enlargement) of this spinal cord region.
- **Lateral horn.** Contains cell bodies for preganglionic autonomic motor neurons and is only seen in some regions of the spinal cord, as identified next.
  - **Sympathetic**. Preganglionic sympathetic neuronal cell bodies arise only in the lateral horns of the T1–L2 spinal cord levels.
  - **Parasympathetic**. Preganglionic parasympathetic neuronal cell bodies arise only in the lateral horns of the S2–S4 spinal cord levels; due to the large ventral horns in this region, it is difficult to distinguish the lateral horns in the sacral spinal cord.
- **Dorsal horn.** Receives sensory neurons entering the spinal cord via the dorsal roots; also contains cell bodies of interneurons that communicate with motor neurons in the ventral horn or ascending tracts of white matter.
- **Central canal.** Located within the middle of the gray matter as an adult remnant of the neural tube.
- **Conus medullaris.** The most caudal portion of the spinal cord; contains the sacral and coccygeal spinal cord segments and is located at the L1–L2 vertebral level.

Contrasting vertebral and spinal cord levels. The vertebral canal is longer than the spinal cord in adults as a result of unequal growth during development. Therefore, a patient with a **C3 vertebral fracture** potentially could have a bone fragment that would impinge upon the C3 spinal cord segment. However, a patient with a **T10 vertebral fracture** potentially could have a bone fragment that would impinge upon the L1 segment of the spinal cord.

Poliomyelitis. A virus that attacks the neurons in the ventral horn gray matter and causes paralysis of voluntary muscle.

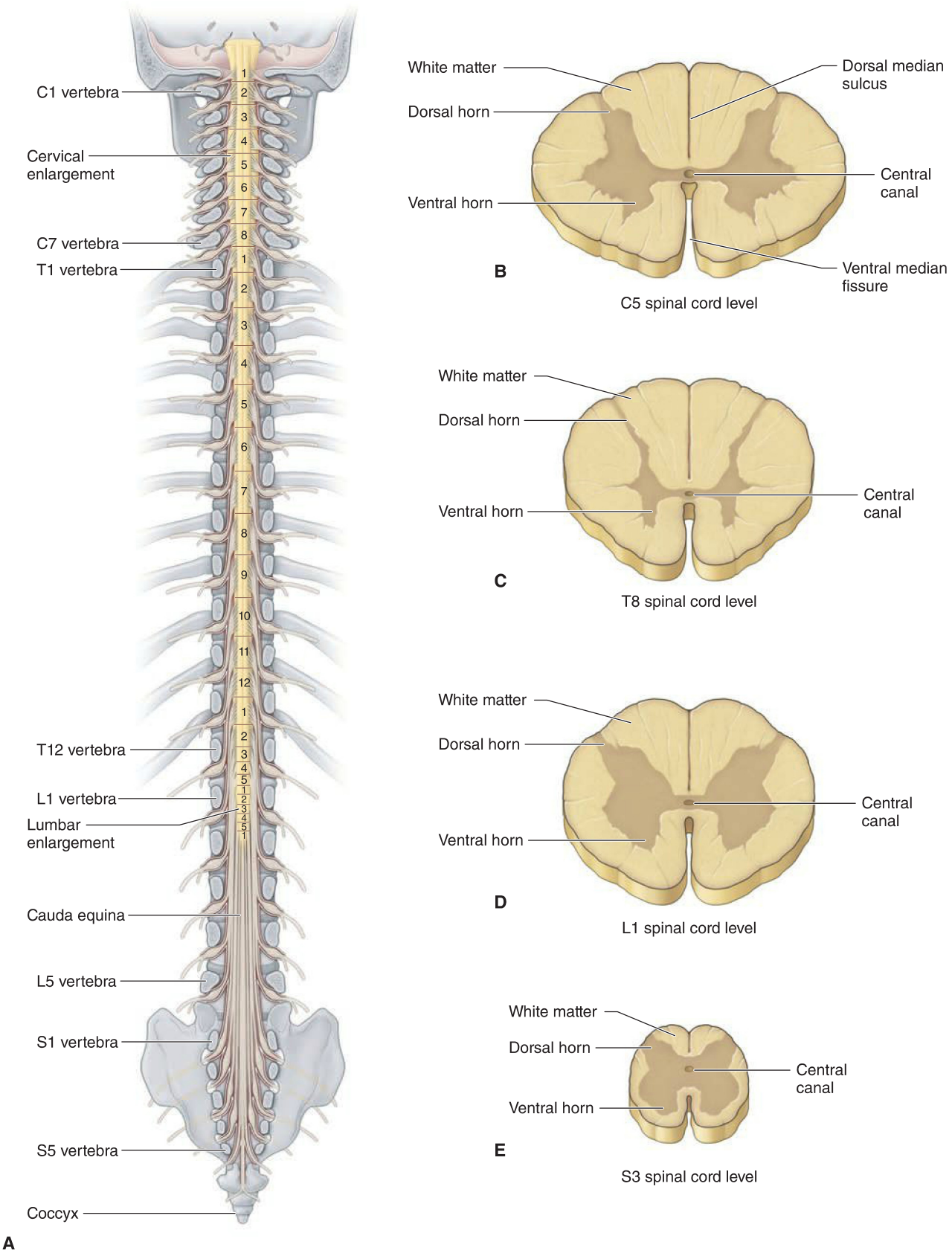

Figure 1-6: A. Posterior view of the coronal section of the vertebral canal. (Levels of the spinal cord are identified within the vertebral canal.). **B–E**. C5, T8, L1, and S3 cross-sections of the spinal cord (compare and contrast gray and white matter at the various levels).

SPINAL NERVES

BIG PICTURE

Spinal nerves consist of ventral and dorsal roots, a spinal nerve trunk, and ventral and dorsal rami. Each spinal cord level gives rise to bilateral dorsal and ventral rootlets, which exit the spinal cord laterally. The rootlets unite to form the segmental dorsal and ventral roots. The roots unite to form left and right spinal nerve trunks, which further divide into a ventral ramus (supplying the limbs and anterolateral body wall) and dorsal ramus (supplying the deep back muscles and skin of the back).

SPINAL ROOTS

Spinal roots arise from the left and right side of each segment of the spinal cord and are classified as either a ventral root or a dorsal root. Ventral and dorsal roots are separated from each other within the vertebral canal by the denticulate ligaments (Figure 1-7A and B).

- **Function.** Spinal roots are like one-way streets:
  - **Ventral root.** Conveys motor neurons, which conduct their impulses in only one direction … away from the spinal cord.
  - **Dorsal root.** Conveys sensory neurons, which conduct their impulses in only one direction … toward the spinal cord (the **dorsal root ganglion** is a swelling that houses cell bodies of all sensory neurons entering the spinal cord at that segmental level on that side).
- **Course.** The vertebral canal is longer than the spinal cord in adults due to unequal growth during fetal development. Consequently, nerve roots in the upper vertebral canal course horizontally, in the middle obliquely and in the bottom vertically.
  - At their respective intervertebral foramen, ventral and dorsal roots unite to form the spinal nerve trunk.
- **Cauda equina.** The spinal cord terminates at the L1–L2 vertebral level in adults. Therefore, the lumbar and sacral nerve roots descending in the vertebral canal below the L1 vertebral level form a vertical collection of nerve roots that resembles the tail of a horse (hence, the name cauda equina) (Figure 1-7C).
  - The cauda equina floats in the CSF; therefore, a needle introduced into the subarachnoid space below the L2 vertebral level will displace the roots with little possibility of damage to them or the spinal cord.

SPINAL NERVE TRUNK

The 31 pairs of spinal nerve trunks are formed by ventral and dorsal roots, and as such together are considered two-way streets in that both motor and sensory neurons are contained within. The spinal nerve trunks are short and are organized as follows (Figure 1-7A; Table 1-3):

- **Eight cervical spinal nerves.** The C1–C7 spinal nerves exit the vertebral canal superior to their respective cervical vertebrae. The C8 spinal nerve exits inferior to the C7 vertebra. All of the remaining spinal nerves segmentally exit the vertebral canal inferior to their respective vertebra.
- **Twelve thoracic spinal nerves.** Exit inferior to their respective thoracic vertebrae.
- **Five lumbar spinal nerves.** Exit inferior to their respective lumbar vertebrae.
- **Five sacral spinal nerves.** Exit inferiorly through their respective sacral foramina of the sacrum.
- **One coccyx spinal nerve.** Exits by the coccyx bone.

▽ **Contrasting vertebral and spinal nerve levels.** Cervical spinal nerves exit the vertebral column superior to their associated vertebra (i.e., the C4 spinal nerve trunk exits between the C3 and C4 vertebrae). All other spinal nerves (thoracic, lumbar, sacral, and coccygeal) exit the vertebral column inferior to their associated vertebra (i.e., the L4 spinal nerve trunk exits between the L4 and L5 vertebrae). ▼

RAMI

Each spinal nerve trunk traverses the intervertebral foramen and immediately bifurcates into a ventral ramus and a dorsal ramus (Figure 1-7B). Similar to spinal nerve trunks, most rami are mixed (contain both motor and sensory nerve fibers).

- **Ventral ramus.** Transports sensory nerve fibers from and motor nerve fibers to the anterolateral body wall and upper and lower limbs in a segmental fashion.
  - Ventral rami form the nerve plexuses of the body (i.e., cervical plexus, brachial plexus, lumbar plexus, and sacral plexus).
- **Dorsal ramus.** Transports sensory nerve fibers from the skin of the back between mid-scapular lines and motor nerve fibers to the deep back muscles (e.g., erector spinae muscles).

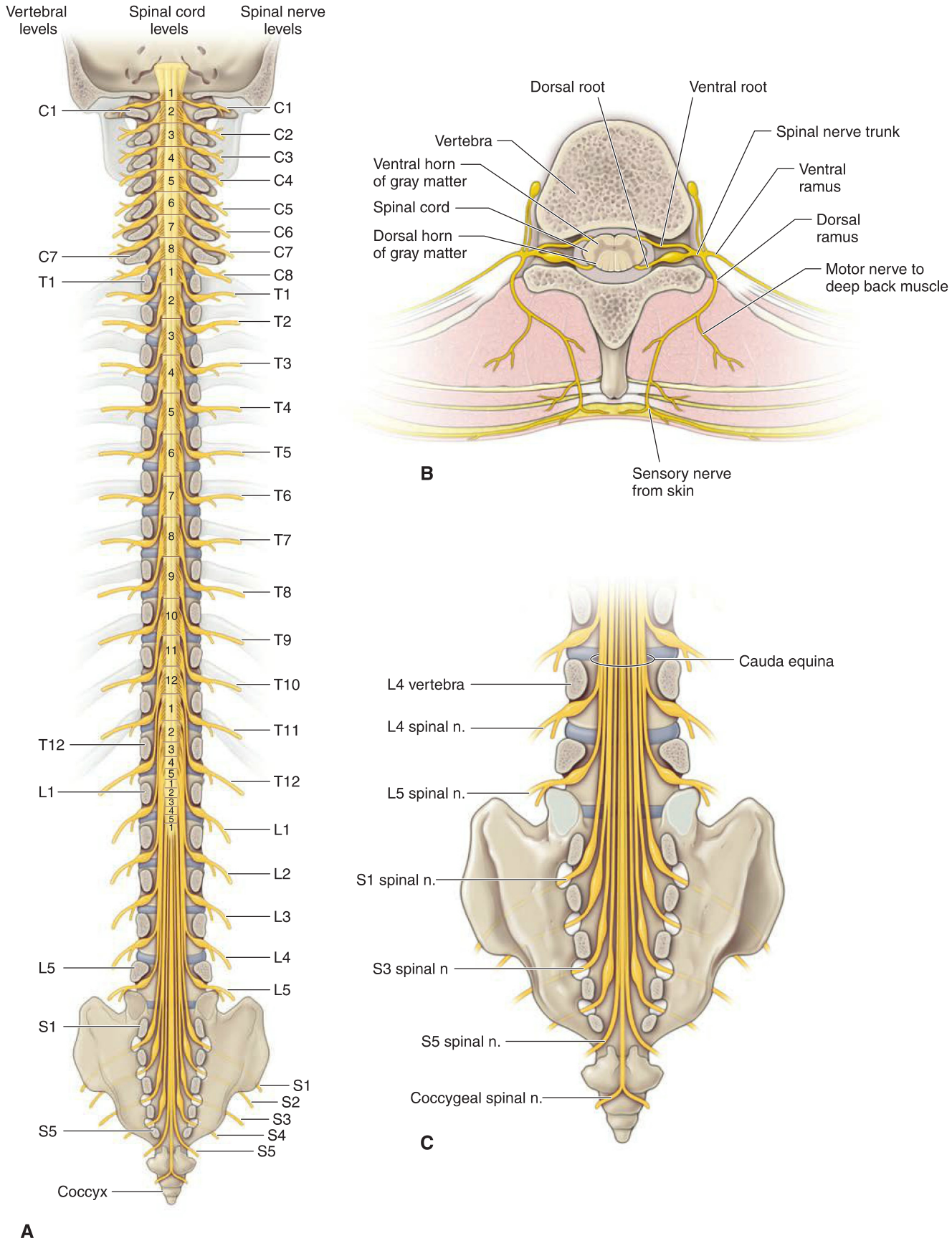

Figure 1-7: **A**. Coronal section of the vertebral canal from the posterior view. **B**. Cross-section through the back showing spinal roots, nerves, and rami. **C**. Caudal end of the vertebral canal with the cauda equina.

DERMATOMES

A dermatome is defined as an area of skin supplied by a single spinal cord level, on one side, by a single spinal nerve. Dermatomes are arranged in a segmental fashion and reflect their associated spinal cord levels. Adjacent dermatomes are often located so close together that their territories overlap, which explains why the clinically detectable areas of sensory loss caused by a segmental nerve lesion may be smaller than the dermatome itself (… and in some cases there may be no detectable sensory loss at all). Touch is used to test these areas of skin in a conscious patient in order to localize lesions to a specific nerve or spinal cord level. The following are the primary places to touch in order to test specific dermatomes (Figure 1-7D):

- **C5.** Lateral side of the elbow.
- **C6.** Dorsal surface of the proximal phalanx of the thumb.
- **C7.** Dorsal surface of the proximal phalanx of the middle finger.
- **C8.** Dorsal surface of the proximal phalanx of the little finger.
- **T1.** Medial side of the elbow.
- **T4.** Midclavicular line at the level of the nipple.
- **T10.** Midclavicular line at the level of the umbilicus.
- **L3.** Medial femoral condyle above the knee.
- **L4.** Over the medial malleolus.
- **L5.** Dorsum of the foot over the third metatarsal phalangeal joint.
- **S1.** Lateral aspect of the calcaneus (heel).
- **S2.** Midpoint of the popliteal fossa.
- **S4–S5.** Perianal region just beside the opening of the sphincter.

MYOTOMES

A myotome is defined as a group of skeletal muscles innervated by a single spinal cord level, on one side, by a single spinal nerve. Myotomes may be more difficult to test than dermatomes because each skeletal muscle in the body is usually innervated by nerves derived from more than one spinal cord level. The following are the myotomes that represent the motor innervation by the cervical and lumbosacral spinal cord levels (thoracic levels are not included because these levels are easier to test from sensory levels):

- **C5.** Elbow flexors (bend the elbow).
- **C6.** Wrist extensors (straightening the wrist).
- **C7.** Elbow extensors (straightening the elbow).
- **C8.** Finger flexors (bending fingers).
- **T1.** Finger abductors (spreading fingers apart).
- **L2.** Hip flexors (lift knee off the ground).
- **L3.** Knee extensors (straightening the knee).
- **L4.** Ankle dorsiflexors (lift foot off the ground).
- **L5.** Long toe extensors (lift toe off the ground).
- **S1.** Ankle plantar flexors (stand on tip-toes).
- **S4–S5.** Voluntary anal contraction.

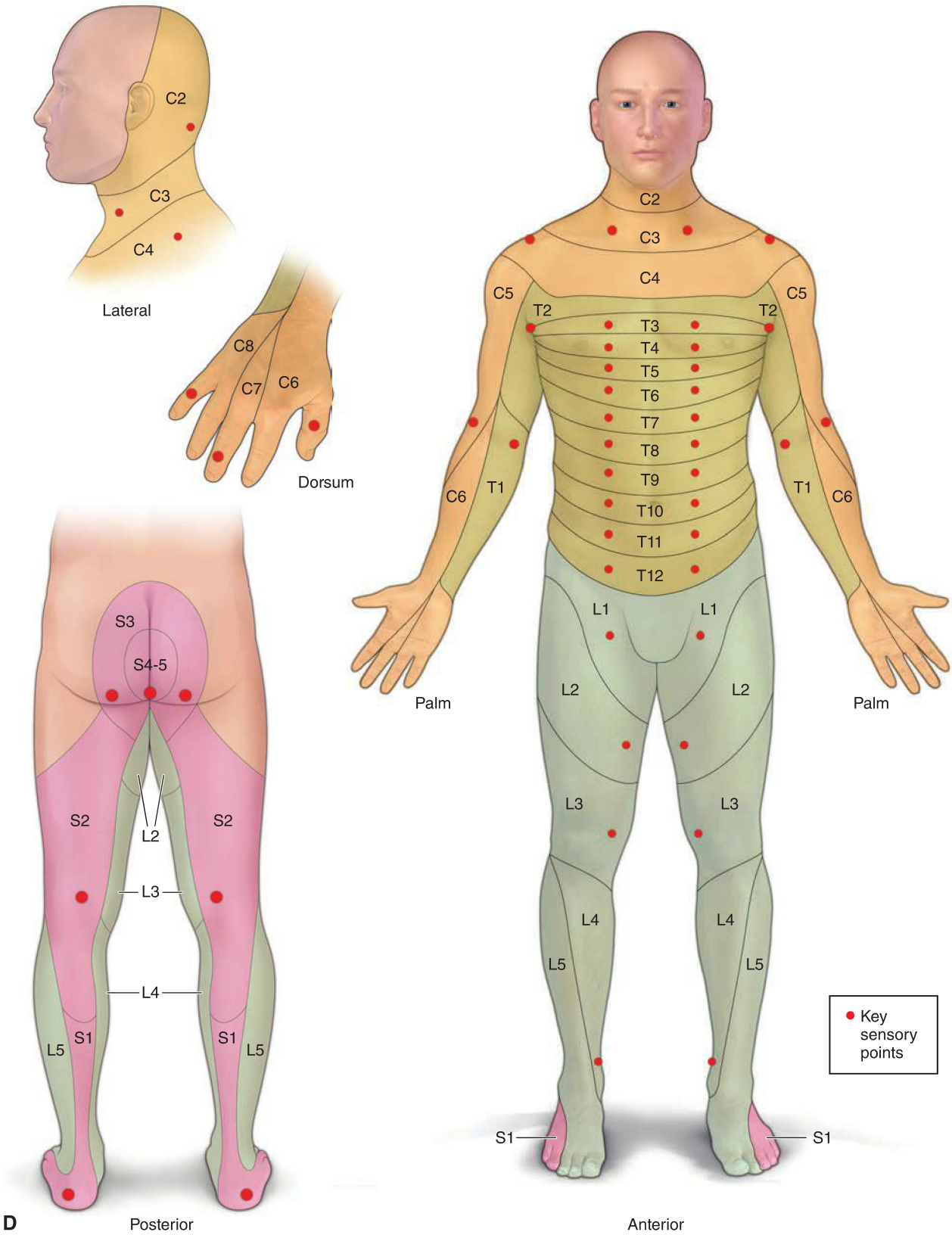

Figure 1-7: (*continued*) **D.** Dermatomes mapping key sensory points to test spinal cord levels.

TABLE 1-1. Superficial Muscles of the Back

Muscle	Proximal Attachment	Distal Attachment	Action	Innervation
Trapezius	Occipital bone, nuchal ligament, and spinous processes of C7–T12 vertebrae	Spine of scapula, acromion, and lateral third of clavicle	Elevates, retracts, depresses, and upwardly rotates scapula	Motor: spinal root of accessory n. (CN XI); proprioception: cervical nn. (C3–C4)
Levator scapulae	Transverse processes of C1–C4 vertebrae	Medial border of the superior angle of scapula	Elevates and rotates scapula; lateral flexion of the neck	Dorsal scapular n. (C5)
Rhomboid major	Spinous processes of T2–T5 vertebrae	Medial margin of scapula	Retracts scapula	Dorsal scapular n. (C5)
Rhomboid minor	Spinous processes of C7–T1 vertebrae	Medial margin of scapula	Retracts scapula	Dorsal scapular n. (C5)
Latissimus dorsi	Spinous processes of T7 sacrum, thoracolumbar fascia, iliac crest, and inferior ribs	Intertubercular groove of humerus	Extends, adducts, and medially rotates humerus	Thoracodorsal n. (C6–C8)

TABLE 1-2. Deep Muscles of the Back

Muscle	Proximal Attachment	Distal Attachment	Action	Innervation
Splenius capitis	Nuchal ligament, spinous processes of C7–T4 vertebrae	Mastoid process of temporal bone and occipital bone	Bilaterally extends the head and neck; unilaterally bends and rotates head	Segmentally innervated by dorsal rami
Splenius cervicis	Spinous processes of T3–T6	Transverse processes of C1–C3		
Erector spinae group (a group of muscles that extends from the sacrum to the skull)				
• Iliocostalis	Iliac crest, sacrum, ribs	Thoracolumbar fascia, ribs, cervical vertebrae	Bilaterally, extends the vertebral column Unilaterally, lateral flexes the vertebral column	Segmentally innervated by dorsal rami
• Longissimus	Thoracodorsal fascia, transverse and cervical vertebrae	Vertebrae and mastoid process of temporal bone		
• Spinalis	Spinous processes of vertebrae	Spinous processes of vertebrae		
Transversospinalis group (a group of muscles that extends from transverse to spinous processes)				
• Semispinalis	Transverse processes of thoracic vertebrae	Spinous processes of thoracic and cervical vertebrae and occipital bone	Bilaterally, extends vertebral column; unilaterally rotates vertebral column contralaterally	Segmentally innervated by dorsal rami
• Multifidus	Sacrum and transverse processes of lumbar, thoracic, and cervical vertebrae	Spinous processes of lumbar, thoracic, and lower cervical vertebrae		
• Rotatores	Transverse processes of C2 vertebra to the sacrum	Lamina immediately above the vertebra of origin		

TABLE 1-3. Vertebral, Spinal Cord, and Spinal Nerve Levels

Region	Number of Vertebrae	Number of Spinal Nerve Levels	Number of Spinal Cord Levels
Cervical	7	8	8
Thoracic	12	12	12
Lumbar	5	5	5
Sacral	5 (fused)	5	5
Coccygeal	3–4 (fused)	1	1

STUDY QUESTIONS

Directions: Each of the numbered items or incomplete statements is followed by lettered options. Select the letter that most likely represents the best option for each question.

1. A 48-year-old man goes to his physician because of pain and paresthesia along the lateral aspect of the leg and the dorsum of the foot. The patient's symptoms suggest impingement of the L5 spinal nerve resulting from a herniated intervertebral disc. The L5 spinal nerve most likely exits between which of the following vertebrae?

A. L3–L4 vertebrae
B. L4–L5 vertebrae
C. L5–S1 vertebrae
D. S1–S2 vertebrae

2. The muscles of the posterior aspect of the thigh, or hamstring musculature, are responsible for flexing the knee joint. Beginning with the motor neuron cell bodies in the gray matter of the spinal cord, identify the most likely pathway that axons would travel from the spinal cord to the hamstring muscles?

A. Ventral horn, ventral root, ventral ramus
B. Ventral horn, ventral root, dorsal ramus
C. Lateral horn, ventral root, ventral ramus
D. Lateral horn, dorsal root, dorsal ramus
E. Dorsal horn, dorsal root, ventral ramus
F. Dorsal horn, dorsal root, dorsal ramus

3. A 27-year-old man is brought to the emergency department after being involved in an automobile accident. Radiographic imaging studies indicate that he has sustained a fracture of the L1 vertebral arch and has a partially dislocated bone fragment impinging upon the underlying spinal cord. Which spinal cord level is most likely compressed by this bone fragment?

A. C1
B. L2
C. S3
D. T4

4. A 50-year-old man is diagnosed with flaccid paralysis limited to the right arm, without pain or paresthesias. No sensory deficits are noted. Laboratory studies reveal that the patient is infected with West Nile virus. The target that the virus has infected resulting in this patient's symptoms is most likely the

A. Ventral horn of spinal cord gray matter
B. Ventral rami of spinal nerves
C. Dorsal horn of spinal cord gray matter
D. Dorsal rami of spinal nerves

5. A 6-year-old boy is stung by a wasp between his shoulder blades. Identify the pain sensation pathway the axons would travel to course from the skin of his back to the spinal cord.

A. Ventral horn, dorsal root, dorsal ramus
B. Ventral horn, dorsal root, ventral ramus
C. Ventral horn, ventral root, dorsal ramus
D. Ventral horn, ventral root, ventral ramus
E. Dorsal ramus, dorsal root, dorsal horn
F. Dorsal ramus, dorsal root, ventral horn
G. Dorsal ramus, ventral root, ventral horn
H. Dorsal ramus, ventral root, dorsal horn

6. Which of the following paired muscles of the back is primarily responsible for extension of the vertebral column?

A. Iliocostalis
B. Latissimus dorsi
C. Levator costarum
D. Rhomboid major and minor
E. Trapezius

7. A 44-year-old woman is suspected of having meningitis. To confirm the diagnosis, a lumbar puncture is ordered to collect a sample of the cerebrospinal fluid (CSF). Identify the last layer of tissue the needle will traverse in this procedure before reaching CSF.

A. Arachnoid mater
B. Dura mater
C. Ligamentum flavum
D. Pia mater
E. Skin

ANSWERS

1—C: Spinal nerves in the thoracic and lumbar vertebral region exit the vertebral canal below their associated vertebra. Therefore, the L5 spinal nerve exits below L5, between L5 and S1.

2—A: The ventral horn of the spinal cord gray matter houses motor neuron cell bodies and conveys motor neurons out through the ventral root into the segmental spinal nerve. All muscles of the limbs and body wall are innervated by ventral rami. Although the muscles are present along the posterior aspect of the thigh, muscles are still innervated by the ventral rami. Dorsal rami innervate the skin of the back and the deep back muscles, such as the erector spinae.

3—C: In an adult, the caudal end of the spinal cord is at the L1–L2 vertebral level. Therefore, a bone fragment from the L1 vertebra would have the potential of touching the caudal end of the spinal cord, not the L1 spinal cord level. C1, L2, and T4 are spinal cord levels superior to the fracture.

4—A: The patient has no sensory deficits and presents with only motor deficits. Therefore, the virus affects the ventral horn of the gray matter because that is the location of the motor neuron cell bodies.

5—E: All skin of the back is segmentally innervated by the dorsal rami branches of spinal nerves. Sensory information is then conducted through the dorsal root into the dorsal horn of the gray matter of the spinal cord.

6—A: The paired iliocostalis muscles, part of the erector spinae musculature, are postural muscles that help to extend the vertebral column and thus keep the spine erect. The latissimus dorsi, rhomboids, and trapezius muscles act primarily on the upper limb. The levator costarum muscles help elevate the ribs during inspiration but will not extend the vertebral column.

7—A: A lumbar puncture collects cerebrospinal fluid and, therefore, the needle has to enter the subarachnoid space, which is located between the arachnoid and pia mater. Therefore, the last layer of tissue the needle would traverse to enter the subarachnoid space is the arachnoid mater.

This page intentionally left blank

SECTION 2

THORAX

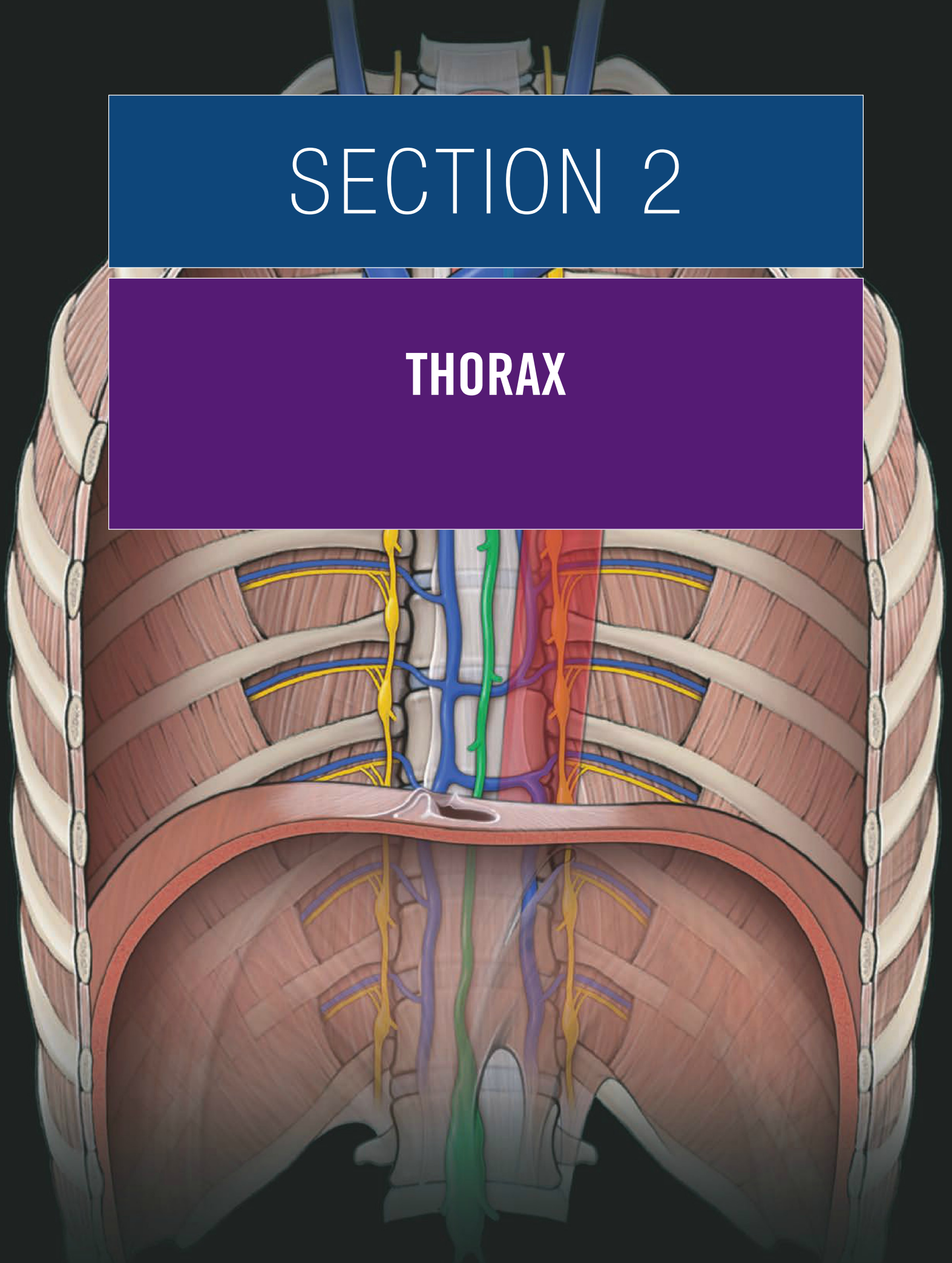

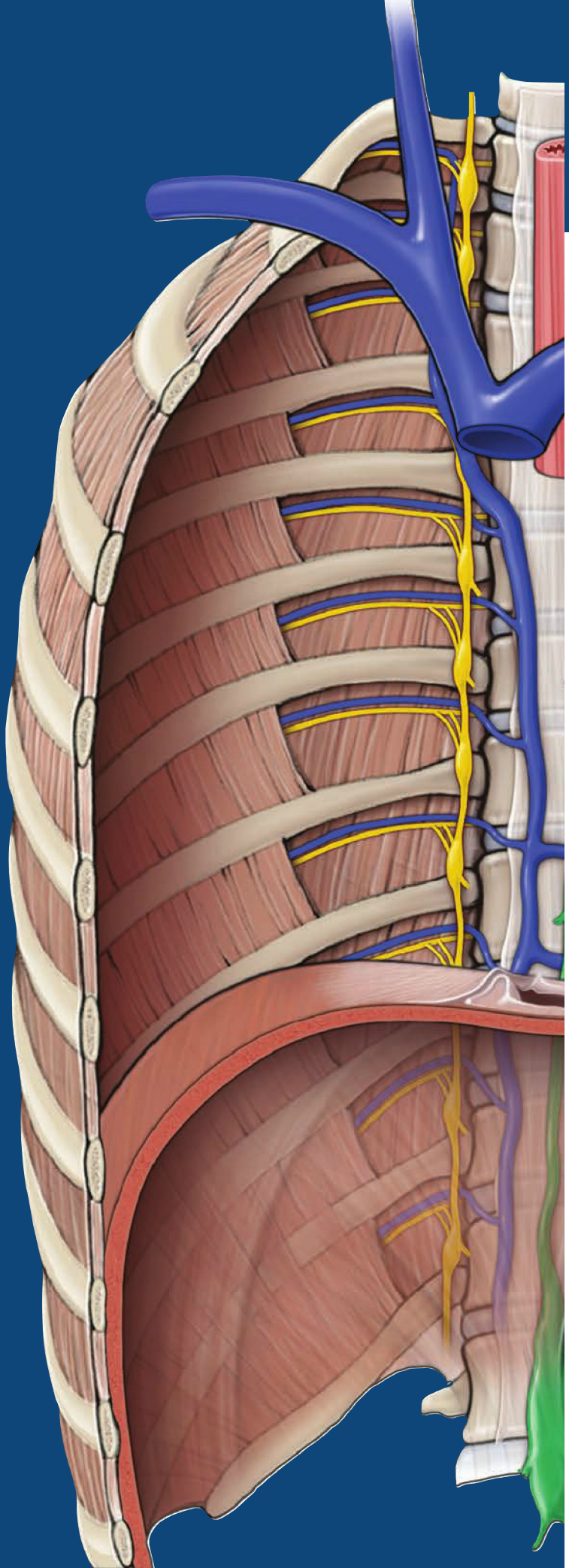

CHAPTER 2

ANTERIOR THORACIC WALL

The Breast 28
Thoracic Muscles 30
Thoracic Skeleton 32
Nerves of the Thoracic Wall 34
Vasculature of the Thoracic Wall 36
Diaphragm 38

THE BREAST

BIG PICTURE

The functional component of the breast is the mammary gland, which synthesizes, secretes, and delivers milk to the newborn. It is only during a pregnancy that the mammary glands reach a mature state of development by way of circulating female hormones. Both men and women have breasts but the male mammary glands do not develop under normal circumstances. Lobules within mammary glands produce milk and the lactiferous ducts transport the milk into openings in the nipples. Branches of the internal thoracic, axillary, and intercostal arteries supply the mammary glands. Lymph from the mammary glands primarily drains into axillary lymph nodes, and also into the pectoral, clavicular, and parasternal nodes.

MAMMARY GLAND STRUCTURE

The mammary gland is located within the superficial fascia and is surrounded by a variable amount of adipose tissue. The breast overlies the pectoralis major and serratus anterior muscles on ribs 2–6 (Figure 2-1A and B).

- **Lobules.** Each mammary gland consists of 15 to 20 radially aligned lobes of glandular tissue, which synthesizes and produces milk; each lobe has a **lactiferous duct** that opens onto the surface of the nipple.
- **Nipple.** The nipple is positioned on the anterior surface of the breast and is surrounded by a circular hyperpigmented region called the **areola**; small collections of smooth muscle at the base may cause erection of the nipple when breastfeeding or when sexually aroused.
- **Suspensory (Cooper's) ligaments.** Bands of fibrous connective tissue that support the breast and maintain its normal shape; the fibrous bands course from the deep fascia, through the breast tissue, and terminate in the dermis.
- **Retromammary space.** A layer of loose connective tissue that separates the breast from the deep fascia overlying the pectoralis major and serratus anterior muscles.
- **Axillary tail.** Mammary gland tissue that extends along the inferior border of the pectoralis major muscle into the axilla.

Breast cancer. Breast cancer is cancer that arises from breast tissue. The phrase "adenocarcinoma of the breast" can be thought of as an overarching term for breast cancer because "adeno" refers to "glands" and "carcinoma" refers to "cancer." The breast is primarily composed of the glandular tissue (lactiferous ducts or lobules of the mammary gland). Breast adenocarcinomas are classified as either noninvasive (referred to as ductal carcinoma in situ or DCIS) or invasive. DCIS tumors are abnormal epithelial cells that remain contained in the mammary gland. Invasive tumors spread from the original site (either lactiferous ducts or lobules) into the lymphatic system and could travel to downstream lymph nodes (often axillary nodes). Inflammatory carcinoma of the mammary gland is a very rare but aggressive disease whereby neoplastic cells block the local lymphatic drainage, which causes the breast to appear red and swollen. One of the criteria used to diagnose inflammatory breast cancer is a "peau d'orange" (dimpled or pitted skin) appearance of the skin overlying the breast. The dimpling occurs because as the breast swells the skin remains tethered to the deep fascia via the suspensory ligaments (of Cooper) and appears much like the peel of an orange (hence the French name "peau d'orange").

ARTERIES, VEINS, AND LYMPHATICS OF THE BREAST

Arteries, veins, and lymphatics of the breast (Figure 2-1C and D):

- **Arteries.** Perforating branches from the internal thoracic (mammary), lateral thoracic, and posterior intercostal arteries.
- **Veins.** Tributaries from the internal thoracic, lateral thoracic, and posterior intercostal veins.
- **Lymphatics.** Most of the lymphatic drainage from the breast, including the nipple, drain into the axillary lymph nodes; some lymph from the medial region of the breast drain into the parasternal and supraclavicular lymph nodes, and may cross the midline or reach inguinal lymph nodes.
  - Lymph from the right breast eventually drains into the **right lymphatic duct** at the junction of the right brachiocephalic vein.
  - Lymph from the left breast (not shown in figure) drains into the **thoracic lymphatic duct** at the left brachiocephalic vein junction.
  - Some of the prominent lymph nodes in the axillary region are as follows:
    - **Humeral (lateral) nodes.** Located posteriorly to the axillary vein and receive lymph from the upper limb.
    - **Pectoral (anterior) nodes.** Located along the distal border of the pectoralis minor muscle; drain the breast and body wall.
    - **Subscapular (posterior) nodes.** Located along the posterior wall of the axilla; drain the axilla, shoulder, and body wall.
    - **Central nodes.** Embedded in the axillary fat and receive lymph from the humeral, pectoral, and subscapular nodes.
    - **Apical nodes.** Surround the axillary vein near the pectoralis minor muscle; drain all other axillary nodes and lymphatic vessels from the mammary gland into the subclavian vein.

Lymphedema. Lymphedema, the accumulation of fluid in tissues, may result when lymph nodes or lymphatic vessels are blocked or surgically removed. A patient with breast cancer, who has undergone axillary lymph node dissection or radiation therapy, or both, is at risk of developing lymphedema because of the removal or damage of the lymph nodes and small lymphatic vessels. Symptoms include persistent accumulation of a protein-rich fluid in the interstitial tissues and swelling of the upper limb on the affected side.

INNERVATION OF THE BREAST

Sensory innervation:

- **Intercostal nerves.** Lateral and anterior cutaneous branches of the second to seventh intercostal nerves provide general sensory innervation to the skin overlying the breast.
- The nipple is located within the T4 dermatome level.

Note: Physiologic changes in the breast are not mediated by nerves but by circulating hormones (i.e., high prolactin levels result in milk production, and oxytocin causes the milk "letdown" reflex).

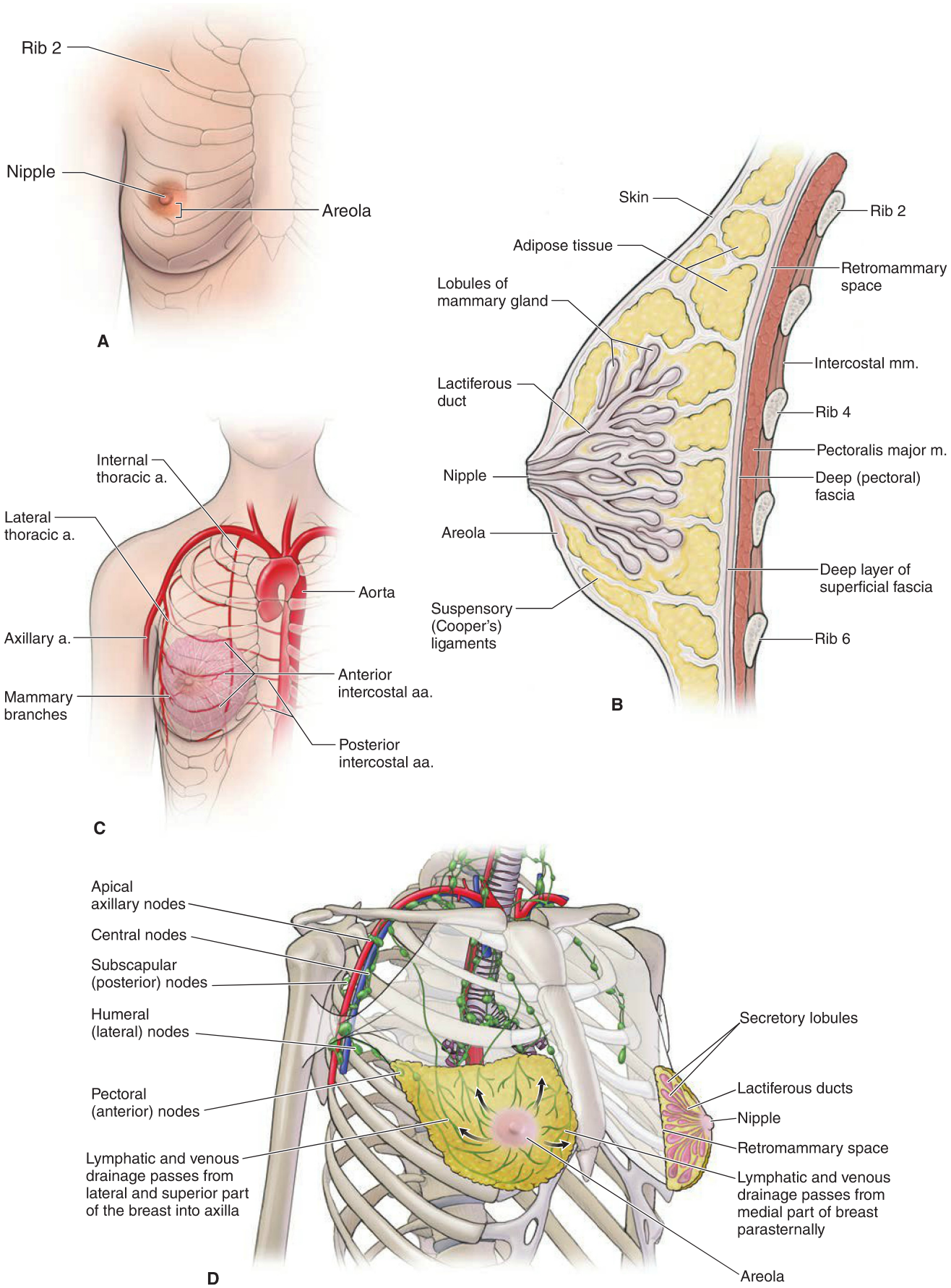

Figure 2-1: **A**. Breast surface anatomy. **B**. Sagittal section of the breast. **C**. Arterial supply of the breast. **D**. Lymphatic drainage of the breast.

THORACIC MUSCLES

BIG PICTURE

Similar to the back, the muscles of the anterolateral thoracic wall are organized into a superficial group and a deep group (Table 2-2):

- **Superficial thoracic muscles.** Muscles that are located on the anterior region of the thoracic cage, but are really upper limb muscles because they attach to and act upon the upper limb and are innervated by branches of the brachial plexus.
- **Deep thoracic muscles.** The true muscles of the thoracic cage; muscles that are located within the intercostal (IC) spaces that act primarily on the rib cage.

SUPERFICIAL THORACIC MUSCLES

The superficial muscles attached to the anterior portion of the thorax primarily act on the scapula and humerus. These muscles are shown in Figure 2-2A and include the following:

- **Pectoralis major muscle.**
  - **Attachments.** Sternum, clavicle, costal margins, and intertubercular groove of the humerus.
  - **Action(s).** Flexor, adductor, and medial rotator of the humerus.
  - **Innervation.** Medial pectoral nerve (C8–T1) and lateral pectoral nerve (C5–C7).
- **Pectoralis minor muscle.**
  - **Attachments.** Ribs 3–5 and the coracoid process of the scapula.
  - **Action(s).** Stabilizes the scapula against the thoracic wall.
  - **Innervation.** Medial pectoral nerve (C8–T1).
- **Serratus anterior muscle.**
  - **Attachments.** Ribs 1–8 and the medial margin of the scapula.
  - **Action(s).** Scapular protraction; stabilizer of the scapula against the thoracic wall.
  - **Innervation.** Long thoracic nerve (C5–C7).
- **Subclavius muscle.** Attaches to the clavicle and rib 1 and moves the clavicle inferiorly.

DEEP THORACIC MUSCLES

The deep thoracic muscles are the muscles that act primarily on the rib cage. Most are located between ribs in the IC spaces (Figure 2-2B and C). The eleven IC spaces contain three overlapping layers of muscles and membranes, which are named according to their topography (external, internal, and innermost IC muscles and membranes).

- **External intercostal muscles.**
  - **Topography.** Fill each IC space posteriorly and laterally; extends anteriorly from the costochondral joint to the sternum as the external IC membrane.
  - **Attachments.** Fibers course down and forward from the inferior border of one rib to the upper border of the rib below.
  - **Action.** Elevate the ribs and thus expand thoracic cavity volume resulting in inhalation.
  - **Innervation.** Intercostal nerves.
- **Internal intercostal muscles.**
  - **Topography.** Fill each IC space anteriorly and laterally; extends posteriorly from the angle of the ribs to the vertebrae as the internal IC membrane.
  - **Attachments.** Fibers course up and forward (perpendicular to the external IC muscles) from the superior border of one rib to the inferior border of the rib above.
  - **Action.** Depress the ribs and thus reduce thoracic cavity volume resulting in exhalation.
  - **Innervation.** Intercostal nerves.
- **Innermost intercostal muscles.**
  - **Topography.** The innermost intercostal muscles fill each IC space laterally (two additional muscles are located in this layer; transversus thoracis muscle is located anteriorly; subcostal muscle is located posteriorly).
  - **Action.** Function of these muscles is expiration because these muscles depress the ribs caudally.
  - **Innervation.** Intercostal nerves.

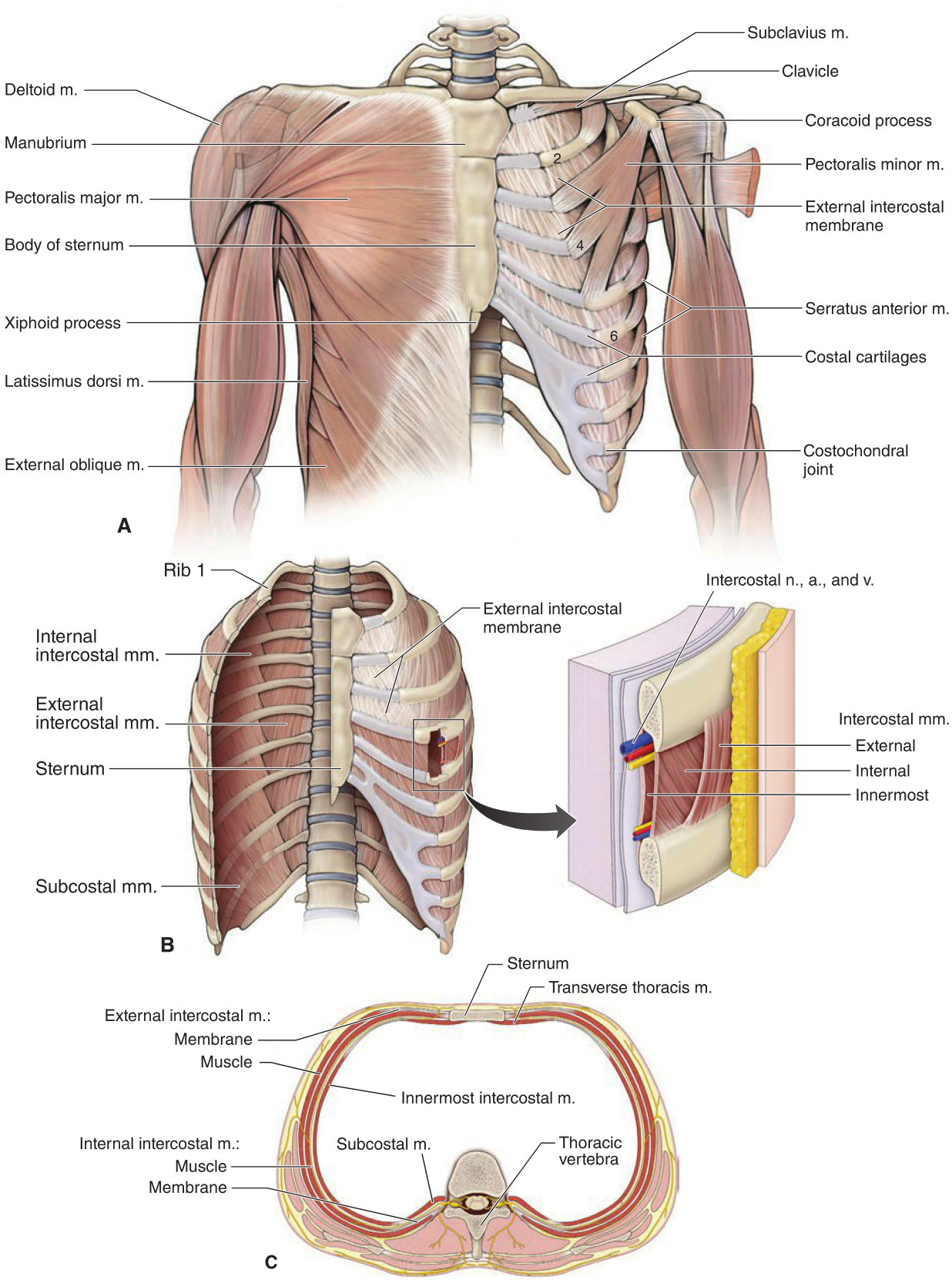

Figure 2-2: **A**. Muscles of the anterior thoracic wall. **B**. Intercostal muscles with step dissection. **C**. Cross-section of intercostal muscles and nerves.

THORACIC SKELETON

BIG PICTURE

The thoracic skeleton consists of the thoracic vertebrae posteriorly, the ribs laterally, and the sternum and costal cartilages anteriorly. The thoracic cage protects vital organs (i.e., heart and lungs) and provides attachment for thoracic, shoulder girdle (scapula and clavicle), and upper limb muscles.

THORACIC VERTEBRAE

The 12 thoracic vertebrae articulate with the 12 pairs of ribs at the following joints (Figure 2-3A):

- **Costovertebral joints.** Articulation of the head of a rib with the inferior costal facet on one thoracic vertebra and the superior costal facet on the adjacent vertebra.
- **Costotransverse joint.** Articulation of the tubercle of a rib with the costal facet on the transverse process of a thoracic vertebra.

RIBS

The 12 pairs of ribs form the flared sides of the thoracic cage and extend anteriorly from the thoracic vertebrae to the sternum (Figure 2-3B). The term "costal" means rib. Primary parts of the ribs are as follows (Figure 2-3C):

- **Head and neck.** Form costovertebral joints by articulating with the costal demifacets of adjacent thoracic vertebral bodies and intervertebral discs.
- **Tubercle.** Articulates with the costal facets of adjacent thoracic vertebral transverse processes.
- **Shaft.** The long shaft of a rib; has an inferior **costal groove**, which houses the intercostal veins, arteries, and nerves. The distal end of a rib shaft articulates with the costal cartilage, forming a **costochondral joint**.

Ribs are classified in the following way:

- **True ribs.** Rib pairs 1–7 attach directly to the sternum by individual **costal cartilages**.
- **False ribs.** Rib pairs 8–10 attach indirectly to the sternum via costal cartilages that curve upward to reach the lowest costal cartilage.
- **Floating ribs.** Rib pairs 11–12 do not attach to the sternum but instead are embedded in the musculature of the body wall.

Course of ribs. The ribs course in an oblique, inferior direction (like the arms of a tall person hugging a short person). Therefore, an axial section through the thorax, like that in an axial CT scan, shows the intersection of several ribs. For example, rib 2 articulates with the T2 vertebra posteriorly but with the sternal angle at the T4 vertebral level anteriorly.

Rib fracture. Fractures commonly occur just anterior to the angle, the weakest point of the rib, and may puncture the parietal pleura and/or lung, resulting in a **pneumothorax**.

STERNUM

The sternum (breastbone) consists of the manubrium, sternal angle, body, and xiphoid process (Figure 2-3D):

- **Manubrium.** A broad plate that has a notch (**jugular notch**) on its superior border.
  - **Sternoclavicular joints.** The clavicles articulate on the superior sides of manubrium, providing the only bony attachment between the upper limb to the axial skeleton.
- **Sternal angle** (of Louis). The junction between the manubrium and the sternal body; forms a palpable transverse ridge (165° angle); the **transverse thoracic plane** (axial plane from the sternal angle through the T4–T5 vertebral level) is an important clinical landmark for the following (Table 2-1) structures:
  - **Rib 2.** Articulates at the sternal angle.
  - **Aortic arch.** Beginning and end of the aortic arch.
  - **Tracheal bifurcation.** Bifurcates into the right and left primary bronchi.
  - **Pulmonary trunk.** Branches into left and right pulmonary arteries.
  - **Ligamentum arteriosum.** Connects the pulmonary trunk to the aortic arch.
  - **Azygos vein.** Courses over the right primary bronchus to join the superior vena cava.
  - **Nerves.** Branch-point of the left recurrent laryngeal nerve from the left vagus nerve; level of the cardiopulmonary plexus of nerves.
  - **Thoracic duct.** Transitions from the right to the left side of the thoracic cavity.
- **Sternal body.** Articulates with the second to seventh costal cartilages.
- **Xiphoid process.** Forms the pointed inferior projection of the sternum.

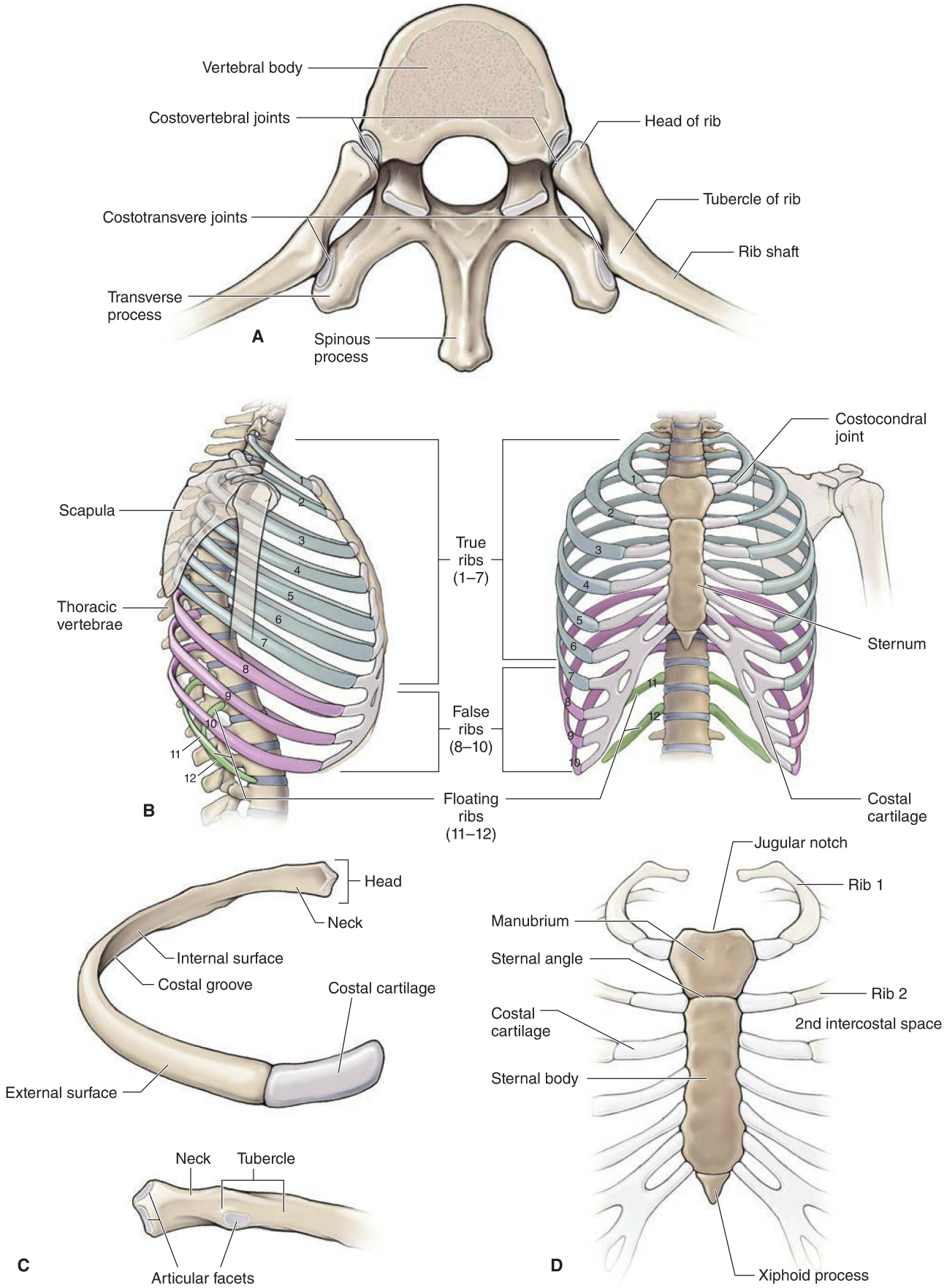

Figure 2-3: **A**. Superior view of a thoracic vertebra articulating with ribs. **B**. Lateral and anterior views of the rib cage. **C**. Anterior and posterior views of a typical rib. **D**. Anterior view of the sternum.

NERVES OF THE THORACIC WALL

BIG PICTURE

The thoracic wall is innervated by intercostal nerves, which course between the internal and innermost intercostal muscles within intercostal spaces. Intercostal nerves provide motor innervation to intercostal muscles and sensory innervation to thoracic dermatomes.

INTERCOSTAL NERVES

The following describes the typical intercostal nerves (Figure 2-4A and B):

- **Origin.** Continues as an extension of a thoracic ventral ramus (i.e., once the T4 ventral ramus enters the intercostal space it becomes the fourth intercostal nerve).
- **Course.** Travels in the upper region of the IC space between the internal and innermost intercostal muscles; courses along with the IC veins and arteries in a neurovascular bundle (IC **v**ein, **a**rtery, **n**erve = **van**).
  - Differs from cervical, lumbar, and sacral ventral rami in that each nerve has a separate course, without forming a plexus (i.e., T4 intercostal nerve courses along the level of the nipple and the T10 intercostal nerve courses at the level of the umbilicus).
  - The T12 ventral ramus forms the **subcostal nerve** (it is below a rib but not in between ribs).
- **Motor.** Provides motor innervation to the intercostal muscles in the thorax and abdominal body muscles in the abdomen.
- **Sensory.** Provides sensory innervation to the anterior and lateral sides of the thoracic wall via the **anterior and lateral cutaneous branches** (Figure 2-4C); additional sensory branches innervate the underlying parietal pleura and parietal peritoneum.
  - Recall that posterior cutaneous branches supply the true (deep) back muscles that are located in the posterior region of the thoracic wall; arise from dorsal rami.

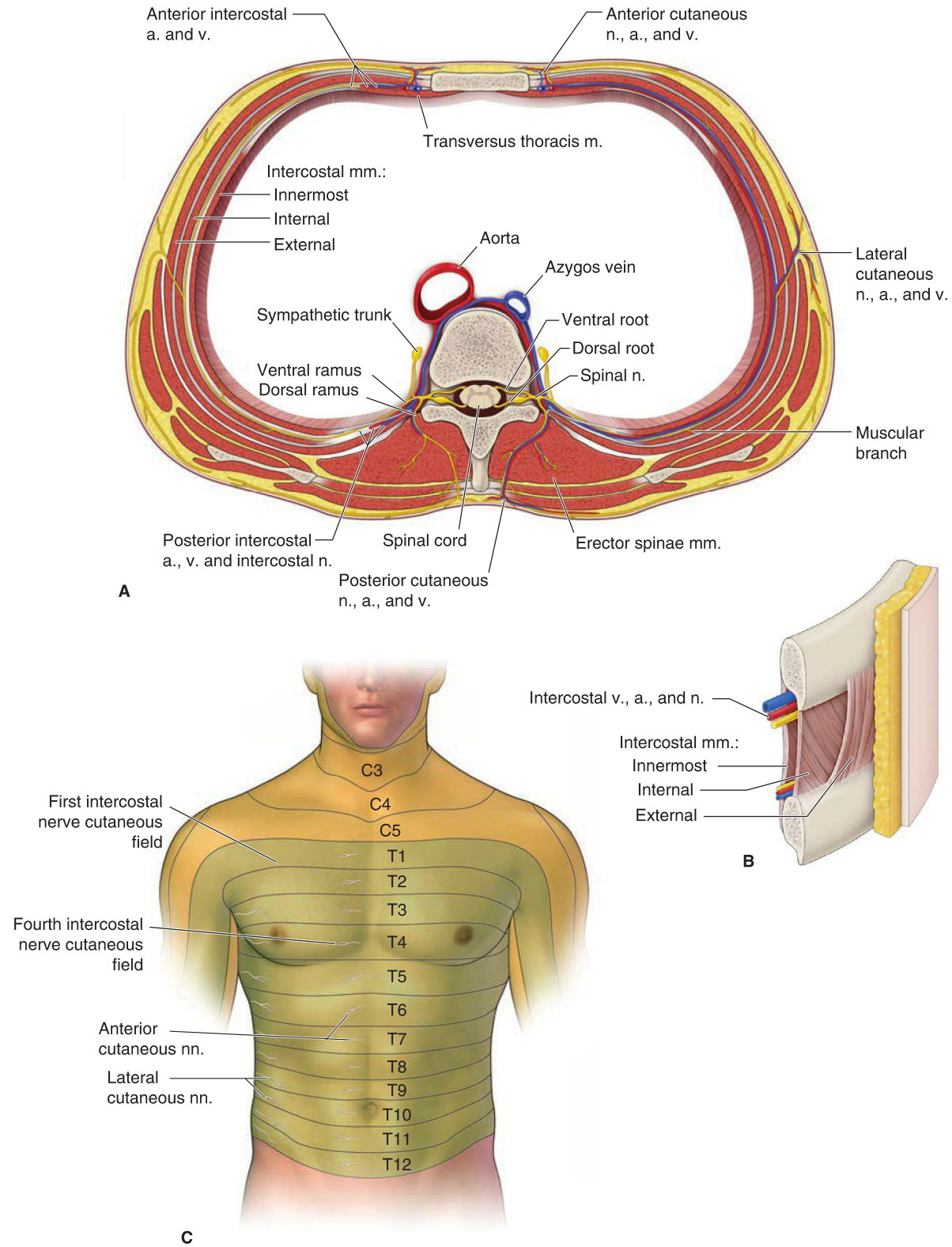

Figure 2-4: **A**. Neurovascular supply of the thoracic wall (cross-section superior view). **B**. Intercostal structures. **C.** Cutaneous nerves of the thoracic wall.

VASCULATURE OF THE THORACIC WALL

BIG PICTURE

The intercostal veins and arteries course along the intercostal spaces between the internal and innermost intercostal muscles in the costal grooves to supply the thoracic body wall. The azygos vein primarily drains posterior IC veins on the right side, whereas the hemiazygos and accessory hemiazygos veins primarily drain posterior IC veins on the left side. The internal thoracic artery supplies the anterior intercostal arteries, whereas the descending aorta supplies the posterior intercostal arteries. The anterior and posterior IC vessels form anastomotic connections.

VENOUS DRAINAGE OF THE THORACIC WALL

Venous drainage of the thoracic wall is from the following veins (Figure 2-5A and B):

- **Internal thoracic veins.** Course vertically, bilaterally, along the internal surface of the rib cage just lateral to the sternum; receive venous blood from the anterior intercostal, musculophrenic, and superior epigastric veins; drains into the brachiocephalic vein on the same side.
- **Anterior intercostal veins.** Drain anterior IC spaces and anterior thoracic wall; their venous blood flows into the musculophrenic and internal thoracic veins.
- **Azygos vein.** Located anterior to the vertebral column and usually right of the midline; the azygos vein receives venous blood from all posterior IC spaces (either directly or indirectly) and empties into the superior vena cava.
  - **Posterior intercostal veins (right side).** Drain the posterior region of IC spaces and posterolateral thoracic wall on the right side; empty into the azygos vein.
  - **Posterior intercostal veins (left side).** Drain the posterior region of IC spaces and posterolateral thoracic wall on the left side; empty into the accessory hemiazygos or hemiazygos veins, which ultimately terminate in the azygos vein.
- **Hemiazygos vein.** Located anterior to the vertebral column and usually left of the midline; receives tributaries from the lower left intercostal, esophageal, and accessory hemiazygos veins.
- **Accessory hemiazygos vein.** Located anterior to the vertebral column and usually left of the midline; receives tributaries from the fourth to eight posterior intercostal veins on the left side.
- The first to third posterior intercostal veins drain directly in the left brachiocephalic vein.

ARTERIAL SUPPLY TO THE THORACIC WALL

The thoracic wall receives its arterial supply from the following arteries (Figure 2-5A and C):

- **Internal thoracic arteries.** Arise from the subclavian artery on each side and descend along the internal surface of the ribcage just lateral to the sternum.
  - Give rise to **anterior intercostal arteries** in the upper IC spaces and terminates at the sixth IC space by bifurcating into the **superior epigastric artery** and **musculophrenic artery**.
- **Anterior intercostal arteries.** Arise from internal thoracic and musculophrenic arteries; supply blood to the anterior region of IC spaces and skin of thoracic wall via **anterior cutaneous branches**.
- **Superior epigastric artery.** The medial terminal branch of the internal thoracic artery; descends on the deep surface of the rectus abdominis muscle and anastomoses with the inferior epigastric artery.
- **Musculophrenic artery.** The lateral terminal branch of the internal thoracic artery; follows the internal surface of the costal arch and gives rise to the seventh through ninth anterior intercostal arteries.
- **Posterior intercostal arteries.** Supply blood to the posterolateral regions of the IC spaces.
  - The first and second posterior intercostal arteries arise from the superior (supreme) intercostal arteries, which arise from the costocervical trunk of the subclavian artery.
  - The rest of the posterior intercostal arteries arise segmentally from the descending aorta and give rise to lateral cutaneous branches.
  - Posterior intercostal arteries form anastomotic connections with anterior intercostal arteries.
  - The **subcostal artery** travels below the 12th rib.

▼ When the **aortic arch is constricted (coarctated)** just beyond the origin of the left subclavian artery, the anastomoses between the anterior and posterior intercostal arteries enable blood in the internal thoracic arteries to reach the descending aorta, bypassing the coarctation. ▼

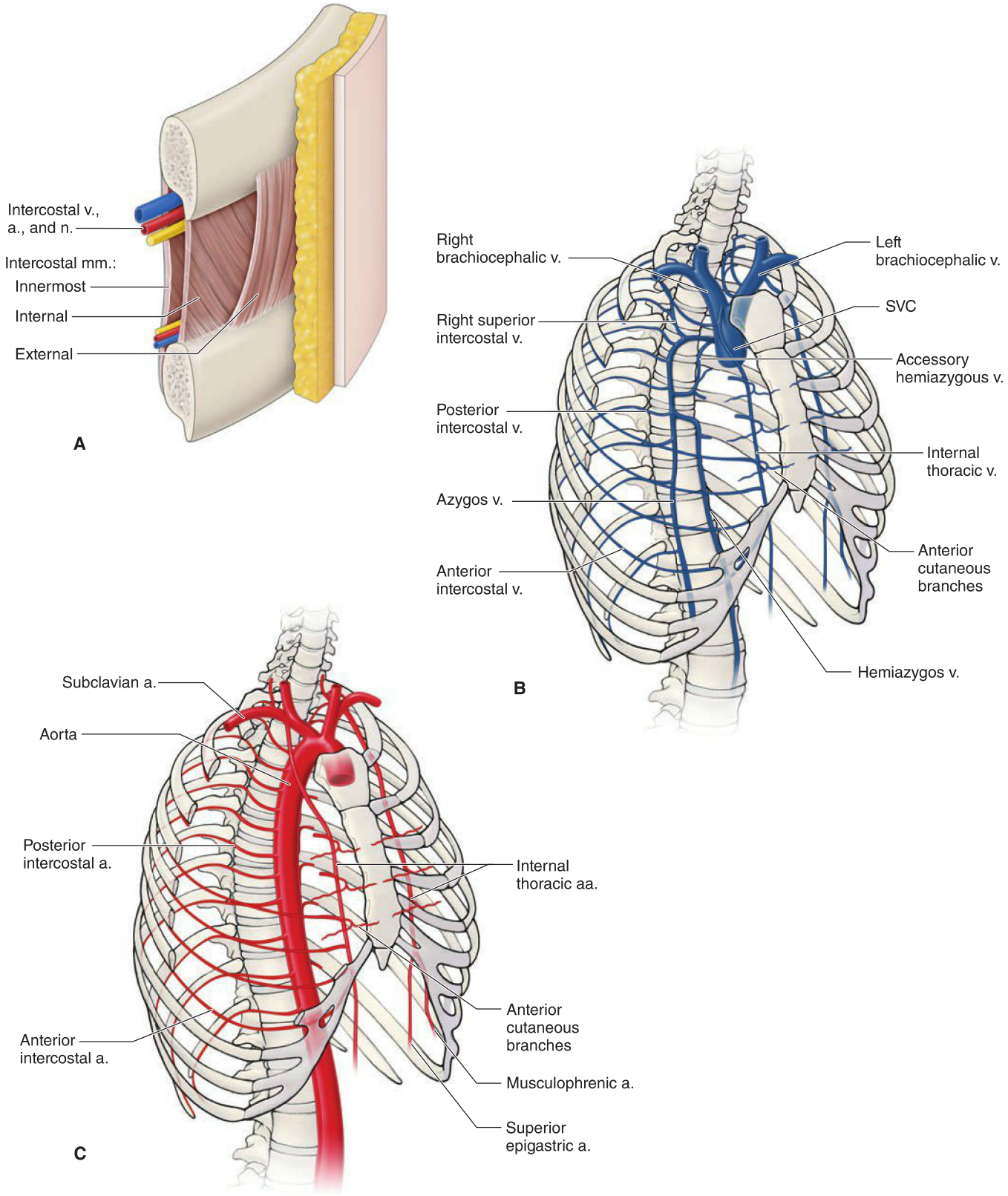

Figure 2-5: **A**. Intercostal structures. **B.** Veins of the thoracic wall (anterolateral view). **C.** Arteries of the thoracic wall (anterolateral view).

DIAPHRAGM

BIG PICTURE

The diaphragm muscle separates the thoracic and abdominal cavities, attaches to the internal surface of lumbar vertebrae and ribcage, is innervated by the phrenic nerve, and is the primary muscle of respiration.

STRUCTURE

The topography and attachments of the diaphragm are as follows (Figure 2-6A and B):

- **Topography.** The diaphragm is a dome-shaped muscle that separates the thoracic cavity from the abdominal cavity. The right dome lies on top of the liver, whereas the left dome lies on top of the fundus of the stomach. As such, the right diaphragmatic dome is usually higher than the left.
- **Attachments.** The diaphragm has peripheral muscle attachments and a central tendon.
  - **Origin.** Xiphoid process, lower six ribs, T12–L2 vertebral bodies (right and left crura are muscular extensions that attach to the L1–L2 vertebral bodies).
  - **Insertion.** Central tendon of the diaphragm; the structure that the diaphragm's muscle fibers pull upon when concentrically contracting.

INNERVATION

The diaphragm is primarily innervated by the **phrenic nerves**, which arise from the C3–C5 spinal nerve levels ("C3, C4, and C5 keep the diaphragm alive") (Figure 2-6A):

- **Motor.** Stimulate the diaphragm to contract.
- **Sensory.** From the parietal pericardium, parietal pleurae (mediastinal and diaphragmatic), and the diaphragmatic parietal peritoneum; the peripheral part of the diaphragm receives sensory innervation from the associated intercostal nerves.
- **Course.** Arise from C3–C5 ventral rami bilaterally, descend along the anterior surface of the anterior scalene muscle, between the subclavian vein and artery, and accompanied by the pericardiacophrenic vessels; the phrenic nerve descends anterior to the root of the lung to the diaphragm.

APERTURES IN THE DIAPHRAGM

The diaphragm has the following openings for passage of structures between the thorax and the abdomen (Figure 2-6A and B):

- **Vena caval hiatus (foramen).** Located at the T8 vertebral level and transmits the IVC and right phrenic nerve.
- **Esophageal hiatus.** Located at the T10 vertebral level and transmits the esophagus, vagus nerves, and left gastric vessels.
- **Aortic hiatus.** Located at the T12 vertebral level and transmits the aorta, thoracic duct, azygos and hemiazygos veins, sympathetic trunk, and lymph nodes.

FUNCTIONS OF THE DIAPHRAGM

- **Respiration.** The diaphragm is the principal muscle of inspiration (Figure 2-6C).
  - **Contraction.** When the diaphragm contracts, it descends and thereby increases thoracic volume, which decreases intrathoracic pressure, creating a vacuum (negative pleural pressure) that pulls air into the lungs. Therefore, contraction of the diaphragm results in inhalation.
  - **Relaxation.** When the diaphragm relaxes, it ascends and decreases thoracic volume, which increases intrathoracic pressure, forcing air out of the lungs. Therefore, relaxation of the diaphragm results in exhalation.
    - The roles of the diaphragm and other thoracic muscles of respiration are discussed in more detail in Chapter 3.
- **Venous return.** The alternating contraction and relaxation of the diaphragm causes pressure changes in the thoracic and abdominopelvic cavity that facilitate the return of venous blood to the heart.

Valsalva maneuver. An action that forcibly exhales, with the glottis, nostrils, and mouth closed. When this occurs, the diaphragm contracts, thereby increasing intra-abdominal pressure. The increased intra-abdominal pressure equalizes pressure in the middle ear, and expels vomit, feces, and urine from the body.

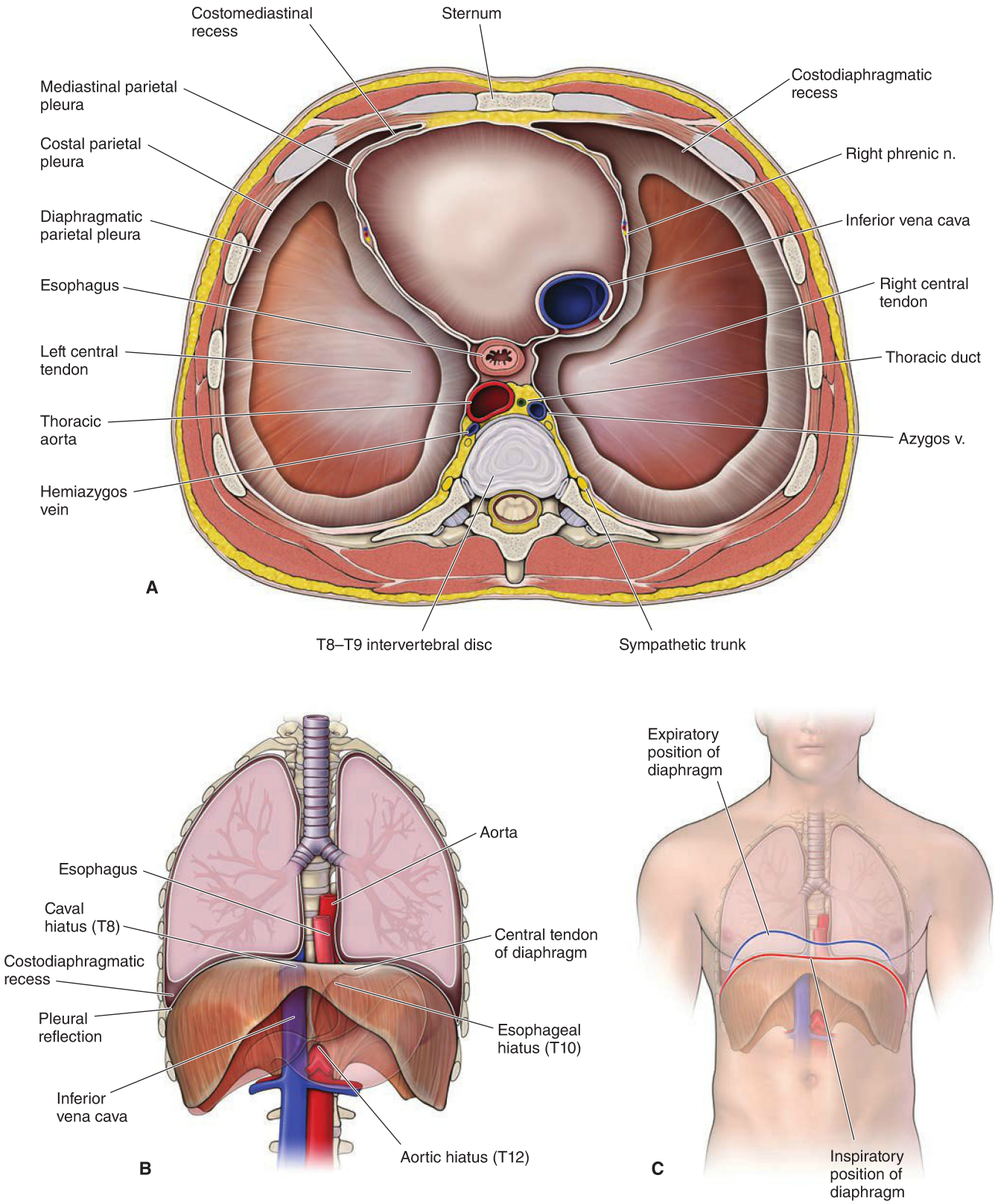

Figure 2-6: **A**. Cross-section of the thorax above the diaphragm (superior view). **B**. Anterior view of the diaphragm and its relationship to the lungs. **C**. Position of the diaphragm during inspiration and expiration.

TABLE 2-1. Important Vertebral Landmarks of the Thorax

Vertebral Level	Landmark
T2	Jugular notch
T3	Base of spine of scapula; junction of brachiocephalic veins to form superior vena cava (SVC)
T4	Sternal angle (second rib, azygos vein arches over right primary bronchus into the SVC, tracheal bifurcation, pulmonary trunk branches into pulmonary arteries, level of the ligamentum arteriosum, beginning and end of aortic arch, thoracic lymphatic duct crosses from right to left side of thoracic cavity)
T7	Inferior angle of the scapula
T8	Vena caval hiatus of the diaphragm
T9	Xiphoid process
T10	Esophageal hiatus of the diaphragm
T12	Aortic hiatus of the diaphragm

TABLE 2-2. Muscles of the Thoracic Region

Muscle	Proximal Attachment	Distal Attachment	Action	Innervation
Pectoralis major	Clavicle, sternum, and ribs	Intertubercular groove of humerus	Flexion, adduction, medial rotation of humerus	Medial (C8–T1) and lateral (C5–C7) pectoral nn.
Pectoralis minor	Ribs 3–5	Coracoid process of scapula	Protraction and stabilization of scapula	Medial pectoral n. (C8–T1)
Serratus anterior	Lateral border of ribs 1–8	Medial margin of scapula	Protraction and stabilization of scapula	Long thoracic n. (C5–C7)
Subclavius	Rib 1	Clavicle	Stabilize clavicle	Nerve to subclavius (C5–C6)
Intercostals				
• **External** • **Internal** • **Innermost**	Inferior border of ribs	Superior border of inferior rib	Elevate ribs Depress ribs Depress ribs	Segmental innervation by intercostal nn.
Transversus thoracis	Posterior surface of sternum	Deep surface of costal cartilages 2–6	Depress ribs	Segmental innervation by intercostal nn.
Subcostalis	Deep surface of lower ribs	Superior borders of ribs 2 and 3	Depress ribs	

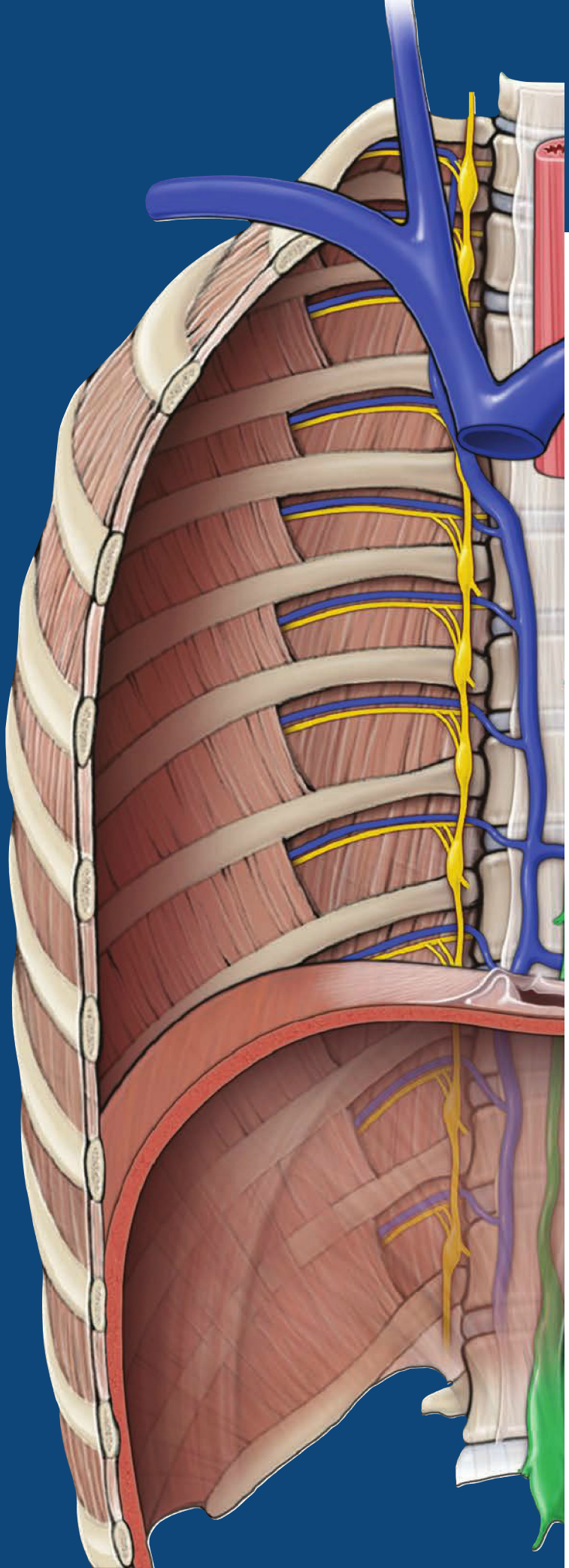

CHAPTER 3

LUNGS

Pleura 42
Anatomy of the Lung 44
Hilum of the Lung 46
Ventilation 48

PLEURA

BIG PICTURE

The lungs (functional organs of the respiratory system) are located within serous membranes that line the inside of the rib cage (parietal pleura) and outside of the lungs (visceral pleura).

The pleurae secrete fluid that decreases resistance against lung movement during breathing.

DESCRIPTION OF PLEURAL SACS

Each lung (right and left) is contained within a serous membrane called a **pleural sac.** The pleural sacs flank both sides of the heart and occupy most of the thoracic cavity. Each pleural sac is composed of **two serous layers**: the parietal pleura and visceral pleura (Figure 3-1A and B).

PARIETAL PLEURA

Parietal pleura lines the internal surface of the thoracic cavity. The endothoracic fascia is a thin layer of connective tissue that adheres the parietal pleura to the internal thoracic wall (Figure 3-1B–D).

- **Regions.** The parietal pleura is assigned specific names, depending on the area it lines:
  - **Mediastinal parietal pleura.** Lines the lateral surface of the mediastinum (location of the pericardium and heart).
  - **Costal parietal pleura.** Lines the internal surface of the ribs.
  - **Diaphragmatic parietal pleura.** Lines the superior surface of the diaphragm.
  - **Cervical parietal pleura (cupula).** Extends above rib 1 to the root of the neck.
- **Innervation.** The parietal pleura on each side is associated with the body wall (i.e., skin and IC muscles) and thus innervated by general sensory neurons (therefore sensitive to pain). The nerves that provide sensory innervation are (Figure 3-1B):
  - **Intercostal nerves.** Innervate the parietal pleura lining the peripheral portion of the diaphragm and the ribs.
  - **Phrenic nerves.** Innervate the parietal pleura lining the central portion of diaphragm and the mediastinum.

VISCERAL PLEURA

The visceral pleura surrounds and is intimately attached to each lung and follows the contour of the lobes; the visceral pleura is contiguous with the parietal pleura at the hilum of each lung (Figure 3-1B–D).

- **Function. The visceral pleura along with the parietal pleura** produce and reabsorb pleural fluid; the bulk of pleural fluid is cleared by lymphatics in the parietal pleura.
- **Innervation.** The visceral pleura is associated with the organ (lung) and thus innervated by visceral sensory neurons (therefore insensitive to pain) from the autonomic vagus nerve (CN X).

PLEURAL SPACE

The pleural space is located between the parietal and visceral pleurae. Because the pericardium and heart occupy the mediastinum, the right and left pleural spaces do not communicate.

- **Pleural fluid.** The pleural space contains a thin film of pleural fluid that lubricates and facilitates gliding movement of the lungs within the thoracic wall during breathing.
  - The surface tension of pleural fluid ensures the parietal and visceral pleura adhere to each other.
- **Pleural pressure.** Normally, the pressure within the pleural space is slightly less than atmospheric pressure because of the opposing elastic forces of the chest wall and lung (outward pull of the thoracic cavity and the inward pull of the lung). As such, the pleural pressure is called "negative pressure."
  - Pleural fluid couples the visceral to the parietal pleura and thus keeps the lungs inflated. Coupling of the visceral and parietal pleurae by pleural fluid resists collapse of the lungs, even at the end of a deep exhalation.
  - Therefore, both pleural fluid, and surfactant in alveoli, work together to reduce friction as the lungs glide across the parietal pleura and keep to reduce surface tension at the air–liquid interface that lines alveoli, respectively.

Pneumothorax. If air enters the pleural space as a result of chest trauma (e.g., a knife wound), the coupling between the parietal pleura and visceral pleura may be broken. This introduction of air would most likely cause equalization between pleural pressure and atmospheric pressure, resulting in a collapsed lung. This pathology is called a pneumothorax, or air in the thoracic cavity. When blood fills the pleural space, the pathology is called a **hemothorax**.

SIGNIFICANCE OF THE PLEURAL REFLECTIONS AND RECESSES

In quiet respiration, the lung, with its covering of visceral pleura, does not fill the entire pleural sac. The locations where the lung does not completely fill the pleural sac are called pleural recesses. There are **two clinically important recesses** (Figure 3-1C and D):

- **Costodiaphragmatic recess.** The recess where the costal parietal pleura meets the diaphragmatic parietal pleura in the inferior limit of the pleural sac.
- **Costomediastinal recess.** The recess where the costal parietal pleura meets the mediastinal parietal pleura anteriorly, near the midline.

The pleural recesses are sites where pleural fluid accumulates during quiet breathing. When a deep breath is taken, the greatly expanded lungs push into the recesses, allowing lung volume to increase and, consequently, the pleural fluid becomes displaced around each lung.

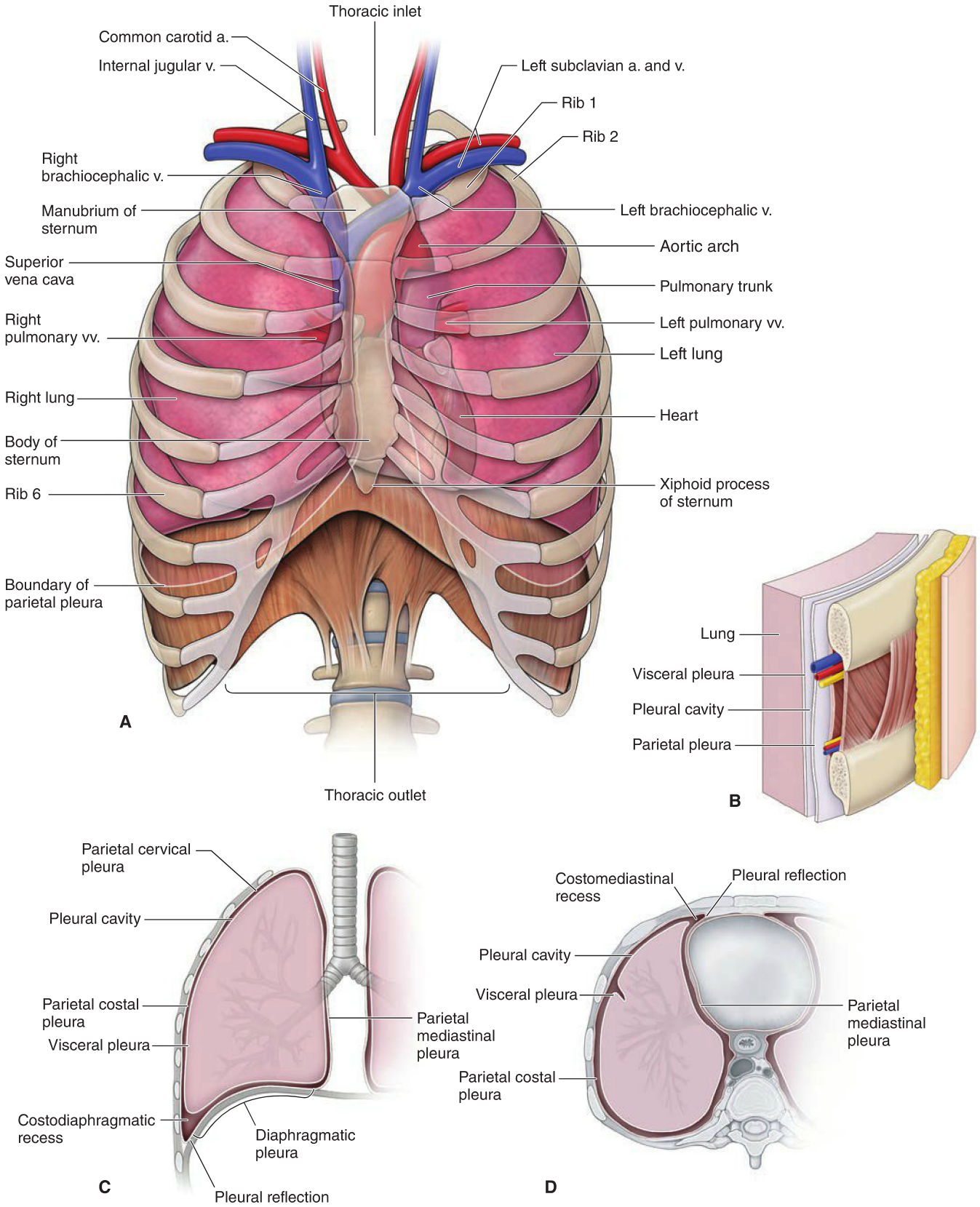

Figure 3-1: A. Pleura sacs in situ. **B**. Step dissection of lateral thoracic wall from skin to the lungs. Pleura in coronal (**C**) and axial (**D**) sections.

ANATOMY OF THE LUNG

BIG PICTURE

The lungs are the organs of respiratory gas exchange. To serve that function efficiently, the lungs are structurally designed to bring air into close proximity of blood. The lungs have two blood supplies: pulmonary and bronchial. The pulmonary circulation supplies the respiratory tissues (parenchyma) with deoxygenated blood. The bronchial (systemic) vessels nourish the non-respiratory tissues (e.g., bronchi, bronchioles, pulmonary arteries and veins, lymphoid tissue, and connective tissue of the lung) with oxygenated blood.

LOBES OF THE LUNG

Each lung is divided into lobes, with its own covering of visceral pleura.

- **Right lung.** The right lung has **three lobes (superior, middle, and inferior)**, which are divided by a **horizontal** and an **oblique fissure**, respectively (Figure 3-2A).
  - The right lung is shorter and wider than the left because of the higher right dome of the diaphragm and because the heart bulges more into the left side of the thorax.
- **Left lung.** The left lung has only **two lobes (superior and inferior)**, which are divided by an **oblique fissure** along the sixth rib (Figure 3-2C).
  - Instead of having a middle lobe, the left lung has a space occupied by the heart. Therefore, the left lung has a **cardiac notch** as well as the **lingula**, an extension of the left superior lobe into the left costomediastinal recess.

AIRWAYS

The conducting airways of the respiratory system are the trachea, primary bronchi, secondary bronchi, and tertiary bronchi (Figure 3-2B).

- **Trachea** (windpipe). Begins at the cricoid cartilage and descends into the thorax, where it bifurcates into right and left primary bronchi at the T4–T5 vertebral level.
  - **Tracheal wall.** Consists of C-shaped rings of hyaline cartilage closed posteriorly by the trachealis muscle.
  - **Carina.** The internal ridge of the tracheal bifurcation into primary bronchi.
- **Right primary (main) bronchus.** Divides into **superior, middle, and inferior secondary (lobar) bronchi**, corresponding to the superior, middle, and inferior lobes of the right lung, respectively.
  - The right primary bronchus is shorter (~3 cm), wider, and more vertical than the left primary bronchus; the azygos vein arches over the right primary bronchus prior to entering the SVC.
- **Left primary (main) bronchus.** Divides into **superior and inferior secondary (lobar) bronchi**, corresponding to superior and inferior lobes of the left lung, respectively.
  - The left primary bronchus is longer (~6 cm), narrower, and more horizontal than the right primary bronchus; the left pulmonary artery arches over the left primary bronchus.
- **Tertiary (segmental) bronchi.** Each secondary bronchus further divides into **tertiary bronchi**, which continue to divide. The smallest bronchi give rise to bronchioles, which terminate in alveolar sacs where the exchange of gases occurs.

REGIONS OF THE LUNG

Each lung has the following regions corresponding to its respective regions of the chest:

- **Mediastinal lung surface.** The medial concave surface containing the **root (hilum)** of the lungs related to the pericardium and heart. This surface contains a mainstem bronchus and a pulmonary artery and pulmonary veins, nerves, lymphatics, and lymph nodes.
- **Diaphragmatic lung surface.** The base of the lungs is curved because it rests on the domed diaphragm.
- **Apex of the lung.** This area projects into the root of the neck and is crossed anteriorly by the subclavian artery and vein.

BRONCHOPULMONARY SEGMENTS

A bronchopulmonary segment is a region of lung supplied by a tertiary (segmental) bronchus. Additionally, each segment has a corresponding branch of the pulmonary artery and vein.

▼ **Surgical removal of lung segments.** Bronchopulmonary segments are clinically important because they serve as anatomic, functional, and "surgical" units of the lungs. A surgeon may remove a bronchopulmonary segment of the lung without disrupting the surrounding lung parenchyma. ▼

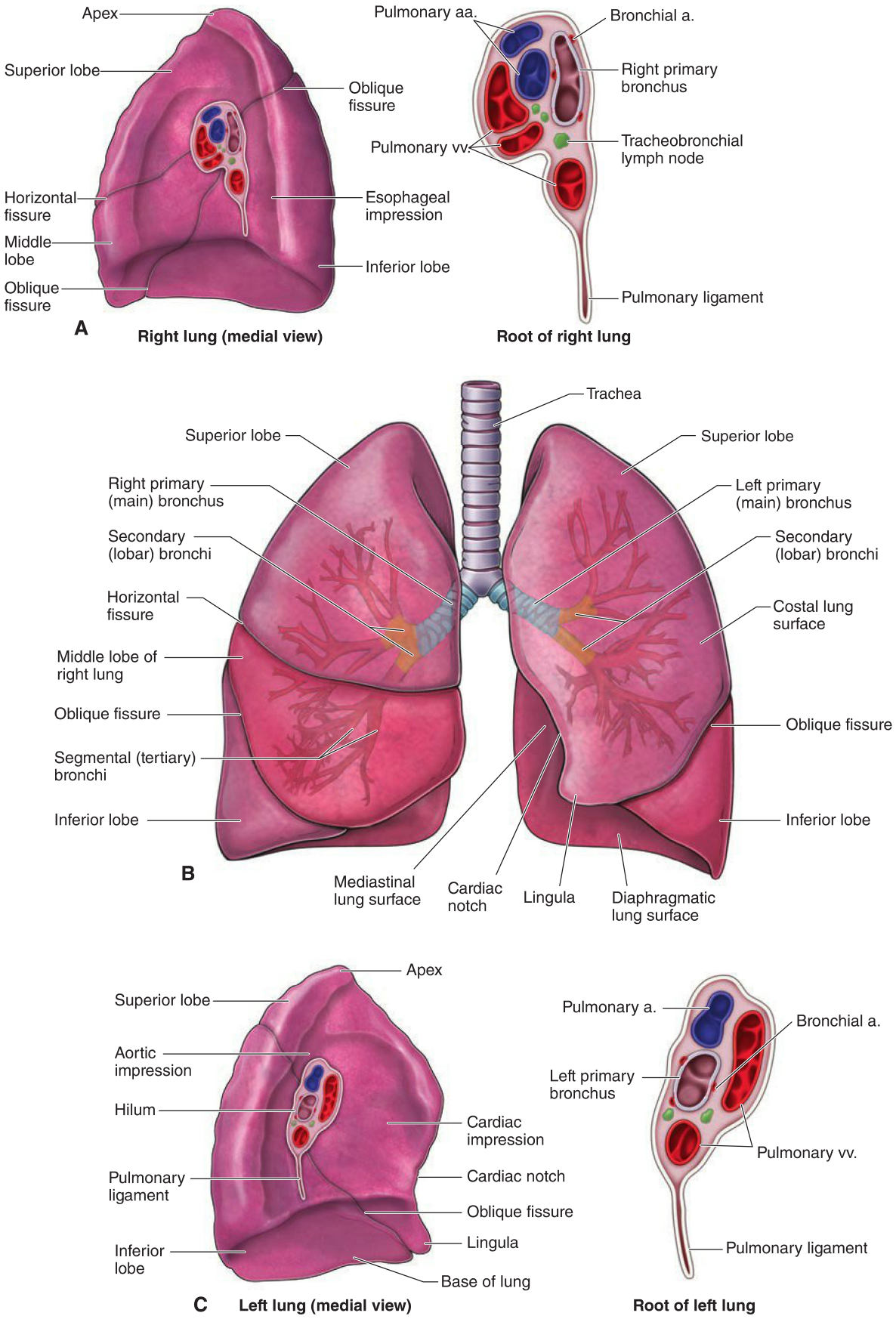

Figure 3-2: **A**. Right lung in medial view. **B**. Bronchial tree and lungs. **C**. Left lung in medial view.

HILUM OF THE LUNG

BIG PICTURE

For gas exchange to occur, the lung must be connected to the heart so that oxygenated blood and deoxygenated blood flow between both organs. The location where blood vessels and other structures enter and leave the lungs is called the hilum of the lung. Parasympathetic innervation causes bronchoconstriction and sympathetic innervation causes bronchodilation.

VASCULATURE OF THE LUNG

The pulmonary and bronchial arteries and veins provide dual vascular supply. These two supplies can be confusing. In a nutshell, here is the information you need to know about the vascular supply: *Pulmonary arteries and veins deal with gas exchange and the circulation of blood between the heart and lungs, whereas the bronchial arteries and veins are the vascular supply to the structural elements of the lungs, such as the bronchial tree.*

- **Pulmonary trunk.** The pulmonary trunk is a wide vessel (~3 cm in diameter) that arises from the right ventricle and after a short ~5 cm course bifurcates into the left and right pulmonary arteries (Figure 3-3A).
  - The **ligamentum arteriosum** (fibrous remnant of the fetal **ductus arteriosus**) is located at the bifurcation of the pulmonary trunk into the pulmonary arteries.
- **Pulmonary arteries.** Branch from the pulmonary trunk and deliver deoxygenated blood to the pulmonary capillaries of the lungs.
  - Travel alongside branches of the bronchial tree.
- **Pulmonary veins.** Transport oxygenated blood from the pulmonary capillaries to the left atrium of the heart.
  - Do not accompany the bronchi or the segmental arteries within the lung parenchyma.
  - Two pulmonary veins exit the left lung and three pulmonary veins exit the right lung (one for each lobe), but the right upper and middle veins usually join so that usually only four pulmonary veins enter the left atrium.

Most arteries seen in lung tissue sections are branches from the pulmonary artery. However, smaller bronchial arteries can also be distinguished, especially at the hilum and along the bronchi.

- **Bronchial arteries.** Arise from the aorta to supply the bronchial tree parenchyma (perfusion pressures in bronchial arteries are higher than pulmonary arteries because they branch from the aorta). There are usually only one bronchial artery for the right lung and two for the left lung.
  - Arterial blood from bronchial arteries is returned to the heart through anastomoses with the pulmonary veins; thus there is a slight diminution in the overall degree of oxygenation of pulmonary venous blood. The remainder of the blood taken to the lung by the bronchial arteries drains into bronchial veins, which empty into the azygos system of veins.

LYMPHATICS OF THE LUNG

Similar to the pulmonary veins, the collecting lymphatic vessels of the lung do not travel parallel to the principal airways but rather are located in the interlobular septa that define the lung lobules.

Lymph from lobes of the lungs drains into **pulmonary** and **bronchopulmonary (hilar) nodes** and then into the **tracheobronchial (carinal) nodes** and into the **paratracheal nodes.** Lymph enters the systemic circulation through either the **right lymphatic duct** (for the right lung) or the **thoracic duct** (for the left lung).

INNERVATION OF THE LUNG

The **pulmonary plexus** of nerves follows the trachea and bronchial tree, providing parasympathetic and sympathetic innervation to the smooth muscle and glands of the lungs (Figure 3-3B).

- **Parasympathetic innervation.** Supplied by branches of the **vagus nerve (CN X)**; causes **bronchoconstriction** and bronchial gland secretion.
- **Sympathetic innervation.** Supplied by postganglionic sympathetic fibers from T1–T4 sympathetic ganglia and cervical sympathetic ganglia; causes bronchodilation and inhibition of bronchial gland secretion. Visceral sensory fibers from the visceral pleura and bronchi accompany sympathetic fibers to the T1–T4 spinal cord levels. The primary sympathetic control of the airways is from circulating epinephrine from the adrenal gland.

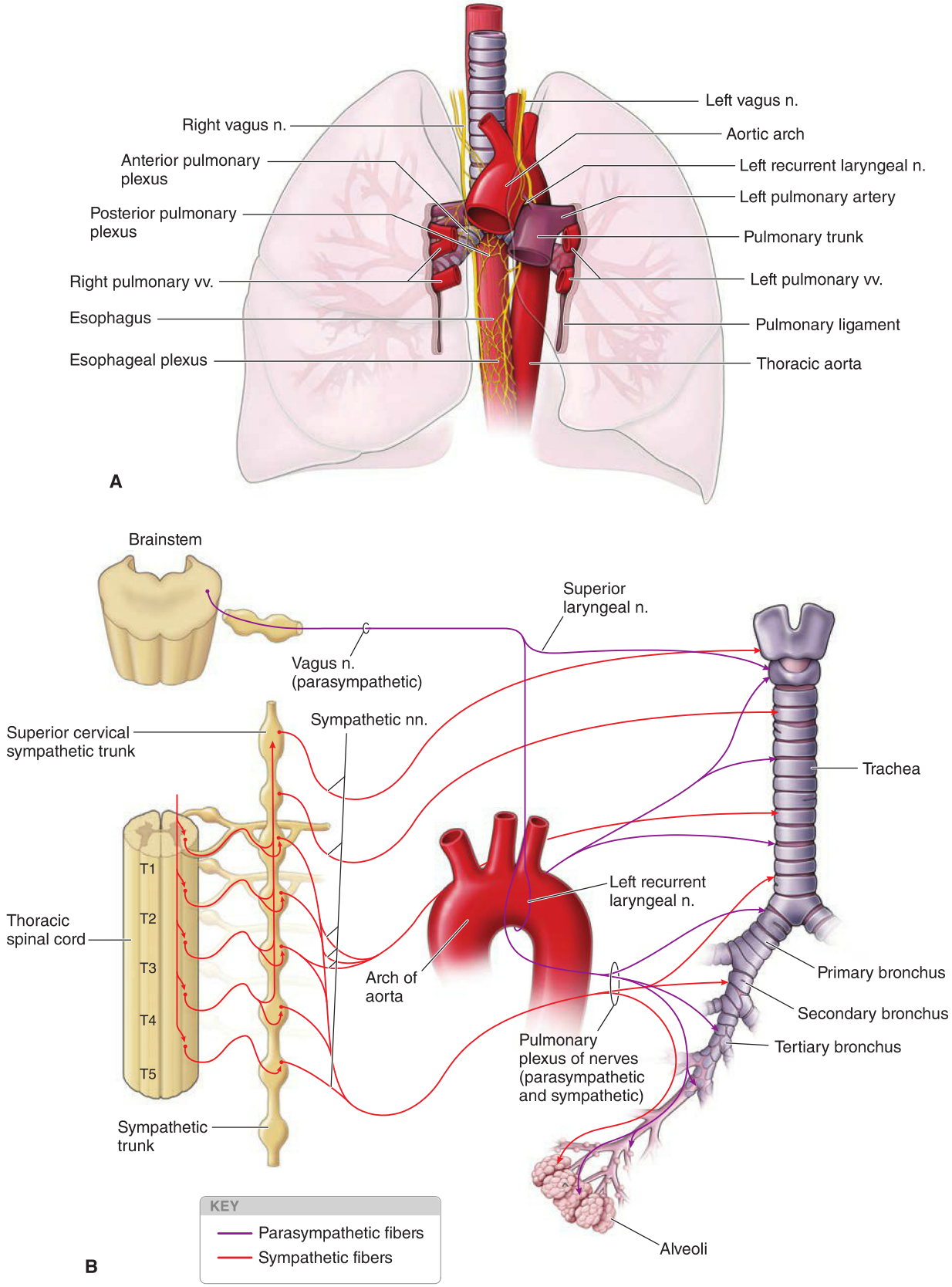

Figure 3-3: **A**. Pulmonary plexus. **B**. Autonomic innervation of the lung.

VENTILATION

BIG PICTURE

Ventilation is the movement of air into and out of the lungs. The coordination of the thoracic skeleton, muscles, and the bronchial tree enables ventilation to occur. Respiratory gas exchange describes the exchange of oxygen and carbon dioxide at the alveoli as blood circulates through the pulmonary capillaries.

VENTILATION OVERVIEW

To understand ventilation, a review of **Boyle's law** is helpful. Boyle's law states the following:

- The volume of an object and the pressure of gas it contains are inversely proportional when temperature remains constant.

In other words:

- When an object's volume increases, the pressure of the contained gas decreases.
- Conversely, when the volume of an object decreases, the pressure of the contained gas increases.

With this background, let us apply these principles to the context of the respiratory system:

- The thoracic cavity is a container lined by the thoracic cage (thoracic vertebrae, ribs, costal cartilage, and sternum) and muscles (diaphragm and intercostal muscles), with a single opening at the top (trachea).
- Muscles acting on the thoracic cage either increase or decrease its volume and thus affect the pressure of gases within.
- The trachea enables air to move into and out of the lungs within the thoracic cavity.

INSPIRATION

When the interaction between the thoracic cage and muscles increases thoracic volume, the pressure within the thoracic cavity decreases. This negative pressure generates a vacuum due to the pressure difference between the atmosphere and inside the thoracic cavity and thus air moves into the lungs. This is called inhalation or inspiration (Figure 3-4A and B). The interaction of thoracic muscles and thoracic cage is outlined below:

- **Diaphragm.** In the relaxed state, the diaphragm is dome-shaped. When the diaphragm contracts, it flattens, increasing the vertical dimensions and thus the volume of the thoracic cavity. The diaphragm is by far the most important structure that brings about the pressure, gas flow, and volume changes that lead to normal inhalation.
- **Intercostal muscles.** Contraction of the external intercostal muscles lifts the rib cage and pulls the sternum anteriorly expanding the diameter of the thoracic cavity. This is similar to the action that occurs when a curved bucket handle is raised away from the bucket (Figure 3-4C).

Although these actions expand the thoracic dimensions by only a few millimeters along each plane, this expansion is sufficient to increase the volume of the thoracic cavity by approximately 0.5 L, the approximate volume of air that enters the lungs during normal inhalation.

During the deep or forced inspirations that occur during vigorous exercise, the volume of the thoracic cavity is further increased by activation of the accessory muscles. Accessory respiratory muscles (i.e., scalenes, sternocleidomastoid, serratus anterior and pectoralis minor) elevate the ribs more than occurs during quiet inspiration.

AIR PRESSURE EQUALIZATION

As the thoracic dimensions increase during inspiration, pleural pressure becomes more negative and "pulls" on the lungs as thoracic volume increases. The consequence is that the lungs expand (fill with gas) and intrapulmonary volume increases. Inspiration ends when thoracic volume ceases to increase, resulting in no further reduction in pleural pressure. Gas flow ceases and thus lung volume does not change.

EXPIRATION

When the interaction between the thoracic cage and muscles decreases thoracic volume, the pressure within the thoracic cavity increases. This pressure increase forces the gases contained within the lung through the trachea to the outside environment. This is called exhalation or expiration. Quiet expiration is largely a passive process that depends more on the natural elasticity of the thoracic wall and lungs than on muscle contraction. In contrast, forced expiration is an active process (Figure 3-4A–C). The interaction of thoracic muscles and thoracic cage are outlined below:

- **Quiet expiration.** As the inspiratory muscles relax, the diaphragm ascends, the rib cage descends, and the stretched elastic tissue of the lungs recoils. Thus, both thoracic and lung volumes decrease. Decreased lung volume compresses the alveoli, resulting in increases above atmospheric pressure, thereby forcing gas flow out of the lungs.
  - For example, when the diaphragm relaxes, it passively moves superiorly. Consequently, the vertical dimension of the thorax is decreased and thus the volume of the thoracic cavity decreases.
- **Forced expiration.** When the expiratory muscles (e.g., the external and internal oblique and transverse and rectus abdominis) contract, they increase intra-abdominal pressure. This forces the abdominal organs superiorly against the diaphragm, raising it. The same muscles depress the rib cage. Both actions forcibly reduce the volume in the thoracic cavity, increasing pleural pressure, forcing air to move from the lungs and out of the trachea.

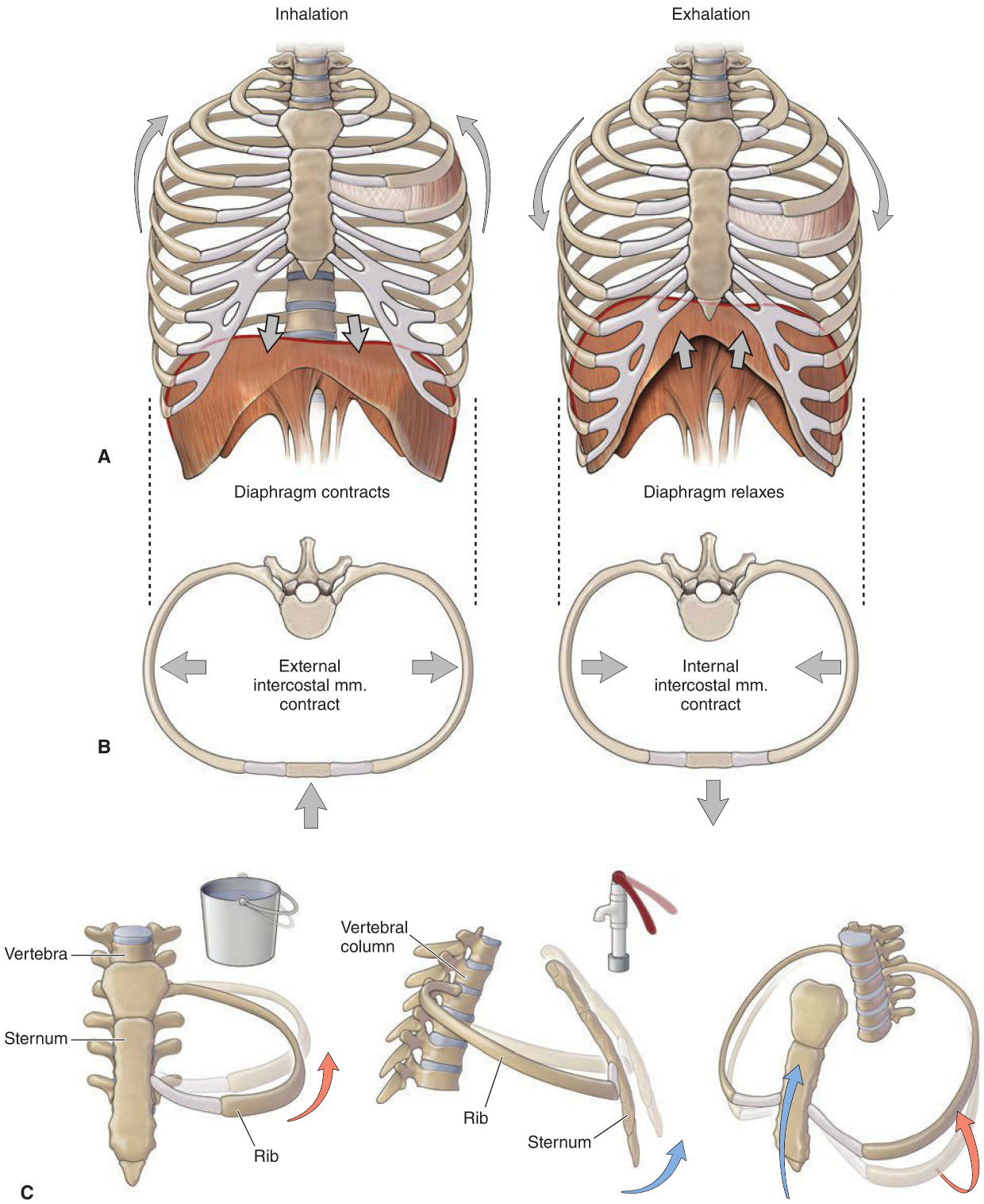

Figure 3-4: Movements of the thoracic wall during inhalation and exhalation in the anterior (**A**) and axial superior (**B**) views. **C**. Thoracic wall movements during respiration. The bucket and water-pump handle are analogies for the movement of the rib cage when acted upon by respiratory muscles.

This page intentionally left blank

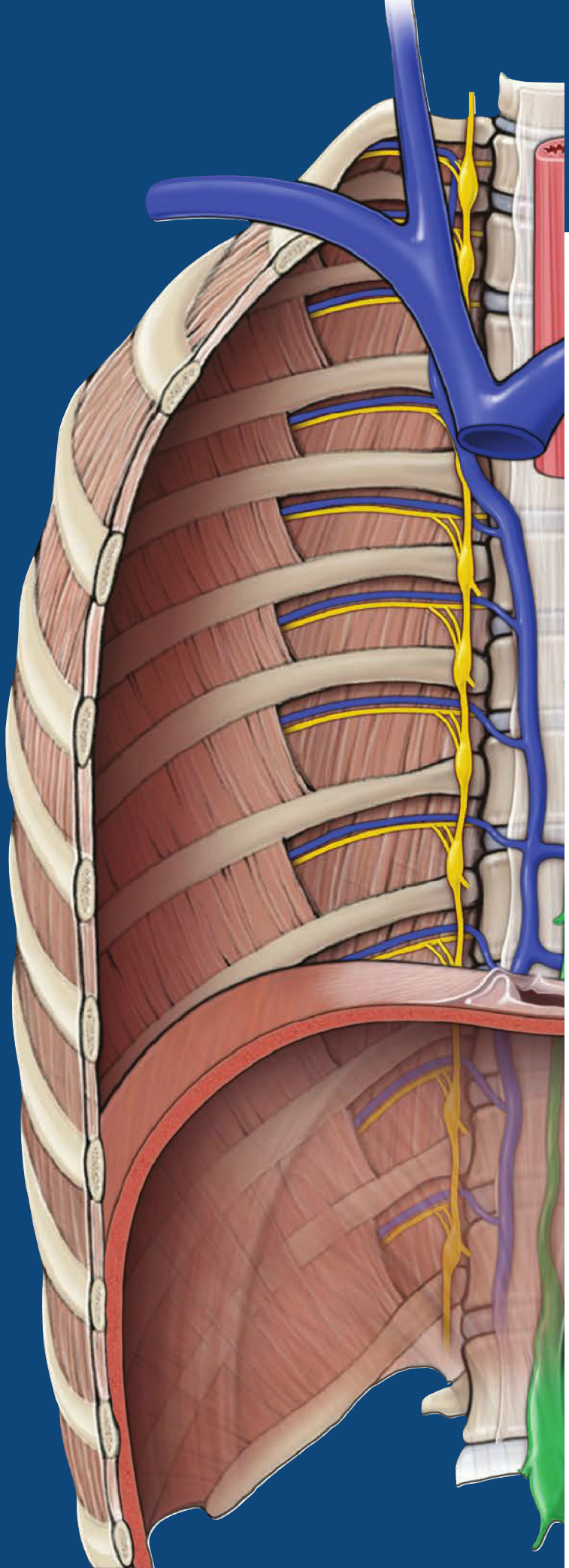

CHAPTER 4

HEART

Pericardium 52
Overview of the Heart 52
Coronary Circulation 54
Chambers of the Heart 56
Heart Valves 58
Cardiac Cycle 58
Innervation of the Heart 60

PERICARDIUM

BIG PICTURE

The pericardial sac encloses the heart, akin to the pleura that encloses the lungs. The pericardial sac has parietal and visceral layers separating a pericardial cavity lined with fluid.

PERICARDIAL SAC

The heart is enclosed within a three-layered pericardial sac that protects the heart, prevents overfilling, and produces a lubricating fluid. The three layers are as follows (Figure 4-1A and B):

- **Fibrous parietal pericardium.** Tough external layer of connective tissue that surrounds the serous pericardium and prevents overfilling; it is attached to the central tendon of the diaphragm and blends with the tunica external of the great vessels of the heart.
- **Serous pericardium.** Thin two-layered serous membrane is composed of an outer parietal layer and an inner visceral layer; produce pericardial fluid to line the pericardial cavity.
  - **Parietal layer of serous pericardium.** Covers the deep surface of the fibrous parietal pericardium; often referred to as the serous parietal pericardium.
  - **Visceral layer of serous pericardium.** Serous tissue that intimately follows the external contours of the heart surface; the combination of visceral pericardium with the underlying loose connective and adipose tissues is referred to as the **epicardium**.
  - **Pericardial cavity.** The space between the parietal and visceral layers of serous pericardium; contains serous fluid, which lubricates the heart to reduce friction.

The pericardial sac has two **pericardial sinuses**:

- **Transverse sinus.** A horizontal space between the arterial ends of heart vessels anteriorly (ascending aorta and pulmonary trunk) and venous ends posteriorly (SVC); on each side the transverse sinus opens into the pericardial cavity.
- **Oblique sinus.** A cul-de-sac space deep to the heart and surrounded by the reflection of the serous pericardium around the IVC and right and left pulmonary veins.

The pericardium has the following neurovascular supply:

- **Innervation.** Parietal pericardium receives general sensory innervation from the phrenic nerve; visceral pericardium receives visceral sensory innervation from sympathetic nerves (to T1–T4 spinal cord levels) and vagus nerves (to medulla oblongata).
- **Blood supply.** Primarily from the pericardiacophrenic vessels.

OVERVIEW OF THE HEART

BIG PICTURE

The heart has the following **three layers** (Figure 4-1B):

- **Epicardium.** The outer layer of the heart consisting of loose connective tissue, adipose tissue and visceral pericardium.
- **Myocardium.** The middle layer, consisting of cardiac muscle responsible for contraction of the heart.
- **Endocardium.** The inner layer, consisting of endothelial cells that line the lumen of the four chambers.

HEART CHAMBERS

- **Atria and ventricles.** The heart has four chambers (two atria and two ventricles):
  - **Two atria.** Paired heart chambers that receive blood from the different circulatory systems: the right atrium receives deoxygenated blood from the systemic and coronary circulations, whereas the left atrium receives oxygenated blood from the pulmonary circulation.
  - **Two ventricles.** Paired heart chambers that pump blood away from the heart; the right ventricle pumps blood to the lungs, whereas the left ventricle pumps blood to the remainder of the body, including the myocardium.

SIDES OF THE HEART

- **Left and right sides.** The heart has two chambers that comprise its right side (the right atrium and ventricle) and two chambers that comprise its left (the left atrium and ventricle):
  - **Right side (pulmonary circuit).** The right atrium receives deoxygenated blood from the systemic and coronary circulations; the right ventricle pumps this blood to the lungs.
  - **Left side (systemic circuit).** The left atrium receives oxygenated blood from the pulmonary veins; the left ventricle pumps this blood to the systemic and coronary circulations.

BORDERS AND SURFACES OF THE HEART

The heart is located within the middle mediastinum and consists of the following borders and surfaces (Figure 4-1C–F):

- **Base (superior surface).** Has the great vessels that enter and exit the heart.
- **Right border.** Formed by the right atrium.
- **Anterior surface (sternocostal surface).** Formed by the right ventricle.
- **Left border.** Formed by the left ventricle
- **Posterior surface.** Formed by the left atrium.
- **Diaphragmatic (inferior) surface.** Formed by the left ventricle.
- **Apex.** Formed by the tip of the left ventricle; positioned at the left fifth IC space near the midclavicular line.

SULCI OF THE HEART

Internally, the heart is divided into four chambers. Externally, sulci mark the internal divisions of the chambers. The **cardiac sulci** are as follows:

- **Atrioventricular (AV) groove (coronary sulcus).** A narrow groove in the heart located along the boundary between the atria and the ventricles; the coronary sulcus is circumferential and is the groove in which the coronary vessels are located.
- **Anterior interventricular sulcus.** Located on the anterior surface of the heart between the left and right ventricles; this sulcus extends from the coronary sulcus to the apex and contains the left anterior descending artery and the great cardiac vein.
- **Posterior interventricular sulcus.** Located on the diaphragmatic surface of the heart between the left and right ventricles; it extends from the coronary sulcus to the apex and contains the posterior interventricular artery and the middle cardiac vein.

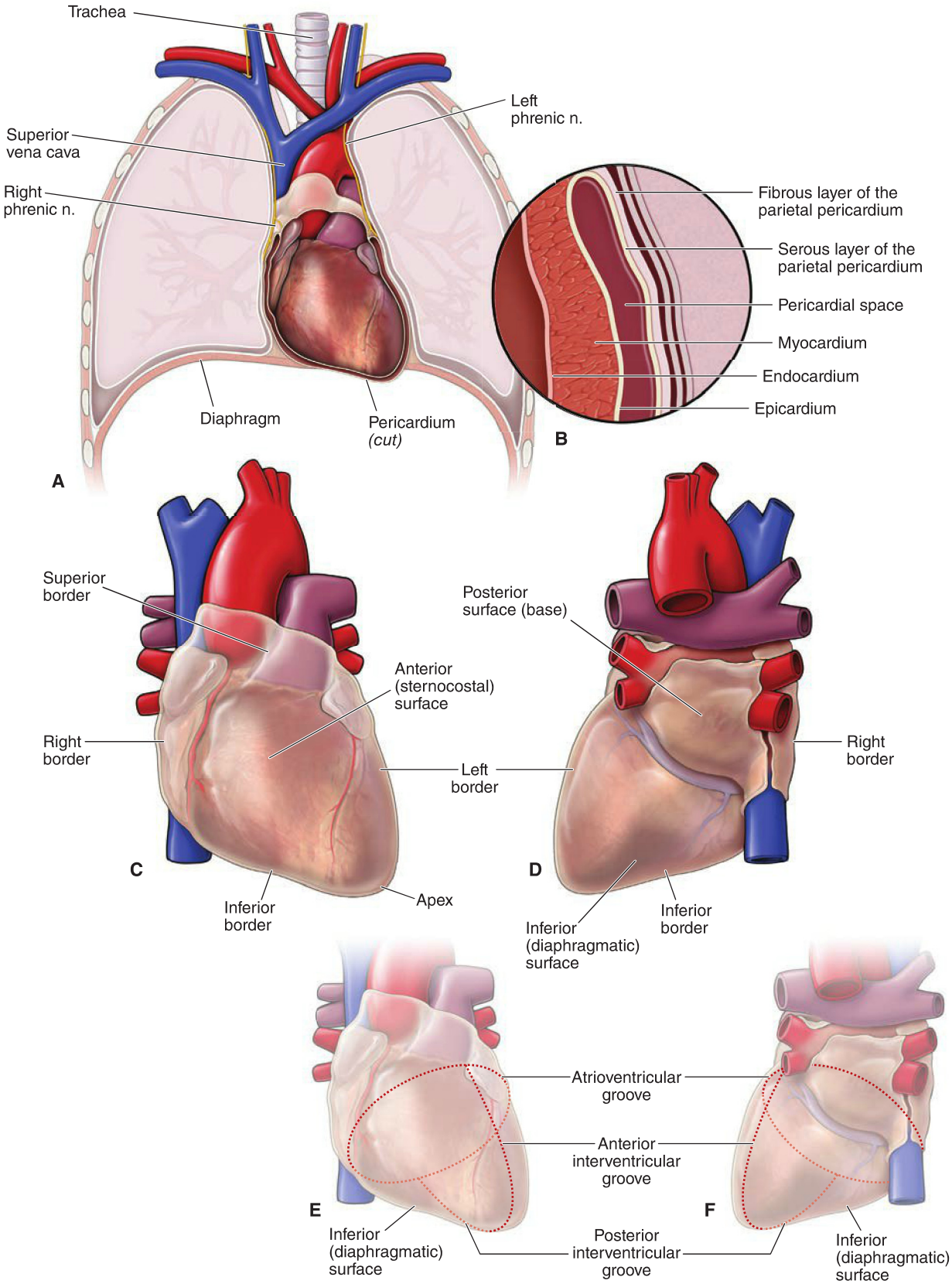

Figure 4-1: A. Coronary section through the thorax. **B**. Layers of the pericardial sac. **C**. Anterior (sternocostal) surface of the heart. **D**. Posterior (base) and inferior (diaphragmatic) surface of the heart. **E**. Atrioventricular (coronary) grooves in an anterior view. **F**. Atrioventricular (coronary) grooves in a posterior view.

CORONARY CIRCULATION

BIG PICTURE

Although blood fills the chambers of the heart, the myocardium is so thick that it requires its own artery–capillary–vein system, called the "coronary circulation," to deliver to and remove blood from the myocardium. The vessels that supply oxygenated blood to the myocardium are known as **coronary arteries**. The vessels that remove the deoxygenated blood from the heart muscle are known as **cardiac veins**.

CORONARY ARTERIES AND ASSOCIATED BRANCHES

The coronary arteries and its branches course along the epicardium in the cardiac sulci and interventricular grooves (Figure 4-2). Each coronary artery sends branches to the heart muscle. Blood flow in the coronary arteries is maximal during diastole (ventricular relaxation) and minimal during systole (ventricular contraction) because of the compression of the blood vessels in the myocardium during systole. All coronary arteries branch from either the left or the right coronary arteries.

▼ **Myocardial infarction.** Coronary arteries are classified as an "end circulation"; that is, they may not anastomose with each other. Therefore, blockage of any of these vessels is detrimental because once a coronary artery is blocked, cardiac tissue supplied by that vessel is damaged. ▼

LEFT CORONARY ARTERY (LCA) Arises from the aorta, superior to the left cusp of the aortic valve, and is shorter than the right coronary artery. However, the branches from the LCA distribute blood to a larger area of myocardium (supplies most of the left ventricle, left atrium, bundle of His, and the anterior aspect of the interventricular septum). The LCA gives rise to the following branches:

- **Left anterior descending artery (LAD).** Also called the anterior interventricular artery. It supplies the anterior region of the left ventricle, including the anterolateral myocardium, apex, anterior interventricular septum, and the anterolateral papillary muscle.
- **Left circumflex artery (LCX).** Wraps around the left side of the heart in the AV groove and supplies the posterolateral side of the left ventricle.

RIGHT CORONARY ARTERY (RCA) Arises from the aorta, superior to the right cusp of the aortic valve. The RCA travels along the right AV groove, between the root of the pulmonary trunk and the right auricle, and supplies the right atrium, right ventricle, the sinuatrial (SA) node, and the AV node. The RCA gives rise to the following branches:

- **SA nodal artery.** Passes between the right atrium and the opening of the superior vena cava and supplies the SA node.
- **Right marginal artery.** Supplies the right ventricular wall.
- **Posterior descending artery (PDA).** Also known as the posterior interventricular artery. Supplies the inferior heart wall, posterior interventricular septum, and the posteromedial papillary muscle.

CORONARY DOMINANCE Coronary dominance is determined by the artery that gives rise to the PDA. Most hearts (approx. 80–85%) are right dominant because the RCA gives rise to the PDA. In left dominant hearts, the LCX gives rise to the PDA. In a codominant heart the PDA is supplied by both the RCA and LCX. Coronary dominance has clinical implications when imaging the heart, planning for a coronary arterial bypass graft (CABG), or when considering the implications of myocardial ischemia.

CARDIAC VEINS

The cardiac veins and associated tributaries are the major veins of the coronary circulation and run parallel to the arteries (Figure 4-2). They drain blood from the myocardium. The cardiac veins are as follows:

- **Coronary sinus.** The coronary sinus is the largest cardiac vein and lies posteriorly in the AV groove (coronary sulcus). The coronary sinus collects blood from the great, middle, and small cardiac veins. The blood is returned to the right atrium via an opening superior to the septal leaflet of the tricuspid valve.
  - **Great cardiac vein.** Begins at the apex of the heart and ascends in the anterior interventricular groove, parallel to the LAD, and drains into the coronary sinus.
  - **Middle cardiac vein.** Begins at the apex of the heart and ascends in the posterior interventricular sulcus, parallel to the PDA, and drains into the coronary sinus.
  - **Small cardiac vein.** Courses along the acute margin of the heart with the right marginal artery and empties into the coronary sinus.
- **Anterior cardiac veins.** Drain the anterior portion of the right ventricle, cross the coronary groove, and empty directly into the right atrium. Anterior cardiac veins do not drain into the coronary sinus.

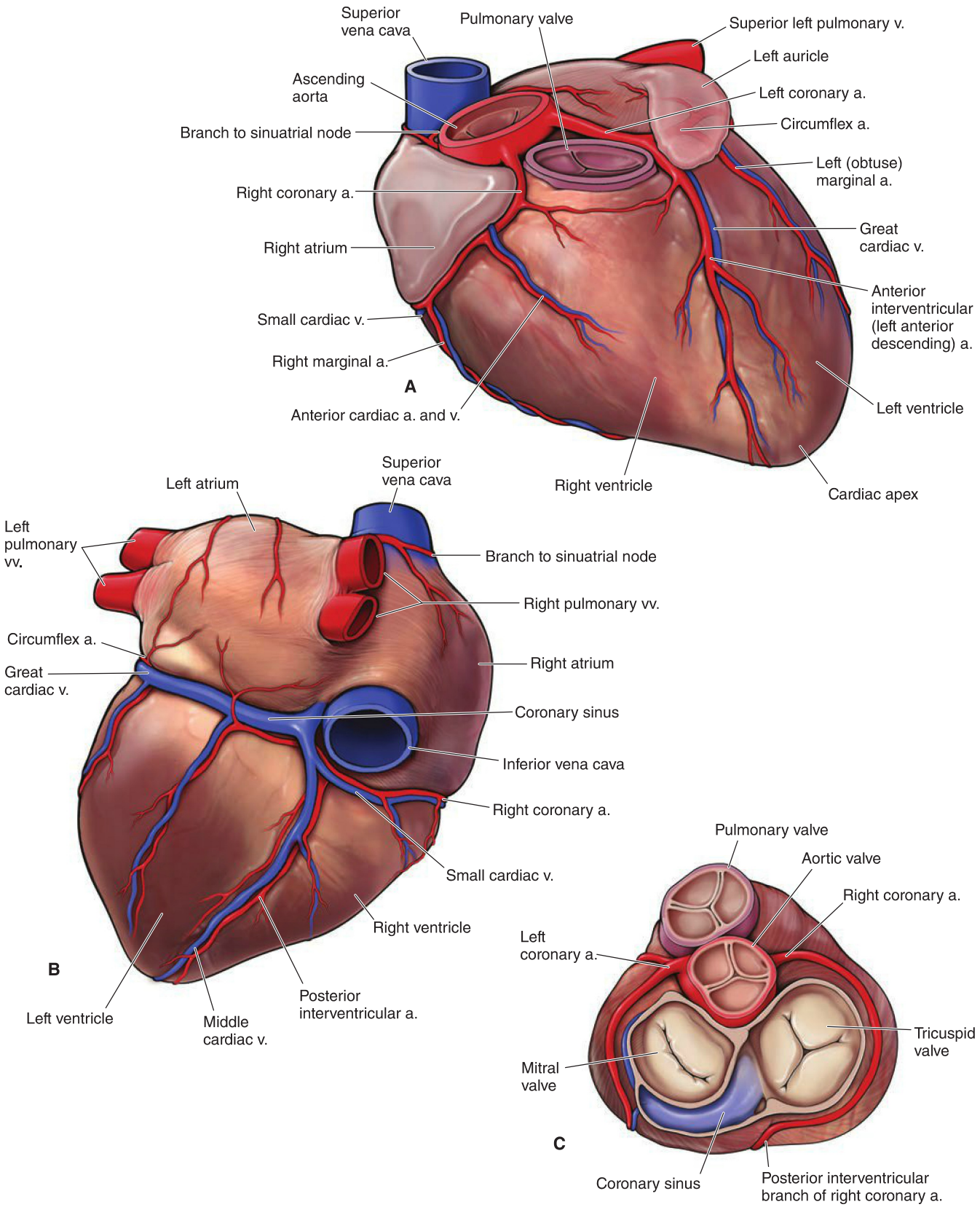

Figure 4-2: Anterior (**A**), posterior (**B**), and superior (**C**) views of the coronary arteries and cardiac veins (note: in **(C)** the atria, pulmonary trunk, and ascending aorta are removed).

CHAMBERS OF THE HEART

BIG PICTURE

The human heart is a four-chambered pump composed of cardiac muscle. Two of the heart chambers, called **atria**, are relatively thin walled. The function of atria is to receive blood from organs outside the heart and pump the blood under low pressure to the corresponding ventricle. The two **ventricles** have thicker muscular walls that pump blood to organs.

RIGHT ATRIUM

The right atrium (RA) forms the right side of the heart and has the following functions:

- **During diastole.** Pumps deoxygenated blood through the tricuspid (right AV) valve into the right ventricle.
- **During systole.** Receives deoxygenated venous blood from the systemic circulation via the superior vena cava (SVC), inferior vena cava (IVC), and the coronary circulation via the coronary sinus.

Anatomical structures associated with the RA are as follows (Figure 4-3A):

- **Venae cavae.** The SVC and IVC deliver deoxygenated blood from the tissues above the diaphragm and below the diaphragm, respectively.
- **Coronary sinus.** The coronary sinus returns deoxygenated blood from the coronary circulation to the RA via an opening superior to the septal leaflet of the tricuspid valve.
- **Foramen/fossa ovalis.** In the fetus, the **foramen ovale** is an opening in the interatrial septum, which allows blood entering the RA from the venae cavae to pass directly to the left side of the heart, thus bypassing the lungs. Blood flow to the lungs is bypassed in a fetus because the placenta is responsible for gas exchange in utero. At birth, the foramen ovale closes and is then referred to as the **fossa ovalis**.
- **Right auricle.** An out-pouching of tissue on the superior aspect of the RA (derived from the fetal atrium). The rough myocardium on its internal surface is known as the **pectinate muscles**.
- **Sinus venarum.** The smooth surface along the internal surface of the remainder of the RA (derived from the fetal sinus venosus).
- **Crista terminalis.** An internal vertical ridge that extends from the SVC to the IVC and separates the rough and smooth portions of the RA. The SA node is located in the superior part of the crista terminalis.

Postnatally, a **patent foramen ovale** (PFO) is a congenital defect in the septal wall between the two atria. Before birth, the foramen is open (patent), providing a right-to-left shunt of blood from the right atrium to the left atrium to reduce blood flow to the fetal lungs. After birth, the foramen ovale gradually closes because of increased pressure in the left side of the heart. Failure of the foramen ovale to close occurs in approximately 20% of the population. This results in blood bypassing the lungs after birth, which interferes with gas exchange. Most cases of patent foramen ovale are asymptomatic.

RIGHT VENTRICLE

The right ventricle (RV) forms the anterior surface side of the heart and has the following functions:

- **During diastole.** Receives deoxygenated blood from the RA via the tricuspid valve.
- **During systole.** Pumps deoxygenated blood through the pulmonary valve into the pulmonary trunk en route to the lungs.

Anatomical structures associated with the RV are as follows (Figure 4-3B):

- **Trabeculae carneae.** Projecting ridges of myocardium on the internal surface of the RV.
- **Papillary muscles.** Elevations of myocardium that attach to the cusps of the tricuspid valve via fibrous chords called chordae tendineae; contraction of papillary muscles during systole keeps the leaflets of the tricuspid valve closed, thus preventing prolapse.
- **Moderator band** (septomarginal trabecula). A ridge of myocardium coursing between anterior and septal papillary muscles and the RV wall. When present (which occurs in approximately 60% of hearts), the moderator band conveys within it the right branch of the AV bundle, which is part of the electrical conducting system of the heart.

LEFT ATRIUM

The left atrium (LA) forms the posterior region of the heart (the LA is juxtaposed to the esophagus). The LA has the following functions:

- **During diastole.** The LA pumps oxygenated blood through the bicuspid (left AV/mitral) valve into the LV.
- **During systole.** The LA receives oxygenated blood from the lungs via the pulmonary veins.

Anatomical structures associated with the LA are as follows (Figure 4-3C):

- **Pulmonary veins.** Paired veins on the left and right deliver oxygenated blood from the lungs to the LA.

LEFT VENTRICLE

The left ventricle (LV) forms the left surface side of the heart and the primary portion that sits on the diaphragm. The myocardial wall of the LV is much thicker than that of the RV, which is necessary to generate higher pressure to pump blood to the organs, muscles, and skin. The LV has the following functions:

- **During diastole.** Receives oxygenated blood from the LA via the bicuspid valve.
- **During systole.** Pumps oxygenated blood through the aortic valve into the aorta en route to the coronary and systemic circulations.

Anatomical structures associated with the LV are as follows (Figure 4-3C):

- **Trabeculae carneae.** Projecting ridges of myocardium on the internal surface of the RV.
- **Papillary muscles.** Elevations of myocardium that attach to the cusps of the bicuspid valve via fibrous chords called chordae tendineae; contraction of papillary muscles during systole keeps the leaflets of the bicuspid valve closed, thus preventing prolapse.

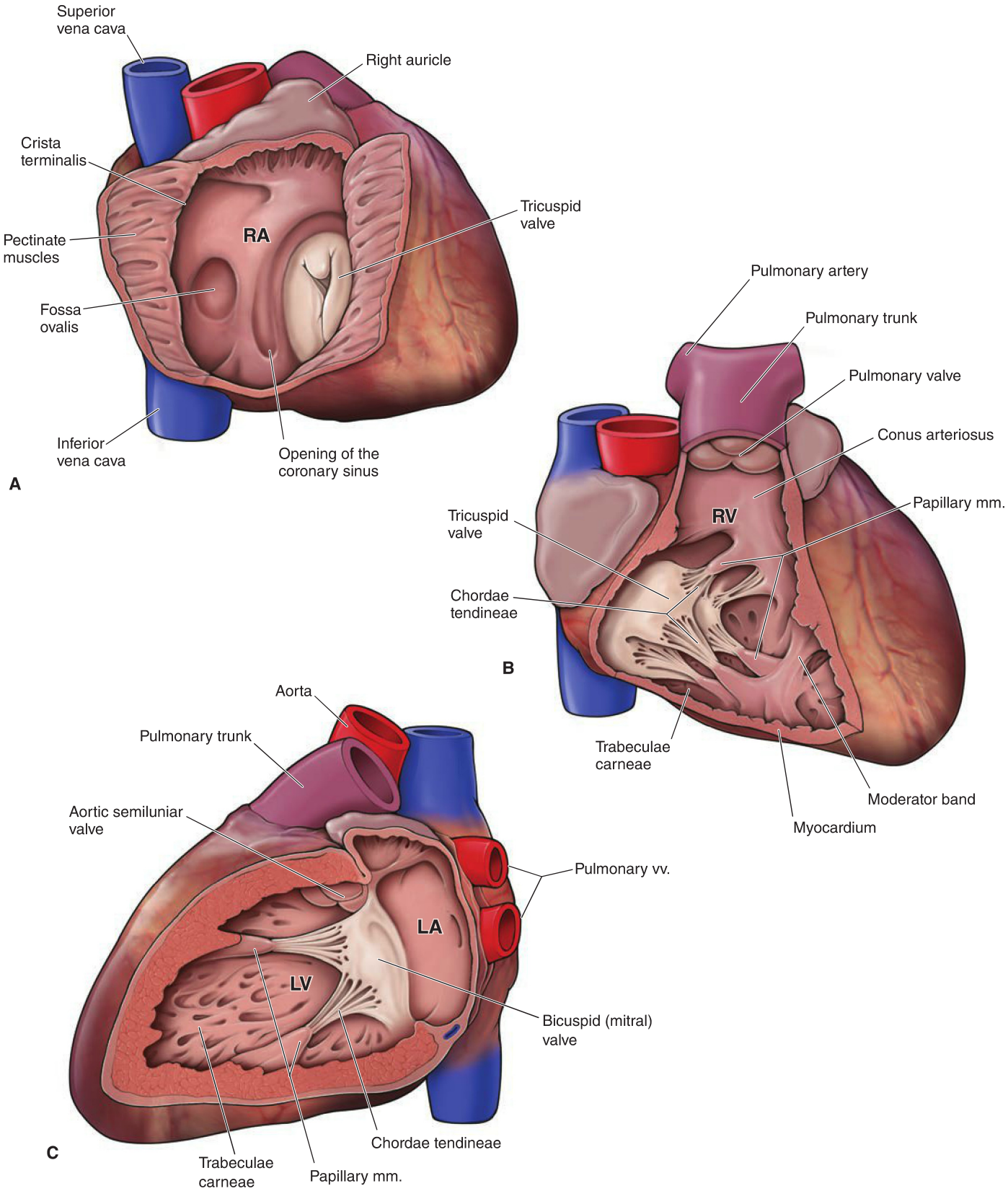

Figure 4-3: A. Right atrium open. **B**. Right ventricle open. **C**. Left atrium and left ventricle open.

HEART VALVES

BIG PICTURE

Heart valves ensure unidirectional flow of blood into and out of the chambers of the heart. Atrioventricular valves (tricuspid and bicuspid) ensure blood flows from atria into ventricles and not vice versa. Semilunar valves (pulmonary and aortic) ensure blood flows from ventricles into the pulmonary or systemic circulations, respectively, and not vice versa.

ATRIOVENTRICULAR VALVES

Atrioventricular (AV) valves enable blood to flow from atria into ventricles and prevent backflow of blood. The closure of AV valves is known as the first heart sound and referred to as "S1".

The AV valves have the following components (sometimes referred to as the subvalvular apparatus):

- **Chordae tendineae.** Tendinous cords that connect AV valve leaflets to papillary muscles.
- **Papillary muscles.** Elevations of ventricular myocardium that attach to the AV valve leaflets via chordae tendineae. Together, papillary muscles and chordae tendineae keep AV valves from prolapsing into the atria when closing during systolic contraction of the ventricles.

The two AV valves are as follows:

- **Tricuspid (right AV) valve.** This valve has three leaflets and is thus referred to as the "tricuspid" valve. The tricuspid valve is located between the RA and RV and has the following functions:
  - The tricuspid valve opens during diastole when RA pressure exceeds RV pressure and blood flows from the RA into the RV.
  - The tricuspid valve closes during systole when RA pressure is less than RV pressure, thus preventing retrograde return of blood from the RV into the RA.
- **Bicuspid (left AV/mitral) valve.** This valve has two leaflets and is thus referred to as the "bicuspid" valve. The bicuspid valve is located between the LA and LV and has the following functions:
  - The bicuspid valve opens during diastole when LA pressure exceeds LV pressure and blood flows from the LA into the LV.
  - The bicuspid valve closes during systole when LA pressure is less than LV pressure, thus preventing retrograde return of blood from the LV into the LA.

SEMILUNAR VALVES

Semilunar valves (pulmonary and aortic valves) open to let blood to flow from the ventricles into the pulmonary and systemic circulations, respectively. The valves close during ventricular diastole to prevent backflow of blood into the ventricles. The closure of semilunar valves is known as the second heart sound and referred to as "S2". The semilunar valves lack chordae tendineae and have a similar structure and function as valves in veins.

The two semilunar valves are as follows:

- **Pulmonary valve.** The pulmonary valve lies between the RV and pulmonary trunk.
  - The pulmonary valve opens during systole because RV pressure exceeds the pressure in the pulmonary trunk and blood is forced through the opened valve into the pulmonary trunk.
  - The pulmonary valve closes during diastole when RV pressure rapidly drops to below pulmonary arterial pressure, thus preventing retrograde return of blood from the pulmonary trunk back into the RV.
- **Aortic valve.** The aortic valve is located between the LV and the ascending aorta.
  - The aortic valve opens during systole when LV pressure exceeds the pressure in the ascending aorta. At this point, blood from the LV flows into the ascending aorta.
  - The aortic valve closes during diastole when LV pressure rapidly drops to below aortic pressure, thus preventing retrograde flow of blood from the ascending aorta back into the LV.

CARDIAC CYCLE

The flow of blood through the heart is described in the following steps (Figure 4-4):

A. Atrial filling. Blood returns to the atria of the heart from all tissues of the body:
- The right atrium (RA) fills with deoxygenated blood from the systemic and coronary circulations.
- The left atrium (LA) fills with oxygenated blood from the pulmonary circulation.

B. Ventricular filling. RA and LA pressures rise until they exceed ventricular pressure, at which time the AV valves open and blood begins to fill the RV and LV. Near the end of ventricular filling, the atria contract simultaneously.

C. and D. Ventricular contraction. Ventricles begin to contract and when ventricular pressure exceeds that of the atria the blood forces the AV valves closed. Closure of the AV valves causes the S1 ("lub") heart sound. The chordae tendineae and papillary muscles prevent prolapse of the valve leaflets into the atria.

E. Ventricular ejection of blood. Ventricular pressure ultimately rises until it exceeds that of the pulmonary trunk and ascending aorta and thus forces these valves open. As a result, blood flows from the RV and LV into the pulmonary trunk and aorta, respectively.

F. Ventricular relaxation. As the ventricles relax, ventricular pressure ultimately decreases to below pulmonary arterial and aortic pressure. This causes blood to flow backward in the pulmonary trunk and ascending aorta, forcing the semilunar valves to close. This closure of the pulmonary and aortic valves results in the S2 ("dub") heart sound.

The cycle repeats.

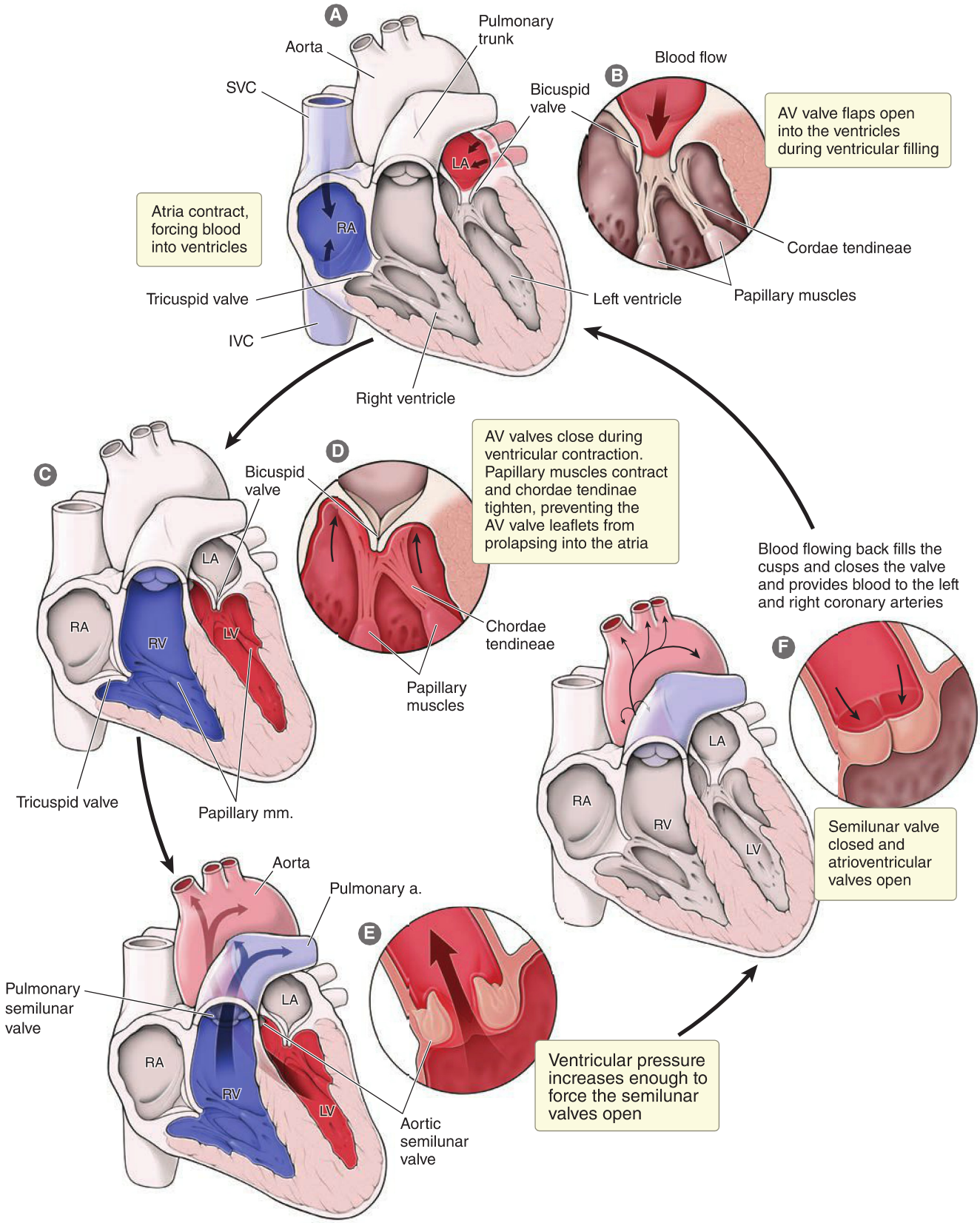

Figure 4-4: Schematic of the autonomic innervation and conduction system of the heart.

INNERVATION OF THE HEART

BIG PICTURE

Cardiac muscle has the ability to depolarize and contract independent of the nervous system. This intrinsic conduction system of the heart consists of specialized cells (SA node, AV node, bundle of His, and Purkinje fibers) that initiate and distribute electrical impulses to the rest of the cardiac muscle to control heart rate and myocardial contraction. The heart also receives extrinsic regulation by autonomic nerves (sympathetic and parasympathetic). Sympathetic nerves arise from T1–T4 spinal cord levels, course to the heart within cardiac splanchnic nerves, and increase heart rate and force of contractility. Parasympathetic nerves arise from the medulla oblongata, course to the heart within the vagus nerve, and decrease heart rate.

CONDUCTING SYSTEM OF THE HEART

The heart's intrinsic conducting system consists of noncontractile cardiac cells specialized to initiate and distribute impulses throughout the heart. In this way the heart depolarizes and contracts in an orderly, sequential manner from atria to ventricles. The sequence of excitation is as follows (Figure 4-5):

- **Sinoatrial (SA) node.** Located in the superior region of the crista terminalis, where the RA meets the SVC.
  - **Function.** Serves as the "pacemaker of the heart" and initiates the heartbeat; is altered by autonomic nerves (sympathetic stimulation speeds it up, parasympathetic (vagal) stimulation slows it down). The wave of depolarization spreads down the walls of the atria, stimulating contraction of the myocardium, and eventually reaches and stimulates the AV node.
  - **Vascular supply.** Supplied by the artery to the SA node, which arises from the RCA.
- **Atrioventricular (AV) node.** Located in the interatrial septum directly above the opening of the coronary sinus.
  - **Function.** This node receives impulses from the SA node and passes them to the AV bundle (of His). The AV node also receives autonomic branches, primarily from sympathetics.
  - **Vascular supply.** Supplied by the PDA, which arises from the RCA.
- **AV bundle (of His).** Arises at the AV node and descends through the fibrous skeleton of the heart where it divides into the left and right bundles (of His), corresponding to the left and right ventricles, respectively.
  - **Function.** Transmits impulses from the AV node, down the interventricular septum to the ventricles. The left and right bundles give rise to Purkinje fibers, which ultimately distribute the impulse to the ventricular muscle.

SYMPATHETIC INNERVATION OF THE HEART

Sympathetic innervation of the heart is as follows (Figure 4-5):

- **CNS origin.** Preganglionic sympathetic neurons originate bilaterally in lateral horn gray matter of T1–T4 spinal cord levels. Axons course through the ventral root, into the ventral ramus, through white rami communicans where they enter the sympathetic chain and synapse in the cervical or thoracic sympathetic chain ganglia.
- **Sympathetic chain ganglia.** Upon entering the sympathetic chain, preganglionic sympathetic neurons synapse in thoracic or cervical sympathetic ganglia:
  - **Thoracic (T1–T4) sympathetic chain ganglia.** Some preganglionic sympathetic neurons synapse with postganglionic sympathetic neurons in thoracic sympathetic chain ganglia. Postganglionic sympathetic neurons exit the sympathetic chain as thoracic cardiac splanchnic nerves, course through the cardiac plexus, and innervate the heart.
  - **Cervical sympathetic chain ganglia.** Some preganglionic sympathetic neurons ascend up the sympathetic chain and synapse in the **superior, middle,** or **inferior cervical sympathetic ganglia.** Postganglionic sympathetic neurons exit the sympathetic chain as cervical cardiac splanchnic nerves course through the cardiac plexus and innervate the heart.
- **Effects.** Postganglionic sympathetic neurons release norepinephrine (noradrenaline) at the SA and AV nodes, and myocardium of the atria and ventricles. Sympathetic innervation increases the overall activity of the heart in the following manner:
  - Increases rate of discharge at the SA node and thus increases heart rate.
  - Increases rate of conduction and level of excitability in all regions of the heart.
  - Increases force of contraction of all cardiac myocardium (atria and ventricles).

PARASYMPATHETIC INNERVATION OF THE HEART

Parasympathetic innervation of the heart is as follows:

- **CNS origin.** Preganglionic parasympathetic neurons originate bilaterally in the dorsal vagal nuclei of the medulla oblongata. Axons descend within the carotid sheath and courses through the cardiac plexus.
- **Intramural ganglia.** The synapse of preganglionic and postganglionic parasympathetic neurons occurs either in intramural ganglia, which reside in either the cardiac plexus or in the walls of the heart adjacent the SA node. Postganglionic parasympathetic neurons course to the SA and AV nodes.

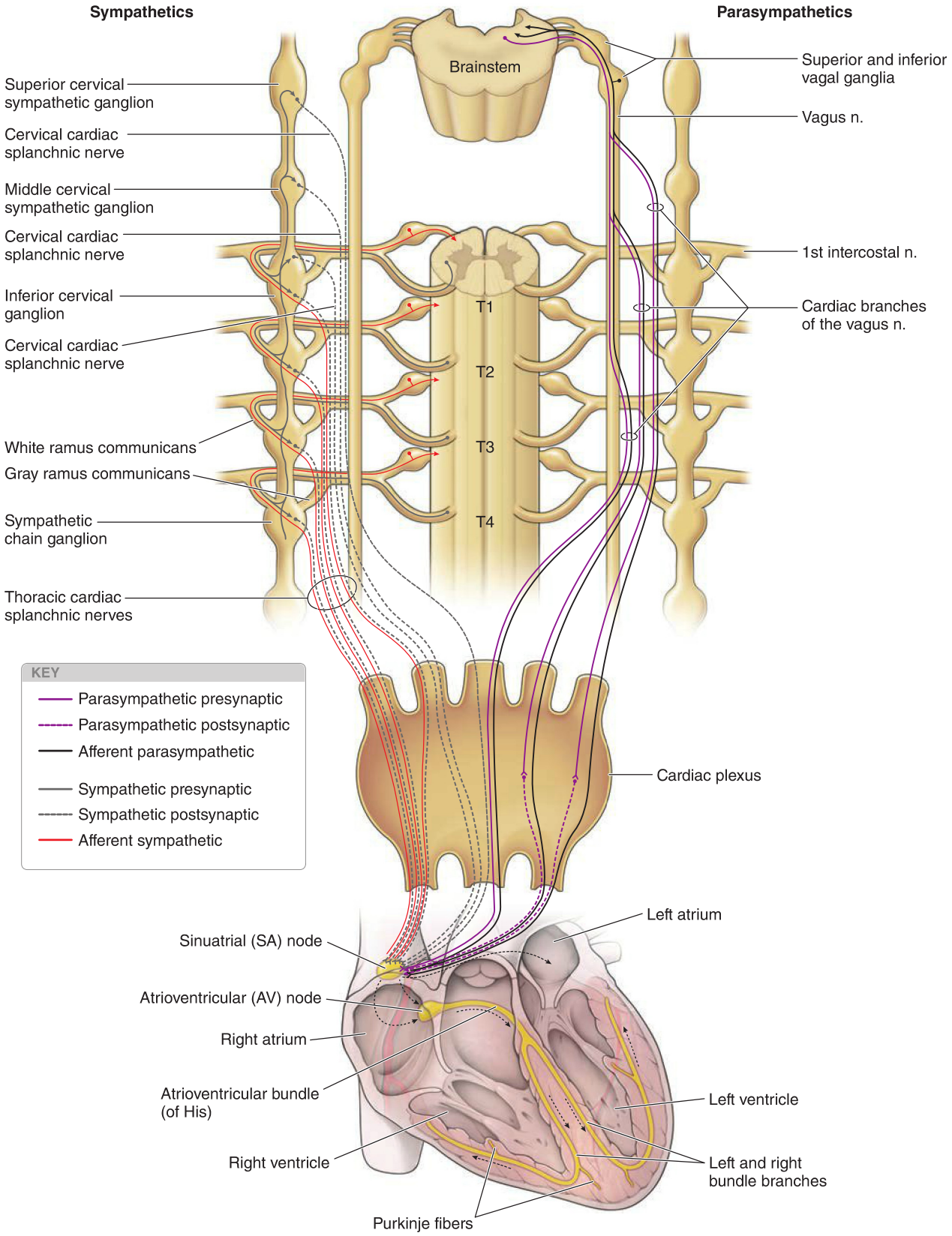

Figure 4-5: Heart valves and the cardiac cycle.

Effects. Postganglionic parasympathetic neurons release acetylcholine (ACh) at the SA and AV nodes, to a lesser extent atrial myocardium and a much lesser extent ventricular myocardium. Parasympathetic innervation of the heart has the following effects:

- Decreases the rate of rhythm of the SA node and thus decreases heart rate.
- Decreases the excitability of the AV node and associated junctional fibers thereby slowing transmission of the cardiac impulse from the atria to the ventricles.

Referred pain. Visceral sensory neurons course from the heart to the T1–T4 spinal cord levels within the cardiac splanchnic nerves (same nerve bundles as sympathetic efferent neurons). These sensory neurons are sensitive to **ischemia** (tissue damage due to lack of oxygen) and mediate the visceral pain associated with angina pectoris and myocardial infarctions. The myocardial ischemic pain is often referred to regions of the T1–T4 dermatomes most likely because the visceral sensory neurons enter the spinal cord at the same segmental levels as the T1–T4 spinal nerves. It is hypothesized that the brain cannot distinguish between sensory input from the ischemic heart tissue (as relayed by visceral sensory neurons) and cutaneous sensation (as relayed by T1–T4 spinal nerves). Therefore, the patient may perceive ischemic heart pain as coming from the chest or upper limb (where the T1–T4 dermatomes reside).

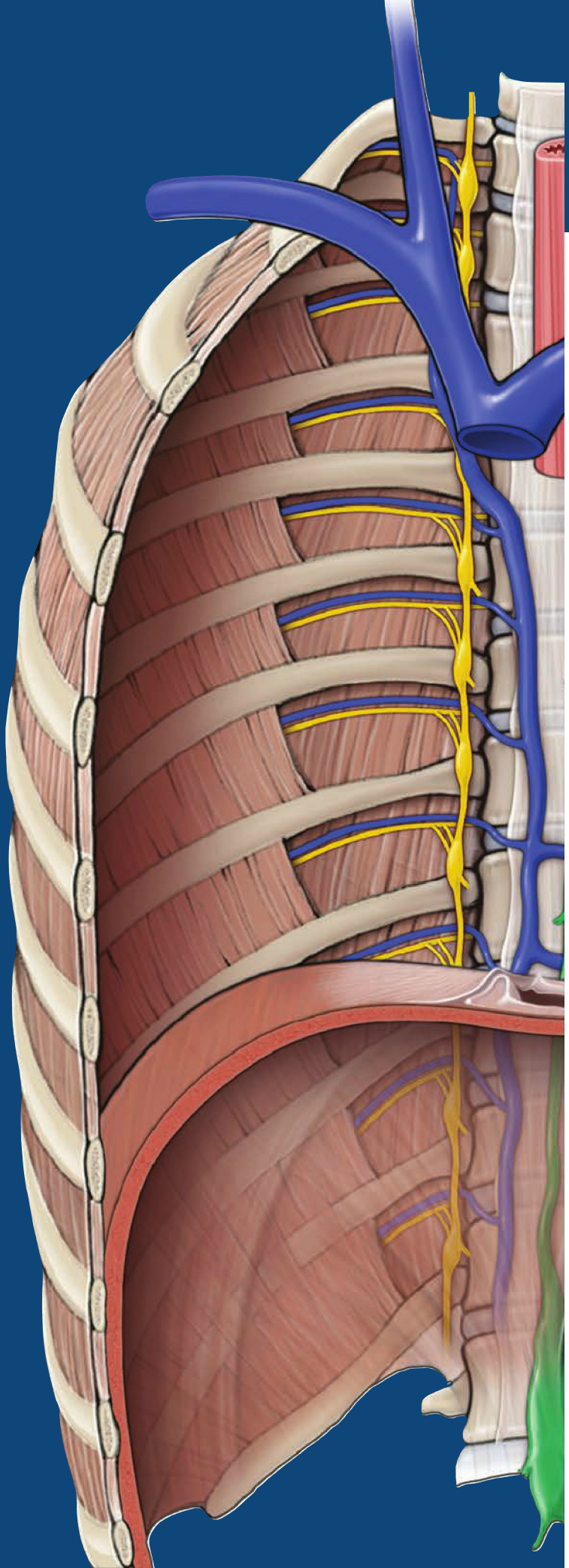

CHAPTER 5

SUPERIOR AND POSTERIOR MEDIASTINUM

Divisions of the Mediastinum 64

Sympathetic Trunk and Associated Branches 66

Azygos Veins, Thoracic Duct, and Thoracic Aorta 68

Posterior and Superior Mediastinum 70

Study Questions 72

Answers 74

DIVISIONS OF THE MEDIASTINUM

BIG PICTURE

The mediastinum is the anatomic region medial to the pleural sacs, between the sternum, vertebral column, rib 1, and the diaphragm. The mediastinum is further divided into inferior and superior regions by the transverse thoracic plane, which is a horizontal plane passing from the sternal angle to the T4–T5 intervertebral disc (Figure 5-1A). The inferior mediastinum is classically subdivided into anterior, middle, and posterior parts. Therefore, the four subregions of the mediastinum are the anterior mediastinum, middle mediastinum, posterior mediastinum, and superior mediastinum.

- **Anterior mediastinum.** The anterior mediastinum is deep to the sternum and bounded by the sternal angle, pericardial sac, and diaphragm; contains the following:
  - **Adipose tissue.**
  - **Thymus.** The thymus in adults is involuted and is primarily a connective tissue remnant.
- **Middle mediastinum.** The middle mediastinum contains the pericardial sac and heart (see Chapter 4 for further details).
- **Posterior mediastinum.** The posterior mediastinum contains the following anatomic structures, which are posterior to the pericardial sac (Figure 5-1B):
  - **Descending aorta.** The thoracic portion of the aorta that gives rise to posterior intercostal arteries.
  - **Azygos system of veins.** Receives venous blood from the thoracic wall.
  - **Thoracic duct.** The primary lymphatic duct that receives lymph from all tissues below the diaphragm and from the left side of the head, neck, upper limb, and thorax.
  - **Esophagus.** The esophagus courses vertically directly posterior to the left atrium.
  - **Sympathetic nerves.**

This chapter focuses on the structures located in the posterior mediastinum and their projection into the superior mediastinum.

- **Superior mediastinum.** The superior mediastinum is the region above the sternal angle and contains the following structures:
  - **Aortic arch.** The aortic arch arises at the level of the transverse thoracic plane, ascends up into the superior mediastinum, and descends in the posterior mediastinum. The aortic arch gives rise to the following three primary branches:
    - **Brachiocephalic trunk.** Supplies the right side of the head and neck and right upper limb.
    - **Left common carotid artery.** Supplies the left side of the head and neck.
    - **Left subclavian artery.** Supplies the left upper limb.
  - **Superior vena cava (SVC).** The SVC collects all venous blood from tissues above the diaphragm. The primary tributaries of the SVC are the azygos vein and the **left and right brachiocephalic veins**.
  - **Trachea.** The trachea bifurcates at the level of the transverse thoracic plane into the left and right primary bronchi.
  - **Esophagus.** The esophagus is a vertical, muscular tube that is located posterior to the trachea and transports food from the pharynx to the stomach.
  - **Nerves.** The phrenic nerves (en route to the diaphragm) and vagus nerves (en route to thoracic and abdominal organs) course through the superior mediastinum.
  - **Thymus.** In an adult, the thymus is usually atrophied and presents as a fatty mass.

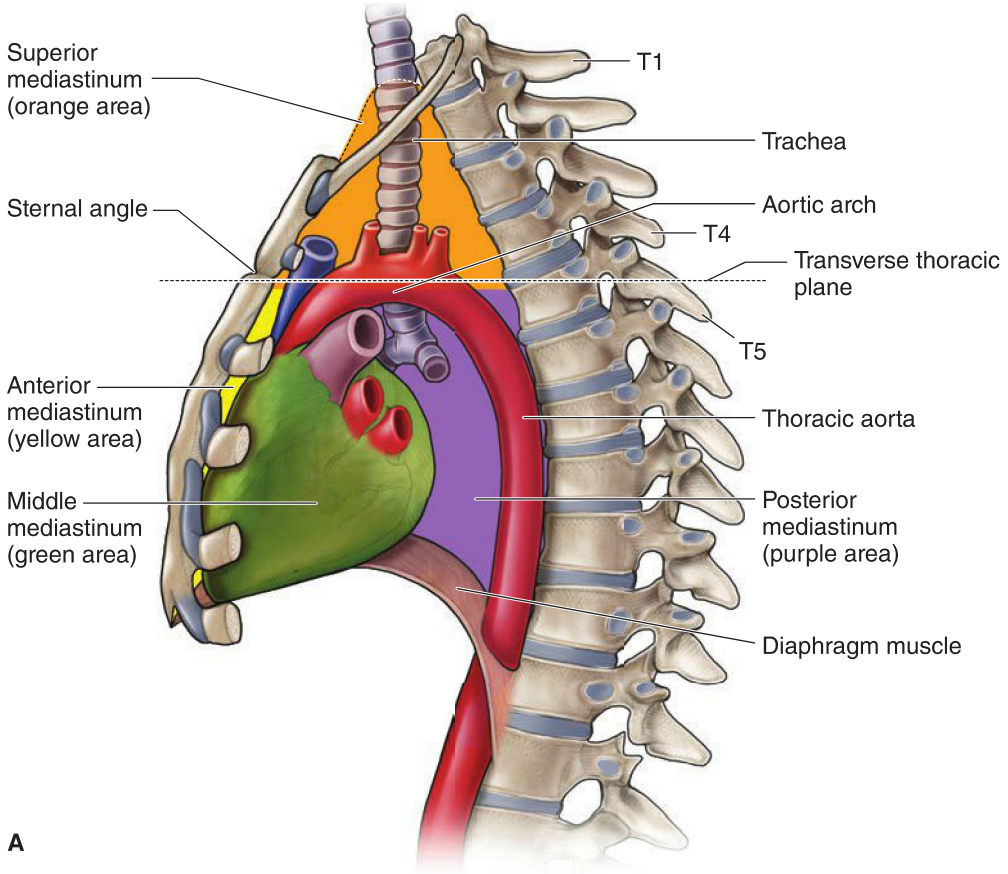

A

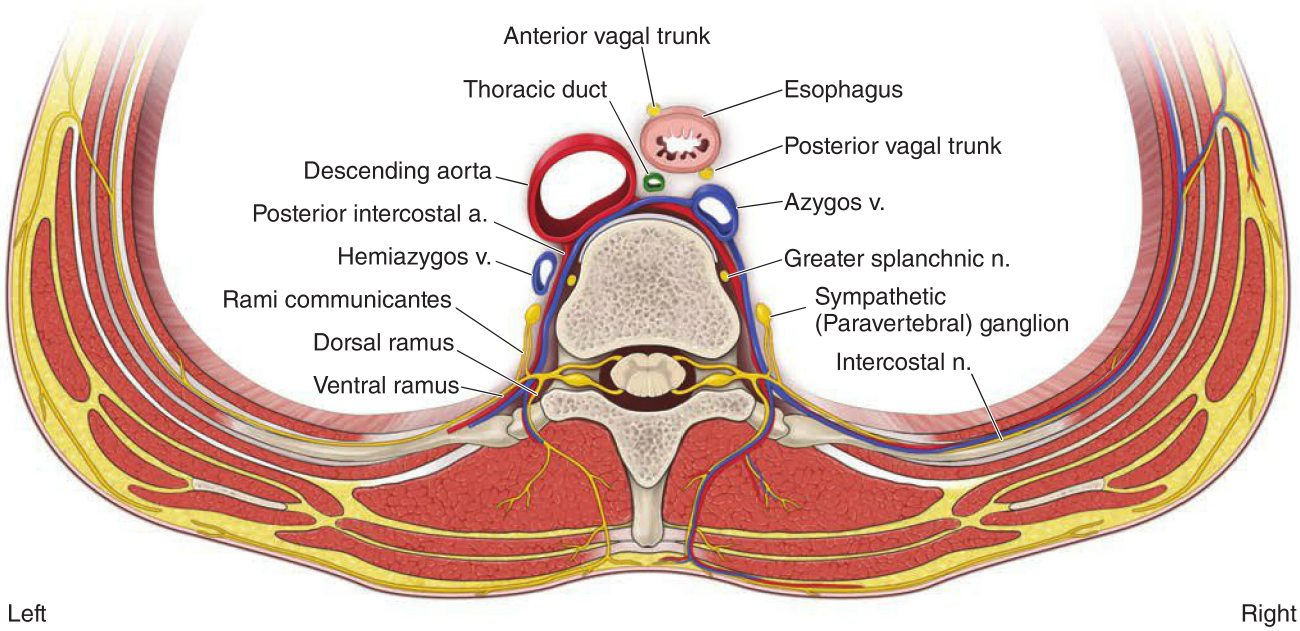

B Posterior mediastinum; superior view

Figure 5-1: A. The lateral view of the thorax illustrating the mediastinal subdivisions. **B**. The posterior mediastinum in axial section (superior view).

SYMPATHETIC TRUNK AND ASSOCIATED BRANCHES

BIG PICTURE

A nerve ganglion is a collection of neuronal cell bodies in the peripheral nervous system. The ganglia that comprise the sympathetic chain are neuronal cell bodies from postganglionic sympathetic neurons. The ganglia associated with the sympathetic chain are organized in a vertical fashion and are segmentally linked with each of the thoracic spinal nerves via white and gray communicantes. The sympathetic chain is associated with the preaortic ganglia by way of greater, lesser, and least splanchnic nerves.

SYMPATHETIC NERVES OF THE THORAX

The **thoracic sympathetic chain or trunk** courses vertically across the heads of the ribs along the posterior thoracic wall, deep to the parietal pleura. The chain continues superiorly into the neck and inferiorly into the abdominal cavity (Figure 5-2A). The sympathetic chain parallels the vertebral column and is therefore also referred to as the **paravertebral ganglia**.

The thoracic portion of the sympathetic trunk typically has 12 bilateral ganglia connected to adjacent thoracic spinal nerves by white and gray rami communicantes.

- **White rami communicantes** have myelinated nerve fibers and thus appear white.
- **Gray rami communicantes** have unmyelinated nerve fibers and, therefore, appear gray.

The thoracic sympathetic ganglia are:

- Numbered according to the thoracic spinal nerve with which they are associated.
- Collections of nerve cell bodies for postganglionic sympathetic neurons.
- Connected together by **internodal fibers**, which are composed of ascending and descending processes of preganglionic sympathetic neurons.

Recall that cell bodies for preganglionic sympathetic neurons originate in the lateral horn of the spinal cord gray matter. The axons exit the ventral root into the ventral ramus where white rami convey the **preganglionic sympathetic neurons** from the ventral ramus to a **sympathetic chain ganglion**. Once the preganglionic sympathetic neurons enter the sympathetic chain, the following possible pathways may occur (Figure 5-2B):

- Preganglionic sympathetic neurons synapse with postganglionic sympathetic neurons within the ganglion, and the segmental gray rami communicantes carry the postganglionic sympathetic neurons back to the ventral ramus at the same segmental level. The postganglionic sympathetic neurons innervate blood vessels, sweat glands, and arrector pili muscles of hair follicles within the associated dermatome.
- Preganglionic sympathetic neurons enter the sympathetic chain and ascend or descend to a different segmental ganglion (e.g., the superior cervical ganglion). At this location, a synapse between pre- and postganglionic sympathetic neurons occurs. Postganglionic sympathetic neurons exit the ganglion and course to the cardiac plexus (see the section Innervation of the Heart in Chapter 4).
- Preganglionic sympathetic neurons en route to abdominal organs course through the sympathetic ganglion without synapsing and become thoracic splanchnic nerves. Thoracic splanchnic nerves are as follows (Figure 5-2A):
  - **Greater splanchnic nerve.** Union of the T5–T9 splanchnic nerves; synapses are in the celiac or superior mesenteric ganglia.
  - **Lesser splanchnic nerve.** Union of the T10–T11 splanchnic nerves; synapses are in the superior mesenteric or aorticorenal ganglia.
  - **Least splanchnic nerve.** The T12 splanchnic nerve; synapses are in the aorticorenal ganglion.

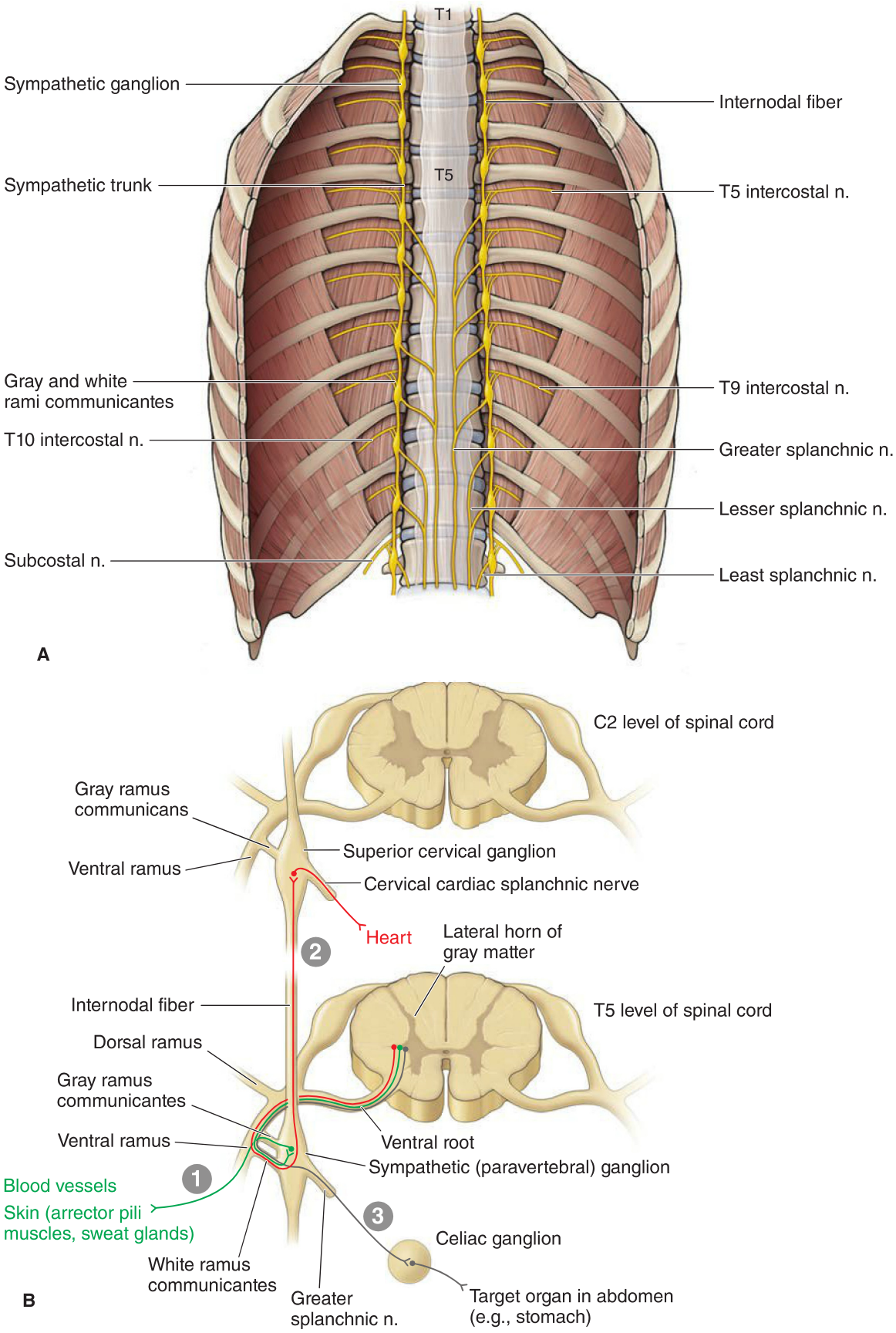

Figure 5-2: A. Sympathetic trunk and splanchnic nerves. **B**. Sympathetic pathways: (1) synapse in a paravertebral ganglion at the same level; (2) synapse in a paravertebral ganglion at a different level; (3) synapse in a prevertebral ganglion (i.e., celiac ganglion) via a splanchnic nerve.

AZYGOS VEINS, THORACIC DUCT, AND THORACIC AORTA

BIG PICTURE

The structures superficial to the sympathetic chain are the azygos system of veins (which drain blood from the posterior thoracic wall), the thoracic lymphatic duct (which courses between the thoracic aorta and esophagus), and the thoracic aorta (located left of the midline, along the anterior surface of the thoracic vertebrae).

AZYGOS SYSTEM OF VEINS

The azygos system of veins is considered to be the azygos vein on the right side of the thorax and the hemiazygos and accessory hemiazygos veins on the left side (Figure 5-3):

- **Azygos vein.** Formed by the union of the right ascending lumbar and right subcostal veins.
  - Receives blood directly from the right posterior intercostal veins and indirectly via the left-sided connections from the hemiazygos and accessory hemiazygos veins.
  - Terminates by arching over the right primary bronchus and converging with the SVC at the level of the sternal angle.
- **Hemiazygos vein.** Formed by the union of the left ascending lumbar and left subcostal veins.
  - Receives blood from the lower four left posterior intercostal veins.
  - Joins the azygos vein via tributaries that cross the vertebral column from left to right.
- **Accessory hemiazygos vein.** Usually begins at the fourth intercostal space.
  - Receives blood from the fourth to eighth left posterior intercostal veins.
  - Joins the azygos vein via tributaries that cross the vertebral column or that join with the hemiazygos vein.

The first posterior intercostal vein on each side drains into the corresponding brachiocephalic vein. Posterior intercostal veins two through four join to form the superior intercostal vein, which drains into the azygos vein on the right side and the brachiocephalic vein on the left side.

LYMPHATIC DRAINAGE

Lymph in the thoracic region drains via two lymphatic vessels, the thoracic duct and the right lymphatic duct.

1. The thoracic (lymphatic) duct:
   - Is the main lymphatic vessel that receives lymph from the entire body, with the exception of the right upper limb, the right side of the head and neck, and the right upper thorax.
   - May have a beaded appearance because of its numerous valves.
   - Begins in the abdomen just inferior to the diaphragm at a dilated sac created by convergence of the intestinal and lumbar lymphatic trunks, called the cisternal chili.
   - Ascends deep to the diaphragm by coursing through the aortic hiatus.
   - Continues superiorly between the esophagus and thoracic aorta.
   - Shifts to the left of the esophagus at the level of the sternal angle.
   - Curves laterally at the root of the neck and empties into the junction of the left internal jugular and subclavian veins.
2. The right lymphatic duct:
   - Drains the right side of the thorax, the right upper limb, and the right head and neck and empties into the junction of the right internal jugular and subclavian veins.

THORACIC AORTA

The thoracic (descending) aorta begins at the T4 vertebral level and courses anterior to the vertebral column, just left of the midline. The thoracic aorta enters the abdominal cavity through the aortic hiatus at vertebral level T12. The following thoracic branches arise from the thoracic aorta:

- **Posterior intercostal arteries (3–11).** Segmental arteries that arise bilaterally and supply the intercostal spaces and overlying skin. The first two intercostal arteries arise from the **costocervical trunk**.
- **Bronchial arteries.** Branches that supply the non-respiratory tissues in the lungs (usually one to the right bronchus and two to the left bronchus).
- **Esophageal arteries.** Supply the middle third of the esophagus.
- **Subcostal arteries.** Segmental arteries that arise bilaterally and supply the T12 segment.
- **Superior phrenic arteries.** Bilateral branches that supply the posterior regions of the diaphragm.

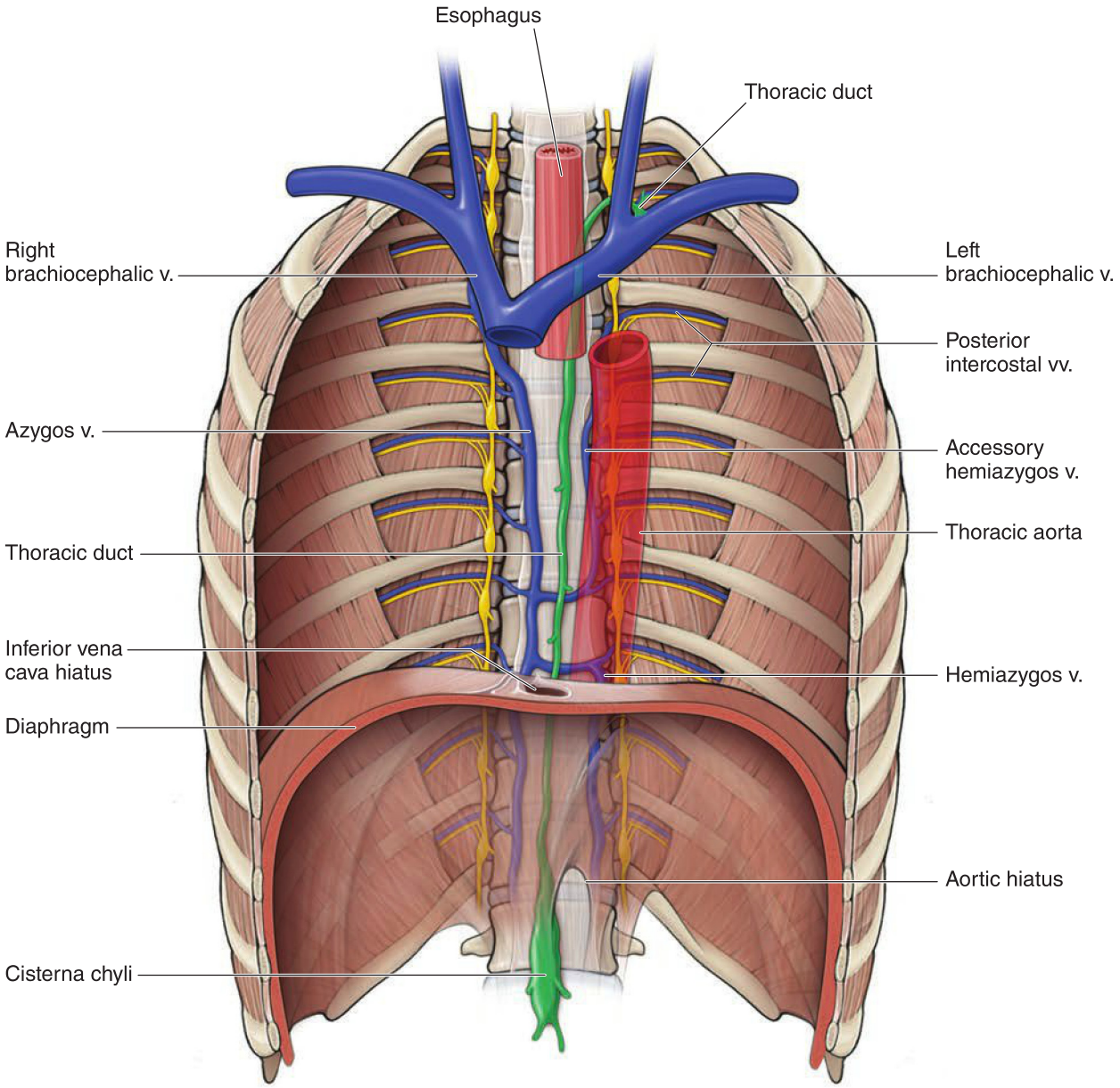

Figure 5-3: Azygos system of veins, thoracic duct, and thoracic aorta.

POSTERIOR AND SUPERIOR MEDIASTINUM

BIG PICTURE

The esophagus is a muscular tube that is continuous with the pharynx in the neck and enters the thorax posterior to the trachea. The superior mediastinum is located between the transverse thoracic plane at the T4 vertebral level and the T2 vertebral level. The posterior and superior mediastinum serve as a thoroughfare for vessels, nerves, and lymphatics that pass between the neck, upper limbs and thorax.

ESOPHAGUS AND VAGUS NERVE

- **Topography.** The esophagus descends against the thoracic vertebrae, deep to the pericardium, and has its anterior surface pressed by the left atrium (Figure 5-4). At the T10 vertebral level, the esophagus exits the thorax through the esophageal hiatus of the diaphragm. Note that the esophageal hiatus is formed by the right crus of the diaphragm, splitting to wrap around the esophagus to become the so-called esophageal sphincter.
- **Vascular supply.** The esophagus receives its arterial supply via esophageal, left gastric, and inferior phrenic arteries. Blood drains from the distal end of the esophagus (near the diaphragm) through the (1) azygos system of veins and (2) left gastric vein, which ultimately drains into the hepatic portal vein (this knowledge will assist in understanding the complications of portal hypertension; see Chapter 10).
- **Innervation.** The vagus nerves supply parasympathetic innervation to the esophagus.
  - **Right vagus nerve.** Descends into the thoracic cavity anterior to the right subclavian artery and gives rise to the following:
    - **Right recurrent laryngeal nerve.** Hooks around the right subclavian artery and ascends back into the neck en route to intrinsic laryngeal muscles.
    - **Esophageal branches.** The right vagus nerve continues to the deep surface of the esophagus, becoming the **posterior vagal trunk**.
    - **Cardiac and pulmonary plexuses.** The right vagus nerve contributes to the cardiac plexus, which slows heart rate, and pulmonary plexus, which causes bronchoconstriction.
  - **Left vagus nerve.** Enters the thorax between the left common carotid and subclavian arteries and gives rise to the following:
    - **Left recurrent laryngeal nerve.** Hooks around the aortic arch by the ligamentum arteriosum and ascends back into the neck en route to the intrinsic laryngeal muscles.
    - **Esophageal branches.** The left vagus nerve continues to the anterior surface of the esophagus, becoming the **anterior vagal trunk**.
    - **Cardiac and pulmonary plexuses.** The left vagus nerve contributes to the cardiac plexus, which slows heart rate, and pulmonary plexus, which causes bronchoconstriction.

The **anterior and posterior vagal trunks** exchange fibers, creating an **esophageal plexus of nerves**. The vagus nerve carries visceral sensory neurons whose sensory cell bodies are located in the inferior vagal ganglion. The visceral afferents from the vagus nerves transmit information to the brain about normal physiologic processes and visceral reflexes. They do not relay pain information.

TRACHEA AND BRONCHIAL TREE

The trachea begins at the cricoid cartilage, at the C6 vertebral level, and has 18 to 20 incomplete hyaline cartilaginous rings, which are open posteriorly. The cartilaginous rings prevent the trachea from collapsing during exhaling. The trachea is anterior to the esophagus and bifurcates into the right and left primary (principal or main-stem) bronchi at the level of the sternal angle. The point of bifurcation, called the **carina**, is marked in the inside of the airway by a cartilaginous wedge that projects upward into the airway lumen.

- **Right primary bronchus.** Courses more vertically and is shorter and wider than the left primary bronchus; gives rise to the **superior, middle, and inferior secondary (lobar) bronchi**.
- **Left primary bronchus.** Courses more obliquely and is longer and thinner than the right primary bronchus; gives rise to the **superior and inferior secondary (lobar) bronchi**.
- **Secondary (lobar) bronchi.** Each secondary bronchus further divides into tertiary (segmental) bronchi and then continue to branch. The smallest bronchi give rise to bronchioles, which terminate in alveolar sacs, where the exchange of gases takes place.

▼ Because of its wider, more vertical orientation, the right bronchus usually has inhaled foreign objects fall into it from the trachea (e.g., peanut). ▼

PULMONARY ARTERIES

The **pulmonary arteries**:

- Arise from the **pulmonary trunk** at the level of the sternal angle.
- Course inferior to the aortic arch and azygos vein.
- Parallel the bronchial tree throughout the lungs.

The relationship of the pulmonary arteries to the bronchi at the root of the lungs can be remembered by the mnemonic **RALS**: *The **R**ight pulmonary artery is **A**nterior to the right primary bronchus, and the **L**eft pulmonary artery is **S**uperior to the left primary bronchus.*

AORTIC ARCH AND ASSOCIATED BRANCHES

The aortic arch arises at the T4 vertebral level, ascends into the superior mediastinum over the pulmonary vessels and left primary bronchus, and descends to the T4 vertebral level where it continues as the thoracic aorta (Figure 5-4).

- **Ligamentum/ductus arteriosus.** A fibrous connective tissue cord, called the ligamentum arteriosus, connects the deep surface of the aortic arch to bifurcation of the pulmonary trunk in the adult. The ligamentum arteriosus is the remnant of the ductus arteriosus, which, during fetal development, shunted blood from the pulmonary trunk to the aorta to bypass the lungs.

The aortic arch has the following three branches, from right to left:

- **Brachiocephalic trunk/artery.** Courses to the right where it bifurcates into the **right common carotid** and **right subclavian arteries**, supplying the right side of the head and neck and upper limb, respectively.
- **Left common carotid.** Supplies the left side of the head and neck.
- **Left subclavian arteries.** Supplies the left upper limb.

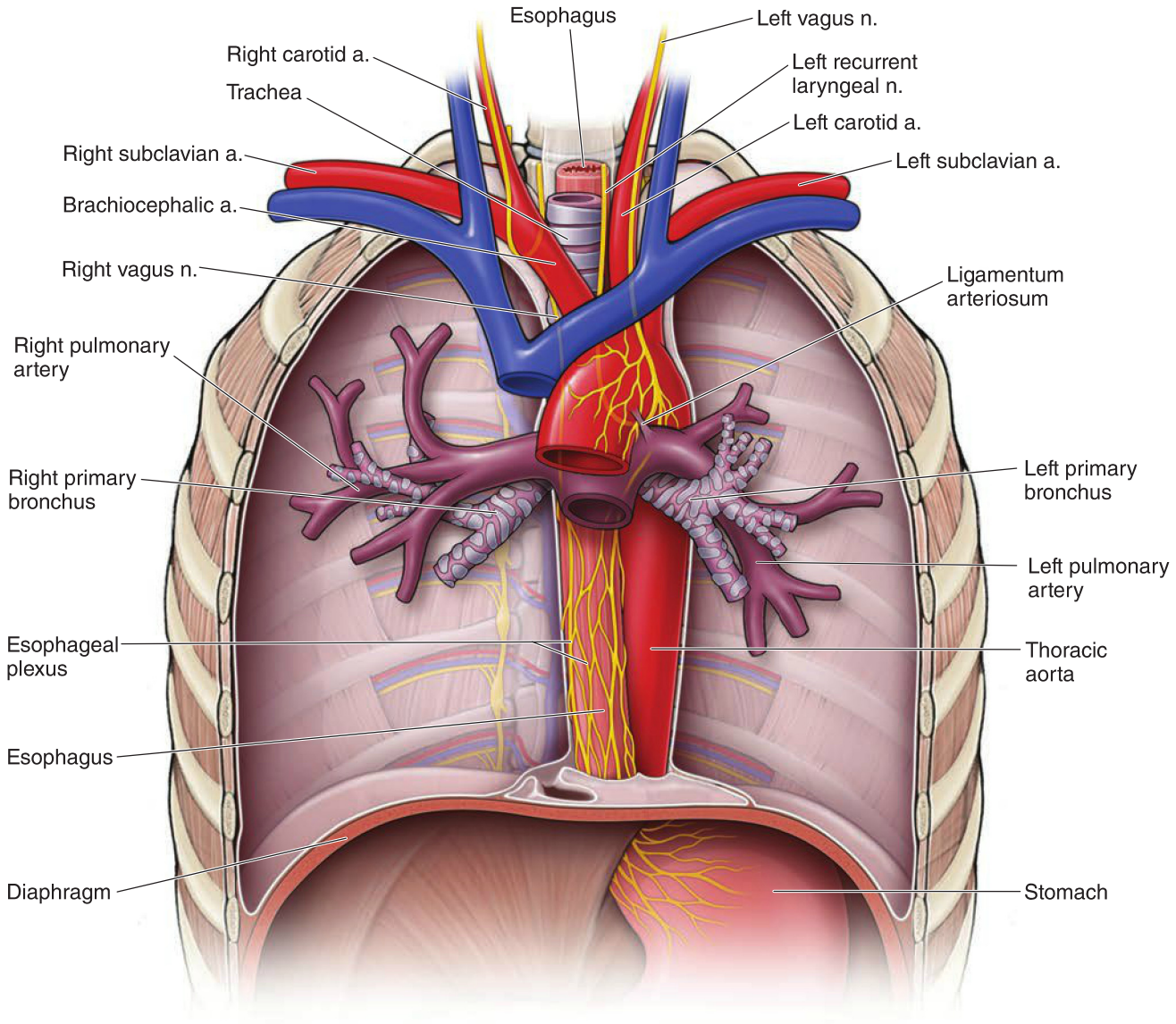

Figure 5-4: Structures of the superior and posterior mediastinum.

STUDY QUESTIONS

Directions: Each of the numbered items or incomplete statements is followed by lettered options. Select the **one** lettered option that is **best** in each case.

1. During the autopsy of a trauma victim, the pathologist noted a tear at the junction of the superior vena cava and the right atrium. Which of the following structures would most likely have been damaged by the tear?

A. Atrioventricular (AV) bundle
B. AV node
C. Left bundle branch
D. Right bundle branch
E. Sinuatrial (SA) node

2. A 62-year-old man is brought to the emergency department after experiencing a myocardial infarction. His heart rate is 40 beats/min. Further examination reveals an occlusion of the patient's right coronary artery. Which of the following structures is most likely affected by this blockage?

A. AV node
B. Bundle of His
C. Mitral valve
D. Tricuspid valve

3. A contrast study of the pulmonary vessels will most likely reveal several pulmonary veins entering the left atrium. How many pulmonary veins entering the left atrium will most likely be seen?

A. Two
B. Three
C. Four
D. Five
E. Six

4. Which of the following structures typically arises from the musculophrenic arteries?

A. Anterior intercostal arteries for the intercostal spaces 7 to 9
B. Inferior phrenic artery
C. Lumbar arteries
D. Posterior intercostal arteries for intercostal spaces 3 to 11
E. Subcostal artery

5. The opening of the coronary sinus is located in which of the following structures?

A. Left atrium
B. Left ventricle
C. Right atrium
D. Right ventricle

6. Which of the following vessels is responsible for transporting oxygenated blood from the lungs to the heart?

A. Ascending aorta
B. Cardiac veins
C. Left coronary artery
D. Pulmonary arteries
E. Pulmonary veins

7. The azygos vein is located in which division of the mediastinum?

A. Anterior mediastinum
B. Middle mediastinum
C. Posterior mediastinum
D. Superior mediastinum

8. Ebstein's anomaly is a congenital heart defect where one or two of the tricuspid valve leaflets forms abnormally low because of misalignment. The heart becomes less efficient. What type of murmur would most likely be associated with this type of anomaly?

A. Diastolic murmur with regurgitation
B. Diastolic murmur with stenosis
C. Systolic murmur with regurgitation
D. Systolic murmur with stenosis

9. After surgery, a 62-year-old patient began experiencing complications. After examination, the physician determined that an important structure located immediately behind the ligamentum arteriosum was damaged during surgery. Which of the following symptoms was the patient most likely experiencing?

A. Partially paralyzed diaphragm
B. Heart arrhythmia
C. Hoarseness of voice
D. Jaundice
E. Loss of cutaneous sensation along T4 dermatome

10. An intercostal artery is identified in a 44-year-old man who is undergoing thoracic surgery. This artery would most likely be located between which two structures?

A. External and internal intercostal muscles
B. Endothoracic fascia and parietal pleura
C. Innermost intercostal muscles and endothoracic fascia
D. Internal and innermost intercostal muscles
E. Skin and external intercostal muscles

11. The ganglia associated with the sympathetic trunk typically contain which of the following cell bodies?

A. Postganglionic parasympathetic cell bodies
B. Postganglionic sympathetic cell bodies
C. Preganglionic parasympathetic cell bodies
D. Preganglionic sympathetic cell bodies

12. The greater, lesser, and least splanchnic nerves are examples of which of the following nerves?

A. Cervical splanchnic nerves
B. Lumbar splanchnic nerves
C. Pelvic splanchnic nerves
D. Sacral splanchnic nerves
E. Thoracic splanchnic nerves

13. Which of the following structures, along with the esophagus, travels through the esophageal hiatus from the thoracic cavity into the abdominal cavity?

A. Abdominal aorta
B. Inferior vena cava
C. Lesser splanchnic nerves
D. Paravertebral ganglia
E. Prevertebral ganglia
F. Vagus nerves

14. In a healthy person, blood from the pulmonary trunk will flow next into which of the following structures?

A. Aortic arch
B. Left atrium
C. Left ventricle
D. Pulmonary arteries
E. Pulmonary veins
F. Right atrium
G. Right ventricle

15. A Doppler echocardiogram evaluates blood flow, speed, and direction within the heart and also screens the four valves for any leakage. If a patient's heart function during diastole is being studied, which valves would the Doppler detect to be open?

A. Mitral and aortic valves
B. Mitral and pulmonary valves
C. Mitral and tricuspid valves
D. Pulmonary and aortic valves
E. Pulmonary and mitral valves
F. Pulmonary and tricuspid valves

16. During thoracocentesis, the needle is pushed in the intercostal space superior to the rib to prevent damage to the intercostal nerve, artery, and vein. Beginning with the external intercostal muscles and ending with the pleural space, which thoracic wall layers, from superficial to deep, does the needle penetrate?

A. Endothoracic fascia, internal intercostal muscles, costal parietal pleura, and pleural cavity
B. Internal intercostal muscles, innermost intercostal muscles, mediastinal parietal pleura, endothoracic fascia, and pleural cavity
C. Internal intercostal muscles, innermost intercostal muscles, costal parietal pleura, endothoracic fascia, and pleural cavity
D. Internal intercostal muscles, innermost intercostal muscles, endothoracic fascia, costal parietal pleura, and pleural cavity
E. Innermost intercostal muscles, internal intercostal muscles, endothoracic fascia, costal parietal pleura, and pleural cavity

17. A 19-year-old man is admitted to the emergency department after being stabbed in the chest with a pocketknife with a 5-cm-long blade. The stab wound was in the left intercostal space just lateral to the sternal body. Which part of the heart is most likely injured?

A. Left atrium
B. Left ventricle
C. Right atrium
D. Right ventricle

ANSWERS

1—E: The SA node, or pacemaker, lies within the right atrial wall, where the right atrium is joined by the superior vena cava.

2—A: A myocardial infarction in the inferior wall involving the right coronary artery may affect the AV node, resulting in bradycardia.

3—C: At the wall of the left atrium, four pulmonary veins deliver oxygenated blood into the left atrium.

4—A: The musculophrenic artery supplies the anterior intercostal arteries for intercostal spaces 7 to 9.

5—C: The coronary sinus collects venous blood from the coronary circulation and returns the blood to the right atrium. Therefore, the coronary sinus opens into the right atrium.

6—E: Oxygenated blood is transported from the lungs to the left atrium via the pulmonary veins.

7—C: The azygos system of veins, along with the thoracic duct, thoracic aorta, esophagus, vagus nerves, sympathetic trunk, and the greater and least splanchnic nerves are located within the posterior mediastinum.

8—C: The function of the tricuspid valve is to ensure unidirectional flow of blood from the right atrium to the right ventricle. Therefore, when the right ventricle contracts (systole), blood flows into the pulmonary trunk and not back into the right atrium. If the tricuspid valve is malformed and does not function correctly (as in Ebstein's anomaly), blood will regurgitate back into the right atrium during systolic contraction of the right ventricle.

9—C: The left vagus nerve gives rise to the recurrent laryngeal nerve, located immediately behind the ligamentum arteriosum. The recurrent laryngeal nerve innervates laryngeal muscles that are associated with speaking. Therefore, if the recurrent laryngeal nerve is damaged, the patient will experience a raspy voice or hoarseness.

10—D: The intercostal arteries and veins course between the internal and innermost intercostal muscles.

11—B: Synapses occur with postganglionic sympathetic neurons within the paravertebral ganglia of the sympathetic trunk for sympathetics en route to blood vessels, sweat glands, and arrector pilae muscles in the associated dermatome. Preganglionic sympathetic cell bodies are located in the lateral horn gray matter of the T1–L2 spinal cord levels.

12—E: The greater, lesser, and least splanchnic nerves all arise from thoracic spinal nerves (T5–T9 form the greater splanchnic nerves; T10–T11 form the lesser splanchnic nerves; and T12 forms the least splanchnic nerves). The cervical sympathetic nerves course from the superior, middle, and inferior cervical ganglia and course to the pulmonary and aortic plexuses. The lumber and sacral splanchnics are located in the abdominal cavity and serve the abdominal viscera. The pelvic splanchnics originate from the S2–S4 ventral rami and transport preganglionic parasympathetic neurons.

13—F: In the thoracic cavity, the vagus nerves (CN X) form a plexus on the surface of the esophagus and then form the anterior and posterior vagal trunks. These vagal trunks course through the esophageal hiatus to enter the abdominal cavity.

14—D: Deoxygenated blood from the right ventricle is pumped into the pulmonary trunk, which bifurcates into the right and left pulmonary arteries before coursing to the lungs.

15—C: The segment of the cardiac cycle when the ventricles relax and the atria contract is known as diastole. When the atria contract, they pump blood through the AV valves (mitral and tricuspid) into the ventricles.

16—D: The layers of the lateral thoracic wall in the intercostal spaces that the needle would pass through during thoracocentesis are skin, superficial fascia, external intercostal muscle, internal intercostal muscle, innermost intercostal muscle, endothoracic fascia, parietal pleura, and pleural cavity.

17—D: The anterior surface of the heart is formed primarily by the right ventricle. Therefore, a stab wound such as the one that occurred in this patient would injure the right ventricle of the heart.

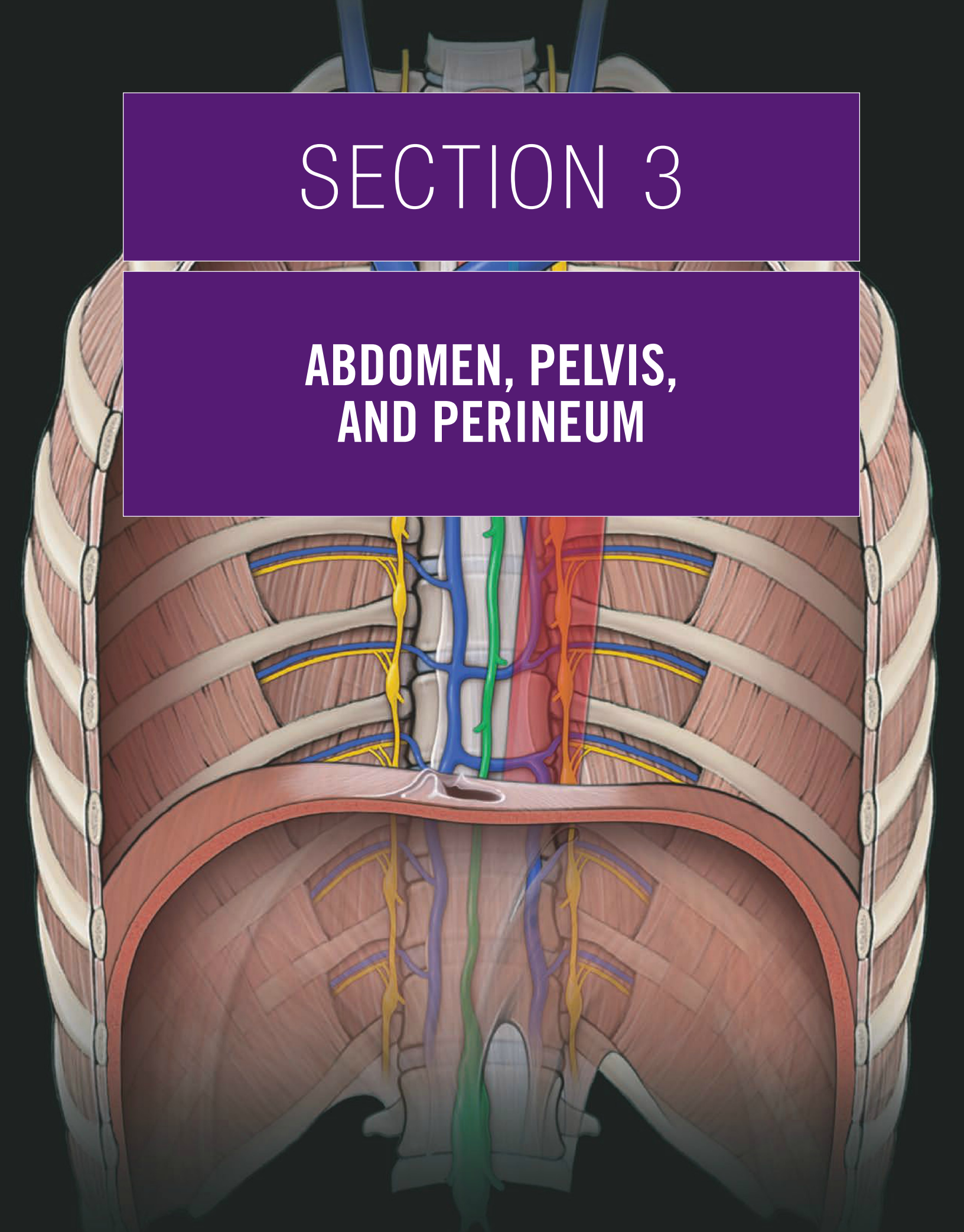

SECTION 3

ABDOMEN, PELVIS, AND PERINEUM

This page intentionally left blank

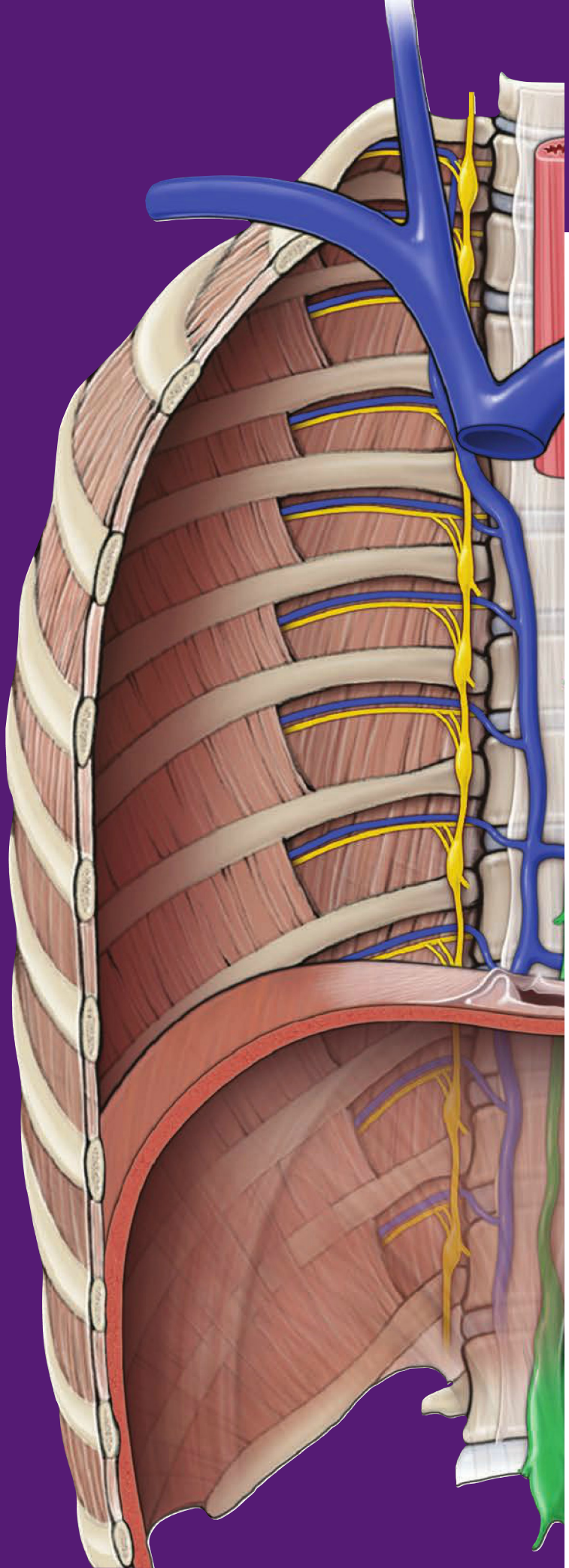

CHAPTER 6

OVERVIEW OF THE ABDOMEN, PELVIS, AND PERINEUM

Osteologic Overview 78
Gut Tube 80

OSTEOLOGIC OVERVIEW

BIG PICTURE

In the adult, the pelvis (os coxae) is formed by the fusion of three bones: ilium, ischium, and pubis (Figure 6-1A and B). The union of these three bones occurs at the acetabulum. The paired os coxae articulate posteriorly with the sacrum and anteriorly with the pubic symphysis.

PELVIC BONE

Each os coxa is formed by the fusion of three bones: **ilium, ischium, and pubis**. The following landmarks are associated within the fused os coxa (Figure 6-1A–C):

- **Acetabulum.** A cup-shaped socket into which the ball-shaped head of the femur articulates.
- **Obturator foramen.** A hole in the os coxa that is covered by a flat sheet of connective tissue called the **obturator membrane**. A small opening located at the top of the membrane provides a route through which the obturator nerve, artery, and vein course.
- **Greater sciatic notch.** Located between the posterior inferior iliac spine and the ischial spine. The sacrospinous ligament converts the notch into the **greater sciatic foramen**, where the piriformis muscle, sciatic nerve, and pudendal neurovascular structures course.
- **Lesser sciatic notch.** Located between the ischial spine and the ischial tuberosity. The sacrotuberous ligament converts the notch into the lesser sciatic foramen.
- **Pubic symphysis.** Fibrocartilage connecting the two pubic bones in the anterior midline of the pelvis.
- **Pelvic inlet.** The superior aperture of the pelvis. The pelvic inlet is oval shaped and bounded by the ala of the sacrum, arcuate line, pubic bone, and symphysis pubis. The pelvic inlet is traversed by structures in the abdominal and pelvic cavities.
- **Pelvic outlet.** The inferior aperture of the pelvis. The pelvic outlet is a diamond-shaped opening formed by the pubic symphysis and sacrotuberous ligaments. Terminal parts of the vagina and the urinary and gastrointestinal tracts traverse the pelvic outlet. The perineum is inferior to the pelvic outlet.

ILIUM The ilium has the following bony landmarks:

- **Iliac crest.** Thickened superior rim.
- **Iliac fossa.** Concave surface on the anteromedial surface.
- **Anterior superior iliac spine (ASIS).** Anterior prominence of the iliac crest. Serves as an attachment site for the sartorius and tensor fascia lata muscles.
- **Anterior inferior iliac spine (AIIS).** Serves as an attachment site for the rectus femoris muscle.
- **Posterior superior iliac spine.** Posterior prominence of the iliac crest.
- **Posterior inferior iliac spine.** Forms the posterior border of the ala of the sacrum.

ISCHIUM The ischium has the following bony landmarks:

- **Ischial tuberosity.** A large protuberance on the inferior aspect of the ischium for attachment of the hamstring muscles and for supporting the body when sitting.
- **Ischial spine.** A pointed projection that separates the greater and lesser sciatic notches.
- **Ischial ramus.** A bony projection that joins with the inferior pubic ramus to form the **ischiopubic ramus (conjoint ramus).**

PUBIS The pubis has the following bony landmarks:

- **Pubic tubercle.** A rounded projection on the superior ramus of the pubis.
- **Superior pubic ramus.** A bony projection that forms a bridge with the acetabulum. The crest on the superior aspect of the superior pubic ramus is the **pectineal line**, which serves as part of the border for the pelvic inlet and as an attachment site for muscles.
- **Inferior pubic ramus.** A bony projection that forms a bridge with the ischium; serves as an attachment site for lower limb muscles.

SEX DIFFERENCES IN THE PELVIS

Due to its importance in childbirth, the typical female pelvis differs from the typical male pelvis in the following features:

- **Pelvic inlet.** A typical female pelvic inlet is usually more circular-shaped compared to the typically heart-shaped male pelvic inlet.
- **Pelvic outlet.** A typical female pelvic outlet is wider and has shorter and straighter ischial spines compared to the typical male pelvis.
  - In addition, the ischial spines typically project less medially in females than in males.
- **Pubic arch.** The pubic arch is the angle between adjacent ischiopubic rami.
  - A typical female pubic arch is usually larger (80 degrees) than the male pubic arch (60 degrees).
  - The angle formed by the female pubic arch can be estimated by the angle between the thumb and the forefinger; in contrast, the male pubic arch is estimated by the angle between the index and the middle fingers (Figure 6-1C and D).

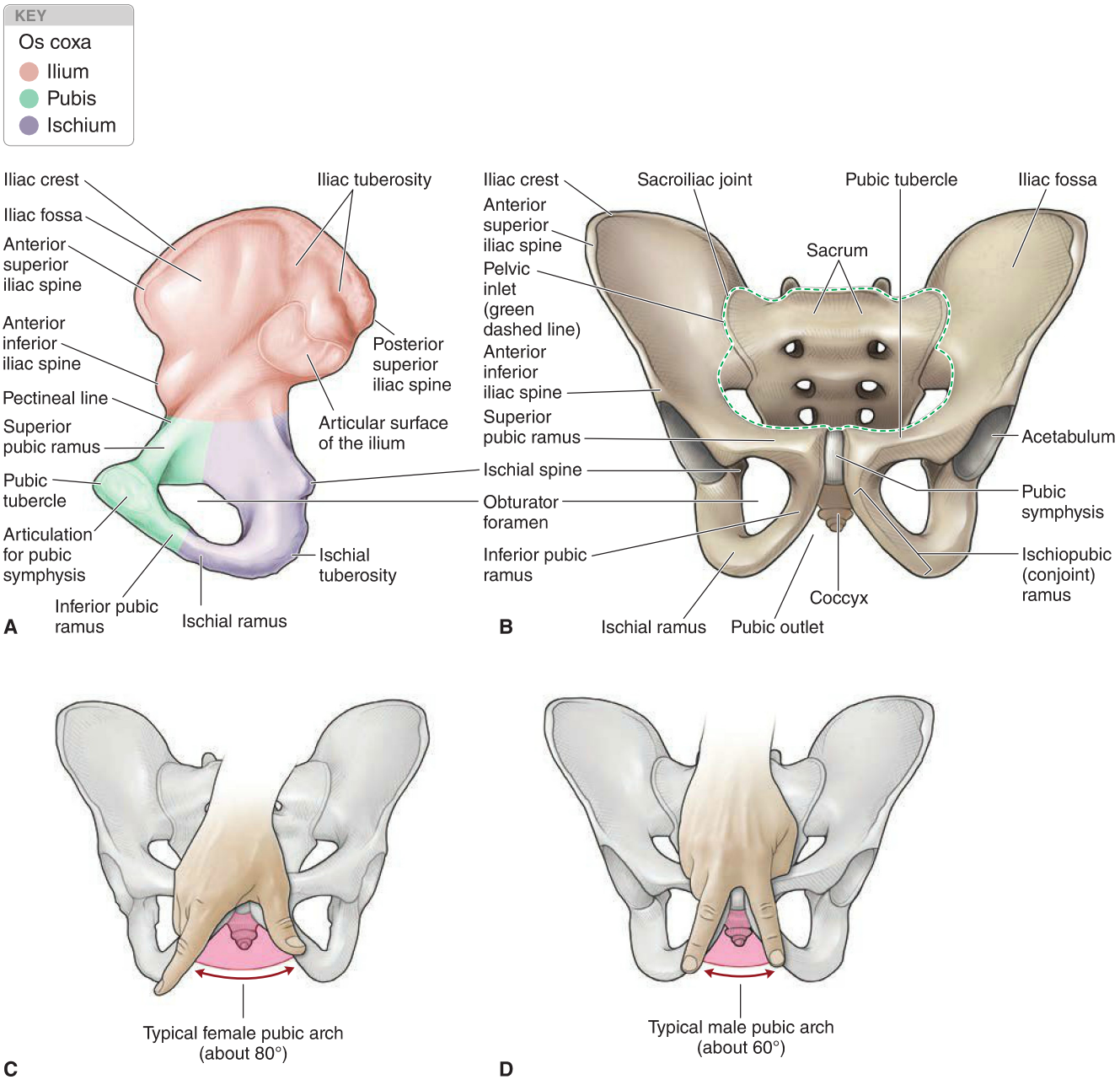

Figure 6-1: A. Medial view of the os coxa. **B**. Anterior view of the pelvis. **C**. Female pelvis. **D**. Male pelvis.

GUT TUBE

BIG PICTURE

The gut tube (aka gastrointestinal or GI tract) has the following primary functions: (1) transport food through the gut tube by way of peristalsis; (2) physical breakdown of food into smaller components by way of rhythmic contractions by gut musculature; (3) chemical breakdown of complex compounds by enzymes released into the gut tube; and (4) absorption of nutrients into the bloodstream and lacteals. The more proximal parts, such as the stomach and small intestines, are primarily involved in the breakdown of food (mechanical and chemical) and the absorption of nutrients. The more distal parts, such as the large intestines and rectum, are primarily responsible for water reabsorption and waste expulsion.

Additionally, the gut tube is categorized into regions based upon the arterial supply. As such, the gut tube is divided into the foregut, midgut, and hindgut regions based upon arterial supply by the celiac trunk, superior mesenteric artery, and inferior mesenteric artery, respectively. Either method of classifying the different regions of the gut tube is appropriate in medicine.

ORGANS OF THE GUT TUBE

The gut tube consists of the following organs (Figure 6-2A):

- **Stomach.** The expanded part of the gut tube between the esophagus and duodenum.
- **Small intestine.** The small intestine functions mainly in the chemical breakdown of food and its subsequent absorption into the blood stream. The veins of the small intestine transport the absorbed nutrients to the liver for processing and ultimately to all other parts of the body. The small intestine consists of three parts: duodenum, jejunum, and ileum.
- **Large intestine (colon).** Receives its name because of its large luminal diameter. The colon absorbs water and vitamins and houses numerous bacteria. The blood supply of the colon overlaps with that of the midgut and hindgut.

SUBDIVISION OF THE GUT TUBE

The gut tube is divided into the following three regions based on arterial supply (Figure 6-2B):

- **Foregut.** Supplied primarily by the celiac trunk. This region of the gut tube extends from the distal end of the esophagus to the proximal half (parts 1 and 2) of the duodenum.
- **Midgut.** Supplied primarily by the superior mesenteric artery. This region of the gut tube extends from the distal half of the duodenum (parts 3 and 4) to the splenic flexure of the colon.
- **Hindgut.** Supplied primarily by the inferior mesenteric artery. This region of the gut tube extends from the splenic flexure of the colon to the rectum.

ABDOMINAL VENOUS DRAINAGE

Blood in the abdomen drains back to the heart via two routes: caval drainage and portal drainage (Figure 6-2C).

CAVAL DRAINAGE Venous blood that is returned to the heart from the anterior and posterior abdominal walls and the retroperitoneal organs is via the inferior and superior vena cava.

- **Inferior epigastric veins.** Return blood to the heart via the inferior vena cava.
- **Intercostal veins.** Return blood to the heart via the superior vena cava.
- **Lumbar veins.** Return blood to the heart directly via the inferior vena cava or indirectly via the superior vena cava (lumbar veins may drain into the ascending lumbar veins to the azygos system of veins to the superior vena cava).

PORTAL DRAINAGE Venous blood from the gut tube and its derivatives returns to the heart via the **hepatic portal vein** to the liver. In other words, venous blood from the gut tube reaches the inferior vena cava after coursing through the liver.

- **Foregut.** Branches from the gastric and splenic veins to the portal vein.
- **Midgut.** Branches from the superior mesenteric vein to the portal vein.
- **Hindgut.** Branches from the inferior mesenteric vein to the portal vein.

ABDOMINAL LYMPHATICS

Lymphatics generally follow neurovascular bundles throughout the body. Clusters of lymph nodes, which are important in monitoring the immune system, are found along the course of the lymphatics. The central lymph nodes in the abdomen are named according to their associated artery.

- For example, the lymph nodes clustered at the origin of the celiac trunk are called celiac lymph nodes.

INNERVATION OF THE GUT TUBE

The regions of the gut tube receive the following autonomic innervation:

- **Foregut.** Sympathetics from the greater splanchnic nerves (T5–T9). Parasympathetics from the vagus nerves.
- **Midgut.** Sympathetics from the lesser splanchnic nerves (T10–T11). Parasympathetics from the vagus nerves.
- **Hindgut.** Sympathetics from the lumbar and sacral splanchnic nerves. Parasympathetics from the pelvic splanchnics (S2–S4 spinal cord levels).

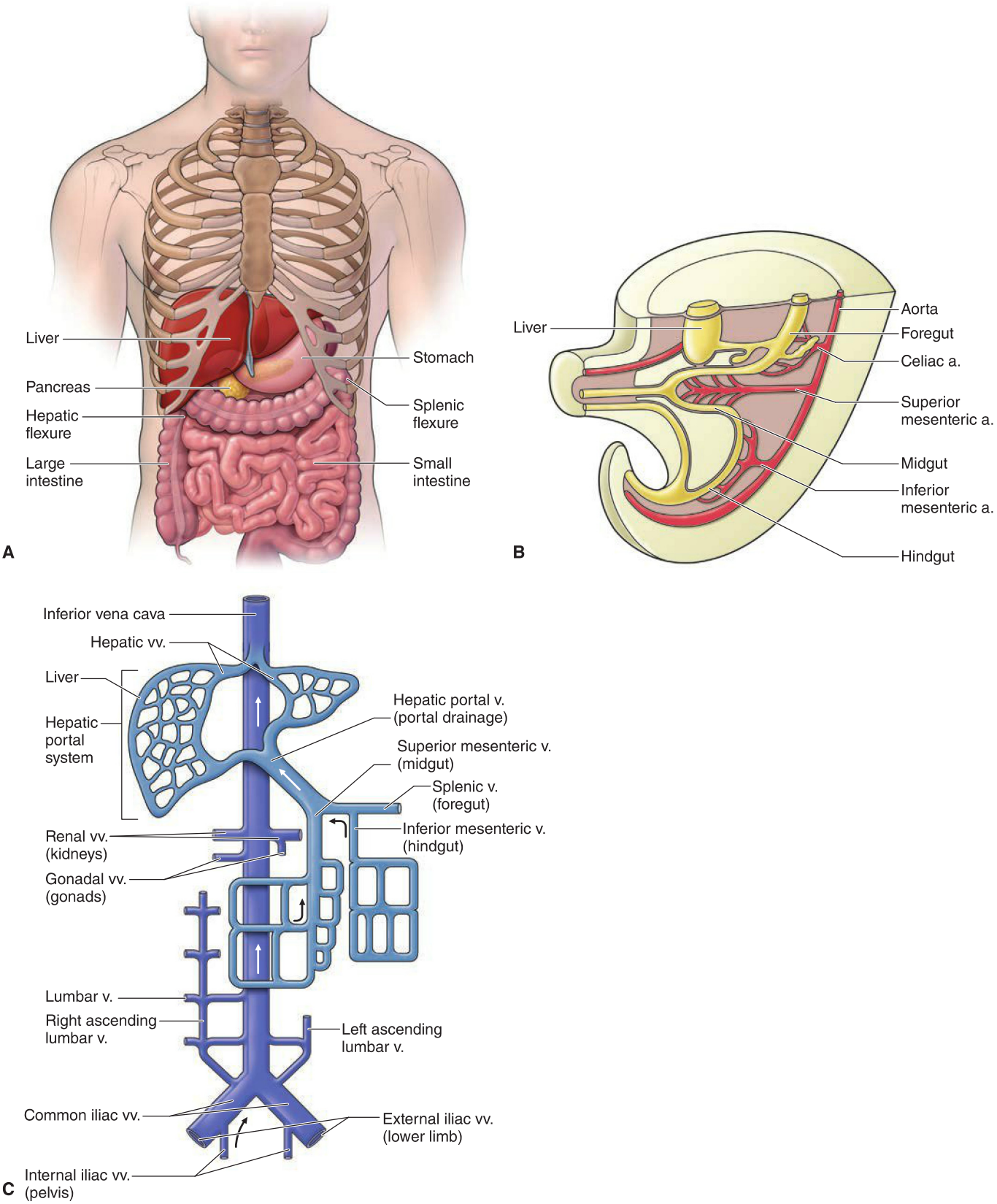

Figure 6-2: A. Gut tube in situ. **B**. Embryonic development of the gut tube, demonstrating the foregut, midgut, and hindgut. **C**. Caval (purple) and portal venous (turquoise) drainage of the abdomen, pelvis, and perineum.

This page intentionally left blank

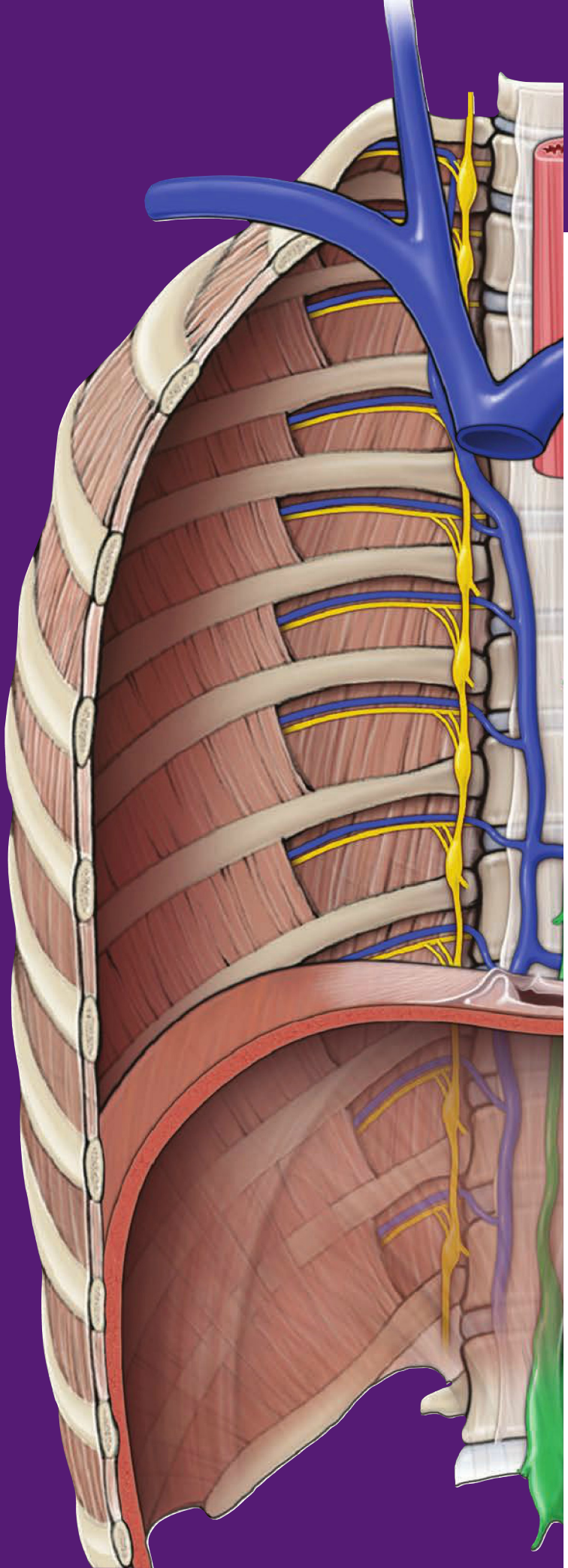

CHAPTER 7

ANTERIOR ABDOMINAL WALL

Partitioning of the Abdominal Region 84
Superficial Layers of the Anterior Abdominal Wall 84
Anterior Abdominal Wall Muscles. 86
Vascular Supply and Innervation of the Anterior Abdominal Wall 88
Inguinal Canal 90
Scrotum and Spermatic Cord 92

PARTITIONING OF THE ABDOMINAL REGION

BIG PICTURE

The abdomen typically is described topographically using two methods. The first method partitions the abdomen into four quadrants. The second method partitions the abdomen into nine regions.

FOUR QUADRANT PARTITIONS

To divide the abdomen into four quadrants, a transverse plane and a sagittal plane intersect through the umbilicus at the L3–L4 vertebral level (Figure 7-1A). The two intersecting planes divide the abdomen into **right and left upper and lower quadrants**. The four-quadrant system is straightforward when used to describe anatomic location. For example, the appendix is located in the lower right quadrant of the abdomen.

NINE REGIONAL PARTITIONS

For more precise description, the abdomen is partitioned into nine regions created by two vertical planes, one each through the middle of each clavicle, and two horizontal planes, one each through the costal margin and the transtubercular plane (Figure 7-1B). The nine regions are:

- **Right hypogastric.** Region under the right costal margin.
- **Right lumbar.** Region on the right side of the abdomen.
- **Right iliac.** Region over the right iliac region.
- **Epigastric.** Upper central region of the abdomen.
- **Umbilical.** Region overlying the umbillicus.
- **Hypogastric.** Lower central region of the abdomen (suprapubic area).
- **Left hypogastric.** Region under the left costal margin.
- **Left lumbar.** Region on the left side of the abdomen.
- **Left iliac.** Region over the left iliac region.

ABDOMINAL SURFACE LANDMARKS

The following structures are helpful anatomic surface landmarks on the anterior abdominal wall (Figure 7-1C):

- **Xiphoid process.** The xiphoid process is the inferior projection of the sternum.
- **Umbilicus.** The umbilicus lies at the L3–L4 vertebral level, within the T10 dermatome. A helpful mnemonic is "T10 for belly but-ten."
- **Inguinal ligament.** Formed by the inferior border of the external oblique muscle and its aponeurosis, where the aponeurosis attaches from the anterior superior iliac spine to the pubic tubercle. The inguinal ligament is revealed superficially as a crease on the inferior extent of the anterior abdominal wall. The inguinal ligament is the location of the dermatome level of L1.

McBurney's point is the name given to a point on the lower right quadrant of the abdomen, approximately one-third the distance along an imaginary line from the anterior superior iliac spine to the umbilicus. McBurney's point roughly corresponds to the skin overlying the most common junction of the appendix to the cecum.

SUPERFICIAL LAYERS OF THE ANTERIOR ABDOMINAL WALL

BIG PICTURE

Multiple layers of fascia and muscle form the anterior abdominal wall (Figure 7-1D). The layers, from superficial to deep, are skin, two layers of superficial fascia, three layers of muscles and their aponeuroses, transversalis fascia, extraperitoneal fat, and the parietal peritoneum.

SKIN

The skin consists of the epidermis and dermis, and receives its vascular supply and innervation via intercostal and lumbar vessels and nerves, respectively.

SUPERFICIAL ABDOMINAL FASCIA

The superficial fascia of the anterior abdominal wall consists of two layers:

- **Camper's fascia.** The external layer composed of adipose tissue and drained by the **superficial epigastric veins**. These cutaneous veins drain into the **femoral** and **paraumbilical veins**. Camper's fascia is absent in the perineum.
- **Scarpa's fascia.** The internal layer of dense collagenous connective tissue. Scarpa's fascia continues into the perineum, but the nomenclature is changed relative to the region in which this fascia is located (i.e., Scarpa's fascia becomes **Colles' fascia** when surrounding the roots of the penis and clitoris, the **superficial penile (or clitoral) fascia** when it surrounds the shaft of the penis (or clitoris), or **dartos fascia** in the scrotum).

A patient diagnosed with **cirrhosis** (fibrotic scarring) of the liver may present with **portal hypertension**. Blood pressure within the portal vein increases because of the inability of blood to filter through the diseased (cirrhotic) liver. In an attempt to return blood to the heart, small collateral (**paraumbilical veins**) veins expand at and around the **obliterated umbilical vein** to bypass the hepatic portal system. These paraumbilical veins form tributaries with the veins of the anterior abdominal wall, forming a **portal–caval anastomosis**, and drain into the femoral or axillary veins. In patients with chronic cirrhosis, the paraumbilical veins on the anterior abdominal wall may swell and distend as they radiate from the umbilicus and are termed **caput medusae** because the veins appear similar to the head of the Medusa from Greek mythology.

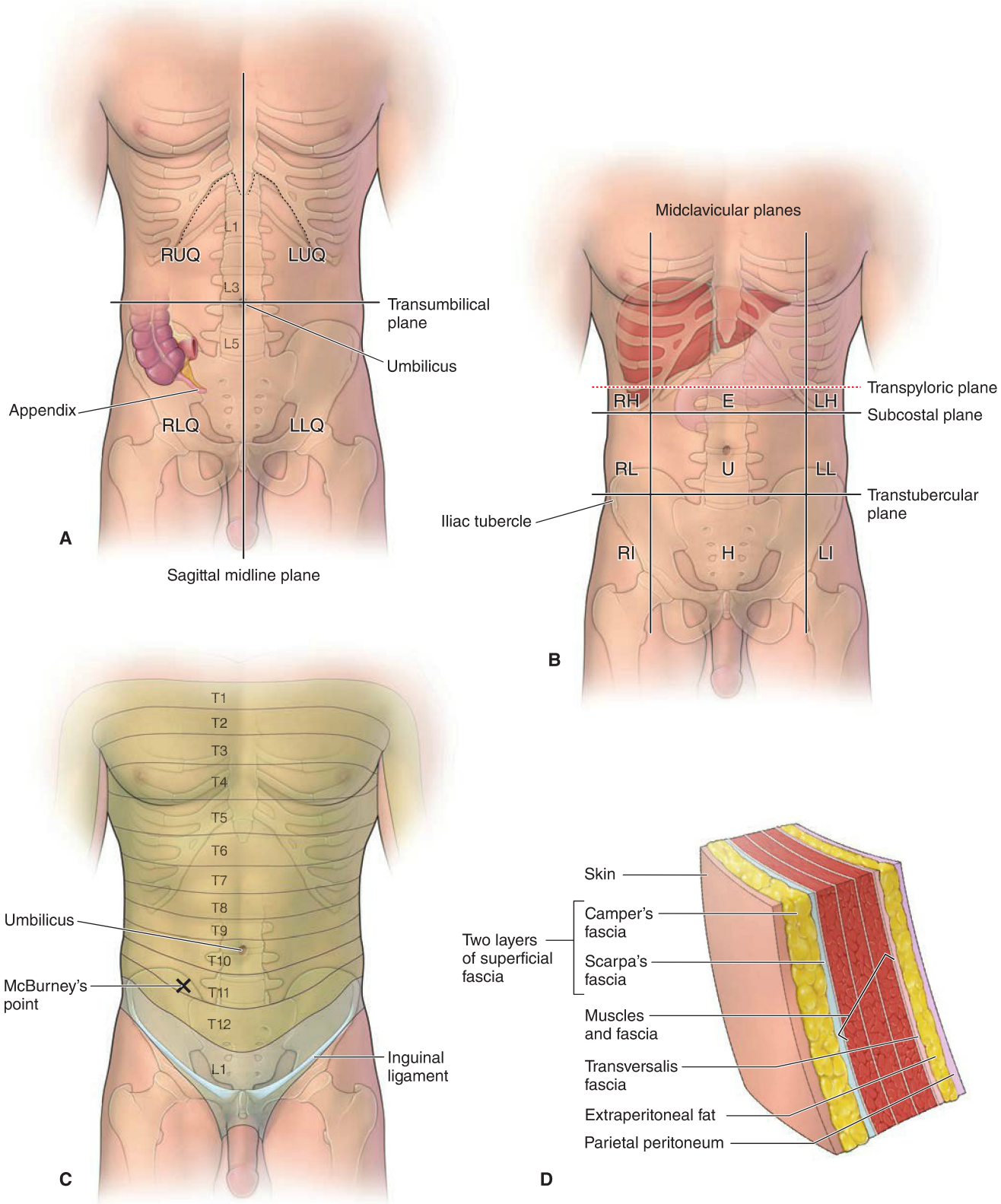

Figure 7-1: A. Quadrant partitioning: right upper quadrant (RUQ); left upper quadrant (LUQ); right lower quadrant (RLQ); and left lower quadrant (LLQ). **B**. Regional partitioning: right hypochondriac (RH); right lumbar (RL); right iliac (RI); epigastrium (E); umbilical (U); hypogastrium (H); left hypochondriac (LH); left lumbar (LL); and left iliac (LI). **C**. Surface anatomy and dermatome levels. **D**. Fascial layers of the anterior abdominal wall.

ANTERIOR ABDOMINAL WALL MUSCLES

BIG PICTURE

Five bilaterally paired anterior abdominal wall muscles are deep to the superficial fascia. The external oblique, internal oblique, and transverse abdominis muscles, with their associated aponeuroses, course anterolaterally, whereas the rectus abdominis and tiny pyramidalis muscles course vertically in the anterior midline (Figure 7-2A). Collectively, these muscles compress the abdominal contents, protect vital organs, and flex and rotate the vertebral column. Each muscle receives segmental motor innervation from the lower intercostal and L1 spinal nerves.

EXTERNAL OBLIQUE MUSCLE

The external oblique muscle is the most superficial of the anterior muscles and attaches to the outer surfaces of the lower ribs and iliac crest. The external oblique muscle continues anteriorly as the **external oblique aponeurosis**, which courses anteriorly to the **rectus abdominis muscle** and inserts into the **linea alba**. The inferior border of the external oblique aponeurosis, between the anterior superior iliac spine and the pubic tubercle, is called the **inguinal ligament**.

INTERNAL OBLIQUE MUSCLE

The internal oblique muscle is the intermediate muscle of the anterior abdominal muscles. This muscle attaches to the thoracolumbar fascia, iliac crest, inguinal ligament, and lower ribs. The internal oblique muscle continues anteriorly as the **internal oblique aponeurosis**, which splits around the rectus abdominis muscle to insert into the linea alba, with some inferior attachments to the pubic crest and pectineal line.

TRANSVERSE ABDOMINIS MUSCLE

The transverse abdominis muscle is the deepest of the anterior abdominal muscles. This muscle attaches to the thoracolumbar fascia, iliac crest, inguinal ligament, and the costal cartilages of the lower ribs. The transverse abdominis muscle continues anteriorly as the **transverse abdominis aponeurosis**, which courses deep to the rectus abdominis muscle and inserts into the linea alba, the pubic crest, and the pectineal line.

- Intercostal and lumbar nerves, arteries, and veins course along the anterolateral abdominal wall between the internal oblique and transverse abdominis muscles.

RECTUS ABDOMINIS MUSCLE

The rectus abdominis muscle is a vertical strap muscle that attaches to the pubic bone and pubic symphysis inferiorly and xiphoid process and lower costal cartilages superiorly (Figure 7-2B and C).

- **Rectus sheath.** Formed by the external oblique, internal oblique, and transverse abdominis aponeuroses that envelop the rectus abdominis muscle in a fascial sleeve. The rectus sheath completely encloses the superior three-fourths of the rectus abdominis muscle but only covers the anterior surface of the inferior one-fourth of the muscle.
- **Linea alba.** A vertical midline of fascia that separates the paired rectus abdominis muscles and is formed by the fusion of the three pairs of aponeuroses of the anterior abdominal muscles.
- **Arcuate line.** A horizontal line between the umbilicus and pubic symphysis that delineates the lower limit of the posterior layer of the rectus sheath.
  - The point where the aponeuroses of the external oblique, internal oblique, and transverse abdominis muscles move anterior to the rectus muscle for the inferior one-fourth of the rectus sheath.
  - In other words, below the arcuate line there is no posterior wall of the rectus sheath and the rectus abdominis muscle is in direct contact with the transversalis fascia.
  - Point where the inferior epigastric vessels enter the rectus sheath.

PYRAMIDALIS MUSCLE

The pyramidalis muscle is a small, triangle-shaped muscle, anterior to the rectus abdominis muscle, that attaches to the pubic bone and linea alba. The pyramidalis muscle tenses the linea alba.

The **Valsalva maneuver** is performed by forcibly exhaling against a closed airway (closed vocal folds). When the maneuver is executed, the contraction of abdominal wall muscles increases intra-abdominal pressure. Increased intra-abdominal pressure assists with vomiting, urinating, defecating, and vaginal birth, and, when the vocal folds are open, with exhaling.

DEEP FASCIAL LAYERS

In addition to the superficial layers of the abdominal fascia, three additional layers of abdominal fascia are located deep to the anterior abdominal muscle layers (Figure 7-2B and C).

- **Transversalis fascia.** A thin, aponeurotic membrane deep to the transverse abdominis muscle.
- **Extraperitoneal fat.** A thin layer of connective tissue and fat lining the abdominal wall between the transversalis fascia and the parietal peritoneum. The extraperitoneal fat is more abundant in the posterior abdominal wall, especially around the kidneys (retroperitoneal space) and in the pelvic floor (infraperitoneal space).
- **Parietal peritoneum.** Parietal peritoneum is a **serous membrane** lining the internal surface of the abdominal wall. The parietal peritoneum forms the mesentery that suspends the abdominal viscera and is continuous with the **visceral peritoneum**. The parietal peritoneum is innervated segmentally by the ventral rami of the spinal (somatic) nerves that course in the abdominal body wall.

A **Caesarean section ("C-section")** is a surgical procedure for which incisions are made through a pregnant woman's abdomen to access the uterus for delivery of the infant. The most common incision location for a C-section is the lower uterine section (known as the "bikini-line incision"), where a transverse cut is made superior to the pubis and bladder, through all layers of the anterior abdominal wall. From superficial to deep, the layers cut through during a C-section are the skin, Camper's fascia, Scarpa's fascia, rectus sheath, pyramidalis muscle, rectus abdominis muscle, transversalis fascia, extraperitoneal fascia, and, finally, the parietal peritoneum. An alternative location is a midline incision through the linea alba, allowing a larger opening for delivery of the infant.

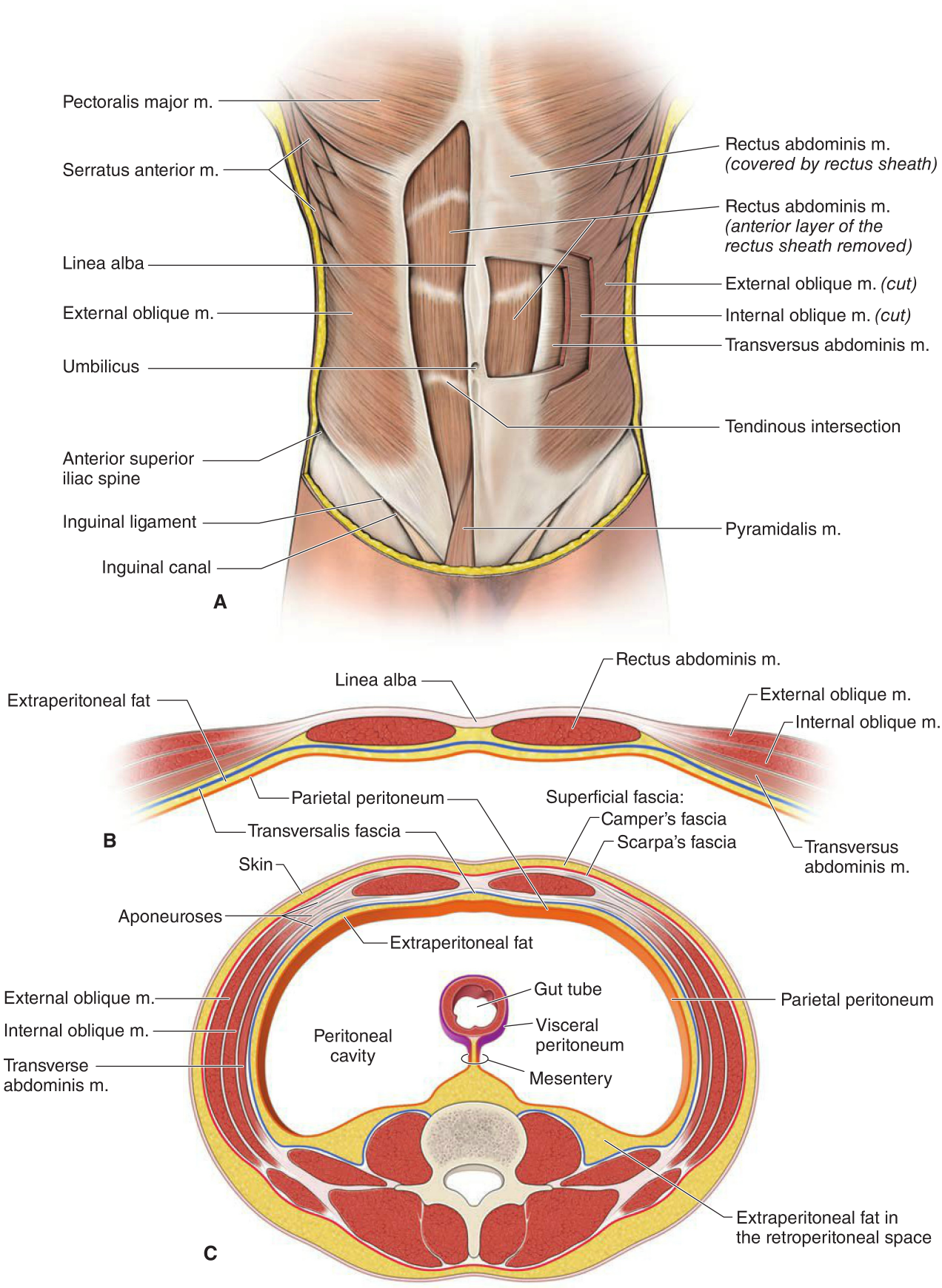

Figure 7-2: A. Step dissection of the anterior abdominal wall muscles. **B**. Horizontal section of the rectus sheath inferior to the arcuate line. **C**. Fascial and muscular layers of the abdomen in horizontal section superior to the arcuate line.

VASCULAR SUPPLY AND INNERVATION OF THE ANTERIOR ABDOMINAL WALL

BIG PICTURE

The neurovascular supply to the body wall courses between the second and third muscle layers (internal oblique and transverse abdominis muscles). Intercostal, subcostal, lumbar, and epigastric arteries supply the skin of the anterolateral abdominal wall (Figure 7-3).

INTERCOSTAL AND LUMBAR ARTERIES

The inferior posterior intercostal arteries and the lumbar arteries from the descending aorta supply the lateral part of the anterior abdominal wall. These vessels course between the internal oblique and the transverse abdominis muscles and may anastomose with the inferior and superior epigastric arteries.

SUPERIOR EPIGASTRIC ARTERY

The superior epigastric artery arises from the internal thoracic artery, enters the rectus sheath, and descends on the deep surface of the rectus abdominis muscle. The superior epigastric artery anastomoses with the inferior epigastric artery within the rectus abdominis muscle.

INFERIOR EPIGASTRIC ARTERY

The inferior epigastric artery arises from the external iliac artery above the inguinal ligament, enters the rectus sheath at the arcuate line, and ascends between the rectus abdominis muscle and the posterior layer of the rectus sheath. The inferior epigastric artery anastomoses with the superior epigastric artery, providing collateral circulation between the external iliac and subclavian arteries.

INNERVATION OF THE ANTERIOR ABDOMINAL WALL

The nerves of the anterior abdominal wall are the ventral rami of the T6–L1 spinal nerves. These nerves course downward and anteriorly between the internal oblique and the transverse abdominis muscles. They segmentally supply cutaneous innervation to the skin and parietal peritoneum and are the motor supply to the anterolateral abdominal wall muscles. The lower intercostal nerves and the subcostal nerve pierce the deep layer of the rectus sheath and course through to the skin to become the anterior cutaneous nerves of the abdomen. The first lumbar nerve bifurcates into the **iliohypogastric** and **ilioinguinal nerves**, which do not enter the rectus sheath. Instead, the iliohypogastric nerve pierces the external oblique aponeurosis superior to the superficial inguinal ring, whereas the ilioinguinal nerve passes through the inguinal canal to emerge through the superficial inguinal ring.

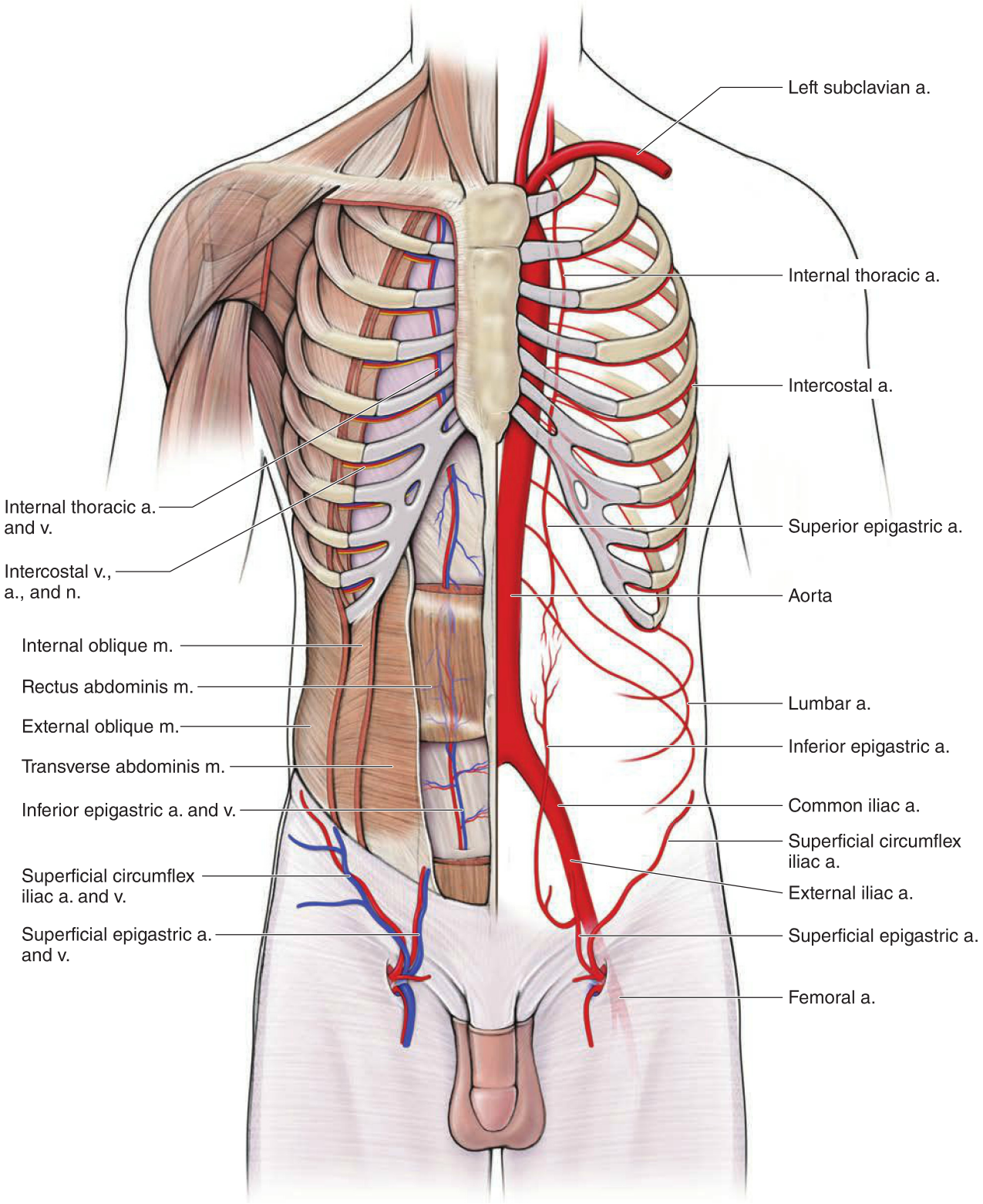

Figure 7-3: Neurovascular structures of the anterior abdominal wall. The left side of the figure shows a step dissection detailing the location of the neurovascular structures. The right side of the figure shows a schematic of arterial supply.

INGUINAL CANAL

BIG PICTURE

The inguinal canal is an oblique passage through the inferior region of the anterior abdominal wall. The inguinal canal is more relevant clinically in males because it is the passageway for structures that course between the testis and the abdomen. The inguinal canal is less clinically relevant in females because only the round ligament of the uterus traverses it. The anterior abdominal wall has five distinct parietal peritoneal folds on its internal surface (one midline and two on each side). These five folds contain the remnant of the urachus, the paired obliterated umbilical arteries, and the paired inferior epigastric vessels.

INGUINAL CANAL STRUCTURE

The inguinal canal is approximately 5-cm long and extends from the deep inguinal ring downward and medially to the superficial inguinal ring. The inguinal canal lies parallel to and immediately superior to the inguinal ligament. The inguinal canal is much like a rectangular tube in that it has four walls, with openings at both ends, described as follows (Figure 7-4A):

- **Anterior wall.** Formed by the external oblique aponeurosis.
- **Posterior wall.** Formed by the conjoint tendon of the internal oblique and the transverse abdominis muscles and the transversalis fascia.
- **Roof.** Formed by arching fibers of the internal oblique and the transverse abdominis muscles.
- **Floor.** The medial half of the inguinal ligament forms the inferior wall of the inguinal canal. This rolled-under, free margin of the external oblique aponeurosis forms a gutter or trough on which the contents of the inguinal canal are positioned. The **lacunar ligament** reinforces most of the medial part of the floor.
- **Deep inguinal ring.** Formed by an opening in the transversalis fascia. The deep inguinal ring is located superior to the inguinal ligament, lateral to the inferior epigastric vessels, and halfway between the pubic bone and the anterior superior iliac spine.
- **Superficial inguinal ring.** Formed by an opening in the external oblique aponeurosis superior and medial to the pubic tubercle.

The contents of the male inguinal canal include the following:

- Genital branch of the genitofemoral nerve (L1–L2).
- Ductus deferens.
- Testicular artery and vein.
- Autonomic nerves.

Additionally, the **ilioinguinal nerve (L1)** courses between the internal oblique and the transverse abdominis muscles. This nerve enters in the middle of the inguinal canal in both males and females. The ilioinguinal nerve exits the inguinal canal through the superficial inguinal ring with other contents that course through the inguinal canal. Therefore, the ilioinguinal nerve does not enter the inguinal canal via the deep inguinal ring but does exit the superficial inguinal ring.

When the anterior abdominal wall muscles contract, intra-abdominal pressure increases (e.g., forceful exhalation; coughing; pushing out stool or urine). This increase in pressure pushes the diaphragm up, forcing air out of the lungs. The inguinal canal, with its openings in the anterior abdominal wall, serves as a potential weakness when intra-abdominal pressure increases. When the posterior wall of the inguinal canal weakens (e.g., in the elderly), an increase in intra-abdominal pressure may force the small intestine into the inguinal canal, resulting in a **hernia**. To check for the presence of a hernia in males, the health care provider inserts a finger up into the scrotum to the superficial inguinal ring. The patient is instructed to increase intra-abdominal pressure by coughing. If the health care provider feels contact on his or her fingertip, a hernia is most likely present.

Hernias are classified as **direct** or **indirect**, with the **inferior epigastric vessels** serving as the differentiating anatomic landmark.

- **Direct hernia.** Results when the small intestine protrudes into the canal *medial* to the inferior epigastric vessels.
- **Indirect hernia.** Results when the small intestine protrudes into the canal *lateral* to the inferior epigastric vessels into the inguinal canal.

UMBILICAL FOLDS

Identify the following structures on the internal surface of the anterior abdominal wall (Figure 7-4B):

- **Median umbilical fold.** Unpaired fold in the mid-sagittal plane that contains the fibrous remains of the urachus, which courses from the apex of the bladder to the umbilicus.
- **Medial umbilical folds.** Paired folds that contain the obliterated umbilical arteries, which course from the internal iliac artery to the umbilicus.
- **Lateral umbilical folds.** Paired folds that contain the inferior epigastric arteries and veins, which course from the external iliac arteries and veins respectively to the arcuate line.

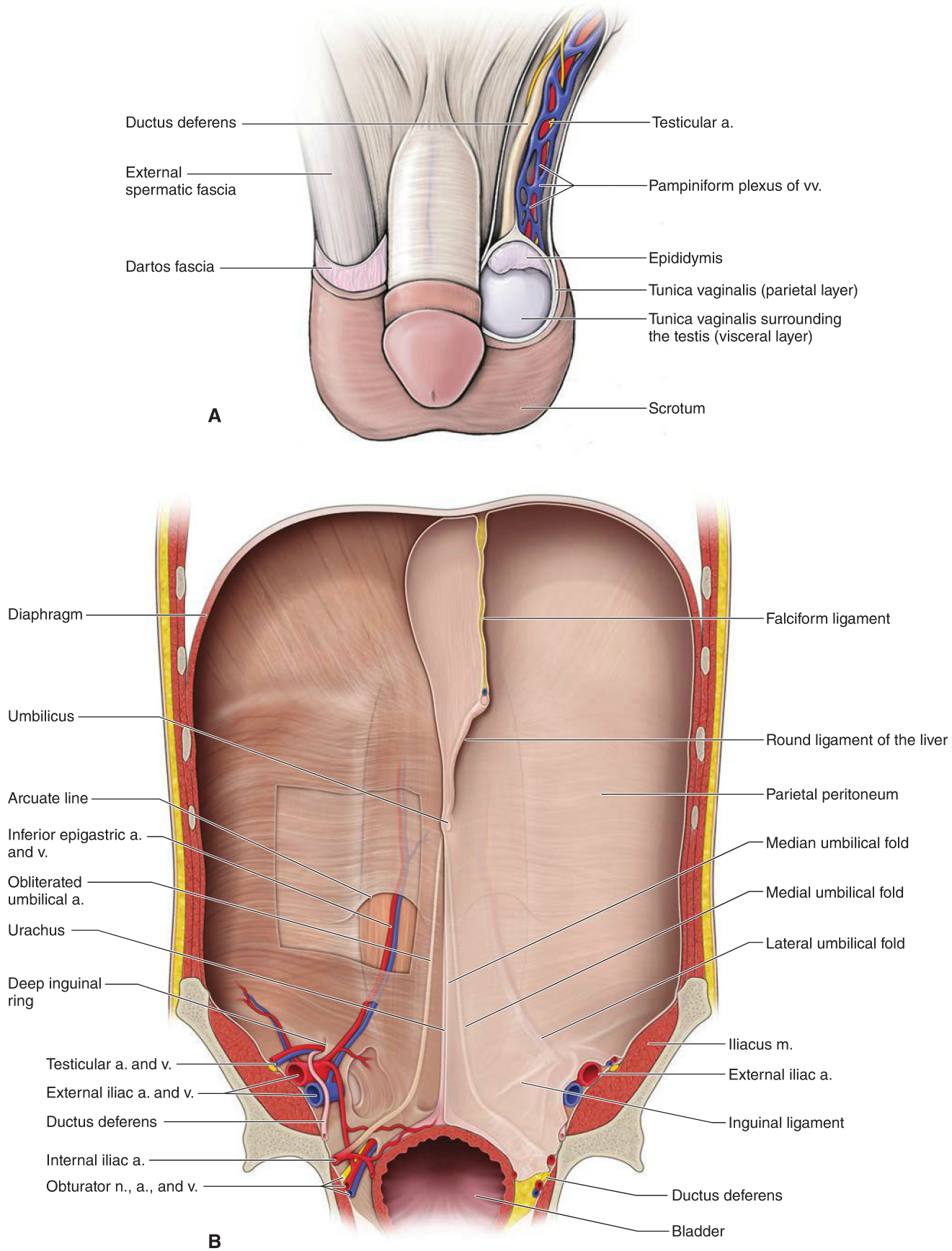

Figure 7-4: A. Schematic of the inguinal canal. **B**. Internal view of the anterior abdominal wall.

SCROTUM AND SPERMATIC CORD

BIG PICTURE

The testes produce sperm and testosterone. The testes are housed in a layered sac of muscle and fascia called the scrotum, which is continuous with the muscle and fascia of the anterior abdominal wall via the spermatic cord (Figure 7-5).

TESTES

The primary sex organs of the males are the **testes** because they produce **sperm**. A temperature of 34°C is required for the testes to produce sperm, which is 3°C lower than core body temperature. As such, the testes must be housed outside the body in the scrotal sac.

- **Embryonic origin.** During embryonic development, the testes arise in the region of the kidneys and descend to protrude through the inferior portion of the anterior abdominal wall. This developmental migration of the testes through the anterior abdominal wall is the basis of formation of the inguinal canal, spermatic cord, and scrotum from the muscle and fascial layers of the anterior abdominal wall. This developmental migration also is the basis of congenital (indirect) inguinal hernia in newborn male infants.

SCROTUM

The layers of the scrotal sac are as follows (review the muscle and fascial layers of the anterior abdominal wall):

- **Skin.** Formed by the epidermis and dermis.
- **Dartos fascia.** A continuation of Scarpa's fascia. Consists of a thin layer of loose connective tissue with some smooth muscle (**dartos muscle**). The smooth muscle contracts and thus wrinkles the skin of the scrotum, enhancing the radiation of heat when the temperature of the testes increases excessively (e.g., a hot bath).
- **External spermatic fascia.** Continuation of the external oblique aponeurosis.
- **Cremasteric muscle.** Continuation of the internal oblique muscle. If the temperature of the testes drops, contraction of the cremasteric muscle moves the testes closer to the body wall, thus helping to maintain appropriate temperature.
- **Internal spermatic fascia.** Continuation of the transversalis fascia (the transverse abdominis aponeurosis has no contributions to the scrotal sac).
- **Tunica vaginalis.** A serous membrane pouch that covers the testis. The testes develop in the retroperitoneal space and as they descend to form the scrotum some peritoneum (processus vaginalis) is pulled into the developing scrotal sac and surrounds the testis (the tunica vaginalis surrounds the testes and does not have a counterpart in the spermatic cord).
- **Tunica albuginea.** The dense white connective tissue capsule of the testis.
- **Seminiferous tubules.** Microscopic tubules that form the interior of the testis; site of production, maturation, and transportation of spermatozoa.

▽ The sensory branch of the **genitofemoral nerve** provides cutaneous innervation of the skin over the medial aspect of the thigh, whereas the motor division innervates the **cremasteric muscle**. Light touch of the medial region of the thigh elicits a motor reflex, causing contraction of the cremaster muscle to pull the testis on the same side of the body closer to the body. This is called the **cremasteric reflex**. ▼

SPERMATIC CORD

Similar to the scrotal sac, the spermatic cord has the same muscular and fascial layers as the anterior abdominal wall because the testis descends through the abdominal wall to the scrotum during embryonic development. The spermatic cord contains the following structures:

- **Ductus deferens.** During ejaculation the ductus deferens transports sperm from the testes, through the spermatic cord and inguinal canal to the ejaculatory duct in the prostate. Much of the ductus deferens is composed of smooth muscle and, as a result, feels rigid and hard to the touch. Therefore, the ductus deferens is easy to palpate in the spermatic cord.

▽ The ductus deferens is also called the **vas deferens**, a misnomer because the word "vas" means vessel. The ductus deferens is not a vessel. However, this term persists frequently so that when each ductus deferens is cut as a form of male birth control, the procedure is called a "**vasectomy**," which means "cutting of the vas." A vasectomy is a relatively straightforward procedure in that it only requires an incision through the skin and layers of each spermatic cord to cut the ductus deferens. ▼

- **Testicular (gonadal) artery.** The paired gonadal arteries are bilaterally symmetrical. Each gonadal artery originates on the abdominal aorta, inferior to the renal arteries. Each artery traverses the deep inguinal ring and courses through the inguinal canal to provide the vascular supply to the testes and ductus deferens on the corresponding side of the body.
- **Testicular (gonadal) vein.** The paired gonadal veins are not bilaterally symmetrical (discussed in the chapter on the posterior abdominal wall). Each vein drains blood from the testis and courses from the scrotal sac, through the spermatic cord, and traverses the superficial inguinal ring through the inguinal canal before entering the abdominal cavity.
  - **Right gonadal vein.** Drains into the IVC.
  - **Left gonadal vein.** Drains into the left renal vein.
- **Autonomic neurons.** Sympathetic and visceral sensory neurons.

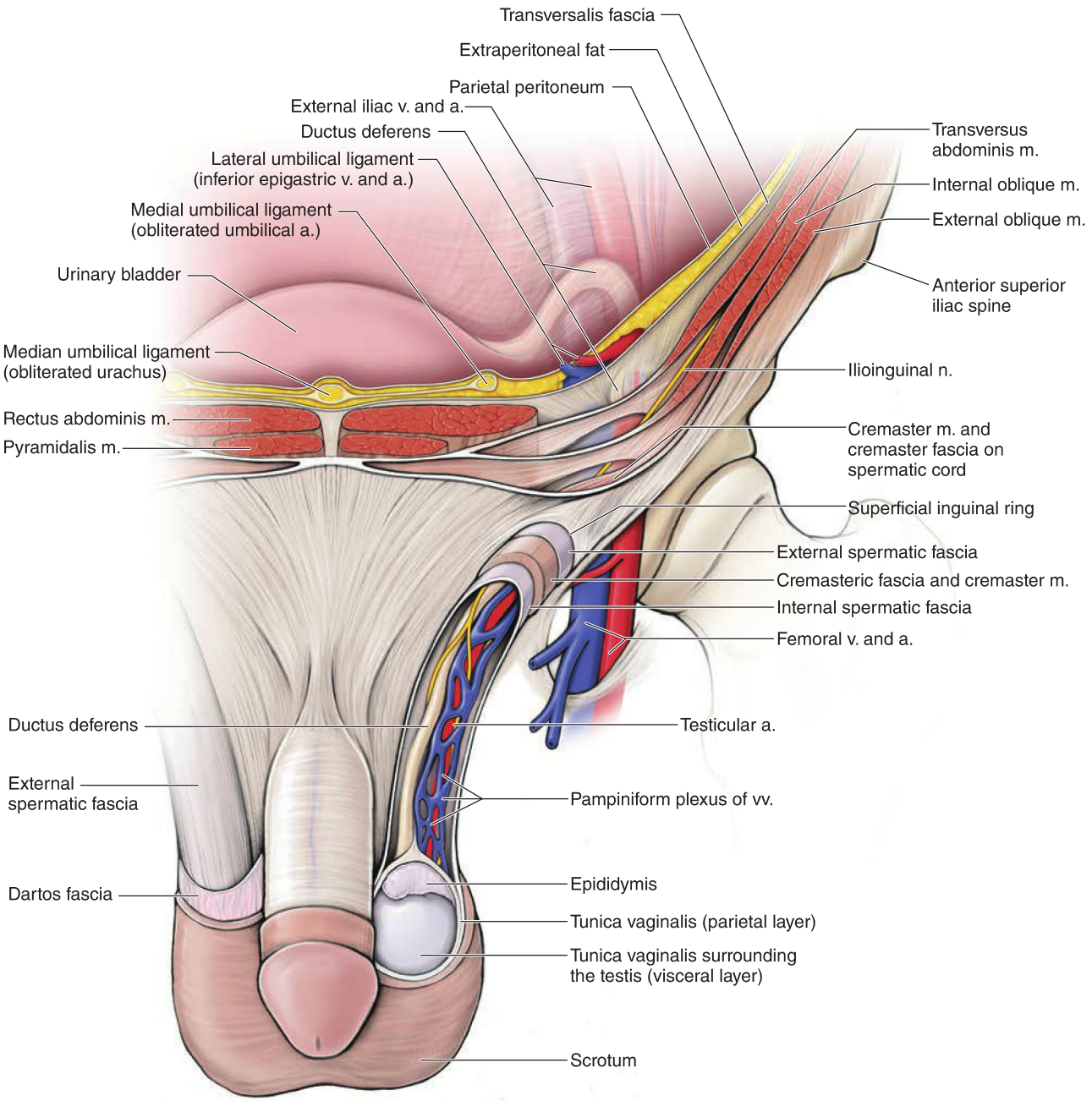

Figure 7-5: Schematic of the inguinal canal, spermatic cord, and scrotum.

This page intentionally left blank

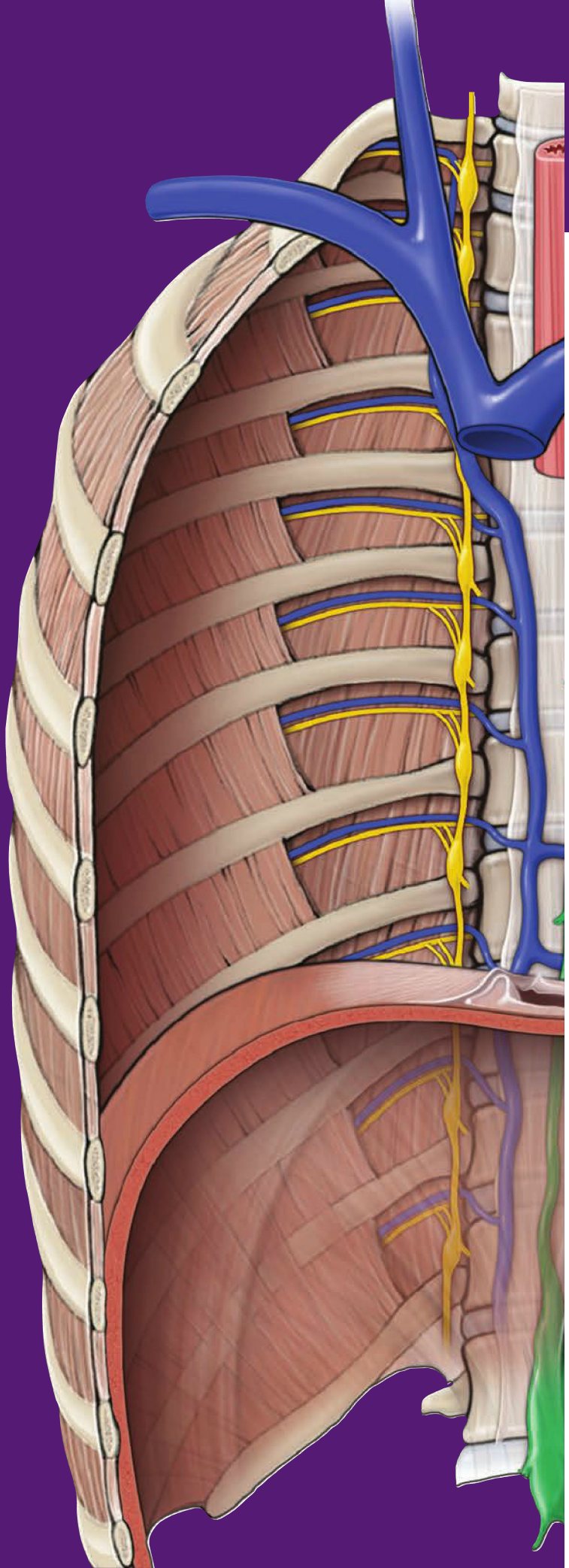

CHAPTER 8

SEROUS MEMBRANES OF THE ABDOMINAL CAVITY

The Peritoneum 96

THE PERITONEUM

BIG PICTURE

The abdominopelvic cavity is lined with a serous membrane called the peritoneum. The peritoneum completely or partially lines the internal surface of the abdominal wall and organs of the abdominal cavity. Like other serous sacs and their associated organs, the peritoneal sac and its organs have the basic structural relationship of a "fist in a balloon." This analogy accurately portrays the relationship of the peritoneal organs and the peritoneum. Digestive organs represent the "fist" and the peritoneal sac represents the "balloon."

PERITONEAL SAC

The peritoneal sac is composed of a serous membrane that lines the internal surface of the abdominal cavity and consists of the following parts (Figure 8-1A–C):

- **Parietal peritoneum.** The portion of the serous sac in contact with the internal surface of the abdominal wall, diaphragm, and pelvis. The posterior surface of the parietal peritoneum forms the anterior wall of the retroperitoneal space, which contains the kidneys, ureters, adrenal glands, aorta, IVC, and other structures.
- **Visceral peritoneum.** The serous membrane that surrounds the parts of the gut tube and forms the outer layer of the organs. The visceral peritoneum is also referred to as the tunica serosa.
- **The mesentery.** The parietal peritoneum reflects off of the posterior abdominal wall, forming a fused, double layer of peritoneum surrounding the blood vessels, nerves, and lymphatics to abdominal organs. This double layer of peritoneum, known as the mesentery, suspends much of the small intestines from the posterior abdominal wall.
- **Peritoneal fluid.** Peritoneal membranes secrete a serous fluid that lubricates the peritoneal surfaces, enabling the intraperitoneal organs to glide across one another with minimal friction.
- **Peritoneal cavity.** The peritoneal cavity is the fluid-filled space within the peritoneal sac. The peritoneal cavity is completely closed in males. In females, the peritoneal cavity has two tiny openings into the ostium of the uterine tubes, which provides a possible communication with the outside via the uterus and vagina. The peritoneal cavity is subdivided into the greater and lesser sacs:
  - **Lesser sac (omental bursa).** The space deep to the stomach and lesser omentum.
  - **Greater sac.** The remaining part of the peritoneal cavity. The greater and lesser sacs communicate with each other through the **epiploic foramen (of Winslow)** formed by the right border of the hepatoduodenal ligament.

OMENTUM

The omentum refers to modified mesenteries associated with the stomach and liver (Figure 8-1A).

- **Greater omentum.** An apron-like fold of peritoneum that develops from the dorsal mesentery and attaches between the transverse colon and greater curvature of the stomach.
  - **Quadruple layer of peritoneum.** The greater omentum consists of a double sheet that folds upon itself to create four layers of peritoneum. The four layers are formed as follows:
    - One sheet descends from the anterior surface and the other from the posterior surface of the stomach and duodenum and they come together at the greater curvature.
    - This double membrane descends from the greater curvature, anterior to the transverse colon and small intestine to the level of the pelvis.
    - This double membrane then turns upon itself and ascends and envelopes the transverse colon.
    - As such, the double layer descending from the stomach to the level of the pelvis and the ascending double layer ascending toward the transverse colon make four layers.
  - **Subdivisions.** The greater omentum is often defined to have the following subdivisions:
    - **Gastrophrenic ligament.** Extends from the greater curvature of stomach to the deep surface of the left dome of the diaphragm.
    - **Gastrosplenic ligament.** Extends from the greater curvature of stomach to the spleen.
    - **Gastrocolic ligament.** Extends from the greater curvature of stomach to the transverse colon; many consider this synonymous with the greater omentum because it forms the bulk of the structure.
- **Lesser omentum.** Double layer of peritoneum that develops from the ventral mesentery. The lesser omentum bridges the space between the lesser curvature of the stomach, first part of the duodenum, and the liver. Due to its attachments, the lesser omentum is often subdivided into the following parts:
  - **Hepatogastric ligament.** Portion of the lesser omentum attaching to the liver and stomach.
  - **Hepatoduodenal ligament.** Portion of the lesser omentum attaching to the liver and first part of the duodenum.

INNERVATION AND VASCULAR SUPPLY OF THE PERITONEUM

The neurovascular and lymphatic supply of the peritoneum course to and from the posterior abdominal wall, as well as to and from the gut tube between the two-layered mesentery (Figure 8-1B).

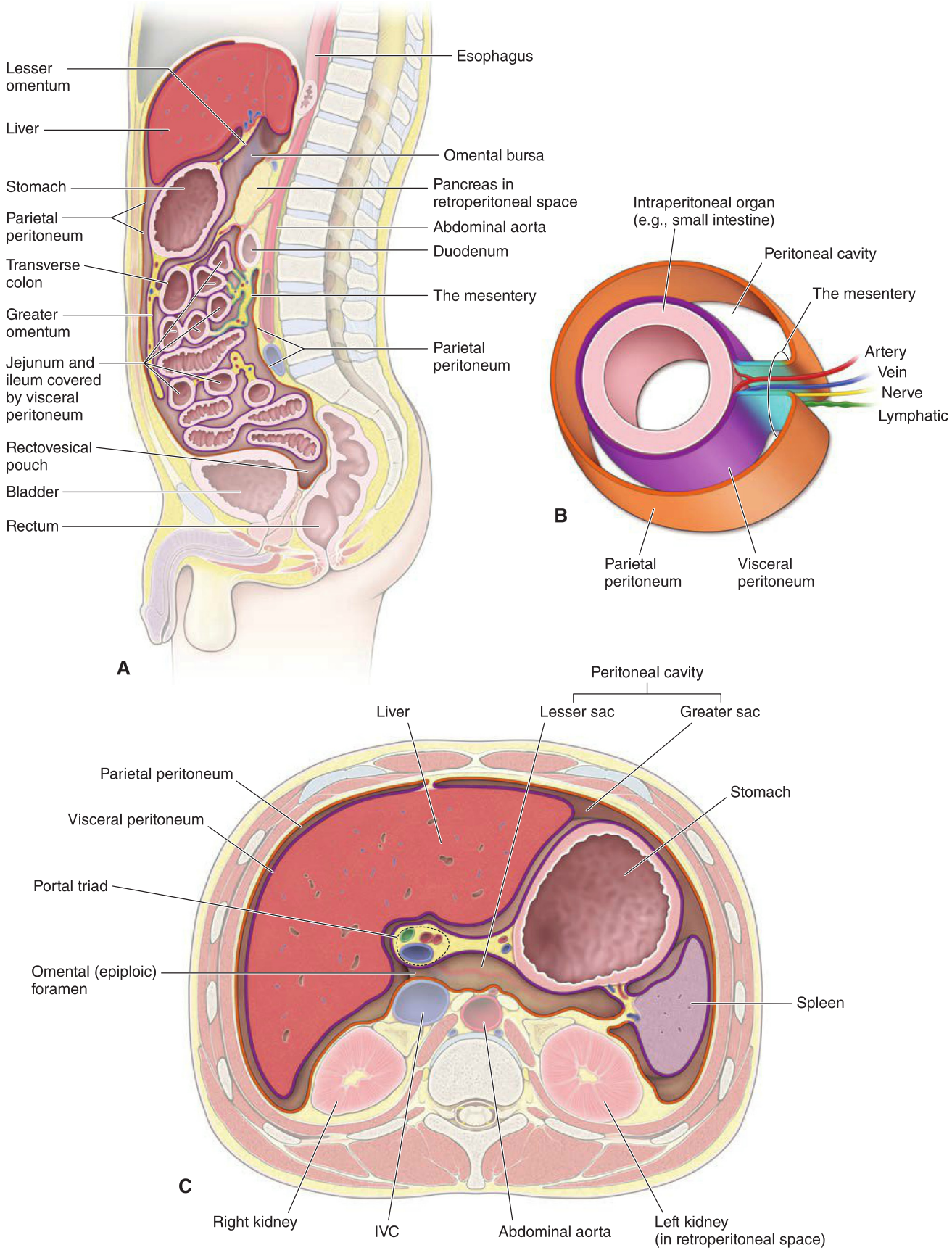

Figure 8-1: **A**. Parasagittal section of the abdomen showing the peritoneum. **B**. Relationship of the mesentery and neurovascular supply to the intraperitoneal organs. **C**. Cross-section of the peritoneum and mesentery at approximately the T11 vertebral level.

- **Parietal peritoneum.** The vascular supply to the parietal peritoneum is through the same vessels that supply the abdominal body wall, mainly the **intercostal, lumbar, and epigastric vessels**. The nerves supplying the parietal peritoneum are the same that supply the body wall (intercostal nerves). The parietal peritoneum receives somatic sensory innervation. Therefore, **somatic pain** is sharp, focused, and specific.
- **Visceral peritoneum.** The vascular supply to the visceral peritoneum is through the same abdominal aortic branch vessels that supply the GI tract. The visceral peritoneum and abdominal organs receive sensory innervation via the visceral afferents that accompany the autonomic nerves (sympathetic and parasympathetic). **Visceral pain** is dull, diffuse, and nonspecific.

The parietal and visceral peritoneum are innervated by different modalities of sensory neurons; that is, parietal peritoneum via somatic innervation and visceral peritoneum via visceral innervation. Therefore, pain experienced in the parietal peritoneum is sharp, focused, and specific. In contrast, pain referred by the visceral peritoneum is dull, diffuse, and nonspecific.

ORGANIZATION OF THE ABDOMINAL VISCERA

Abdominal viscera are classified as either intraperitoneal or retroperitoneal (Figure 8-1A and C).

- **Intraperitoneal.** Viscera that are suspended from the posterior abdominal wall by mesenteries. Intraperitoneal organs are surrounded by visceral peritoneum (e.g., stomach).
- **Retroperitoneal.** Viscera that are not suspended from the abdominal wall by mesenteries. Retroperitoneal organs lie against the posterior abdominal wall or floor of the pelvis, superficial to the parietal peritoneum (e.g., kidney).

Surgical procedures involving organs located in the **retroperitoneal space** are typically accessed through the body wall, superficial to the parietal peritoneum. For example, to access organs in the retroperitoneal space, such as the kidney, a lateral incision is made through the muscles of the abdominal body wall, leaving the parietal peritoneum intact. This approach reduces the risk of infection and peritonitis because the peritoneal cavity is not entered.

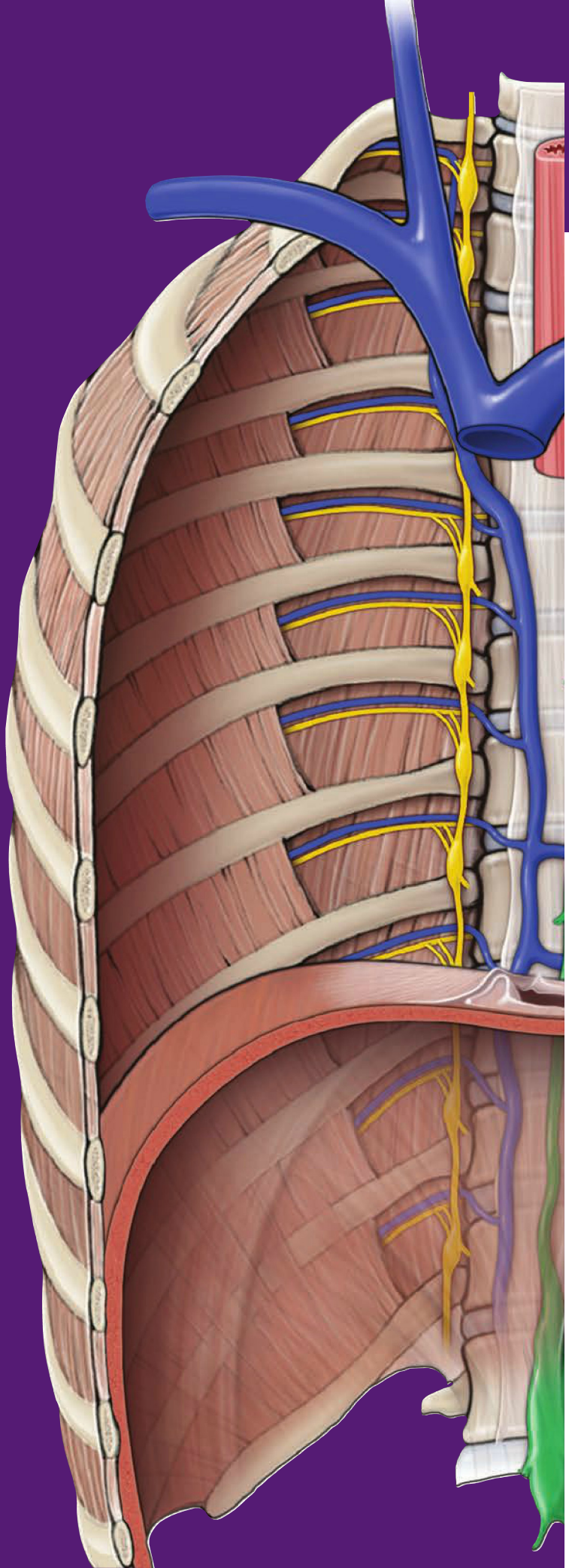

CHAPTER 9

FOREGUT

GI Portion of the Foregut 100
Liver and Gallbladder 102
Pancreas and Spleen 104
Vascular Supply of the Foregut 106

GI PORTION OF THE FOREGUT

BIG PICTURE

The foregut consists of the distal end of the esophagus, stomach, duodenum (first and second parts), pancreas, liver, and gallbladder. The celiac trunk is the primary arterial supply of the foregut and the portal vein provides its venous drainage. Lymph from the foregut drains into the celiac nodes surrounding the celiac trunk.

ESOPHAGUS

The esophagus traverses the diaphragm to enter the abdominal cavity at the T10 vertebral level where the esophagus transitions immediately into the stomach. The **cardiac sphincter** serves as the transition boundary between esophagus and stomach.

GERD. A function of the stomach is the production of hydrochloric acid. If the cardiac sphincter fails to contain the acidic chyme produced by the stomach, the acid moves into the esophagus, irritating its mucosal lining and causing gastroesophageal reflux disease (GERD). The irritation presents as an uncomfortable, perhaps burning, sensation in the region of the esophagus, deep to the heart. As a result, this condition is also referred to as "**heart burn**."

STOMACH

The stomach is a dilated portion of the foregut between the esophagus and duodenum (Figure 9-1A and B).

- **Topography.** The stomach is located in the upper left quadrant of the abdomen and is superficial to the spleen, pancreas, and aorta.
- **Function.** Peristaltic movements churn gastric contents, facilitating their breakdown and mixing in secretions from gastric glands.
  - **Gastric secretions.** Include **pepsin** (digests proteins) and **gastric lipase** (digests lipids); the stomach churns food contents and gastric secretions into **chyme**, which is transported to the duodenum.
- **Regions.** The stomach has the following regions:
  - **Cardia.** Surrounds the gastroesophageal opening into the stomach.
  - **Fundus.** Dome-shaped region superior to the cardia.
  - **Great curvature.** The longer, inferior region of the stomach.
  - **Lesser curvature.** The shorter, superior region of the stomach.
  - **Body.** Largest stomach region.
  - **Pylorus.** Distal region of the stomach, which lies at the L1 vertebral level (transpyloric plane).
  - **Pyloric sphincter.** A thick circular layer of smooth muscle that controls the passage of gastric contents into the duodenum.
  - **Gastric rugae.** Folds along the internal surface of the stomach that increases surface area and channels chyme toward the duodenum. The gastric rugae disappear when the stomach fills (can hold up to 1.5 L of food).
- **Peritoneum.** The stomach is covered externally by the peritoneum that is the transition between the lesser omentum and greater omentum.

Hiatal hernia. The distal end of the esophagus and gastric fundus can herniate through the esophageal hiatus of the diaphragm into the thoracic cavity. This is known as a hiatal hernia and results from conditions such as long-term strain on the diaphragm associated with raised intra-abdominal pressure (e.g., passing stool and childbirth) or congenital defects in the diaphragm.

DUODENUM (FIRST AND SECOND PARTS)

The duodenum is the smallest segment of the small intestine (25-cm long), wraps around the pancreatic head, and is the location for most chemical digestion. The duodenum is divided into four parts. The first part is intraperitoneal and second to fourth parts are retroperitoneal (Figure 9-1A and B):

- **First Part (superior).** Courses from the pylorus at the L1 vertebral level to the superior duodenal flexure; is attached to the liver by the hepatoduodenal ligament of the lesser omentum.
  - The **duodenal bulb** is a dilated region of the first part of the duodenum and is superficial to the gastroduodenal artery, portal vein, and common bile duct. As such, a duodenal ulcer that perforates through the posterior wall of the duodenal bulb will likely bleed due to erosion through the gastroduodenal artery.
- **Second Part (descending).** Courses vertically from the superior duodenal flexure to the inferior duodenal flexure at the L3 vertebra.
  - The **main pancreatic duct (of Wirsung)** and **common bile duct** enter the posterior wall of the second part where they form the **major duodenal papilla (of Vater)**. The papilla is surrounded by smooth muscle called the **sphincter of Oddi.**
  - An **accessory pancreatic duct (of Santorini)** may enter the duodenum proximal to the main pancreatic duct.
  - The transition from foregut to midgut occurs immediately inferior to the major duodenal papilla.
- **Third Part (horizontal).** Courses horizontally from the inferior duodenal flexure to the left across the IVC, aorta, and vertebral column.
  - The **superior mesenteric artery and vein** descend anteriorly over the third part of the duodenum.
- **Fourth Part (ascending).** The distal portion of the fourth part is transitional, from retroperitoneal to intraperitoneal in the region of the **duodenojejunal junction**.

Duodenal ulcers. The submucosal layer of the duodenum contains **Brunner's glands**, which protect the duodenum against the acidic chyme from the stomach. Brunner's glands produce and secrete alkaline mucus that is rich in bicarbonate and **urogastrone**, which inhibits production of hydrochloric acid by parietal cells. Despite this protection, the duodenum is a relatively common site of ulcer formation.

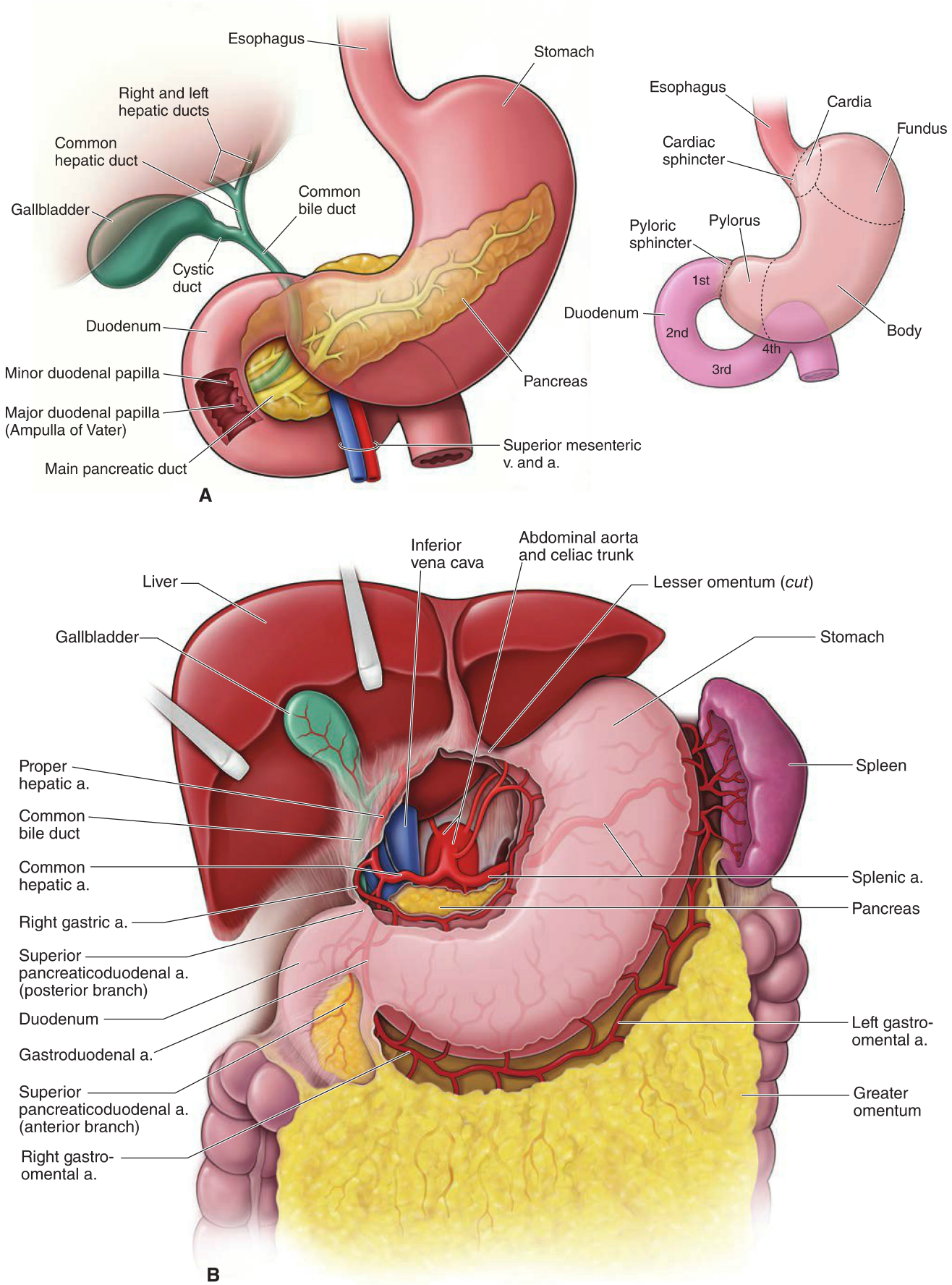

Figure 9-1: A. Parts of the stomach and duodenum. **B**. Anterior view of the foregut; the lesser omentum is partially removed.

LIVER AND GALLBLADDER

BIG PICTURE

The liver is the largest gland in the body, consists of four lobes of unequal size and shape, and is located in the upper right quadrant of the abdomen. The liver produces bile, which is transported and stored in the gallbladder. When food, especially fatty food, reaches the duodenum, the gallbladder releases bile, which emulsifies fat in the duodenum. The liver is also involved in cholesterol metabolism, the urea cycle, protein production, clotting factor production, detoxification, and phagocytosis via the Kupffer cells lining the sinusoids. The liver receives its blood supply from the hepatic artery and its venous drainage is into the portal vein. Blood courses through hepatic sinusoids where hepatocytes filter the blood.

LIVER

Mesenteries of the liver. The following peritoneal reflections are associated with the liver:

- **Visceral peritoneum.** Completely envelops the liver, except for the **bare area**, which is a small area of the liver that is apposed to the diaphragm. Visceral peritoneum is connected to the stomach and duodenum by the lesser omentum (hepatogastric and hepatoduodenal ligaments, respectively).
- **Bare area of the liver.** A triangular region of the liver that is devoid of peritoneal covering. When parietal peritoneum from the under surface of the diaphragm becomes continuous with the visceral peritoneum of the liver, some of the liver's superior surface remains uncovered (this is the bare area). The IVC is located in the bare area. The coronary ligaments represent reflections of the visceral peritoneum covering the liver onto the diaphragm. As such, between the two layers of the coronary ligaments lies the bare area of the liver. The most lateral regions of the coronary ligaments are referred to as **triangular ligaments**.
- **Falciform ligament.** The parietal peritoneum lining the anterior abdominal wall courses vertically to separate the left and right lobes of the liver. The free inferior border of the falciform ligament between the umbilicus and liver encloses the **ligamentum teres**, which is the remnant of the fetal umbilical vein.

The liver is subdivided into lobes and by the Couinaud classification system:

Lobes of the liver. The liver is divided into four anatomical lobes based upon external depressions and grooves (Figure 9-2A):

- **Right lobe.** Positioned to the right of the inferior vena cava and gallbladder.
- **Left lobe.** Positioned to the left of the ligamentum teres.
- **Quadrate lobe.** Positioned anterior to the portal triad between the falciform ligament and gallbladder.
- **Caudate lobe.** Positioned posterior to the portal triad between the falciform ligament and IVC.

Couinaud classification system. According to this system, the liver is divided into eight functionally independent segments, with each segment having its own vascular inflow and outflow, and biliary drainage. Within the center of each segment is a branch of the portal vein, hepatic artery, and bile duct. In the periphery of each segment, vascular outflow is through the hepatic veins.

- The right hepatic vein divides the right lobe into anterior and posterior segments.
- Middle hepatic vein divides the liver into right and left lobes.
- The left hepatic vein divides the left lobe into medial and lateral segments.
- The portal vein divides the liver into upper and lower segments.

PORTAL TRIAD The portal triad lies between the caudate and quadrate lobes (Figure 9-2B and C). The portal triad consists of the **proper hepatic artery**, **portal vein,** and the **common hepatic duct**. This triad relationship is the structural unit within the liver.

Proper hepatic artery. Arises from the celiac trunk via the common hepatic artery. The proper hepatic artery supplies oxygenated blood to the hepatic sinusoids where blood from the hepatic arteries and portal vein mix.

Portal vein. Formed through the union of the splenic and superior mesenteric veins deep to the hepatic artery and the common hepatic duct.

- **Hepatic sinusoids.** The portal vein collects nutrient-rich venous blood from the foregut, midgut, hindgut and spleen, where it is transported to the hepatic sinusoids of the liver for filtration and detoxification.
- **Terminal hepatic venules.** The hepatic sinusoids empty into the terminal hepatic venules, which empty into the hepatic veins and ultimately into the IVC.
- **Hepatic portal system.** The flow of blood from one capillary bed (intestinal capillaries) through a second capillary bed (liver sinusoids) before its return by systemic veins to the heart is defined as the hepatic portal system.

Common hepatic duct. The union of the left and right hepatic ducts forms the common hepatic duct. The common hepatic duct transmits bile produced in the liver to the gallbladder for storage.

Portal hypertension. Results when the flow of blood through the hepatic sinusoids is obstructed. Possible causes include hepatitis or cirrhosis of the liver. Signs of portal hypertension include hemorrhoids and gastroesophageal bleeding, which result from the obstruction of the portal venous blood flow through the liver and the increased flow of blood through alternate routes to reach the IVC (e.g., rectal and esophageal veins). When these alternate paths receive more blood than normal, the veins dilate, distend, and become more prone to hemorrhage.

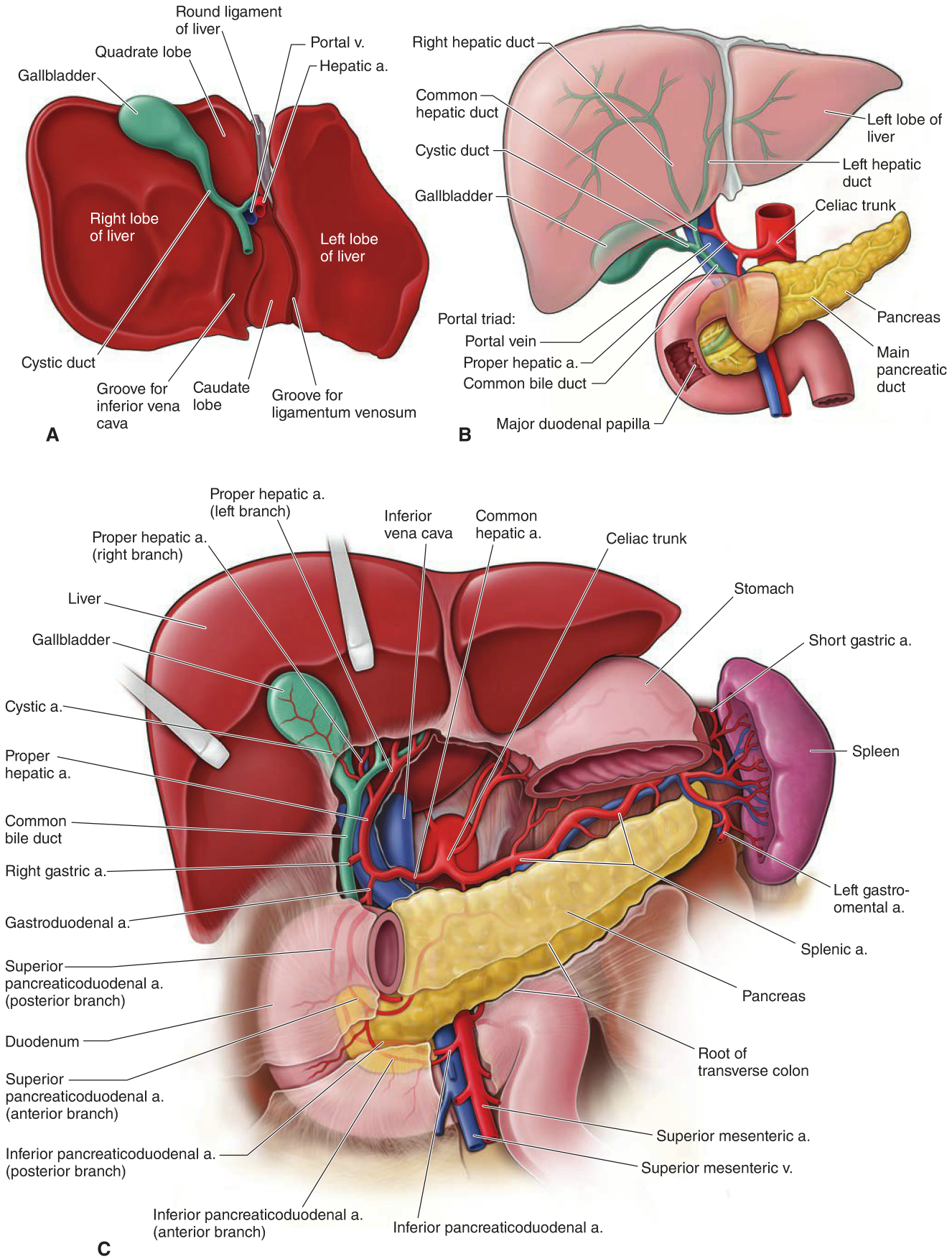

Figure 9-2: A. Visceral (inferior) view of the liver. **B**. Portal triad. **C**. Anterior view of the foregut with the body and pylorus of the stomach removed; the lesser omentum is also removed.

Pringle maneuver. All blood passing to the liver enters through either the proper hepatic artery (oxygenated from the aorta) or portal vein (deoxygenated but nutritionally rich from the GI tract). Both vessels course within the free border of the lesser omentum in the hepatoduodenal ligament. As such, compressing the free border of the lesser omentum can stop bleeding from the liver. This procedure is called Pringle Maneuver. If bleeding continues following this maneuver then the IVC is most likely leaking or cut.

GALLBLADDER

The gallbladder lies on the visceral surface of the liver, to the right of the quadrate lobe. The gallbladder stores and concentrates bile secreted by the liver (Figure 9-2A–C).

- Bile is released from the gallbladder into the **cystic duct** after being stimulated following a fatty meal. The cystic duct joins the **common hepatic duct**, becoming the **common bile duct**.
- The common bile duct courses within the **hepatoduodenal ligament** of the **lesser omentum**, deep to the first part of the duodenum, where it joins the **main pancreatic duct** and enters the second part of the duodenum at the **hepatopancreatic ampulla (of Vater)**.
- The **sphincter of Oddi** surrounds the ampulla and controls the flow of bile and pancreatic digestive enzyme secretions into the duodenum.

Gallstones. Form in the gallbladder and may obstruct the flow of bile, resulting in inflammation and enlargement. These stones may be composed of bilirubin metabolites, cholesterol, and/or various calcium salts. Gallstones frequently obstruct the gallbladder, causing retention of bile and the risk of rupture into the peritoneal cavity, which ultimately results in **peritonitis**. Pain is often felt in the right upper abdominal quadrant and referred to the right shoulder. The surgical removal of a gallbladder is referred to as a **cholecystectomy**.

PANCREAS AND SPLEEN

BIG PICTURE

The pancreas is an organ of dual function: exocrine secretion for digestion and endocrine function for regulation of glucose metabolism. By comparison, the spleen contributes to the formation of blood cells during fetal and early postnatal life, is involved in the development of immune cells (lymphocytes), and is involved in clearance of red blood cells from the blood (tissue macrophages).

PANCREAS

The pancreas is a retroperitoneal organ located deep to the stomach at the L2 vertebral level, is about 15 cm long, and consists of both exocrine and endocrine tissues.

- **Pancreas as an exocrine organ.** The pancreas produces enzymes that are secreted into the **main pancreatic duct**, which empties into the duodenum. The digestive enzymes chemically digest carbohydrates, proteins, and fats into simple sugars, amino acids, and fatty acids, and glycerol, respectively. An **accessory pancreatic duct** may open separately into the duodenum, proximal to the common bile duct.
- **Pancreas as an endocrine organ.** Endocrine tissue islands, called **pancreatic islets (of Langerhans)**, are located within the pancreas and produce the hormones **insulin and glucagon**. These hormones are secreted into the blood stream via **pancreatic veins**.

The pancreas has the following structures (Figure 9-3A and B):

- **Head and neck.** Nestled within the concavity of the duodenum; the head surrounds the superior mesenteric artery and vein.
- **Body and tail.** Located anterior to the left kidney; the end of the pancreatic tale touches the spleen and is the only portion that is not retroperitoneal.

SPLEEN

The spleen is located in the left upper quadrant of the abdomen, between the stomach and the diaphragm (Figure 9-3B). The spleen is the size of a fist and stores blood, phagocytizes foreign blood particles, and produces mononuclear leukocytes. The spleen also maintains "quality control" over erythrocytes by removal of senescent and defective red blood cells.

Splenomegaly. A condition that results in an excessively large spleen. This may occur in association with portal hypertension or an increase in the number of red blood cells. Splenomegaly can occur in patients who are diagnosed with diseases that change the shape of red blood cells (e.g., malaria). As a result, in these patients, the spleen filters an abnormally high number of red blood cells, which results in enlargement of the spleen.

Splenectomy. Although protected by the ribs, the spleen is frequently injured in trauma. In many cases, the force applied to the ribcage pushes the ribs inward, fracturing the ribs, the free edges of which puncture the spleen.

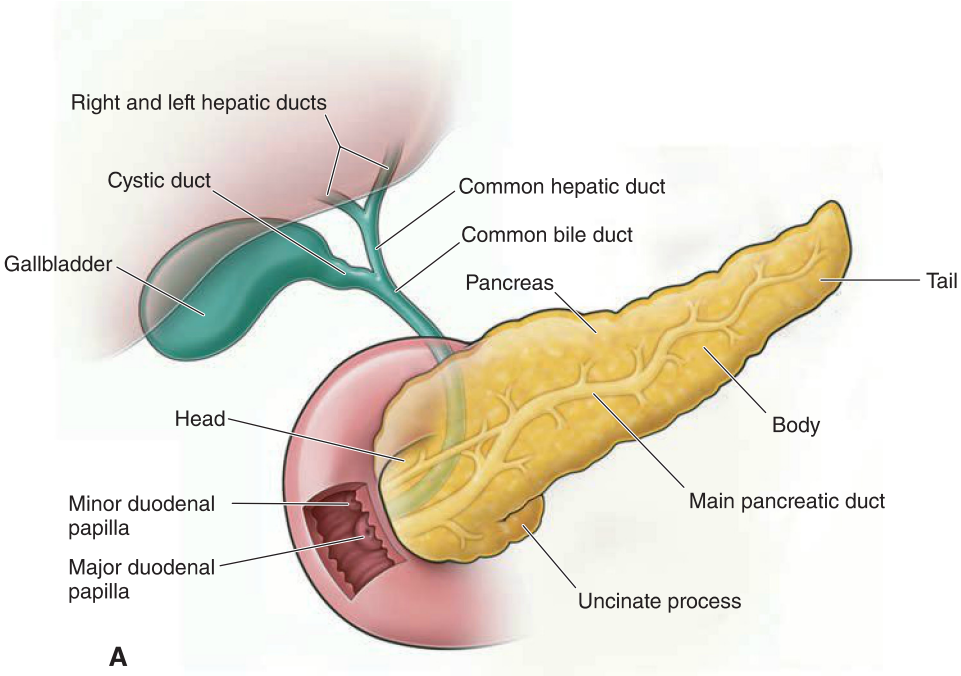

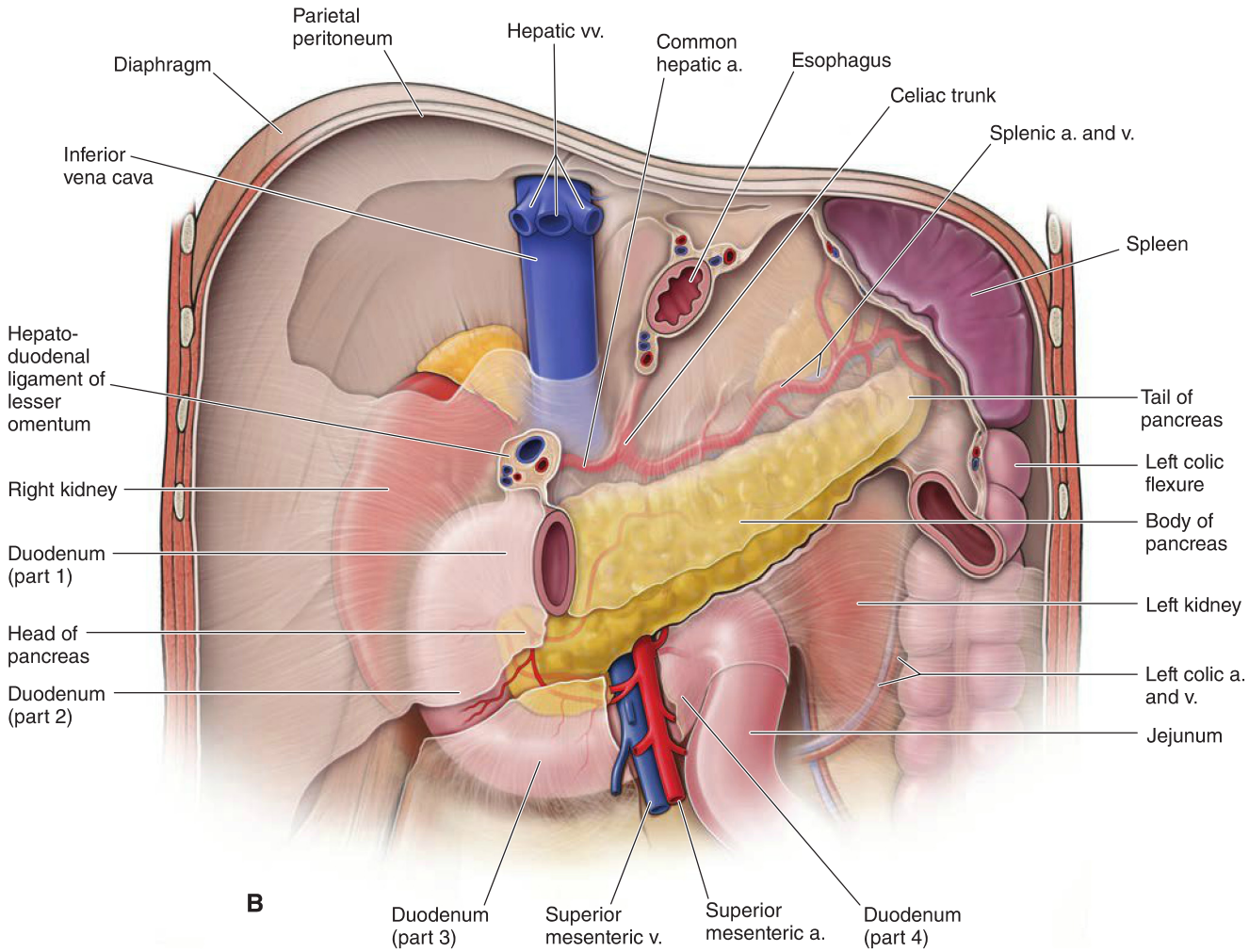

Figure 9-3: A. Pancreas and duct systems. **B**. Anterior view of the foregut; the stomach and liver are removed.

VASCULAR SUPPLY OF THE FOREGUT

BIG PICTURE

The foregut is the region of the GI tract that consists of the distal end of the esophagus, stomach, proximal half of the duodenum, liver, gall bladder, pancreas, and spleen. All organs associated with the foregut receive their arterial supply from branches off the celiac trunk.

ARTERIAL SUPPLY

The **celiac trunk** is an unpaired artery arising from the anterior surface of the abdominal aorta immediately below the aortic hiatus of the diaphragm (T12 vertebral level). The celiac trunk is the principal blood supply to the foregut. The celiac trunk gives rise to three branches: left gastric, splenic, and common hepatic arteries (Figure 9-4A).

- **Left gastric artery.** Courses within the lesser omentum and supplies the lesser curvature of the stomach and inferior portion of the esophagus; forms anastomosis with the right gastric artery.
- **Splenic artery.** Follows a highly torturous course along the superior border of the pancreas; terminates by passing between the layers of the splenorenal ligament and supplying the spleen. Gives rise to the following branches:
  - **Left gastroomental (gastroepiploic) artery.** Courses within the greater omentum and supplies the greater curvature of the stomach; forms anastomosis with the right gastroomental artery.
  - **Short gastric artery.** Supplies the left portion of the greater curvature and fundus.
  - **Pancreatic arteries.** Multiple branches that supply the neck, body, and tail of the pancreas.
  - **Posterior gastric artery.** Supplies posterior region of stomach.
- **Common hepatic artery.** Courses within the lesser omentum and gives rise to the following branches:
  - **Proper hepatic artery.** Arises from the common hepatic artery within the hepatoduodenal ligament of the lesser omentum, along with the portal vein and common bile duct. Gives rise to the following branches:
    - **Left hepatic artery.** Supplies the left lobe of the liver.
    - **Left and right hepatic arteries.** Supplies the right lobe of the liver; usually courses posterior to the common bile duct.
    - **Cystic artery.** Arises from the hepatic artery to supply the gallbladder; located within the **hepatobiliary (Calot's) triangle**, which is bordered by the common hepatic artery, cystic duct, and visceral surface of the liver.
  - **Right gastric artery.** Courses within the lesser omentum and supplies the lesser curvature of the stomach; forms an anastomosis with the left gastric artery.
  - **Gastroduodenal artery.** Descends deep to the first part of the duodenum, giving rise to the following two principal branches:
    - **Right gastroomental (gastroepiploic) artery.** Courses within the greater omentum and supplies the right half of the greater curvature of the stomach; forms anastomosis with the left gastroomental artery.
    - **Superior pancreaticoduodenal artery.** Descends on the pancreatic head and supplies the proximal portion of the duodenum and pancreatic head; forms an anastomosis between foregut and midgut arterial supply by way of the inferior pancreaticoduodenal arteries (branch off the superior mesenteric artery).

VENOUS DRAINAGE

The **portal venous system** drains nutrient-rich venous blood from the gastrointestinal tract and the spleen to the liver. Tributaries of the portal venous system associated with the foregut are as follows (Figure 9-4B):

- **Portal vein**. Formed by the union of the splenic and superior mesenteric veins; collects venous blood from the entire GI tract, including the following tributaries from the foregut:
  - **Right and left gastric veins.** Drain the lesser curvature of the stomach directly into the portal vein.
  - **Splenic vein.** Drains the spleen, fundus, and pancreas; receives the following tributaries:
    - **Left gastroomental vein.** Drains the greater curvature.
    - **Pancreatic veins.** Drain the body and tail directly into the splenic vein.
  - **Superior mesenteric vein.** Drains primarily the midgut but receives the following foregut tributary:
    - **Right gastroomental vein.** Drains the greater curvature directly into the superior mesenteric vein.

LYMPHATICS

Lymph is drained from organs of the GI tract to the regional lymph nodes along the arterial supply to that organ. Typically, this means the next set of lymph nodes is located at the origin of the artery to an organ. As such, lymph from foregut organs drains into the:

- **Celiac lymph nodes** surrounding the celiac trunk.

From the celiac lymph nodes, lymph passes to the cisternal chyli, the thoracic duct and its termination in the formation of the left brachiocephalic vein.

Gastric cancer. In some cases of upper abdominal malignant disease, primarily gastric cancer, involvement of left supraclavicular nodes may occur, presumably because of their proximity to the termination of the main thoracic duct. This, when present, is known as Virchow's node.

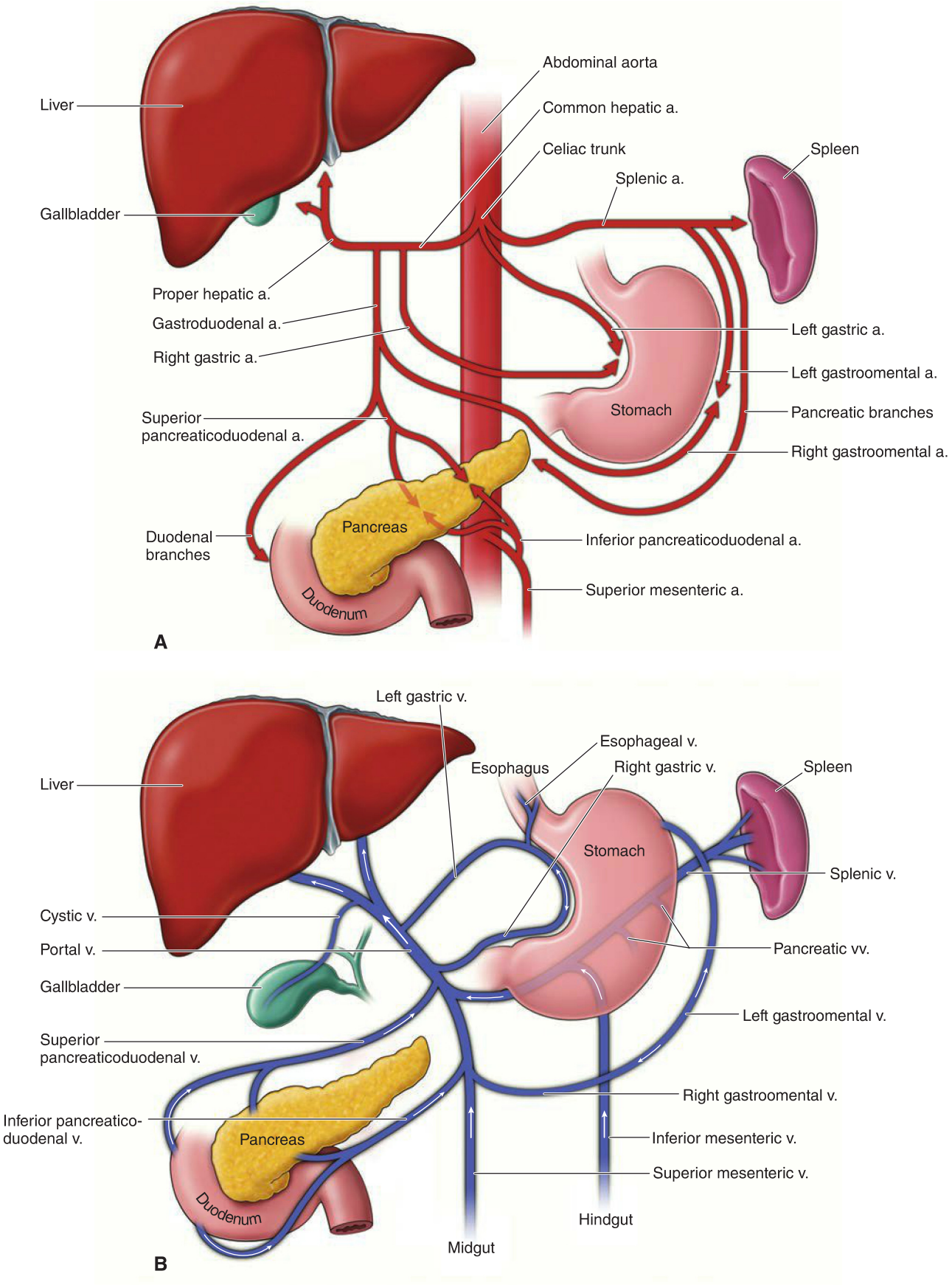

Figure 9-4: A. Arterial supply to the foregut supplied principally by the celiac trunk. **B**. Venous drainage of the foregut supplied principally by the portal vein.

This page intentionally left blank

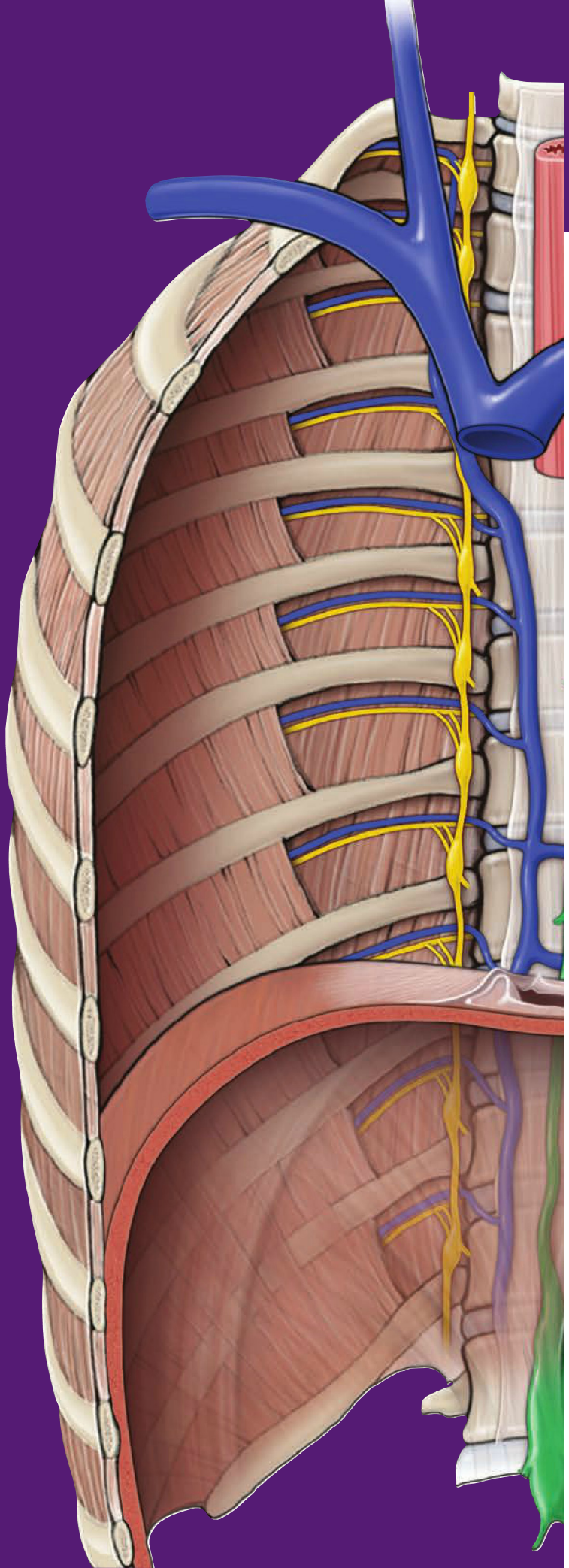

CHAPTER 10

MIDGUT, HINDGUT, AND GI VASCULAR SUPPLY AND INNERVATION

Midgut 110
Hindgut 112
Innervation of the GI Tract 114
Hepatic Portal System 116

MIDGUT

BIG PICTURE

The midgut consists of the duodenum (third and fourth parts), jejunum, ileum, cecum, ascending colon, and the proximal half of the transverse colon. The superior mesenteric arteries and veins provide the primary vascular supply for the midgut. Lymph from the midgut drains into the superior mesenteric nodes surrounding the superior mesenteric artery.

DUODENUM (THIRD AND FOURTH PARTS)

The duodenum chemically digests food because of the secretion of pancreatic enzymes. The parts of the duodenum associated with the midgut are as follows:

- **Third Part (horizontal).** Crossed anteriorly by the superior mesenteric artery and vein.
- **Fourth Part (ascending).** The distal portion of the fourth part is transitional, from retroperitoneal to intraperitoneal in the region of the **duodenojejunal junction**.
  - **Suspensory ligament of the duodenum (ligament of Treitz).** A structure composed of smooth muscle and connective tissue that arises from the left crus of the diaphragm and courses to the duodenojejunal junction, marking the transition from duodenum to jejunum.

JEJUNUM AND ILEUM

The jejunum and ileum are intraperitoneal organs and are tethered to the posterior abdominal wall via the mesentery. This double-layered peritoneum serves as the conduit for the mesenteric neurovascular structures.

- **Jejunum.** The jejunum is the second part of the small intestine and has the most highly developed **circular folds** lining the lumen, thereby increasing the surface area of the mucosal lining for absorption.
  - In contrast to the ileum, the jejunum also has a greater number of **vasa recti**. A histologic section of the jejunum is usually identified negatively: it lacks Brunner's glands (like the duodenum) or Peyer's patches (like the ileum).
- **Ileum.** The ileum is the third part of the small intestine and contains large lymphatic aggregates known as **Peyer's patches**. In some conditions, such as lymphomas, these Peyer's patches may enlarge and cause intestinal obstruction.
  - In contrast to the jejunum, the ileum has fewer circular folds lining the lumen and more **vascular arcades**.
  - The **terminal end of the ileum** has a thickened smooth muscle layer known as the **ileocecal valve** (sphincter), which prevents feces from the cecum to move backward from the large intestine into the small intestine.

▼ **Meckel's diverticulum.** Approaching the distal end of the ileum is the site of the embryonic vitellointestinal duct attachment. If a remnant of this duct persists it presents as Meckel's diverticulum. This diverticulum is important clinically in that it may contain ectopic gastric mucosa, which secretes acid. This may result in inflammation, bleeding from intestinal mucosa, bowl obstruction, intussusception, or perforation. A helpful way of remembering this condition is the rule of "2s": occurs in 2% of the population, is 2 inches in length, may contain 2 types of ectopic tissue (gastric and pancreatic), found within 2 feet of the ileocecal valve, and most become symptomatic before 2 years of age. ▼

CECUM AND APPENDIX

The cecum is the blind-ended sac at the beginning of the large intestine, is located inferior to the **ileocecal valve,** and is located in the right lower quadrant of the abdomen, within the iliac fossa (Figure 10-1A and B).

- **Appendix.** Attached to the cecum is the vermiform appendix, which has an unknown function in humans. The appendix is variable in length and position (usually lies deep to the cecum but may extend down into the pelvis). The surface projection of the appendix is McBurney's point, which is located 1/3 of the distance between the right anterior superior iliac spine and the umbilicus.

ASCENDING AND TRANSVERSE COLON

- **Ascending colon.** Arises from the cecum and courses vertically to the liver, where the colon bends at the **right colic (hepatic) flexure** (Figure 10-1B). The parietal peritoneum covers its anterior surface, and thus the ascending colon is considered a secondary-retroperitoneal organ.
- **Transverse colon.** The transverse colon is an intraperitoneal organ located between the right and left colic flexures.
  - **Gastrocolic ligament.** Connects the transverse colon to the stomach.
  - **Transverse mesocolon.** Two-layered peritoneum that connects the transverse colon to the posterior wall of the abdomen and contains its associated neurovascular structures (i.e., middle colic vessels); continuous with the two posterior layers of the gastrocolic ligament.

ARTERIAL SUPPLY

The superior mesenteric artery arises immediately inferior to the celiac trunk at the L1 vertebral level, courses anteriorly and inferiorly at an acute angle, and supplies the midgut through the following branches (Figure 10-1B):

- **Inferior pancreaticoduodenal arteries.** Supplies the distal duodenum and pancreatic head; superior and inferior pancreaticoduodenal arteries form an anastomosis between foregut and midgut.
- **Jejunal arteries.** Supplies the jejunum via seven to nine branches with a few large arterial arcades and long vasa recti.
- **Ileal arteries.** Supplies the ileum via seven to nine branches with numerous short arterial arcades and short vasa recti.
- **Middle colic artery.** Supplies part of the transverse colon; forms anastomoses with the left and right colic arteries in the marginal artery (of Drummond).

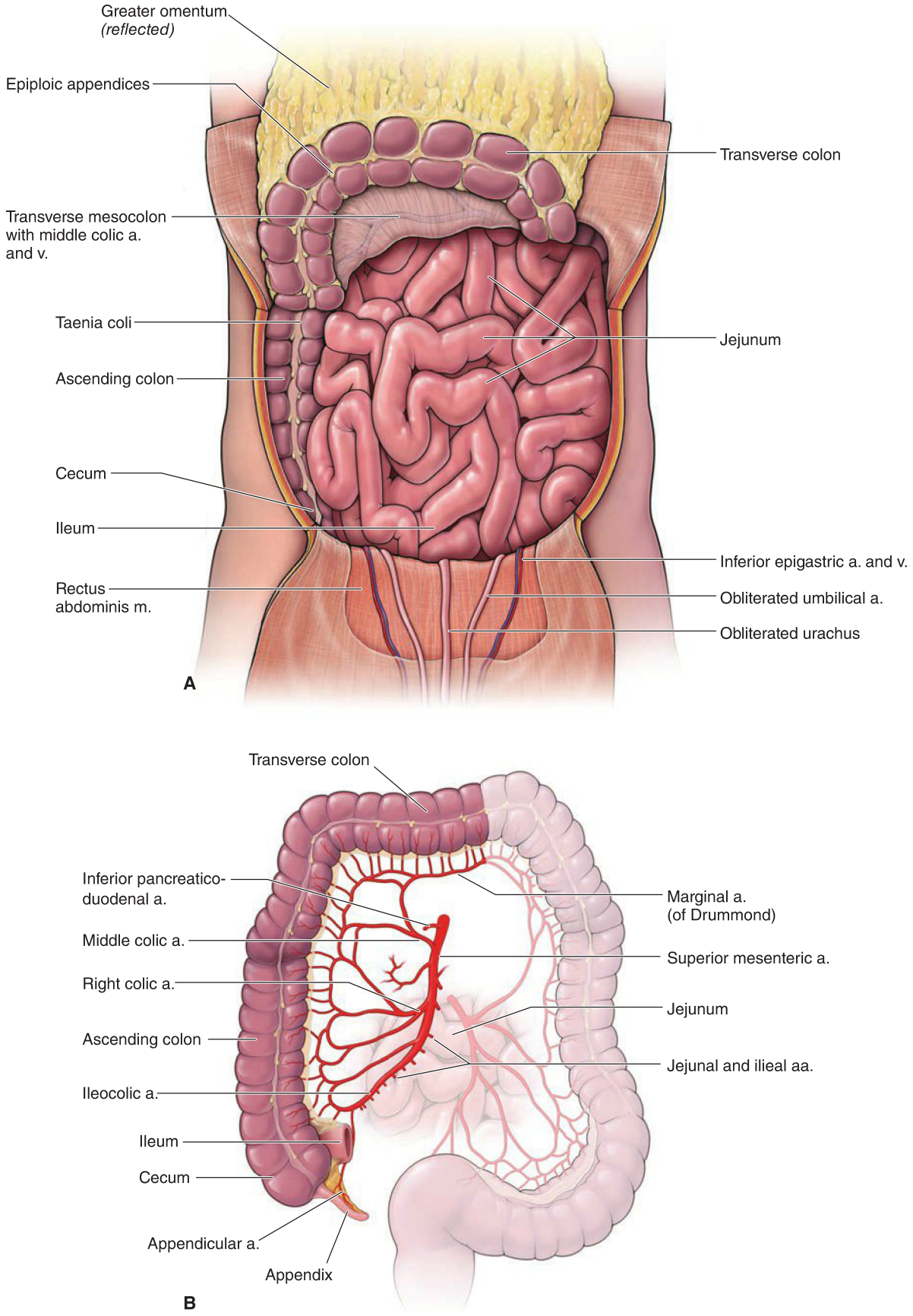

Figure 10-1: A. Midgut with the greater omentum reflected superiorly and the anterior abdominal wall reflected inferiorly. **B**. Primary blood supply to the midgut is through the superior mesenteric artery.

- **Right colic artery.** Supplies the ascending colon; forms anastomoses with the ileocolic and middle colic arteries in the marginal artery (of Drummond).
- **Ileocolic artery.** Supplies the cecum; forms anastomoses with the ileal and right colic arteries.
  - **Appendicular artery.** A branch off the ileocolic that courses within the mesoappendix and supplies the appendix.

LYMPHATICS

Lymph is drained from organs of the gastrointestinal (GI) tract to the lymph nodes along the arterial supply to that organ. Typically this means the next set of lymph nodes is located at the origin of the artery to an organ. As such, lymph from midgut organs drains into the:

- **Superior mesenteric lymph nodes** surrounding the superior mesenteric artery.

From the superior mesenteric lynph nodes, lymph passes to the celiac nodes, cisterna chyli, the thoracic duct and its termination in the formation of the left brachiocephalic vein.

HINDGUT

BIG PICTURE

The hindgut consists of the distal half of the transverse colon, descending colon, sigmoid colon, and proximal rectum. Branches of the inferior mesenteric artery and vein provide vascular supply to the hindgut. Lymph from the hindgut drains into the inferior mesenteric nodes surrounding the inferior mesenteric artery.

TRANSVERSE, DESCENDING, AND SIGMOID COLON

- **Transverse colon.** The transverse colon transitions from midgut to hindgut somewhere between the left and right colic flexures (Figure 10-2A).
- **Descending colon.** The colon continues vertically down the left wall of the abdomen as the descending colon. The parietal peritoneum covers only the anterior surface of the descending colon, and thus the descending colon is considered a secondary retroperitoneal structure.
- **Sigmoid colon.** The continuation of the descending colon as it courses into the left side of the pelvis, making an "S shape." The curving nature of the sigmoid colon enables gases to be stored in the superior arch, thus expelling gas without defecating is possible.
  - **Sigmoid mesocolon.** A fold of peritoneum that attaches the sigmoid colon to the pelvic wall causing the sigmoid colon to be intraperitoneal; sigmoid and superior rectal vessels course between the layers.

ARTERIAL SUPPLY

The inferior mesenteric artery arises at the L3 vertebral level and supplies the hindgut through the following branches (Figure 10-2B):

- **Left colic artery.** Supplies the descending colon; forms anastomoses with the middle colic and sigmoidal arteries.
- **Sigmoidal arteries.** Supplies the sigmoid colon.
- **Superior rectal artery.** Supplies the superior region of the rectum.

LYMPHATICS

Lymph from the hindgut drains into the inferior mesenteric lymph nodes. From here lymph passes to the superior mesenteric nodes, celiac nodes, cisterna chyli, the thoracic duct and its termination in the left brachiocephalic vein.

RECTUM AND ANUS

- **Rectum.** The rectum is the terminal, straight portion of the colon and becomes the anal canal as it traverses through the pelvic floor muscles. Unlike other portions of the colon, the rectum lacks taeniae coli. The rectum has a unique neurovascular supply:
  - **Arteries.** Supplied by the superior rectal, middle rectal, and inferior rectal arteries.
  - **Veins.** Drained by the hepatic portal system (superior rectal vein) and caval system (middle and inferior rectal veins to the internal iliac vein).
  - **Lymphatics.** Lymph follows the arteries retrograde in the following way:
    - **Inferior mesenteric nodes.** Lymph from the upper part of the rectum follows the path of the superior rectal artery into nodes surrounding the inferior mesenteric artery.
    - **Internal iliac nodes.** Lymph from the middle part of the rectum follows the path of the middle rectal artery into nodes surrounding the internal iliac artery.
    - **Inguinal nodes.** Lymph from the lower part of the rectum follows the path of the inferior rectal and along the internal pudendal artery into inguinal lymph nodes.
- **Anus.** The transition from sigmoid colon to rectum occurs at approximately the **S3 vertebral level**, where the rectum is covered anteriorly by parietal peritoneum and thus is a retroperitoneal structure.

The **marginal artery (of Drummond)** is an arterial anastomosis between the superior and inferior mesenteric arteries. The marginal artery courses within the mesentery and parallels the ascending, transverse, and descending colon. The anastomosis is so complete that during the repair of an aortic aneurism, the inferior mesenteric artery often will not be regrafted to the aorta because the marginal artery will supply blood to the hindgut via the superior mesenteric artery.

Near the left iliac fossa, the descending colon continues as the **sigmoid colon**, which is an intraperitoneal structure. The vascular supply of the sigmoid colon is via **sigmoid arteries** from the inferior mesenteric artery.

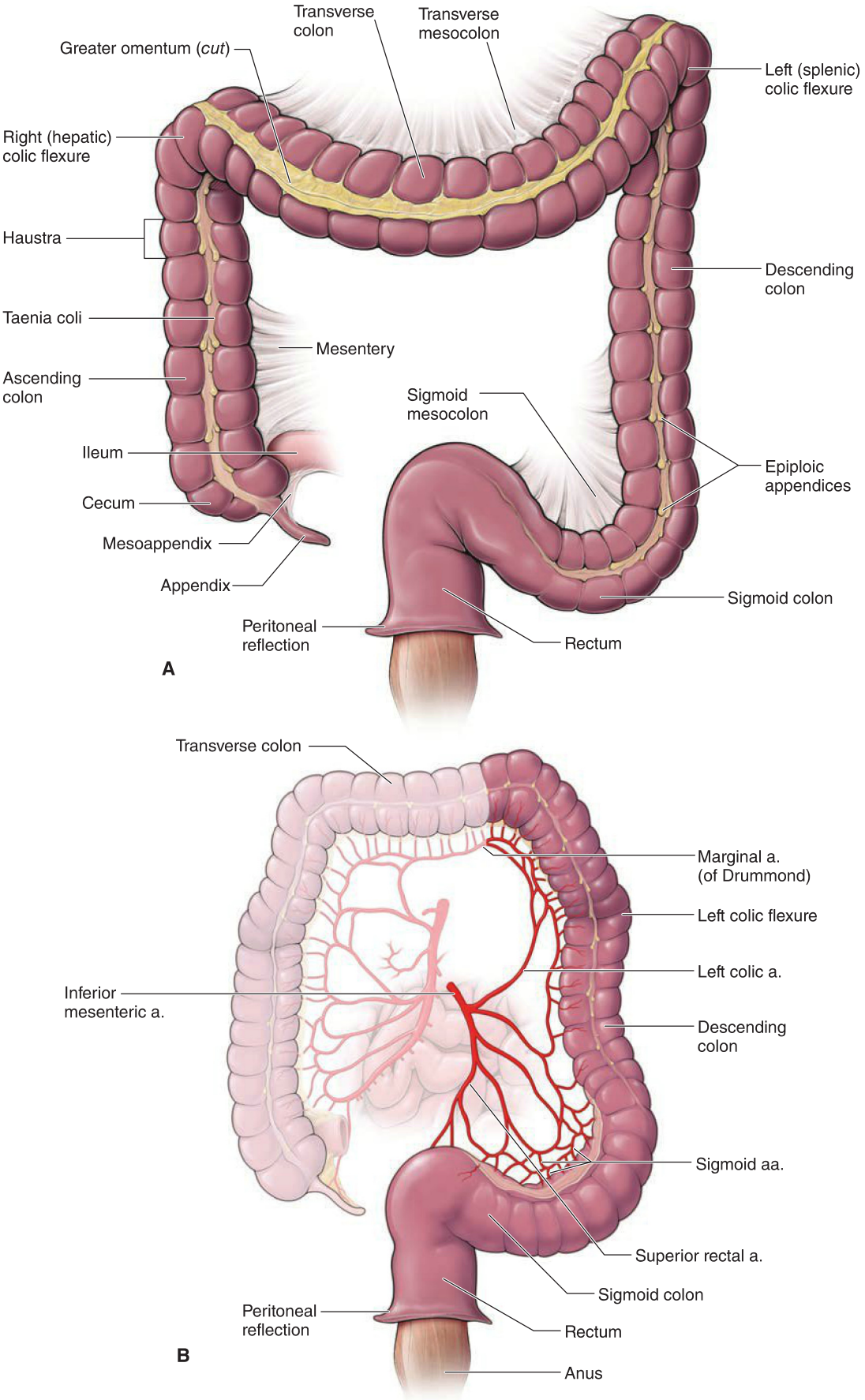

Figure 10-2: A. Hindgut with the small intestine removed. **B**. Primary blood supply to the hindgut is through the inferior mesenteric artery.

INNERVATION OF THE GI TRACT

BIG PICTURE

Autonomic innervation of the foregut and midgut is accomplished via the celiac and superior mesenteric ganglia and plexuses, respectively. These plexuses receive sympathetic innervation via the greater and lesser splanchnic nerves and parasympathetic innervation via the vagus nerves. Autonomic innervation of the hindgut is accomplished via the inferior mesenteric ganglia and plexus. This plexus receives sympathetic innervation via lumbar splanchnic nerves and parasympathetic innervation via pelvic splanchnic nerves (Figure 10-3).

GI TRACT SYMPATHETIC INNERVATION

Sympathetic motor innervation to the GI tract decreases motility, peristalsis, sphincter muscle contraction, absorption, and glandular secretions, in addition to causing vasoconstriction. Sympathetic innervation to the GI tract is accomplished via the following nerves:

- **Greater splanchnic nerve.** Has preganglionic sympathetic neurons from T5–T9 spinal cord levels to the prevertebral plexus (celiac and superior mesenteric ganglia and plexuses); innervates the foregut and associated organs.
- **Lesser splanchnic nerve.** Has preganglionic sympathetic neurons from T10–T11 spinal cord levels to the prevertebral plexus (celiac and superior mesenteric ganglia or plexuses); innervates the midgut.
- **Least splanchnic nerve.** Has preganglionic sympathetic neurons from the T12 spinal cord level to the prevertebral plexus (aorticorenal and inferior mesenteric ganglia or plexuses); innervates the kidney and adrenal gland.
- **Lumbar splanchnic nerve.** Has preganglionic sympathetic neurons from the L1–L2 spinal cord level to the prevertebral plexus (inferior mesenteric and inferior hypogastric ganglia or plexuses); innervates the hindgut.

GI TRACT PARASYMPATHETIC INNERVATION

Parasympathetic motor innervation increases GI tract motility, absorption, smooth muscle contraction, and glandular secretions. In addition, parasympathetic motor innervation relaxes the sphincter muscles. Parasympathetic innervation to the GI tract is accomplished via the following:

- **Vagus nerve (CN X).** Has preganglionic parasympathetic neurons from the medulla to the prevertebral plexuses and accompanies sympathetic neurons to regions of the foregut and midgut.
- **Pelvic splanchnic nerves.** Have preganglionic parasympathetic neurons from the **S2–S4 spinal cord levels** to the prevertebral plexus (inferior hypogastric plexus) where they provide innervation to the hindgut and pelvic and perineal organs.

Appendicitis. When the appendix becomes inflamed. Sensory neurons from the visceral peritoneum of the appendix signal the CNS that the appendix is inflamed. These signals are transmitted via **visceral sensory neurons** in the **lesser splanchnic nerve**, which enters the **T10 vertebral level** of the spinal cord. However, somatic sensory neurons from the skin around the umbilicus also enter at the T10 vertebral level of the spinal cord. Because both visceral and somatic neurons enter the spinal cord at the same level and synapse in the same region, the brain interprets the inflammation from the appendix as if the pain originated in the region of the umbilicus. This phenomenon is known as **referred pain**.

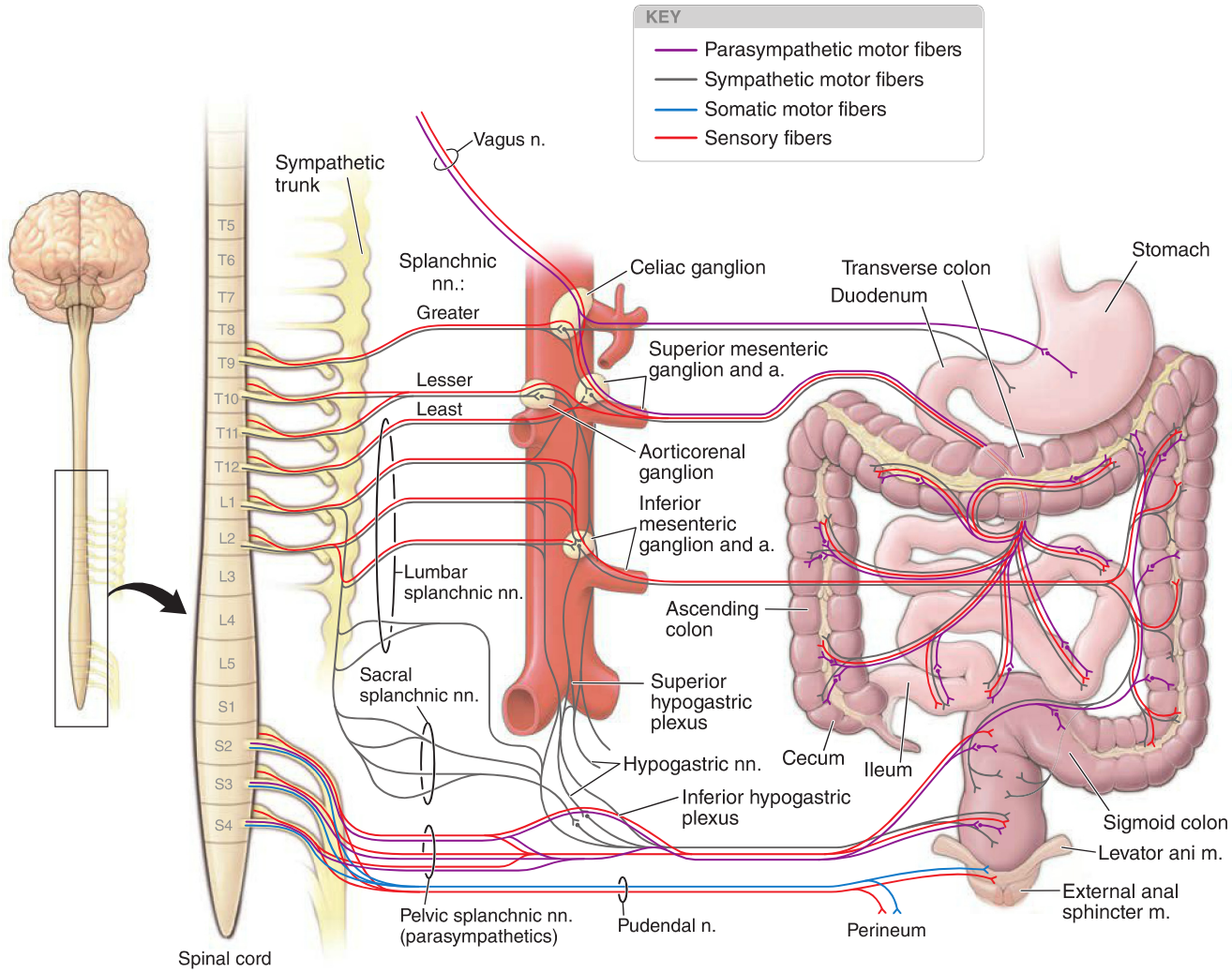

Figure 10-3: Innervation of the foregut, midgut, and hindgut.

HEPATIC PORTAL SYSTEM

BIG PICTURE

The hepatic portal system is a system of veins responsible for transporting blood from most of the GI tract to the liver for metabolic processing before the blood returns to the heart.

HEPATIC PORTAL SYSTEM OVERVIEW

In the systemic circulation, blood is transported from the heart through one set of capillaries before returning to the heart. For example:

- Heart-artery-arteriole-capillary-venule-vein-heart

In contrast, the portal system transports blood through two capillary beds in tandem before returning to the heart. For example:

- Heart-artery-arteriole-capillary #1-venule-vein-venule-capillary #2-venule-vein-heart

The hepatic portal system (often abbreviated to the portal system) is a collection of veins that drain blood from capillaries of the GI tract, liver, gallbladder, pancreas, and spleen (i.e., capillary #1) eventually into the portal vein, which delivers the blood into the liver's hepatic sinusoids (capillary #2). The purpose of hepatic sinusoids is to remove nutrients and filter toxins from the blood prior to its entering the IVC en route to the heart. Therefore, all ingested nutrients, medicines and toxins from the GI tract pass through the liver via the hepatic portal system before returning to the heart.

BLOOD SUPPLY TO THE LIVER

The liver is unique in that it receives blood from two sources:

1. **Portal vein.** Nutrient-rich deoxygenated blood from the GI tract and associated organs.
2. **Proper hepatic artery.** Oxygenated blood from the celiac trunk.

Blood from the portal vein and hepatic artery proper enter tiny vascular channels known as **hepatic sinusoids** where the blood mixes and percolates around **hepatocytes**. Hepatocytes detoxify the blood, metabolize fats, carbohydrates, and drugs, in addition to producing bile. Blood exits the hepatic sinusoids into a **terminal hepatic venule**, which empties into the **hepatic veins** and ultimately into the **IVC**, which passes through the diaphragm before entering the right atrium of the heart.

First Pass Effect. Oral drugs travel throughout the GI tract, where they are absorbed by the small intestine. These drugs then travel to the liver via the hepatic portal system, where they are metabolized before entering the systemic circulation. Because of hepatic metabolism, the concentration of oral drugs is greatly reduced before entering the systemic circulation. This is known as the first pass effect. Therefore, drugs that are inactivated by the liver must be administered by a different method. For example, nitroglycerin is administered sublingually (absorption under the tongue) because, if swallowed, the liver inactivates the drug before it can enter the systemic circulation.

VEINS OF THE PORTAL SYSTEM

Veins of the portal system generally mirror the arterial branches of the celiac trunk and the superior and inferior mesenteric arteries (Figure 10-4A). The splenic, superior mesenteric, and inferior mesenteric veins drain the organs of the embryological foregut, midgut, and hindgut, respectively.

- **Portal vein.** Collects blood from the foregut, midgut, and hindgut, including the spleen, pancreas, and gallbladder. The portal vein courses within the hepatoduodenal ligament deep to the hepatic artery and cystic duct. The portal vein is formed by the union of the superior mesenteric and splenic veins, deep to the neck of the pancreas.
  - **Right gastric vein.** Located with the lesser omentum and drains the distal portion of the lesser curvature of the stomach and pylorus directly in the portal vein.
  - **Left gastric vein.** Located with the lesser omentum and drains the distal esophagus and proximal portion of the lesser curvature of the stomach directly into the portal vein. The left gastric vein may contribute to esophageal varices in portal hyperstension.
  - **Cystic vein.** Drains the gallbladder into the portal vein.
  - **Paraumbilical veins.** Drain the anterior abdominal wall around the umbilicus. The veins course within the ligamentum teres hepatis directly into the portal vein. Paraumbilical veins anastomose with branches of the superior and inferior epigastric veins. Paraumbilical veins may cause *caput medusae* in portal hypertension.
  - **Splenic vein.** Courses deep and within the pancreas and drains blood from the foregut, spleen, pancreas, and part of the stomach. The splenic vein and ultimately the spleen can be engorged with blood during portal hypertension resulting in splenomegaly. The splenic vein receives the following tributaries:
    - **Left gastroomental vein.** Courses within the greater omentum and drains the greater curvature of the stomach.
    - **Pancreatic veins.** Drain the body and tail of the pancreas.
    - **Inferior mesenteric vein.** Drains hindgut organs and drains directly into the splenic vein. The inferior mesenteric vein has the following tributaries:
      - **Left colic vein.** Drains the descending colon.
      - **Sigmoid veins.** Drain the sigmoid colon.
      - **Superior rectal vein.** Drains the upper rectum and forms anastomoses with the middle and inferior rectal veins. The superior rectal vein may engorge with blood during portal hypertension resulting in internal hemorrhoids.
  - **Superior mesenteric vein.** Drains blood from the midgut and contributes to the formation of the hepatic portal vein. Has the following tributaries:
    - **Right gastroomental vein.** Courses within the greater omentum and drains the distal portion of the greater curvature of the stomach.

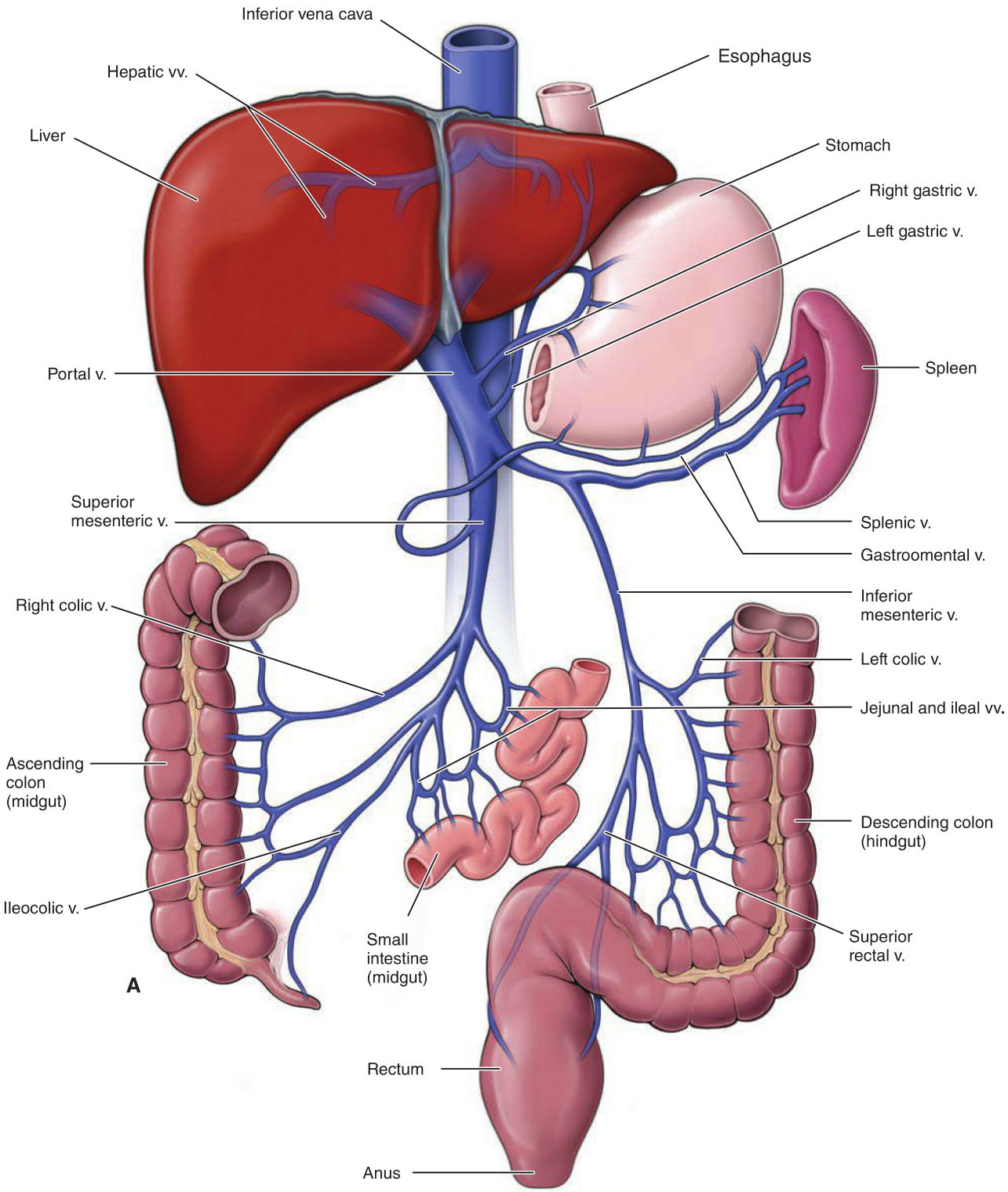

Figure 10-4: A. The portal venous system.

- **Jejunal veins.** Drain the jejunum.
- **Ileal veins.** Drain the ileum.
- **Ileocolic vein.** Drains the distal ileum and cecum.
- **Right colic vein.** Drains the ascending colon.
- **Middle colic vein.** Drains the transverse colon.

PORTAL–CAVAL ANASTOMOSES

To better understand the portal–caval anastomoses, recall that veins in the abdomen return blood to the heart via two routes (Figure 10-4B):

- **Portal system.** Veins from the GI tract, gallbladder, pancreas, and spleen transport blood to the liver before entering the IVC and ultimately returning to the heart.
- **Caval system.** Veins from the lower limbs, pelvis, and posterior abdominal wall transport blood directly into the IVC before the blood returns to the heart.

Portal–caval anastomoses are located at tissues in the abdomen that are drained by both the portal and systemic (-caval) veins. The principal portal–caval anastomoses are as follows:

1. **Distal end of the esophagus.** Blood drains into azygos veins and to the SVC and into the left gastric vein into the hepatic portal vein. Normally in the adult, most of the venous drainage is from the azygos veins.
2. **Anterior abdominal wall.** Blood from the tissue surrounding the umbilicus drains into the superior and inferior epigastric veins and to the SVC and IVC, respectively, and into the paraumbilical veins into the hepatic portal vein. Normally in the adult, most of the venous drainage is from the epigastric veins.
3. **Rectum.** Blood from the rectum drains into the middle and inferior rectal veins and on to the internal iliac vein as well as the superior rectal vein, which empties into the hepatic portal system.

Portal hypertension. When hepatocytes are damaged (e.g., due to disease, alcohol, or drugs), the liver cells are replaced by fibrous tissue, which impedes the flow of blood through the liver (cirrhosis). When the hepatic portal system is blocked, the return of blood from the GI tract and spleen is impeded, resulting in portal hypertension (veins that usually flow into the liver are blocked). Consequently, blood pressure in the blocked veins increases, causing them to dilate and gradually reopen previously closed connections with the caval system. Veins in the distal portion of the esophagus begin to enlarge (**esophageal varices**); veins in the rectum begin to enlarge (**internal hemorrhoids**); and in chronic cases, the veins of the paraumbilical region enlarge (**caput medusa**).

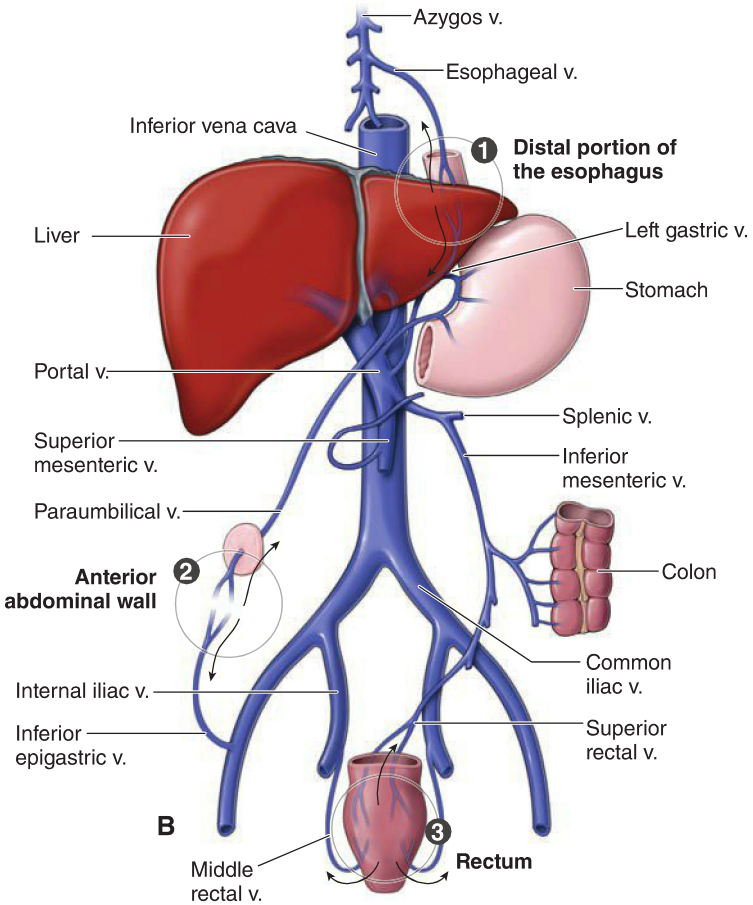

Figure 10-4: (*continued*) **B**. The three primary portal–caval anastomoses.

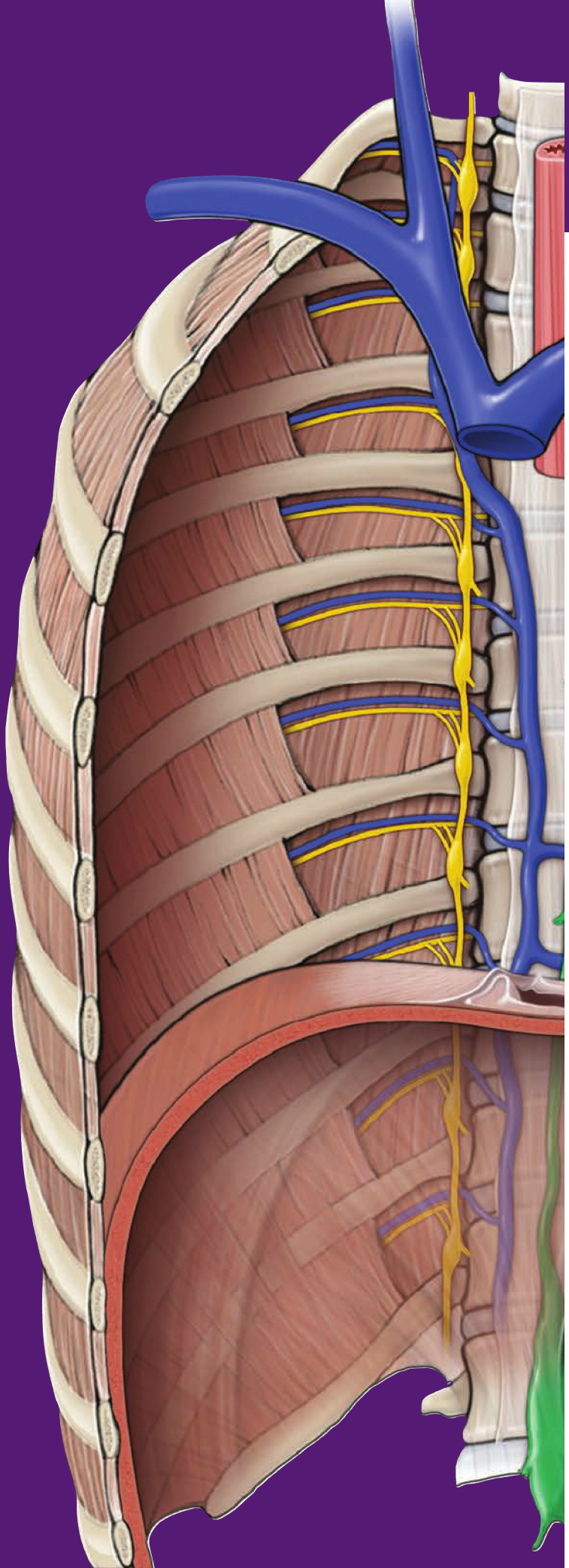

CHAPTER 11

POSTERIOR ABDOMINAL WALL

Posterior Abdominal Wall Muscles and Nerves 120
Posterior Abdominal Wall Vessels 122
Posterior Abdominal Wall Autonomics 124
Adrenal Glands, Kidneys, and Ureters 126

POSTERIOR ABDOMINAL WALL MUSCLES AND NERVES

BIG PICTURE

The diaphragm (principal respiratory muscle) and the psoas major, iliacus, and quadratus lumborum muscles (trunk and lower limb muscles) form the posterior abdominal wall. The ventral rami from the subcostal nerve and lumbar spinal nerves provide somatic innervation to the abdominal wall and lower limb muscles and skin.

MUSCLES AND FASCIA

The muscles of the posterior abdominal wall are as follows (Figure 11-1):

- **Diaphragm.** A dome-shaped muscle that separates the abdominal and thoracic cavities.
  - **Origin.** The internal surface of the xiphoid process, ribcage, and lumbar vertebrae via the left and right crura.
  - **Insertion.** An aponeurosis called the **central tendon** (**of the diaphragm**); the right dome of the diaphragm is slightly higher than the left because of the liver.
  - **Innervation.** Each half of the diaphragm is innervated by the right or left phrenic nerve (C3–C5).
  - **Action.** Primary muscle of respiration; additionally, the diaphragm increases intra-abdominal pressure for defecation, urination, vomiting, and childbirth.
  - **Apertures.** The diaphragm has the following openings:
    - **Caval hiatus (T8).** Transmits the IVC.
    - **Esophageal hiatus (T10).** Transmits the esophagus, vagus nerves, and left gastric vessels.
    - **Aortic hiatus (T12).** Transmits the aorta, thoracic duct, azygos and hemiazygos veins, and sympathetic trunk.
- **Quadratus lumborum muscle**
  - **Attachments.** Iliac crest, lumbar transverse processes, and the 12th rib.
  - **Actions.** Laterally flexes the vertebral column.
  - **Innervation.** Branches from T12-L4 ventral rami.
- **Psoas major muscle**
  - **Attachments.** Courses from L1–L5 vertebrae, deep to the inguinal ligament to the lesser trochanter of the femur.
  - **Actions.** Flexes the hip joint.
  - **Innervation.** Branches from the L2 ventral ramus.
- **Iliacus muscle**
  - **Attachments.** Iliac fossa and lesser trochanter of the femur. Between its attachments, the iliacus muscle courses deep to the inguinal ligament and joins with the psoas major muscle to attach to the lesser trochanter of the femur. The combination of these two muscles in the thigh is often referred to as the **iliopsoas muscle**.
  - **Actions.** Flexes the hip joint.
  - **Innervation.** Femoral nerve (L2–L4).

SOMATIC NERVES

The somatic nerves of the posterior abdominal wall are the ventral rami of the subcostal and lumbar spinal nerves. These nerves for the most part course between the internal oblique and transverse abdominis muscles (Figure 11-1).

- **Subcostal nerve (T12).** Arises from the T12 ventral ramus.
  - **Motor.** Segmentally supplies abdominal body wall muscles (external oblique, internal oblique, transverse abdominis, and rectus abdominis).
  - **Sensory.** Anterolateral region of the T12 dermatome.
- **Iliohypogastric nerve (L1).** Arises from the L1 ventral ramus.
  - **Motor.** Internal oblique and transverse abdominis muscles.
  - **Sensory.** Skin in the hypogastric region.
- **Ilioinguinal nerve (L1).** Arises from the L1 ventral ramus; after coursing through the body wall, enters the inguinal canal laterally and then exits the superficial inguinal ring to enter the spermatic cord.
  - **Motor.** Internal oblique and transverse abdominis muscles.
  - **Sensory.** Superior-medial region of the thigh and anterior surface of the scrotal sac and labia majora.
- **Genitofemoral nerve (L1–L2).** Arises from the L1 and L2 ventral rami, pierces through the psoas major muscle, and courses along its anterior surface where this nerve bifurcates into the following two branches:
  - **Genital branch.** Traverses the deep inguinal ring, courses through the inguinal canal, and exits the superficial inguinal ring. Supplies the cremaster muscle and skin over the scrotum. In females, the genital branch innervates the skin of the mons pubis and labia majora.
  - **Femoral branch.** Provides sensation over the femoral triangle.
- **Femoral nerve (L2–L4).** Emerges from the lateral surface of the psoas major muscle and courses deep to the inguinal ligament to enter the femoral triangle of the thigh.
  - **Motor.** Anterior compartment group of muscles of the thigh ("quads"), which extend the joint knee.
  - **Sensory.** Anterior surface of the thigh (anterior cutaneous nerves of the thigh) and medial side of the leg (saphenous nerve branch).
- **Lateral femoral cutaneous nerve (L2–L3).** Emerges along the lateral border of the psoas major muscle, crosses the iliacus muscle, and enters the thigh deep to the inguinal ligament. Also called the lateral cutaneous nerve of the thigh.
  - **Sensory.** Lateral aspect of the thigh.
- **Obturator nerve (L2–L4).** Emerges from the medial surface of the psoas major muscle and traverses the obturator foramen to enter the medial compartment of the thigh.
  - **Motor.** Medial compartment muscles of the thigh, which adduct the hip joint.
  - **Sensory.** Medial aspect of the thigh.

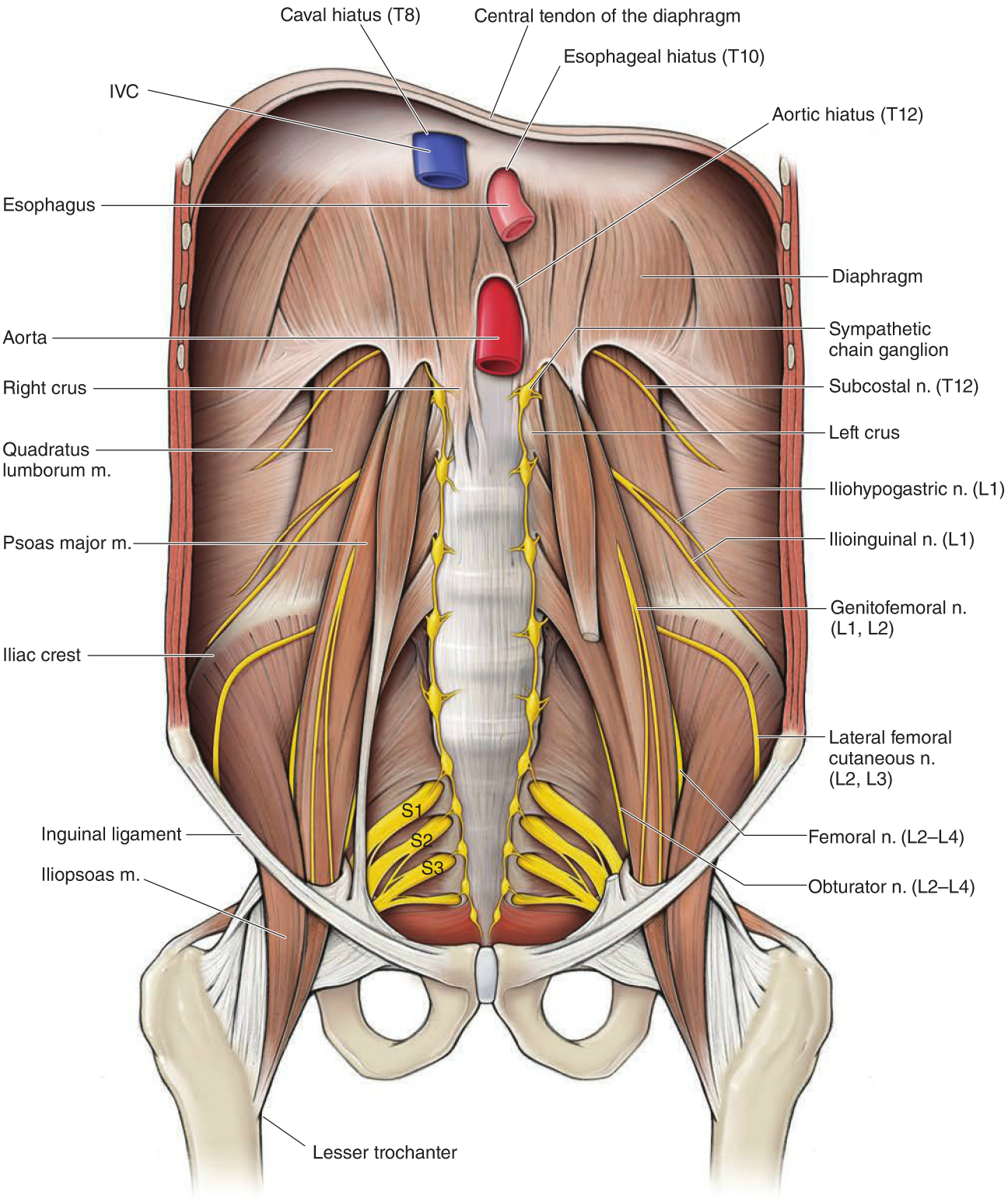

Figure 11-1: Muscles and nerves of the posterior abdominal wall.

- **Lumbosacral trunk (L4–L5).** Branches of the L4 and L5 ventral rami that unite and course inferiorly over the pelvic brim into the pelvic cavity and contribute to the sciatic nerve (L4–S3).

Cremasteric reflex. A reflex is a predictable and dependable way of testing a sensory-motor loop of a spinal level. To test the L1 spinal cord level, the cremasteric reflex is used: stroking the superior-medial part of the thigh results in contraction of the cremasteric muscle on the same side. The ilioinguinal nerve senses the stroke on the thigh and relays that information to the L1 spinal cord level, which then relays a motor impulse along the genitofemoral nerve, causing contraction of the cremasteric muscle. An absent cremasteric reflex also is a sensitive indicator for a male with testicular torsion.

POSTERIOR ABDOMINAL WALL VESSELS

BIG PICTURE

Paired arteries and veins of the aorta and IVC, respectively, supply the body wall and organs in the retroperitoneal space. Unpaired arteries arising from the anterior surface of the abdominal aorta supply the GI tract. The aorta and IVC terminate in the pelvis as the common iliac arteries and veins, respectively. These vessels branch to supply the pelvis and perineum (internal iliac branch) and lower limb (external iliac branch).

ABDOMINAL AORTA

The aorta enters the abdomen from the thorax by traversing the aortic hiatus of the diaphragm at the **T12 vertebral level**. The aorta courses along the anterior surface of vertebral bodies to the left of the IVC. The abdominal aorta has the following branches, from superior to inferior (Figure 11-2):

- **Inferior phrenic arteries.** The first paired branches of the aorta in the abdominal cavity; supply the inferior surface of the diaphragm.
- **Middle suprarenal arteries.** One of the three pairs of arteries supplying the adrenal glands.
- **Gonadal arteries.** Paired arteries that supply the gonads.
- **Lumbar arteries.** Paired arteries that supply the abdominal wall (akin to the intercostal arteries of the thorax).
- **Celiac trunk.** Unpaired artery that supplies the foregut, liver, gall bladder, pancreas, and spleen.
- **Superior mesenteric artery (SMA).** Unpaired artery that is located immediately below the celiac trunk; supplies the midgut.
- **Inferior mesenteric artery (IMA).** Unpaired artery that arises superior to the bifurcation of the abdominal aorta into the common iliac arteries; supplies the hindgut.
- **Common iliac arteries.** At the L4 vertebral level, the abdominal aorta bifurcates into the left and right common iliac arteries.

INFERIOR VENA CAVA

The inferior vena cava (IVC) is formed by the union of the common iliac veins, ascends along the vertebral bodies to the right of the abdominal aorta, and drains the abdominal wall, perineum, lower limbs, and organs in the retroperitoneal space. The IVC also drains blood from the GI tract by way of the hepatic portal system. The IVC receives the following tributaries:

- **Right inferior phrenic vein.** Drains inferior surface of the diaphragm into the IVC.
- **Hepatic veins.** Before entering the thoracic cavity, the IVC courses within a groove on the posterior surface of the liver. This portion of the IVC has three **hepatic veins** (left, middle, and right), which receive blood from the hepatic portal system.
- **Right renal vein.** Drains the right kidney.
- **Right suprarenal vein.** Drains the right adrenal gland via two to three tributaries.
- **Left renal vein.** Drains the left kidney, is longer than the right renal vein, and has the following tributaries (the IVC is not bilaterally symmetrical and as such the right counterparts to the following veins drain directly into the IVC):
  - **Left inferior phrenic vein.** Drains the inferior surface of the diaphragm.
  - **Left suprarenal vein.** Drains the left adrenal gland.
  - **Left gonadal vein.** Drains the left gonad (testicle/ovary) into the left renal vein.
- **Right gonadal vein.** Drains the right gonad into the IVC. In males, the gonadal veins often form a pampiniform plexus of veins around the gonadal artery.
- **Lumbar veins.** Drain the abdominal wall.
  - **Ascending lumbar veins.** Ascend along transverse processes of the lumbar vertebrae and form anastomoses with lumbar veins. These ascending veins course deep to the diaphragm and upon entering the thorax become the azygos vein (on the right) and hemiazygos vein (on the left).

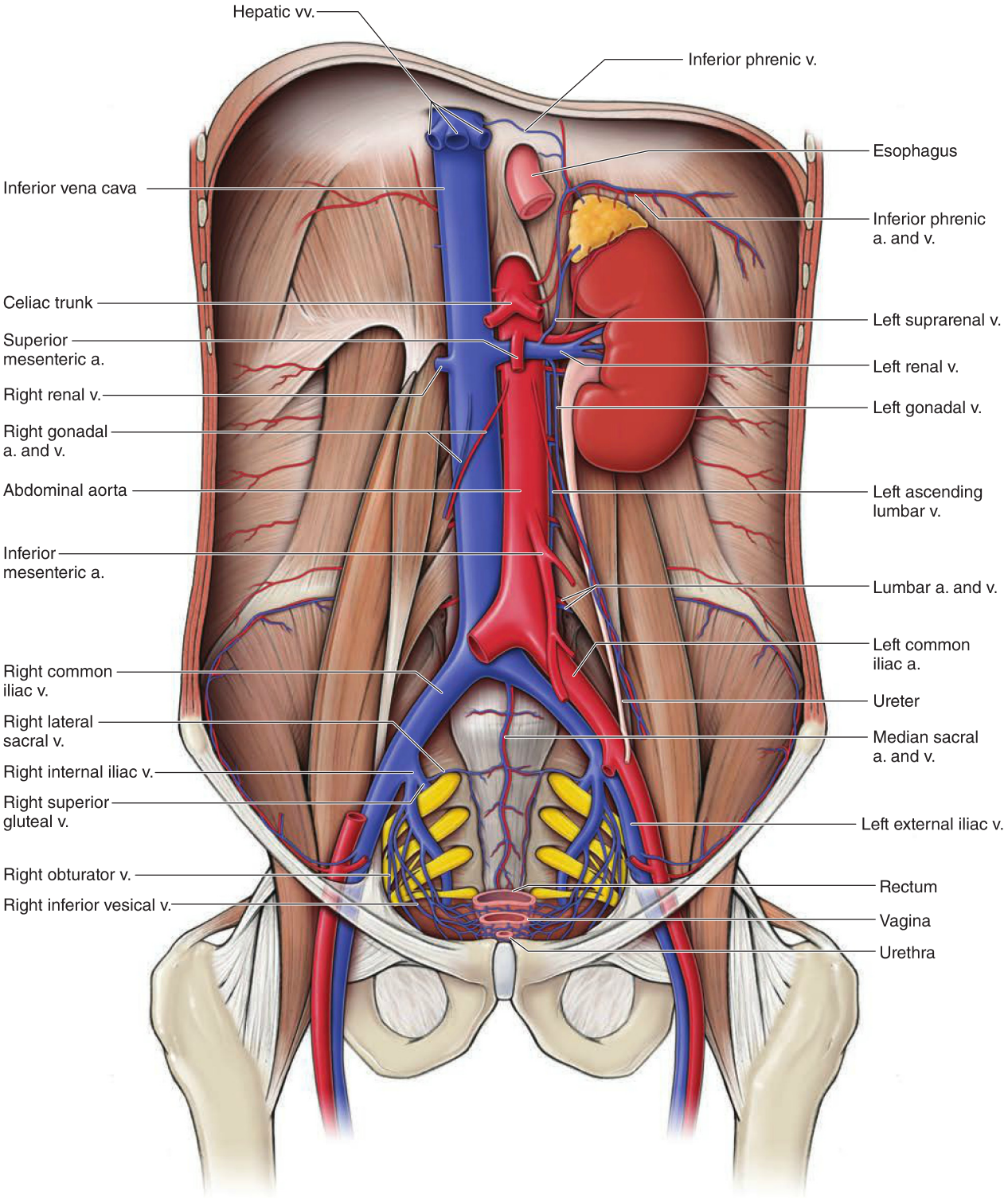

Figure 11-2: Arteries and veins of the posterior abdominal wall in a female.

POSTERIOR ABDOMINAL WALL AUTONOMICS

BIG PICTURE

The prevertebral plexus is a network of sympathetic and parasympathetic fibers that innervate the digestive, urinary, and reproductive systems. Sympathetic nerves contribute to the prevertebral plexus via splanchnic nerves from the sympathetic trunk. Parasympathetic nerves contribute to the prevertebral plexus via the vagus nerve (CN X) and pelvic splanchnic nerves from the S2–S4 spinal nerves (Figure 11-3).

SYMPATHETIC CONTRIBUTIONS TO THE PREVERTEBRAL PLEXUS

The sympathetic trunk is located along the anterolateral surface of the vertebrae and is continuous in the thorax, abdomen, and pelvis. Each sympathetic ganglion has the cell bodies of postganglionic sympathetic neurons. The following splanchnic nerves convey preganglionic sympathetic and visceral afferent neurons between the sympathetic trunk and prevertebral plexus:

- **Greater splanchnic nerve.** Arises from the T5–T9 sympathetic ganglia and travels to the celiac ganglia.
- **Lesser splanchnic nerve.** Arises from the T10–T11 sympathetic ganglia and travels to the superior mesenteric and aorticorenal ganglia.
- **Least splanchnic nerve.** Arises from the T12 sympathetic ganglion and travels to the aorticorenal ganglia.
- **Lumbar splanchnic nerves.** Arise from the lumbar sympathetic ganglia and travels to the inferior mesenteric ganglia.
- **Sacral splanchnic nerves.** Arise from sacral sympathetic ganglia and travels to their corresponding side's inferior hypogastric plexus.

Recall that the preganglionic sympathetic neurons contributing to the lumbar and sacral sympathetic ganglia arise primarily from the T11–L2 spinal cord levels and descend via the sympathetic trunk to each of the lumbar and sacral sympathetic ganglia.

PARASYMPATHETIC CONTRIBUTIONS TO THE PREVERTEBRAL PLEXUS

The following nerves convey preganglionic parasympathetic and visceral afferent neurons:

- **Vagus nerve (CN X).** The right and left vagus nerves enter the abdomen as the anterior and posterior vagal trunks and enter the prevertebral plexus at the celiac plexus. Once inside the prevertebral plexus, parasympathetic and sympathetic neurons mix and course together to organs along the supplying arteries. The vagus nerve innervates foregut (and associated accessory digestive organs) and midgut.
- **Pelvic splanchnic nerves (S2–S4).** Preganglionic parasympathetic neurons originate in the S2–S4 levels of the spinal cord and course in the ventral root and rami and into the pelvic splanchnic nerves, which contribute to the inferior hypogastric plexus en route to innervate the distal part of the transverse colon, descending colon, sigmoid colon, and rectum, as well as the urinary and reproductive systems.

Recall that pre- and post-ganglionic parasymapthetic fibers synapse within the wall of the end organ.

PREVERTEBRAL GANGLIA AND PLEXUS

The **prevertebral (preaortic) ganglia and plexuses** consist of a network of autonomic neurons covering the abdominal aorta and extending into the pelvic cavity between the common iliac arteries. The prevertebral ganglia and plexuses transport autonomics associated with the digestive, urinary, and reproductive organs. The names of the parts of the prevertebral ganglia and plexuses are for their associated branch of the abdominal aorta:

- **Celiac ganglia and plexus.** Located around the celiac trunk and distributed along its branches. This plexus receives sympathetic input from the greater splanchnic nerve and parasympathetic input from the vagus nerve (recall that parasympathetic neurons course through the celiac ganglion en route to the viscera without synapsing). The celiac plexus innervates foregut, liver, gallbladder, pancreas, and spleen.
- **Superior mesenteric ganglion and plexus.** Located around the superior mesenteric artery and distributed along its branches. This plexus receives sympathetic input from the lesser splanchnic nerve and parasympathetic input from the vagus nerve. The superior mesenteric plexus innervates the midgut, kidneys, and adrenal glands.
- **Aorticorenal ganglia and plexuses.** Located at the origin of the renal arteries and distributed along their branches. This plexus receives sympathetic input from the least splanchnic nerve and parasympathetic input from the vagus nerve. The aorticorenal plexus innervates the kidneys and adrenal glands.
- **Inferior mesenteric ganglion and plexus.** Located around the inferior mesenteric artery and distributed along its branches. This plexus receives sympathetic input from lumbar splanchnic nerves and parasympathetic input from the pelvic splanchnic nerves. The inferior mesenteric plexus innervates the hindgut.
- **Superior hypogastric plexus.** Located inferior to the bifurcation of the aorta, between the common iliac arteries. The superior hypogastric plexus is a continuation of the prevertebral plexus into the pelvic cavity and receives contributions from lumbar splanchnic nerves (sympathetics). The superior hypogastric plexus continues inferiorly by bifurcating and becoming the left and right **hypogastric nerves**.
- **Inferior hypogastric plexus.** Located posterolateral to the bladder, seminal vesicles, and prostate in males and posterolateral to the bladder and cervix in females. The inferior hypogastric plexus receives contributions from the following:
  - **Sympathetics.** Preganglionic sympathetic neurons enter the inferior hypogastric plexus through the sacral splanchnic nerves.
  - **Parasympathetics.** Preganglionic parasympathetic neurons enter the inferior hypogastric plexus through the pelvic splanchnic nerves. Once parasympathetic neurons enter the inferior hypogastric plexus, some neurons ascend into the superior hypogastric plexus to innervate the hindgut. Some neurons exit the plexus to innervate the urinary and reproductive systems.

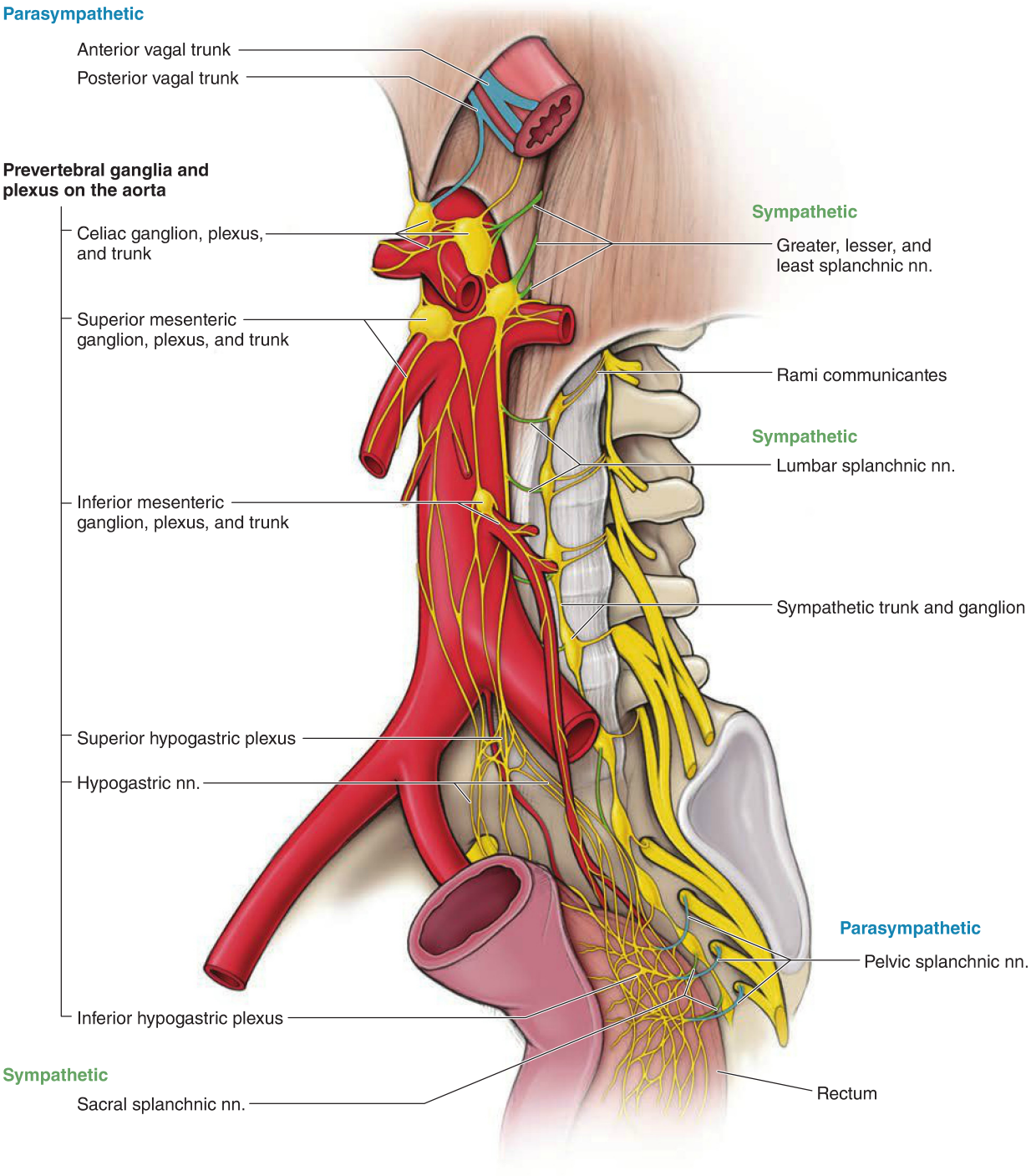

Figure 11-3: Anterolateral view of the autonomics of the posterior abdominal wall.

ADRENAL GLANDS, KIDNEYS, AND URETERS

BIG PICTURE

The adrenal (suprarenal) glands are responsible for regulating stress through the production and secretion of hormones such as glucocorticoids, mineralocorticoids, androgens. and catecholamines. The kidneys are the functional unit of the urinary system and filter a quarter of total cardiac output (1 L of blood) every minute. The ureters, urinary bladder, and urethra provide conduit and storage of urine.

ADRENAL GLANDS

The adrenal gland is located on the superior pole of the kidney and consists of the following (Figure 11-4):

- **Adrenal cortex.** Forms the outer region of the adrenal; regulated by the endocrine system (i.e., pituitary gland secretes ACTH). The cortex is subdivided into three regions:
  - **Zona glomerulosa.** Produces the mineral corticoid aldosterone, which regulates blood pressure and electrolytes.
  - **Zona fasciculata.** Produces the glucocorticoid cortisol, which is released in response to stress and low blood glucose.
  - **Zona reticularis.** Produces precursor androgens such as dehydroepiandrosterone (DHEA).
- **Adrenal medulla.** Forms the inner region of the adrenal gland and produces catecholamines, primarily epinephrine (adrenaline), and some norepinephrine (noradrenaline).
- **Arterial supply.** Superior, middle, and inferior adrenal arteries.
- **Venous drainage.** Right adrenal vein into IVC; left adrenal vein into left renal vein.
- **Regulation.** Hormones and nerves regulate the different regions of the adrenal gland.
  - **Adrenal cortex (hormone).** Regulated by adrenocorticotropic hormone (ACTH) from the pituitary gland.
  - **Adrenal medulla (nerves).** Regulated by sympathetic nerves.
    - Preganglionic sympathetic neurons travel from the T12 spinal cord level, within the least splanchnic nerve, through the aorticorenal ganglion to the adrenal medulla.
    - The adrenal medulla functions like a postganglionic sympathetic neuron, except instead of secreting epinephrine into a synapse (to act locally) epinephrine is secreted into the blood stream (to act systemically). Therefore, unlike other organs, only preganglionic sympathetic neurons enter the adrenal medulla.
    - **Epinephrine.** Increases heart rate, blood pressure, and glucose metabolism.

KIDNEYS

- **Topography.** Each kidney is about the size of a fist, weighs about 150 g, and is located in the retroperitoneal space at the T12–L3 vertebral levels. The right kidney is slightly lower than the left due to the physical presence of the liver. The kidneys serve as the functional unit of the urinary system (Figure 11-4).
- **Supportive kidney tissues.** The following connective tissue structures support the kidneys:
  - **Renal capsule.** Dense connective tissue intimately attached to each kidney.
  - **Perirenal fat.** Adipose tissue surrounding each kidney located between the renal capsule and renal fascia.
  - **Renal fascia.** A layer of connective tissue that encapsulates perirenal fat, kidney, and adrenal gland.
  - **Pararenal fat.** Adipose tissue superficial to the renal fascia; provides cushioning (protection).
- **Kidney structure.** When viewed in coronal section, each kidney has the following features:
  - **Renal cortex.** The superficial region, which consists of numerous blood vessels (causing its dark brown appearance). These blood vessels serve the nephrons, which are millions of tiny blood-filtering structures within each kidney.
    - **Renal columns.** Internal cortical projections that separate the renal pyramids.
  - **Renal medulla.** Formed by 12 to 18 conical structures, called **renal pyramids**, organized centrally in the kidney. The renal pyramids consist of collecting ducts, the loops of Henle, and capillaries. Extensions of the medulla, called medullary rays, are organized around the collecting tubules and project into the cortex. These tubes course from base to apex of the renal pyramid and thus give it a striped or striated appearance.
  - **Calyces.** The collecting ducts exit at the tips of the renal pyramids into spaces called **minor calyces**, into which urine flows. The minor calyces merge together to form the **major calyces**, which in turn merge in the **renal pelvis** and ultimately the **ureter**.
  - **Ureter.** Transports urine to the bladder; descends anterior to the psoas major muscle, over the bifurcation of the common iliac artery and into the pelvis.
- **Arterial supply.** Renal arteries arise as 90-degree branches from the abdominal aorta and deliver a quarter of the total cardiac output to the kidneys. Upon entering the hilum, the renal arteries divide into progressively smaller arteries as they travel through the medulla to the cortex to supply the nephrons.
- **Kidney functions.** Filters up to 180 L of blood per day, which results in toxins, metabolic wastes, and excess ions excreted in the urine. Kidneys simultaneously regulate the volume and chemical makeup of the blood by reabsorbing needed substances back into the bloodstream, and maintaining the proper balance of water, salts, acids, and bases.

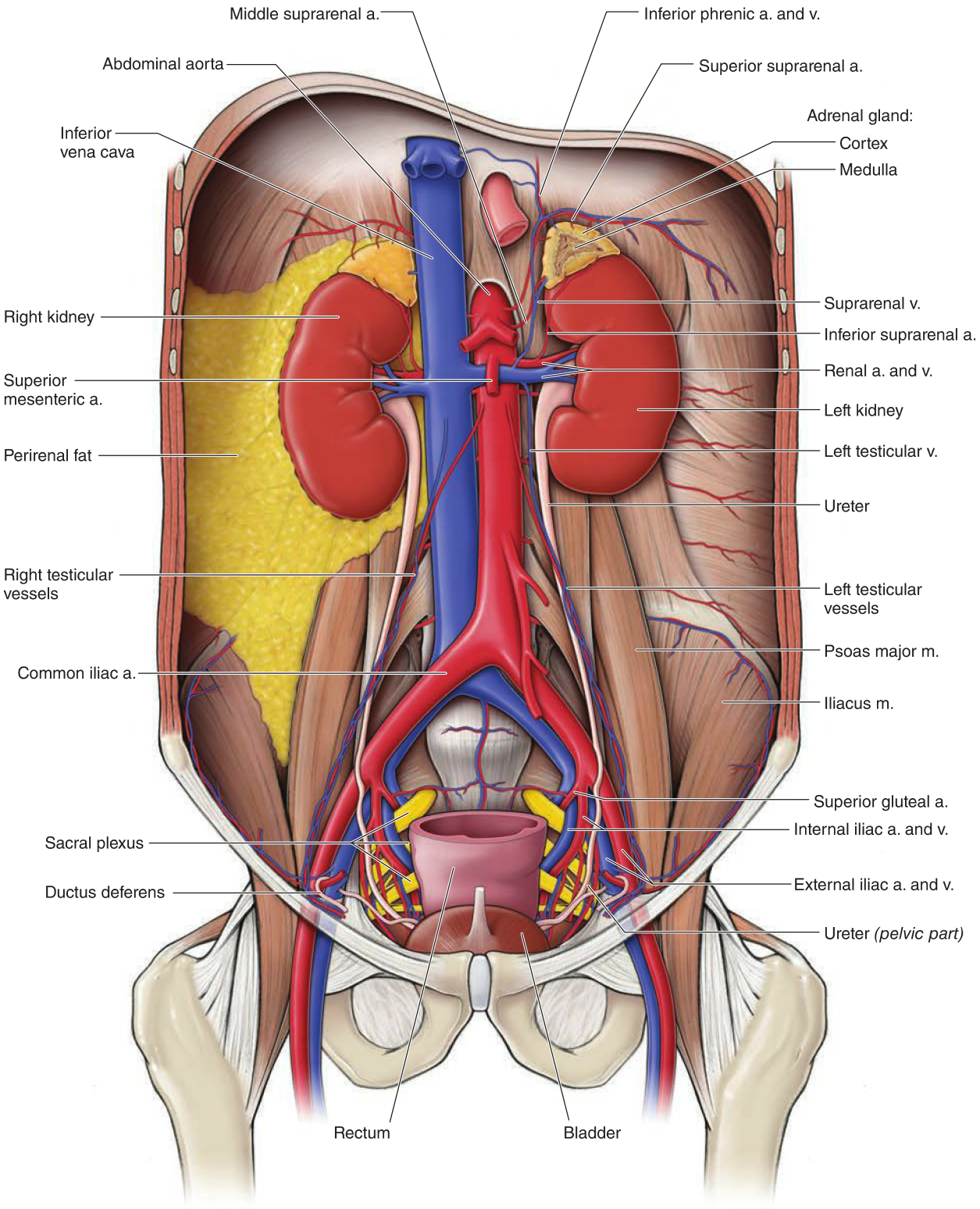

Figure 11-4: Kidneys, adrenals, and ureters in a male.

This page intentionally left blank

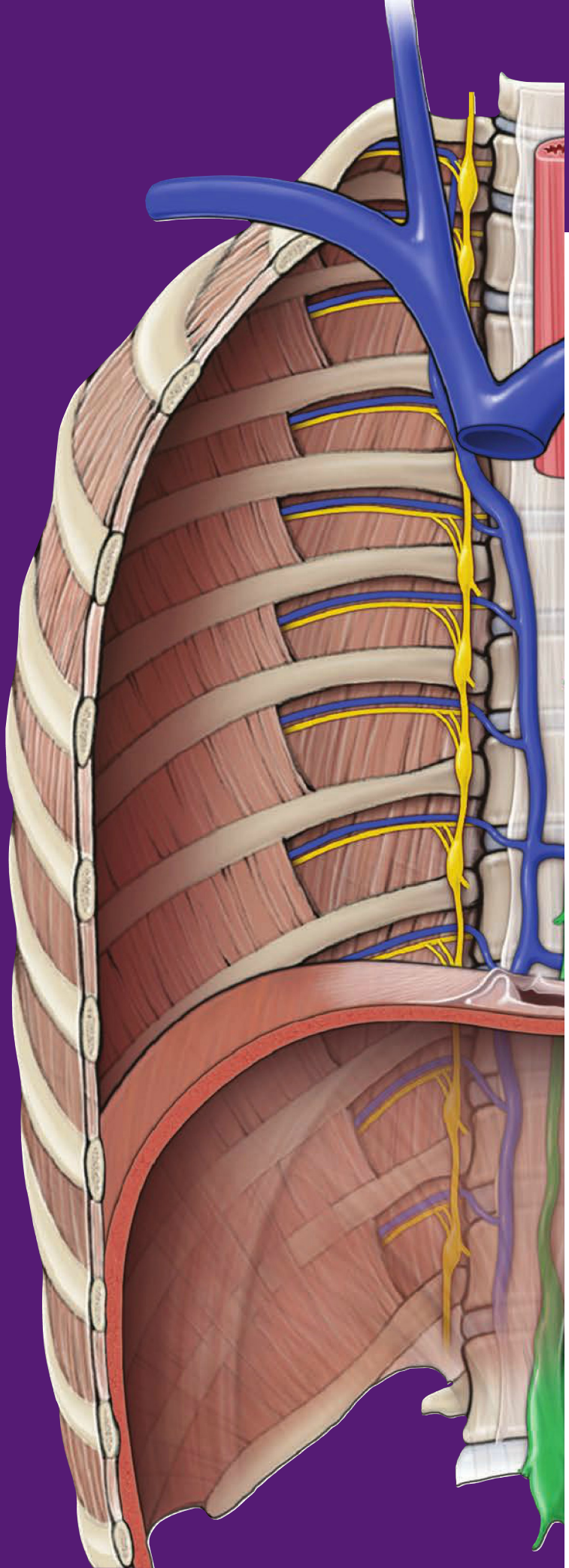

CHAPTER 12

PERINEUM AND PELVIS

Perineum 130
Pelvic Floor 132
Pelvic Vasculature 134
Pelvic Innervation 136
Rectum and Anal Canal. 138
Ureters and Urinary Bladder 140

PERINEUM

BIG PICTURE

The perineum is the diamond-shaped region inferior to the pelvic diaphragm (Figure 12-1A). The pubic symphysis, pubic arches, ischial tuberosities, and coccyx bound the perineum. An imaginary line between the ischial tuberosities divides the perineum into urogenital and ischioanal triangles. The pudendal nerve (S2–S4) and internal pudendal artery primarily supply the perineum. The urogenital triangle extends between the paired ischiopubic rami. The ischioanal triangle is the fat-filled area (ischioanal fossa) surrounding the anal canal and situated below the pelvic diaphragm.

PERINEAL FASCIA

The perineum consists of fascial layers (like other areas of the trunk) that divide the perineum into different spaces (Figure 12-1B-E). The perineal fascia is as follows:

- **Superficial perineal fascia.** The subcutaneous tissue in the perineal region. This tissue is similar to the superficial fascia of the lower anterior abdominal wall, which consists of a superficial fatty layer and deeper membranous layer.
  - **Fatty layer of superficial perineal fascia.** Continuous into the labia majora and the mons pubis in females; diminished in males, being replaced in the penis and scrotum with smooth (dartos) muscle and fascia.
  - **Membranous layer of superficial perineal fascia (Colles' fascia).** Attached to the perineal membrane (posterior margin), perineal body, fascia lata of the superomedial thigh, and Scarpa's fascia of the abdomen. In males, the membranous layer is continuous with dartos fascia in the scrotum and in females helps form the labia majora.
- **Deep perineal fascia (investing or Gallaudet's fascia).** Attached laterally to the ischiopubic rami and invests the ischiocavernosus, bulbospongiosus, and superficial transverse perineal muscles; continuous with the deep fascia covering the external oblique muscle and rectus sheath.
- **Perineal membrane.** Thick triangular fascia; attached to the ischiopubic rami in the horizontal plane; has a free posterior margin.
  - **Perineal spaces.** The perineal membrane forms a boundary between the deep perineal space (situated superiorly to the perineal membrane) and the superficial perineal space (situated inferiorly to the perineal membrane).
  - **Support.** The perineal membrane and associated structures in the deep perineal space contribute to the pelvic floor and support elements of the urogenital system in the pelvic cavity. The perineal membrane and adjacent ischiopubic rami provide attachment for the roots of the external genitalia and superficial perineal muscles.

UROGENITAL TRIANGLE

The urogenital (UG) triangle is the anterior region of the perineum and is oriented in the horizontal plane. The boundaries of this triangle are the pubic symphysis, ischiopubic rami, ischial tuberosities, and perineal body. The UG triangle is associated with the superficial and deep perineal spaces (Figure 12-1A-E).

- **Superficial perineal space (pouch).** An enclosed compartment between the membranous layer of superficial perineal fascia and the perineal membrane. Contains the following:
  - **Males**
    - Root (bulb and crura) of the penis (erectile tissue).
    - Superficial perineal muscles (ischiocavernosus, bulbospongiosus, and superficial transverse perineal muscles).
    - Spongy urethra.
    - Pudendal nerve branches.
    - Internal pudendal artery and vein branches.
  - **Females**
    - Root (crura) of the clitoris (erectile tissue).
    - Bulbs of the vestibule (erectile tissue).
    - Greater vestibular glands.
    - Superficial perineal muscles (ischiocavernosus, bulbospongiosus, and superficial transverse perineal muscles).
    - Pudendal nerve branches.
    - Internal pudendal artery and vein branches.
- **Deep perineal space (pouch).** Bounded inferiorly by the perineal membrane, superiorly by the inferior fascia of the pelvic diaphragm, and laterally by the obturator fascia. The posterior edge contributes to the perineal body (junction of muscles and their fascia in the perineum). Contains the following:
  - **Males**
    - Membranous urethra.
    - External urethra sphincter.
    - Deep transverse perineal muscles.
    - Bulbourethral glands.
    - Pudendal nerve branches.
    - Internal pudendal artery and vein branches.
  - **Females**
    - Urethra: Passageway for urine.
    - External urethral sphincter.
    - Deep transverse perineal muscles.
    - Pudendal nerve branches.
    - Internal pudendal artery and vein branches.

Contents of the superficial and deep perineal spaces will be covered in more detail in Chapters 13 and 14.

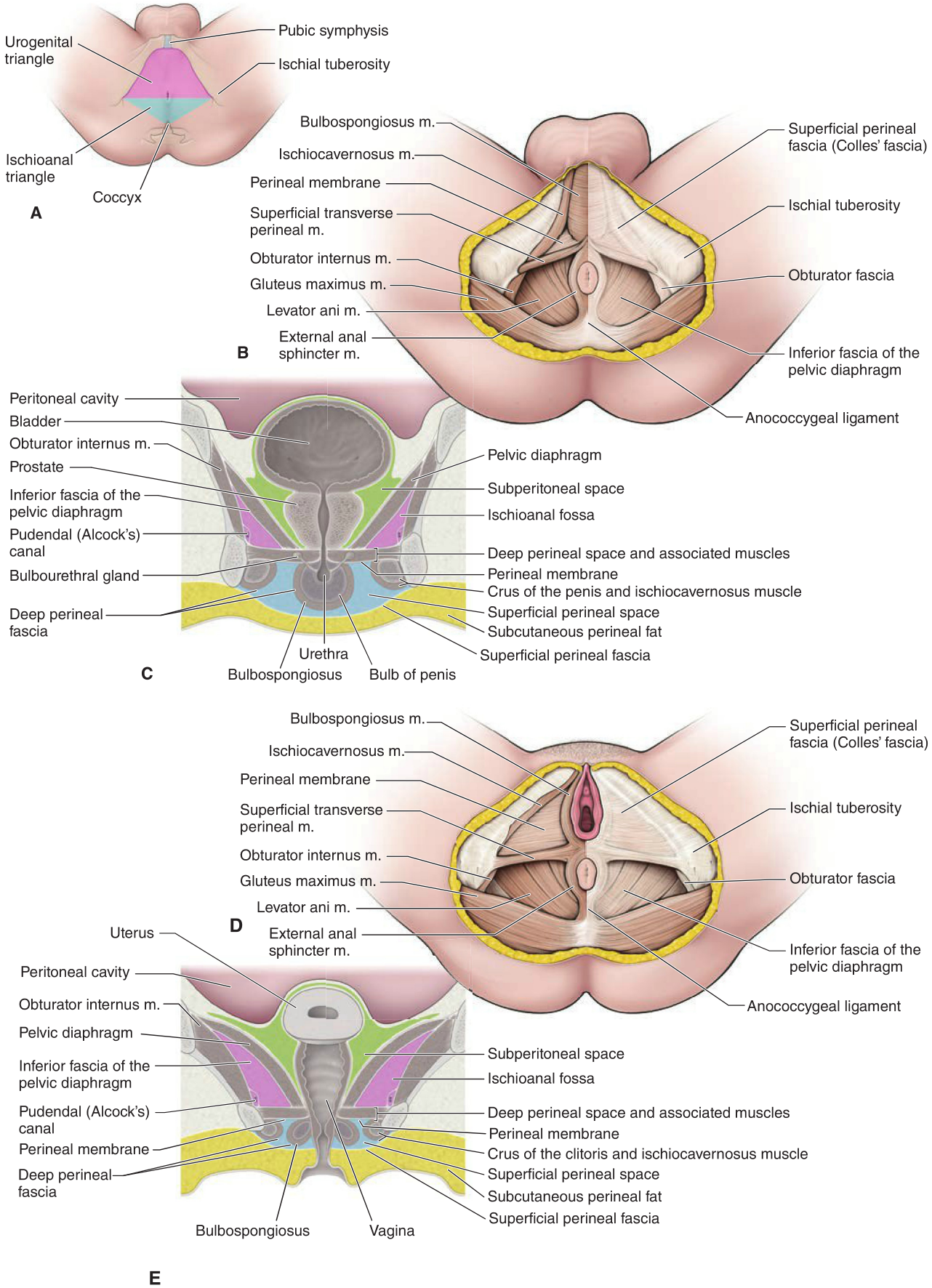

Figure 12-1: A. Urogenital and anal triangles. **B**. Male perineum. **C**. Coronal section of the male perineum. **D**. Female perineum. **E**. Coronal section of the female perineum.

ISCHIOANAL TRIANGLE

The ischioanal triangle contains a horseshoe-shaped fossa known as the **ischioanal fossa**. This fossa is space between the skin surrounding the anus and pelvic diaphragm. The space primarily contains the **anal canal** and associated sphincters at the center surrounded by adipose tissue.

- **Ischioanal triangle boundaries.** Posterior border of the urogenital triangle, gluteus maximus muscle, sacrotuberous ligament, and deep fascia of the obturator internus and levator ani muscles.
- **Pudendal (Alcock's) canal.** The deep fascia of the obturator internus muscle condenses around the **pudendal nerve (S2–S4)** and the **internal pudendal artery and vein**, forming the **pudendal (Alcock's) canal**.
  - **Inferior rectal vessels and nerves.** Arise from the internal pudendal artery and pudendal nerve within the pudendal canal, course across the ischioanal fossa, and supply the inferior region of the rectum.
  - **Perineal vessels and nerves.** The pudendal nerve and internal pudendal artery and vein exit the pudendal canal and supply the structures of the urogenital triangle (superficial and deep perineal spaces) and external genitalia.

PELVIC FLOOR

BIG PICTURE

The pelvic diaphragm forms the floor of the pelvis and serves as a bed for the pelvic organs.

PELVIC DIAPHRAGM

The pelvic diaphragm is formed by the union of the **levator ani** and the **coccygeus muscles**. The levator ani muscle consists of three separate muscles: pubococcygeus, puborectalis, and iliococcygeus. A layer of fascia lines the superior and inferior aspects of the pelvic diaphragm's muscles (Figure 12-2A).

- **Attachments.** Attaches circumferentially along the pubis, lateral pelvic walls, and coccyx.
- **Topography.** The rectum pierces the center of the pelvic diaphragm, giving the appearance of a funnel suspended within the pelvis. In addition to the rectum, the urethra and the vagina (in females) and the urethra (in males) pierce the pelvic diaphragm.
- **Innervation.** Pudendal nerve (S2–S4).
- **Functions.** Closes the pelvic outlet, supports the abdominopelvic viscera, controls the openings of the rectum, urethra, and vaginal canal.

Pelvic floor insufficiency. The complex organization of overlapping muscles and fascia causes the pelvic diaphragm to be susceptible to injury and damage, especially in women. Repetitive stresses, such as those that occur during labor and delivery, can stretch and damage the levator ani muscles and cause pelvic floor insufficiency and its associated clinical problems (e.g., uterine prolapse; urinary incontinence).

OTHER MUSCLES OF THE PELVIC FLOOR

- **Obturator internus muscles.** Covers and lines most of the lateral wall of the pelvis. The obturator nerves and vessels and other branches of the internal iliac vessels course along the medial surface of the obturator internus muscle. The obturator internus muscle exits the pelvis through the lesser sciatic foramen and inserts on the greater trochanter of the femur and performs external hip rotation.
- **Piriformis muscles.** Covers most of the posterior wall of the pelvis. The piriformis muscle exits the pelvis through the greater sciatic foramen and inserts on the greater trochanter of the femur and performs external hip rotation. The sacral plexus of nerves is medial to the piriformis muscle (Figure 12-2).

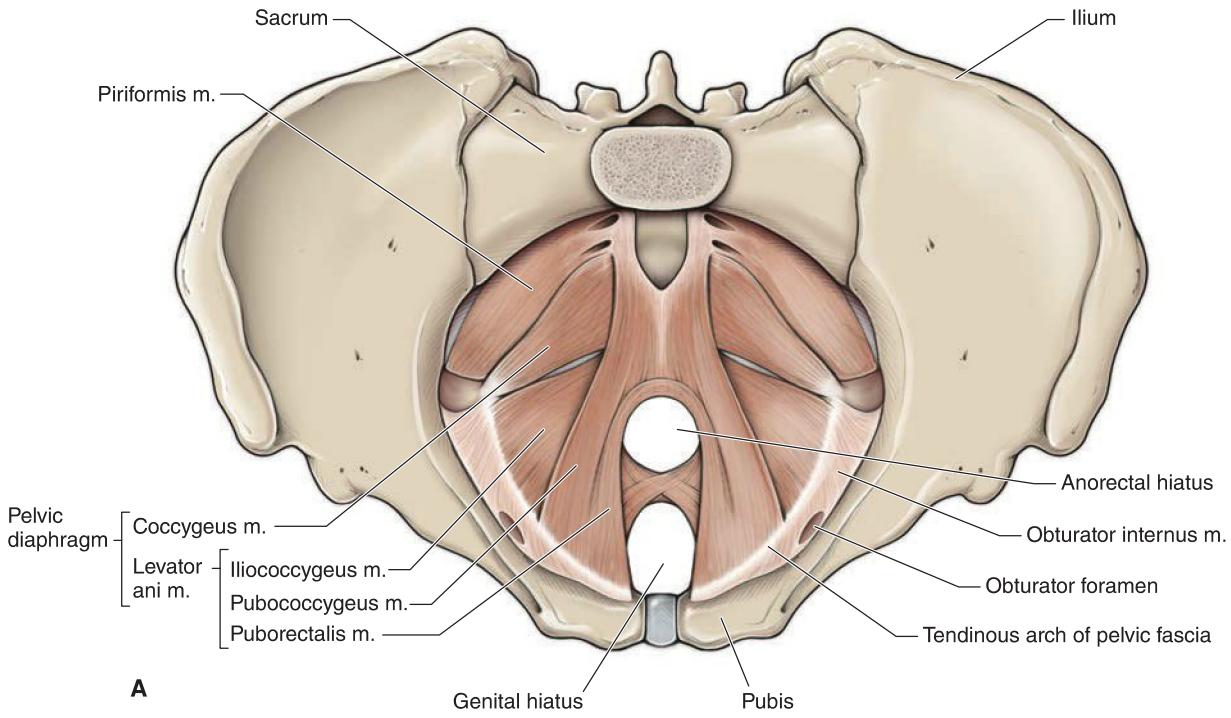

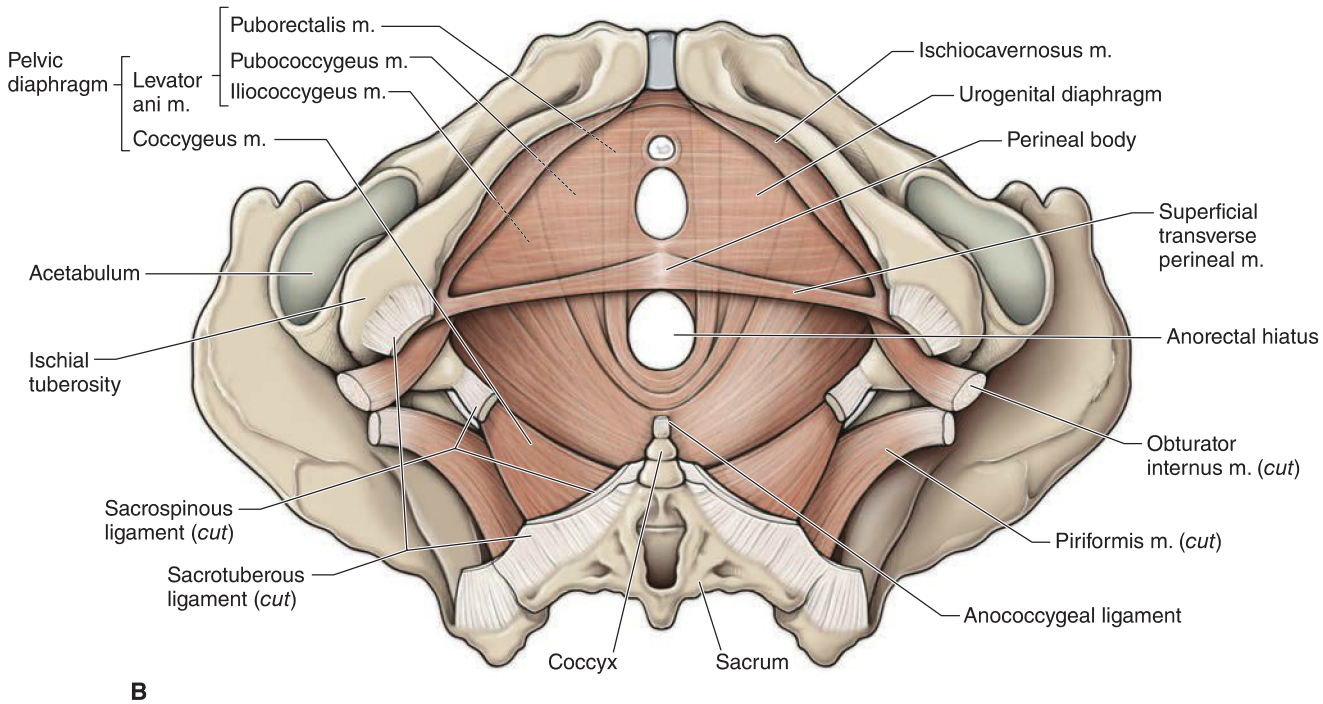

Figure 12-2: Superior (**A**) and inferior (**B**) views of the pelvic diaphragm muscles in a female.

PELVIC VASCULATURE

BIG PICTURE

The common iliac arteries divide at the sacroiliac joints to become the external and internal iliac arteries. The external iliac arteries mainly serve the lower limb. The internal iliac arteries mainly supply the pelvic walls and viscera (i.e., rectum, bladder, prostate, ductus deferens, uterus, uterine tubes, and ovaries). Additionally, the internal iliac arteries distribute blood to the gluteal region, the perineum, and the medial compartment of the thigh.

BRANCHES OF THE EXTERNAL ILIAC ARTERY

The external iliac artery courses deep to the inguinal ligament, and becomes the **femoral artery** (Figure 12-3A). The femoral artery is the principal blood supplier to the lower limb. Before exiting the pelvis, the external iliac artery gives rise to the **inferior epigastric artery**, which ascends vertically along the internal surface of the anterior abdominal wall.

BRANCHES OF THE INTERNAL ILIAC ARTERY

The internal iliac artery divides into an anterior and a posterior trunk near the greater sciatic foramen (Figure 12-3A and B).

ANTERIOR TRUNK Branches from the anterior trunk supply the pelvic viscera, perineum, gluteal region, and medial compartment of the thigh:

- **Obliterated umbilical artery.** Ascends out of the pelvis along the internal surface of the anterior abdominal wall to terminate at the umbilicus. In the fetus, the umbilical artery conveys blood from the fetus through the umbilical cord to the placenta. After birth, the vessel collapses after the umbilical cord is cut.
  - **Superior vesical artery.** Supplies the bladder and the ductus deferens.
- **Obturator artery.** Courses along the obturator internus muscle and exits the pelvis through the obturator canal, along with the obturator nerve and vein; supplies the medial compartment of the thigh.
- **Uterine artery.** In females, the uterine artery courses within the broad ligament; prior to supplying the cervix the uterine artery courses over the ureter; ascends laterally along the uterus and forms an anastomosis with the ovarian artery at the uterine tubes. During pregnancy, the uterine artery enlarges significantly to supply blood to the uterus, ovaries, and vaginal walls. This artery is not present in males.
- **Inferior vesical artery.** In males, the inferior vesical artery supplies the bladder, ureter, seminal vesical, and prostate.
- **Vaginal artery.** In females, the vaginal artery is the equivalent of the inferior vesical artery in males and supplies the vagina and bladder.
- **Middle rectal artery.** Supplies the rectum and forms anastomoses with the superior rectal artery (branch of inferior mesenteric artery) and the inferior rectal artery (branch of the internal pudendal artery).
- **Internal pudendal artery.** Exits the pelvis through the greater sciatic foramen, inferior to the piriformis muscle. Along with the pudendal nerve, the internal pudendal artery traverses the lesser sciatic foramen to enter the urogenital triangle. The internal pudendal artery supplies the perineum, including the erectile tissues of the penis and clitoris.
- **Inferior gluteal artery.** The terminal branch of the anterior division of the internal iliac artery; courses inferior to the piriformis muscle and exits the pelvis through the greater sciatic foramen; supplies the gluteal region.

POSTERIOR TRUNK Branches from the posterior trunk of the internal iliac artery serve the lower portion of the posterior abdominal and pelvic walls and the gluteal region.

- **Iliolumbar artery.** Supplies the posterior portion of the abdominal and pelvic walls.
- **Lateral sacral artery.** Traverses the anterior sacral foramina to supply the posterior sacrum and overlying muscles.
- **Superior gluteal artery.** The terminal branch of the posterior trunk; courses between the lumbosacral trunk and the S1 ventral ramus superior to the piriformis muscle and exits the pelvis through the greater sciatic notch; supplies the gluteal region.

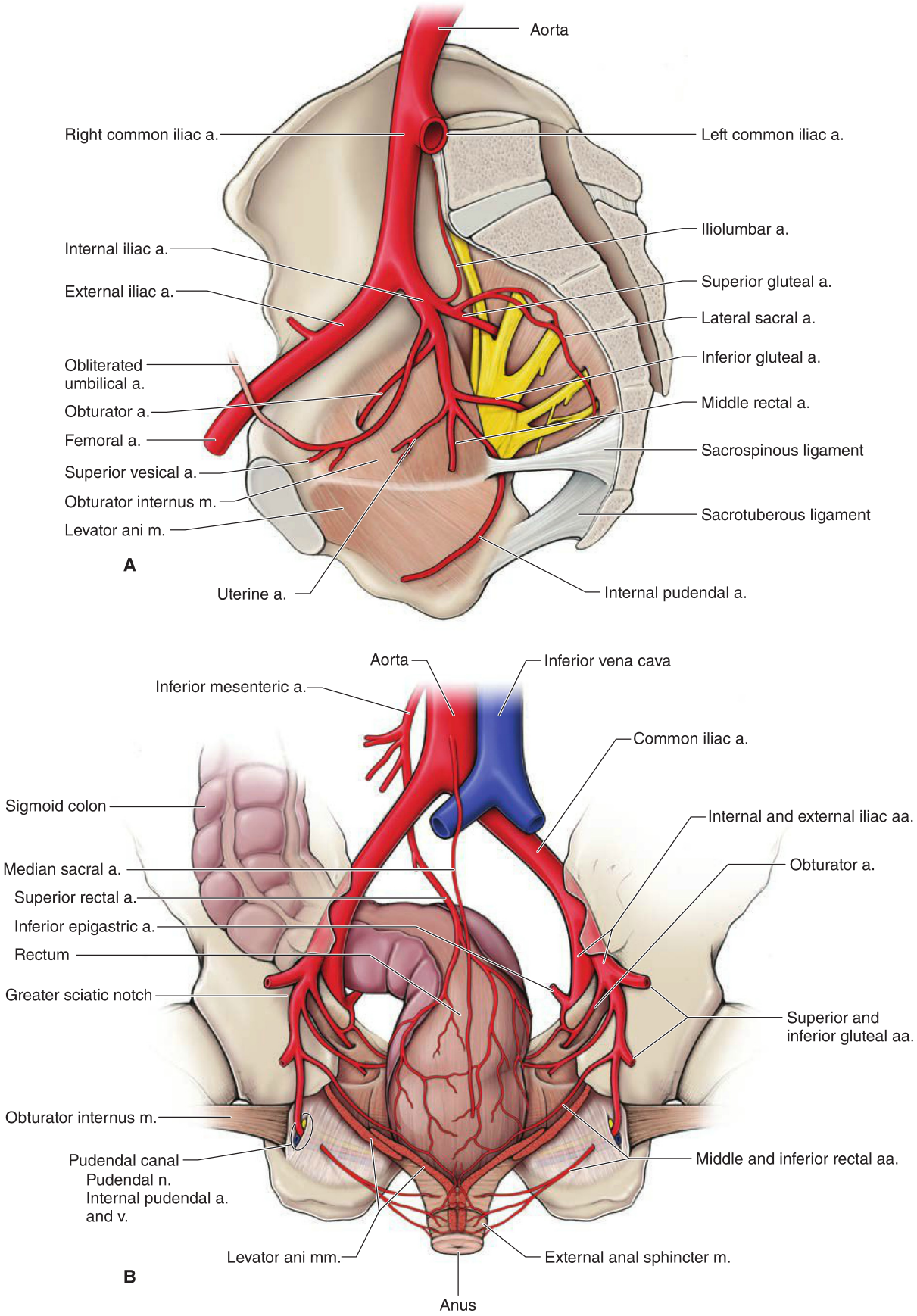

Figure 12-3: A. Branches of the internal iliac artery. **B**. Arteries of the pelvis, posterior view.

PELVIC INNERVATION

BIG PICTURE

Somatic and autonomic nerves contribute to pelvic innervation. The obturator nerve, femoral nerve, and the sacral plexus provide innervation to skeletal muscles and skin in the pelvis and lower limbs. All autonomics of the pelvis and perineum pass through the inferior hypogastric plexus. Sympathetic and parasympathetic nerves contribute to the inferior hypogastric plexus through the sacral splanchnics and pelvic splanchnics, respectively.

OBTURATOR NERVE

The obturator nerve originates from the ventral rami of spinal nerves L2–L4, and courses along the obturator internus muscle, with the obturator artery and vein, where they exit the pelvis through the obturator canal. Transmits sensation from medial thigh and supplies medial compartment thigh muscles.

▼ **Obturator nerve lesion.** The course of the obturator nerve is near the ovary. Therefore, the obturator nerve is at risk during an **oophorectomy** (surgical removal of an ovary). If the obturator nerve is damaged, the adductor muscles of the medial compartment of the thigh may lose function. In addition, loss of cutaneous sensation may occur over the medial surface of the thigh. ▼

FEMORAL NERVE

The femoral nerve originates from the ventral rami of spinal nerves L2–L4, courses lateral to the iliopsoas muscle, and exits the pelvis deep to the inguinal ligament. Conveys sensation from anterior thigh and medial leg and supplies anterior compartment thigh muscles.

SACRAL PLEXUS

The sacral plexus is formed by the lumbosacral trunk (L4–L5 ventral rami) and the S1–S4 ventral rami (Figure 12-4A and B). The sacral plexus lies on the anterior surface of the piriformis muscle. The following nerves branch from the sacral plexus:

- **Superior gluteal nerve (L4–S1).** Exits the pelvis superior to the piriformis muscle and courses through the greater sciatic notch; innervates the gluteus medius, gluteus minimus, and tensor fascia lata muscles.
- **Inferior gluteal nerve (L5–S2).** Exits the pelvis inferior to the piriformis muscle and courses through the greater sciatic notch; innervates the gluteus maximus muscle.
- **Pudendal nerve (S2–S4).** Exits the pelvis inferior to the piriformis muscle and enters the perineum through the lesser sciatic foramen, where the pudendal nerve enters the pudendal canal along the lateral wall of the ischioanal fossa. Transmits sensation from skin of the genitalia, perineum, and anus and innervates perineal muscles, pelvic diaphragm, and external urethral and anal sphincters.
- **Sciatic nerve (L4–S3).** The largest peripheral nerve in the body; composed of the **tibial** and **common peroneal nerves** and exits the pelvis inferior to the piriformis muscle, between the ischial tuberosity and the greater trochanter of the femur. Transmits sensation from posterior thigh and skin below the knee (except medial leg). Innervates hamstring muscles and all muscles below the knee.

SACRAL SYMPATHETIC TRUNK

The sacral sympathetic trunk crosses the pelvic brim posterior to the common iliac vessels (Figure 12-4A). Four ganglia are present along the trunk. The trunks of the two sides unite in front of the coccyx at a small swelling called the **ganglion impar**. The sacral sympathetic trunk contributes sympathetic nerves to the somatic branches of the sacral nerves (targeting the skin) and contributes visceral branches to the inferior hypogastric plexus (targeting the pelvic viscera and perineum).

PELVIC SPLANCHNIC NERVES

The pelvic splanchnic nerves are the only splanchnic nerves that carry parasympathetic fibers (Figure 12-4A). All other splanchnic nerves, such as the greater splanchnic nerve, carry only sympathetic fibers.

- Preganglionic parasympathetic fibers originate from the S2–S4 spinal cord levels. The fibers course within the S2–S4 ventral rami, exit as the pelvic splanchnic nerves, and course to the inferior hypogastric plexus.
- These nerves supply the distal portion of the hindgut as well as organs of the pelvis and perineum.

INFERIOR HYPOGASTRIC PLEXUS

The inferior hypogastric plexus is formed by the union of nerves from the superior hypogastric plexus, sacral splanchnic nerves, and pelvic splanchnic nerves (Figure 12-4A). The inferior hypogastric plexus is located diffusely around the lateral walls of the rectum, bladder, and vagina. The plexus contains ganglia in which both sympathetic and parasympathetic preganglionic fibers synapse. Therefore, the inferior hypogastric plexus consists of preganglionic and postganglionic sympathetic and parasympathetic fibers, as well as visceral sensory fibers. The inferior hypogastric plexus gives rise to many other smaller plexuses that provide innervation to organs involved with urination, defecation, erection, ejaculation, and orgasm.

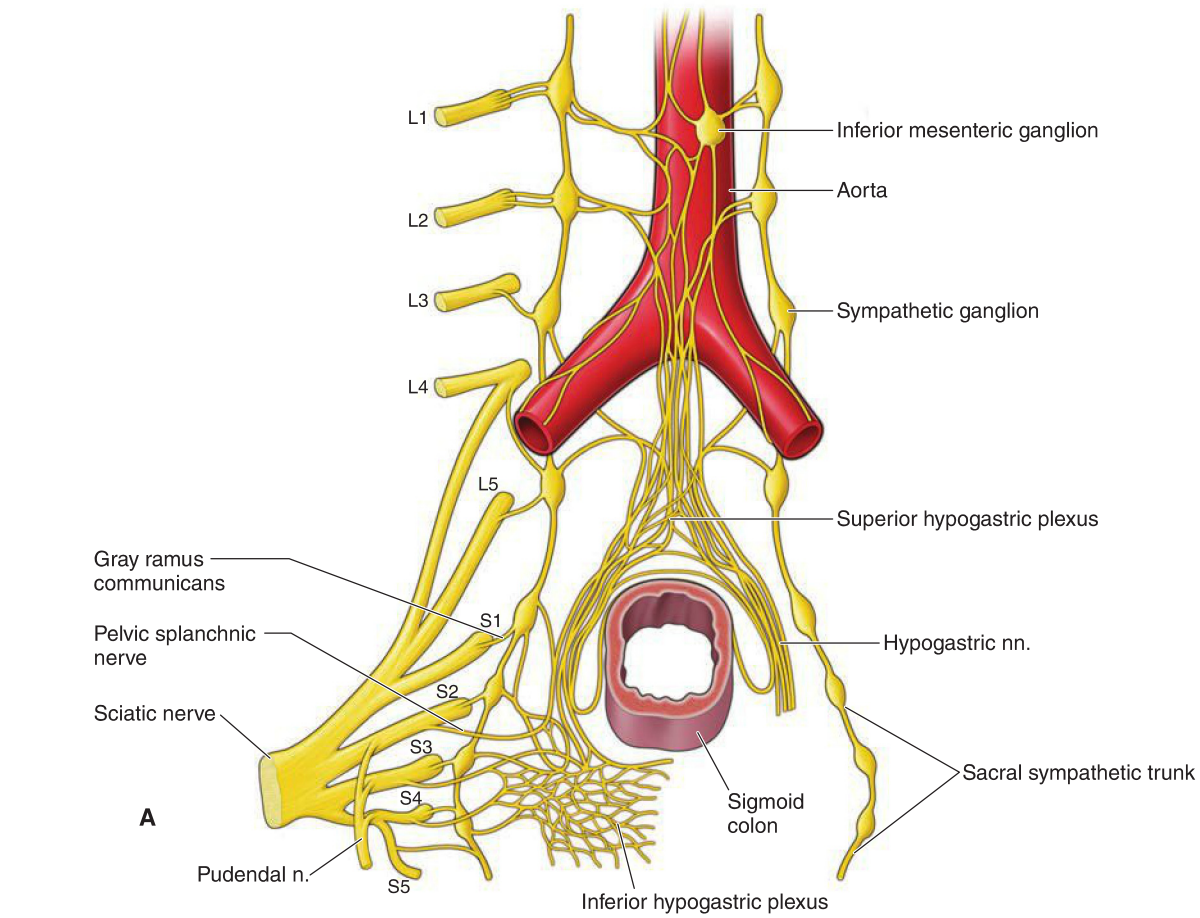

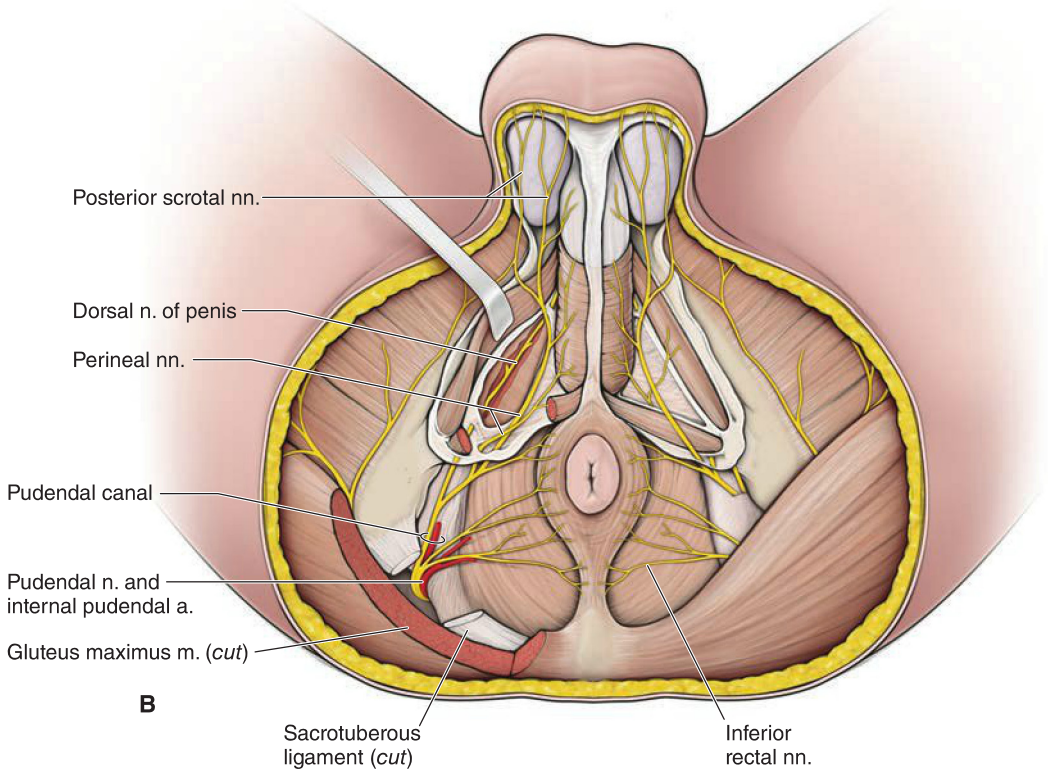

Figure 12-4: A. Prevertebral and sacral plexuses. **B**. Innervation of the male perineum.

RECTUM AND ANAL CANAL

BIG PICTURE

The sigmoid colon becomes the rectum, which in turn terminates at the anus. The rectum is located superior to the pelvic diaphragm in the pelvic cavity. The anus is located inferior to the pelvic diaphragm in the ischioanal fossa. The terminal end of the GI tract is significant because it is a junction of two embryologic origins of tissue: endoderm and ectoderm.

RECTUM

The rectum is a continuation of the sigmoid colon and is located superior to the pelvic diaphragm in the pelvic cavity.

- **Peritoneum.** Covers the anterior and lateral surfaces of the proximal portion of the rectum; however, there is no peritoneal covering for the distal portion of the rectum.
- **Ampulla.** A dilated region in the rectum. As feces collect in the ampulla, the walls bulge and pressure increases. Stretch receptors in the rectal wall relay messages to the brain for the need to defecate.
- **Arteries.** The rectum receives its blood supply from the superior rectal artery (a branch of the inferior mesenteric artery), the middle rectal artery (a branch of the internal iliac artery), and the inferior rectal artery (a branch of the internal pudendal artery) (Figure 12-5A).
- **Veins.** Venous return is through the superior rectal vein (a branch of the inferior mesenteric vein of the portal system), the middle rectal vein (the internal iliac vein), and the inferior rectal vein (the internal pudendal vein) (Figure 12-5B).
  - The anastomosis of the middle and inferior rectal veins is an important portal-systemic anastomosis.
- **Lymphatics.** Lymphatic drainage of the rectum is through three principal directions. Lymph from the superior region of the rectum drains into the **inferior mesenteric nodes**, from the middle of the rectum into the **internal iliac nodes**, and from the inferior part of the rectum into the **superficial inguinal nodes**.
- **Innervation.** Parasympathetic innervation via the pelvic splanchnic nerves is through the inferior hypogastric plexus.

ANAL CANAL

The anal canal, surrounded by the internal and external anal sphincters, descends between the anococcygeal ligament and perineal body into the ischioanal fossa inferior to the pelvic diaphragm. The anal canal is divided into an upper two-thirds (visceral portion), which is part of the large intestine, and a lower one-third (somatic portion), which is part of the perineum.

- **Pectinate line (anorectal junction).** An important landmark that divides the anal canal into upper and lower portions. Developmentally, the pectinate line is the junction between the forming hindgut (gut tube) and the proctodeum (body wall). The pectineal line is an important anatomic landmark, which distinguishes the vascular, nerve, and lymphatic supplies as follows:
  - **Superior to the pectinate line.** Has a series of longitudinal ridges called **anal columns**, which contain terminal branches from the superior rectal arteries and veins. Visceral motor and sensory innervation is via the inferior hypogastric plexus. Lymph drainage is to inferior mesenteric lymph nodes. The epithelium is simple columnar, as is the remainder of the small and large intestines, which reflects the endodermal origin of this part of the anal canal.
  - **Middle rectal arteries and veins.** Arise from the internal iliac artery and assist with the blood supply to the anal canal by forming anastomoses with the superior rectal vessels (above the pectineal line) and inferior rectal vessels (below the pectineal line). Lymph drainage is to the internal iliac lymph nodes.
  - **Inferior to the pectineal line.** The vascular supply is from the inferior rectal arteries and veins. Somatic motor and sensory innervation is via the inferior rectal nerves. Lymph drainage is to the superficial inguinal lymph nodes. The epithelium is stratified squamous keratinized epithelium, similar to the skin, which reflects the ectodermal origin of this part of the anal canal.

▽ **Hemorrhoids.** Dilated and inflamed venous plexuses within the anorectal canal. Hemorrhoids are classified as **internal** (superior to the pectineal line) or **external** (inferior to the pectineal line). Internal hemorrhoids usually are not painful because visceral sensory nerves lack pain receptors. In contrast, external hemorrhoids are usually painful because their innervation is from somatic sensory nerves, which detect pain. ▼

ANAL SPHINCTERS

The following two sphincters are responsible for regulating passage of fecal matter:

- **Internal anal sphincter.** Located in the superior region of the anal canal and is a continuation of smooth muscle (involuntary control) from the GI tract.
  - **Sympathetic innervation.** Causes the internal anal sphincter to be in a state of continual contraction to prevent leakage of fluid or flatus.
  - **Parasympathetic innervation.** When pressure in the rectal ampulla increases (build up of feces), parasympathetic nerve branches from pelvic splanchnic nerves cause internal anal sphincter relaxation. If defecation is not to occur at this time, voluntary contraction of the puborectalis and external anal sphincter muscles is required to avoid fecal incontinence.
- **External anal sphincter.** Blends superiorly with the puborectalis muscles and consists of skeletal muscle that encircles the distal portion of the anus enabling voluntary contraction or relaxation.
  - **Topography.** Anterior to the external anal sphincter is the **perineal body**, a strong tendon into which many of the perineal muscles insert, including the urogenital diaphragm, the levator ani muscle, and the external anal sphincter.
  - **Innervation.** Inferior rectal nerve branches from the pudendal nerve (S2–S4); mainly the S4 level.

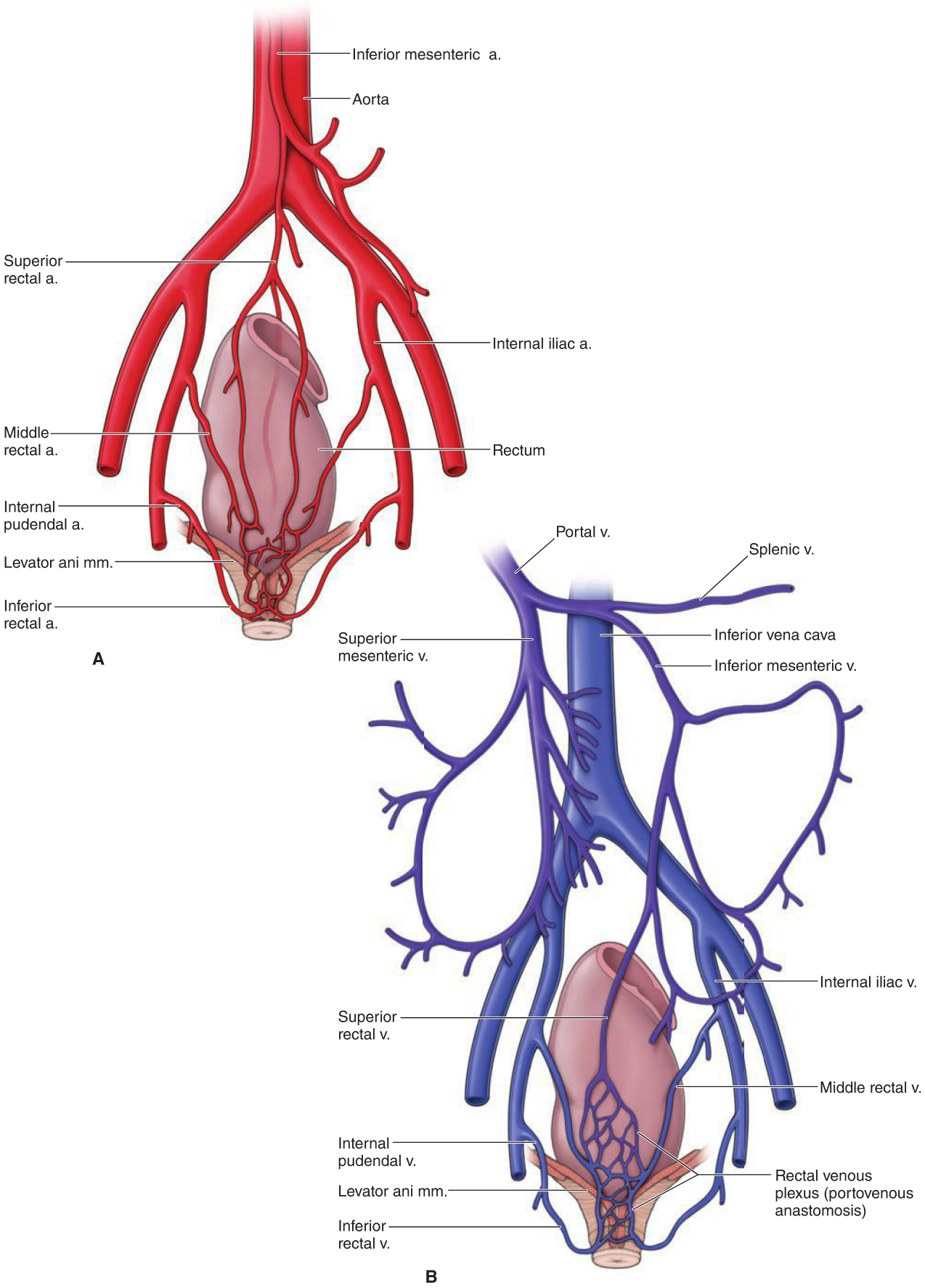

Figure 12-5: A. Rectal arteries. **B**. Rectal veins.

URETERS AND URINARY BLADDER

BIG PICTURE

The ureters connect the kidneys to the urinary bladder, which stores urine until urination occurs. The urethra voids urine from the urinary bladder.

URETER

The ureter is a retroperitoneal tube that transports urine via peristalsis from the kidney to the urinary bladder (Figure 12-6A and C). The three constrictions that occur along the course of the urethra are where the ureter:

- Forms from the renal pelvis.
- Crosses the pelvic brim anterior to the bifurcation of the common iliac artery.
- Enters the bladder.

In males, the ureter courses posterior and medial to the ductus deferens and anterior to the seminal vesicle. In females, the ureter courses lateral to the cervix, where the ureter courses inferior to the uterine artery.

Water under the bridge. An important anatomic relationship that pelvic surgeons rely on is that the ureter courses inferior to the uterine artery. When performing a hysterectomy, the surgeon clamps the uterine artery to prevent bleeding. If the surgeon is not careful, the ureter may be clamped and cut by accident. A mnemonic for remembering this relationship is "**water under the bridge**," where "water" represents "urine" and the "bridge" represents the "uterine artery."

URINARY BLADDER

The urinary bladder is located below the peritoneum (infraperitoneal) between the pubis and pelvic diaphragm (Figure 12-6A-C). The superior surface of the bladder is dome shaped when the bladder is empty and swells superiorly into the abdomen when full. The bladder has the following parts:

- **Apex.** The top of the bladder at the top of the pubic symphysis. The apex continues as the embryonic remnant of the urachus within the median umbilical ligament.
- **Base.** The base of the bladder is located inferiorly and posteriorly. The paired ureters enter the bladder at each of the superior corners of the base. Internally, the triangular area between the openings of the ureters is known as the **trigone**.
- **Neck.** The inferior portion of the bladder that surrounds the origin of the urethra; supported by the pubovesical ligament (fibromuscular bands that attach between the neck and pubic bones).
- **Detrusor muscle.** The detrusor muscle consists of smooth muscle within the wall of the bladder.
  - **Contraction.** Parasympathetic innervation causes urination (bladder contraction voids urine from the bladder).
  - **Relaxation.** Sympathetic innervation enables urine storage (bladder relaxation enables more urine from the ureter to be stored).
- **Internal urethral sphincter.** Smooth muscle located at the neck of the bladder that involuntarily contracts or relaxes, thereby regulating the emptying of the bladder.
  - **Contraction.** Sympathetic innervation causes continual contraction of the internal urethral sphincter, thus inhibiting the release of urine from the bladder.
  - **Relaxation.** Parasympathetic innervation relaxes the internal urethral sphincter, thus enabling the release of urine from the bladder.
- **External urethral sphincter.** This sphincter is composed of skeletal muscle within the urogenital diaphragm that voluntarily opens and closes the urethra to void urine.
  - **Innervation.** Voluntary control via the pudendal nerve (S2–S4).
- **Vascular supply.** Superior and inferior vesical arteries (branches of the internal iliac artery) and vaginal arteries in females; drained by the vesical plexus of veins (into the internal iliac vein).
- **Innervation.** The **vesical and prostatic plexuses** (extensions of the inferior hypogastric plexus). Parasympathetic innervation is from the S2–S4 spinal cord levels, which enter the inferior hypogastric plexus, as do sacral splanchnic nerves for sympathetic innervation. The inferior hypogastric plexus then gives rise to the vesical and prostatic plexuses, which innervate the ureter, urinary bladder, and internal urethral sphincter.

URINATION

The process of urination occurs as follows:

- The bladder fills with urine, causing the bladder to distend.
- Visceral sensory fibers relay to the spinal cord (S2–S4), via the pelvic splanchnic nerves, that the bladder wall is stretched.
- Preganglionic parasympathetic fibers from the S2–S4 spinal cord segments enter the spinal nerves and pelvic splanchnic nerves. The pelvic splanchnic nerves enter the inferior hypogastric plexus; the preganglionic parasympathetic fibers course from the inferior hypogastric plexus to the bladder, where they synapse with postganglionic parasympathetic fibers. Stimulation of these parasympathetic nerves causes the detrusor muscle to contract and the internal urethral sphincter to relax.
- Somatic motor neurons in the pudendal nerve cause relaxation of the external urethral sphincter and contraction of the bulbospongiosus muscles, which expel the last drops of urine from the urethra.

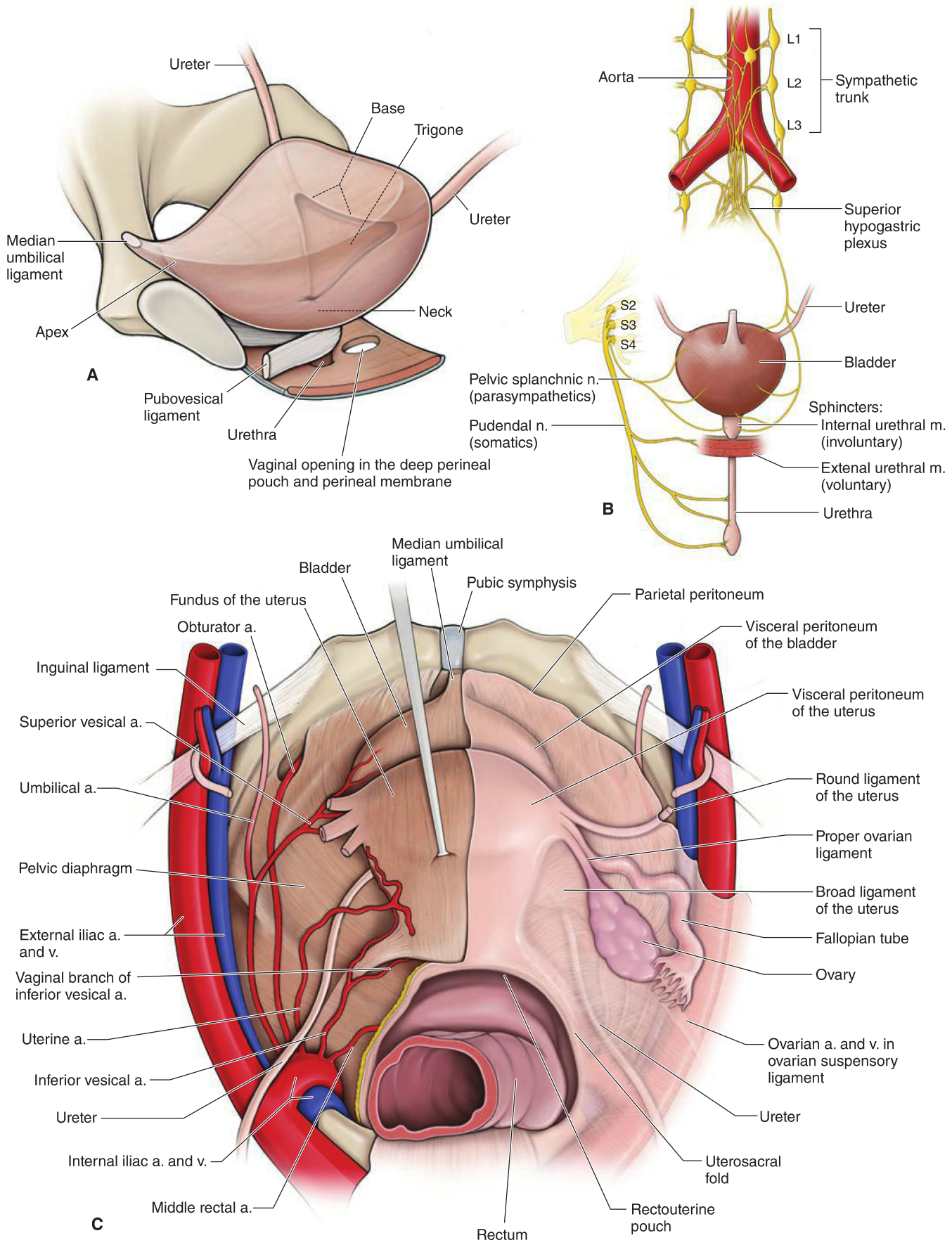

Figure 12-6: A. Bladder. **B**. Innervation of distal ureter, bladder, and urethra. **C**. Superior view of the bladder in situ (female).

This page intentionally left blank

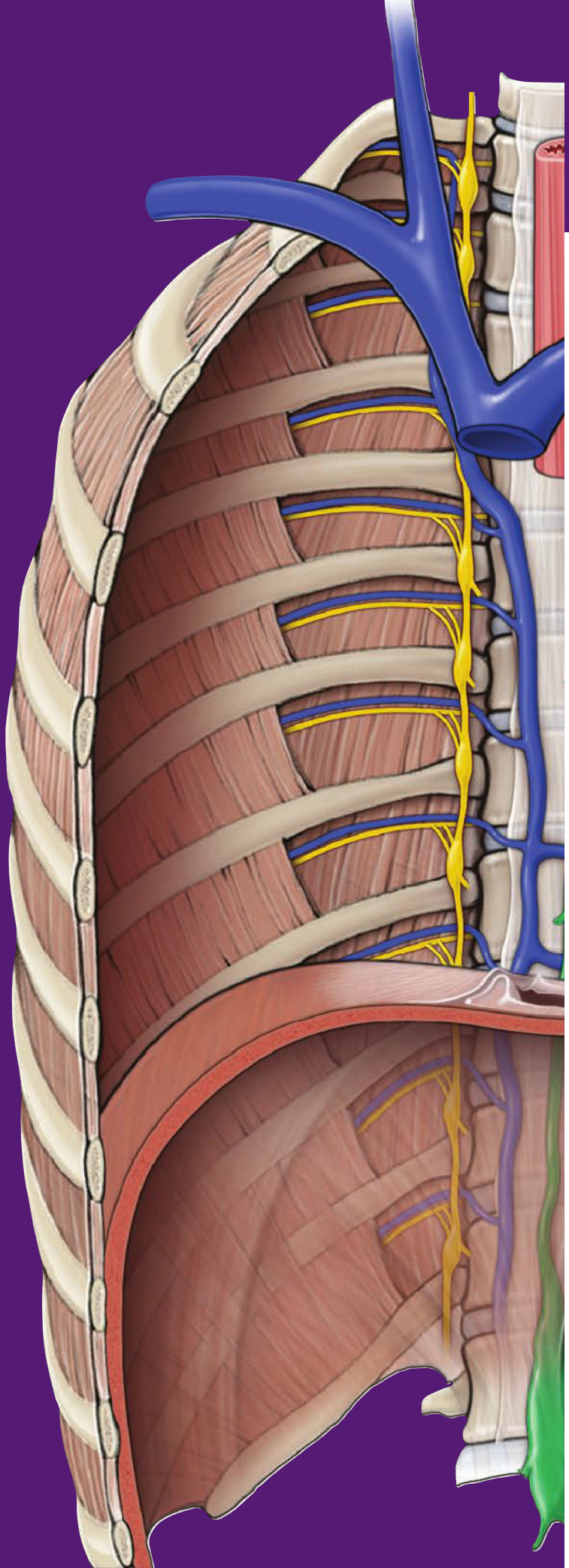

CHAPTER 13

MALE REPRODUCTIVE SYSTEM

Male Reproductive System 144
The Male Sexual Responses 148

MALE REPRODUCTIVE SYSTEM

BIG PICTURE

The male reproductive system primarily consists of the paired testes and the penis. In addition, accessory sex glands contribute to seminal fluid. The male reproductive system matures during adolescence and remains active for the remainder of the lifespan of the male.

MALE EXTERNAL GENITALIA

The external genitalia have the following structures (Figure 13-1A–D):

- **Penis.** The male copulatory organ, composed of erectile tissue, transports urine and semen via the urethra; the penis is highly innervated by perineal nerve branches and becomes engorged with blood and erects during stimulation. The penis erects in the anatomical position (i.e., when the penis is flaccid, its dorsal surface is positioned anteriorly). The penis consists of the following parts:
  - **Glans penis.** Formed by the terminal part of the corpus spongiosum; projects posteriorly over the end of the corpora cavernosa; covered by a free fold of skin called the prepuce. **Circumcision** is the surgical removal of the prepuce.
  - **Body (corpus).** The free pendulous part of the penis; contains the single corpus spongiosum and the paired corpora cavernosa.
    - **Corpus spongiosum.** Erectile tissue surrounding the spongy urethra (transports urine and semen) on the ventral surface of the penis; expands distally into the glans penis. During an erection, the corpus spongiosum prevents the urethra from being pinched closed, thereby maintaining the urethra open for transporting semen during ejaculation.
    - **Corpora cavernosa.** Paired erectile tissues that form most of the body of the penis on its dorsal surface; less pliable than the corpus spongiosum because the corpora cavernosa fill with the majority of blood during erection.
  - **Root.** The attached part of the penis consisting of the bulb and two crura:
    - **Bulb of the penis.** Attached in the midline to the perineal membrane; the bulb is the dilated root of the corpus spongiosum and is surrounded by the bulbospongiosus muscle.
    - **Crura of the penis.** Paired structures attached to the ischiopubic rami on either side of the bulb; the crura are the roots of the corpora cavernosa and are surrounded by the ischiocavernosus muscles.
- **Testes.** The primary male sex organ; produces spermatozoa and sex hormones (e.g., testosterone).
- **Epididymis.** Consists of a head, body, and tail; located on the superior pole of each testis; stores sperm during the maturation process.
- **Ductus deferens.** A thick-walled tube in the spermatic cord that transports sperm from the epididymis through the inguinal canal to the ejaculatory ducts in the prostate gland.
  - **Innervation.** Sympathetic nerves from the inferior hypogastric plexus cause peristaltic contractions in the thick smooth muscle wall to propel sperm during emission.
- **Ejaculatory ducts.** Formed by the union of the ductus deferens and ducts from the seminal vesicles. The ejaculatory ducts open into the prostatic urethra.
- **Seminal vesicles.** Lobular glands located on the base of the bladder. During emission and ejaculation, the seminal vesicles empty their secretions (e.g., fructose, citric acid, prostaglandins, and fibrinogen) into the ejaculatory duct as sperm traverse the ductus deferens. Seminal vesicle secretions add substantially to the volume of semen.
- **Prostate gland.** Located between the neck of the bladder and pelvic diaphragm; anterior to the rectum.
  - **Lobes.** Composed of five lobes: Right and left lateral lobes, which are situated on either side of the prostatic urethra and form the bulk of the prostate gland. Anterior lobe (isthmus), which is anterior to the urethra and devoid of glandular tissue. Middle lobe, which lies between the urethra and ejaculatory ducts. Posterior lobe, which lies posterior to the urethra and contains glandular tissue.
  - **Function.** Secretes a milky fluid that contributes to the bulk of the semen.
- **Bulbourethral glands.** Located posterolateraly to the membranous urethra within the deep perineal space; ducts traverse the perineal membrane to enter the spongy urethra.
  - **Function.** Secrete mucus that lines the urethral lumen during sexual arousal to aid in passageway lubrication during ejaculation.
  - **Innervation.** Parasympathetic nerves from the prostatic plexus (inferior hypogastric plexus origin).

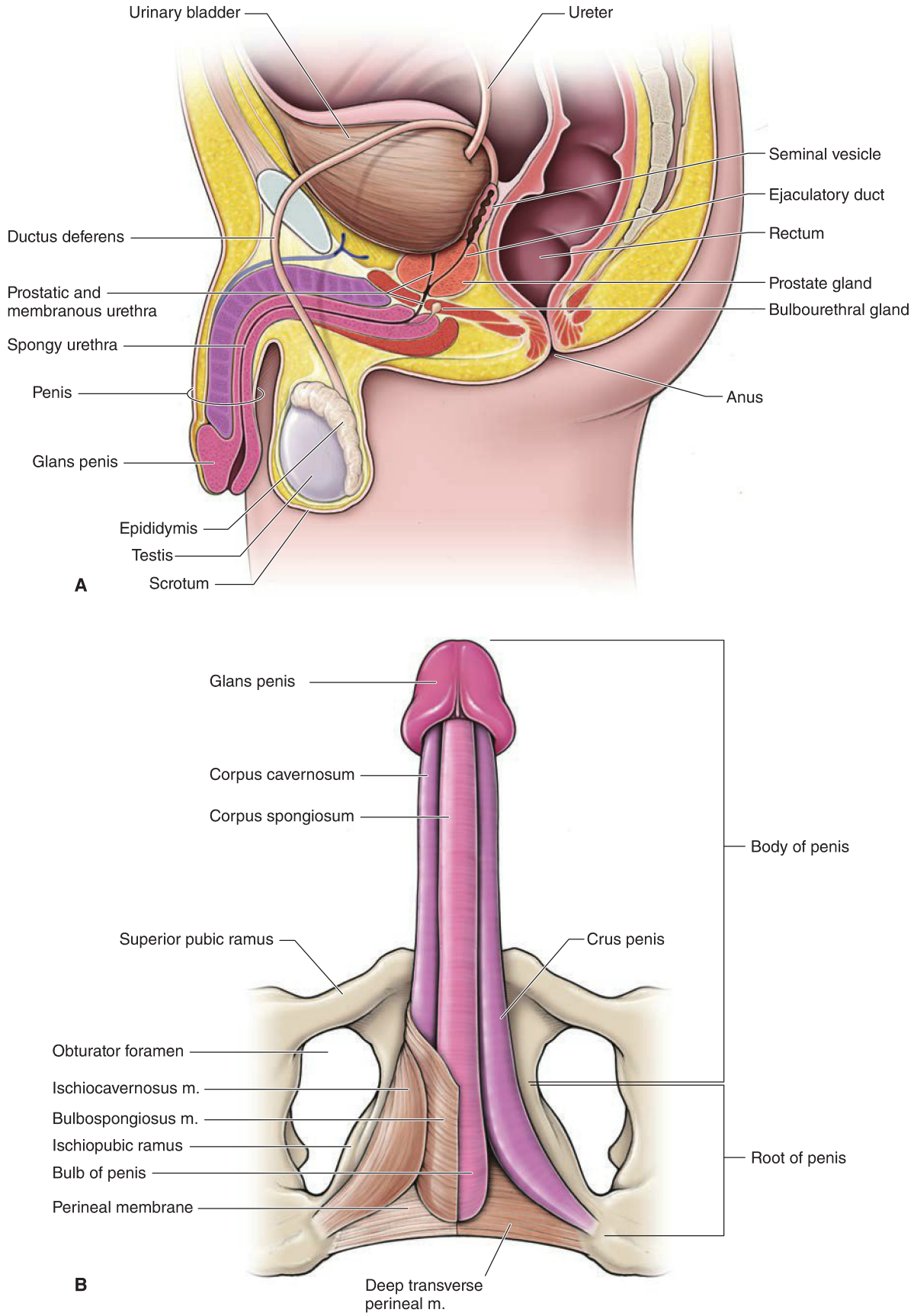

Figure 13-1: A. Male reproductive system. **B**. Male erectile muscles and tissues.

MALE PERINEAL MUSCLES

The following voluntary skeletal muscles reside in the perineum and are innervated by perineal nerve branches:

- **Ischiocavernosus muscles.** Voluntary skeletal muscles that arise from the ischiopubic rami and insert into the corpus cavernosum surrounding the crura of the penis; stabilize an erect penis and compress the crus of the penis to impede venous drainage from the erectile tissue, thereby maintaining an erection.
- **Bulbospongiosus muscle.** Voluntary skeletal muscle that arises from the perineal body and bulb of the penis and inserts into the corpus spongiosum; assists during erection, ejaculation, and expelling the final drops of urine during micturition.
- **Superficial transverse perineal muscle.** Voluntary skeletal muscle that arises from the ischial tuberosities and attaches to and contributes to the perineal body.
- **Internal urethral sphincter.** Located within the deep perineal space; encircles the membranous urethra to inhibit or enhance the voiding of the bladder during urination.

Prostate health. A common condition among men over the age of 50 is **benign prostatic hyperplasia (BPH)**, which is characterized by smooth, elastic, firm nodular enlargement of the middle and lateral lobes of the prostate gland. Affected men may have difficulty urinating because the enlarged gland compresses the urethra. Due to its proximal location anterior to the rectum, the prostate gland is relatively easy to palpate. A digital rectal examination is used to determine the size of the prostate gland. During a digital rectal examination, the physician may also palpate the seminal vesicles and the ductus deferens. Measuring **prostate-specific antigen (PSA)** is a measure for BPH and prostate cancer (**prostatic adenocarcinoma**), which arises primarily from the posterior prostatic lobe.

SEVEN UP. To remember the pathway that sperm travel during ejaculation, the following mnemonic may be helpful: **SEVEN UP** = **S**eminiferous tubules, **E**pididymis, **V**as deferens, **E**jaculatory ducts, **N**othing, **U**rethra, **P**enis.

- **Penile fascial coverings.** The penis is enveloped by the following fascial layers (from superficial to deep):
  - **Superficial penile fascia (Dartos fascia).** Loose connective tissue devoid of fat, contains the superficial dorsal penile veins and is continuous with the following: dartos muscle and fascia (scrotum), Colles' fascia (perineum) and Scarpa's fascia (abdomen).
  - **Deep penile fascia (Buck's fascia).** Dense connective tissue sheath that forms a strong membranous covering for the corpora cavernosa and corpus spongiosum; courses between the superficial and deep dorsal penile veins and is continuous with the following: deep perineal fascia (covering superficial perineal muscles), external spermatic fascia (scrotum), and suspensory ligament of the penis.
  - **Tunica albuginea.** A thin white layer of connective tissue that surrounds the corpora cavernosa and corpus spongiosum; more dense around the corpora cavernosa and inhibits blood return during an erection.
- **Vascular supply of the penis.** Perineal artery branches (from the internal pudendal artery) supply the penis and dorsal penile veins drain it.
  - **Deep penile artery (cavernosal artery).** Traverses the perineal membrane and enters the crus of the penis to supply the erectile tissue; the deep penile artery runs the length of the corpus cavernosum.
  - **Dorsal penile artery.** Courses deep to the deep penile fascia along the dorsum of the penis; supplies the glans penis, penile skin, and tunica albuginea of the corpus cavernosum and forms anastomoses with deep penile arteries.
  - **Artery of the bulb of the penis.** Pierces the perineal membrane and supplies the bulb of the penis and corpus spongiosum.
  - **Dorsal penile veins.** Located between the tunical albuginea and deep penile fascia and receives blood from the glans penis and corpora cavernosa; courses along between the paired dorsal penile arteries in the midline to join with the internal pudendal vein and ultimately the prostatic plexus of veins.

INNERVATION OF THE MALE REPRODUCTIVE SYSTEM

Innervation of the male reproductive system is as follows (Figure 13-2):

- **Somatic innervation.** The pudendal nerve provides motor and sensory innervation to the male genitalia:
  - **Motor.** Superficial perineal muscles (ischiocavernosus, bulbospongiosus, superficial transverse perineal) and deep perineal muscles (external urethral sphincter).
  - **Sensory.** Sensation of the perineum.
- **Sympathetic innervation.** The sympathetic pathway begins in the L1–L2 spinal cord levels and courses through the lumbar and sacral splanchnic nerves to the inferior hypogastric plexus, which cause:
  - Peristaltic contractions in the smooth muscle of the ductus deferens to propel sperm during emission and ejaculation.
  - Secretion of seminal vesicles and prostate gland during ejaculation.
- **Parasympathetic innervation.** The parasympathetic pathway begins in the S2–S4 spinal cord levels and courses through the pelvic splanchnic nerves to the inferior hypogastric plexus, which cause:
  - Dilation of deep penile arteries result in erection.
  - Secretion of the bulbourethral glands.

Urethral rupture. Perforation or tear of the membranous urethra (within the deep perineal space) from a pelvic fracture results in urine leaking into the retropubic space. Rupture of the spongy urethra from a straddle injury results in urine leaking beneath the deep perineal fascia (Buck's) into the superficial perineal space (extravasated urine) by spreading into the scrotum, around the penis, and superiorly into the abdominal wall.

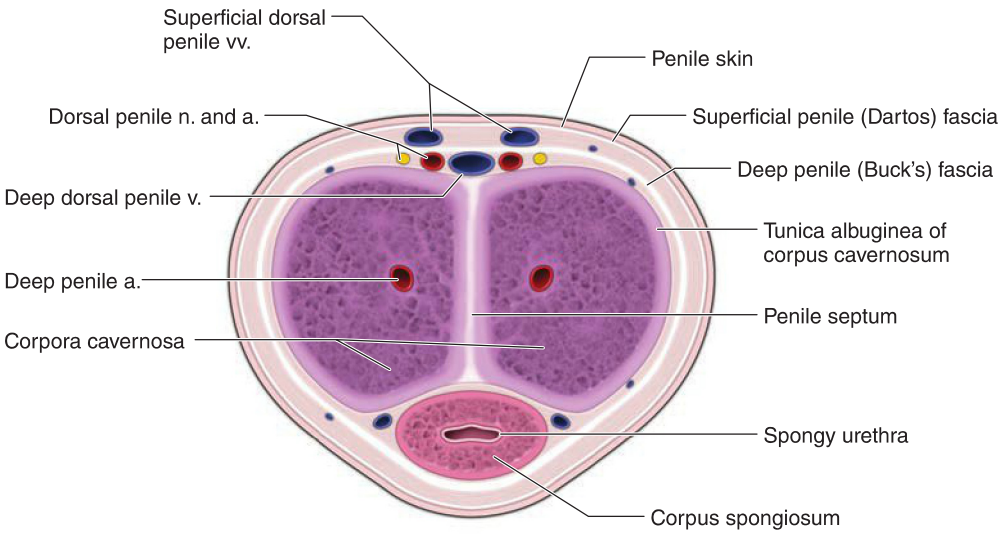

C

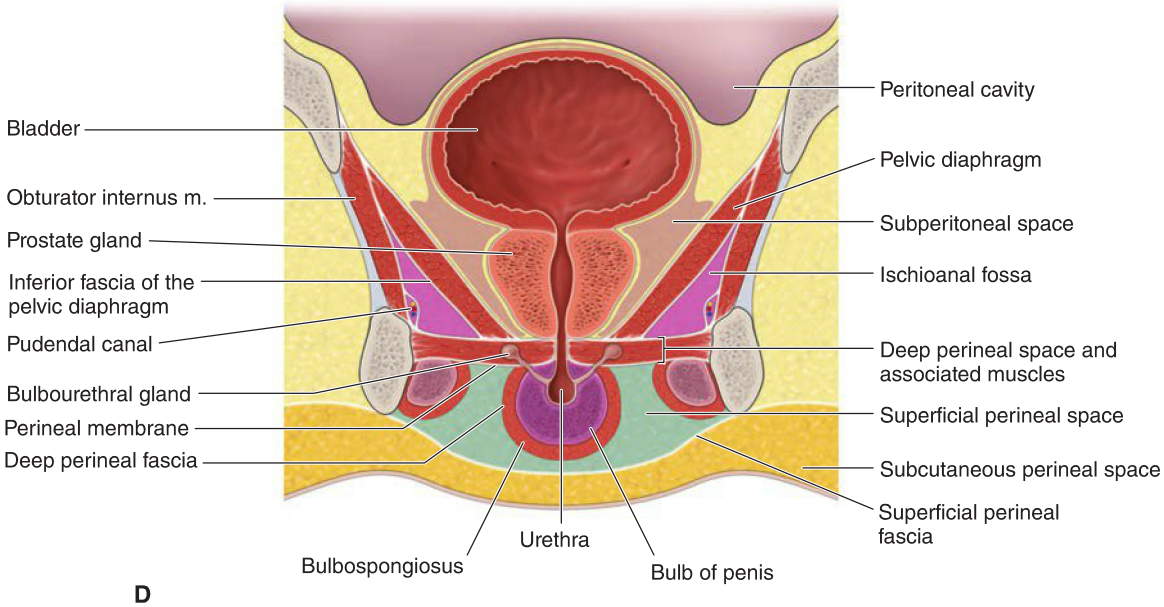

D

Figure 13-1: (*continued*) **C**. Cross-section of the penis. **D**. Coronal section of the male perineum.

THE MALE SEXUAL RESPONSES

BIG PICTURE

The male sexual responses begin with sexual stimulation. Physical stimulation of the genitals is relayed by the somatic sensory nerves (pudendal nerve) to the central nervous system. Parasympathetic impulses arising from the S2–S4 levels of the spinal cord cause blood to flow from the central arteries into the erectile tissue of the penis, resulting in penile erection. Sympathetic impulses from the T10–L2 spinal cord levels cause seminal fluids to mix with the sperm in the urethra in a process called emission. Ejaculation is the expulsion of the semen from the penis, which is caused by sympathetic and somatic innervation.

MALE SEXUAL RESPONSES

The male sexual responses are similar to that of females in many respects, where touch and psychological stimuli promote sexual excitement. During sexual excitement, parasympathetic innervation from the pelvic splanchnic nerves (S2–S4 spinal cord levels) cause the following to occur:

- **Increased blood flow.** Relaxation of smooth muscle in the central arteries of the penis (internal pudendal artery branches) causes blood to fill the spaces of the erectile tissue (e.g., corpus cavernosus), causing the erectile bodies to enlarge and become erect.
  - Because the erectile tissue is surrounded by the deep penile (Buck's) fascia, pressure within the sinusoids increases, causing expansion of the erectile tissue so that the penis becomes elongated and rigid, which compresses the penile veins and therefore impedes venous emptying of the engorged erectile tissue.
  - As long as the stimulation continues or emission and ejaculation occur, the erection is maintained.
- **Lubrication of the urethra.** Bulbourethral glands secrete mucus, which lines the urethra facilitating exit of the semen during ejaculation.

EMISSION AND EJACULATION

When the stimulation reaches maximum intensity, reflexes are initiated that cause the male orgasm. During orgasm, emission and ejaculation occur (due to sympathetic and pudendal nerve innervation):

- **Emission.** Begins with the peristaltic contraction of the ductus deferens, which moves sperm into the urethra, where contractions of the seminal vesicles and the prostate and bulbourethral glands lead to secretion of seminal fluid into the urethra to force the sperm forward. All of the fluids mix in the urethra, forming semen.
- **Ejaculation.** Sympathetic impulses cause rhythmic contraction of smooth muscle within the ductus deferens and urethra. In addition, impulses conveyed through the pudendal nerves cause contraction of the ischiocavernosus and bulbocavernosus muscles, which compress the bases of the penile erectile tissue. These effects together cause wavelike increases in pressure in the erectile tissue of the penis, the genital ducts, and the urethra, which ejaculate the semen from the urethra to the exterior.
  - **Internal urethra sphincter.** Contracts via sympathetic innervation to prevent the entry of urine into the urethra or reflux of semen into the bladder during ejaculation.
- **Systemic effects.** During the male orgasm sensations of intense pleasure and increased blood pressure, pulse rate, and overall muscle tension occur throughout the body.

The following two events are unique to the male orgasm:

1. A refractory period follows the male orgasm and as such a male must wait a period of time before another ejaculation and orgasm can occur.
2. An ejaculatory event accompanies the male orgasm.

General skeletal muscle tone decreases following the male orgasm.

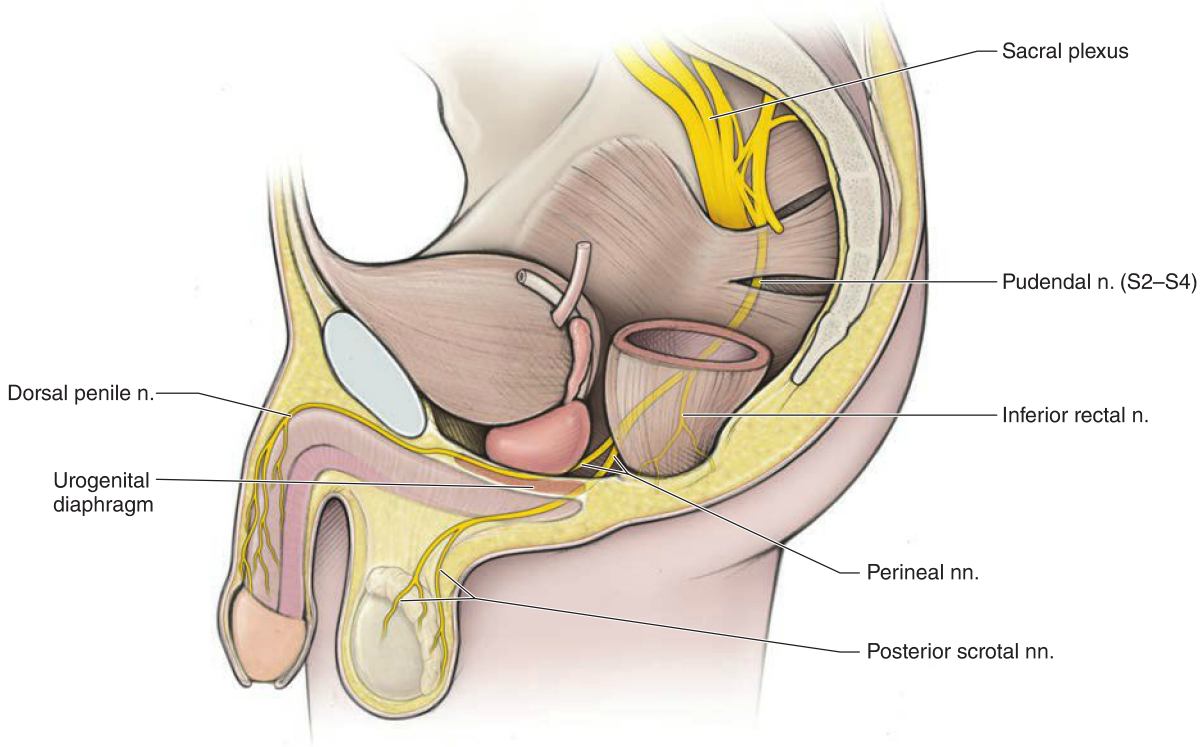

Figure 13-2: Innervation of the penis.

This page intentionally left blank

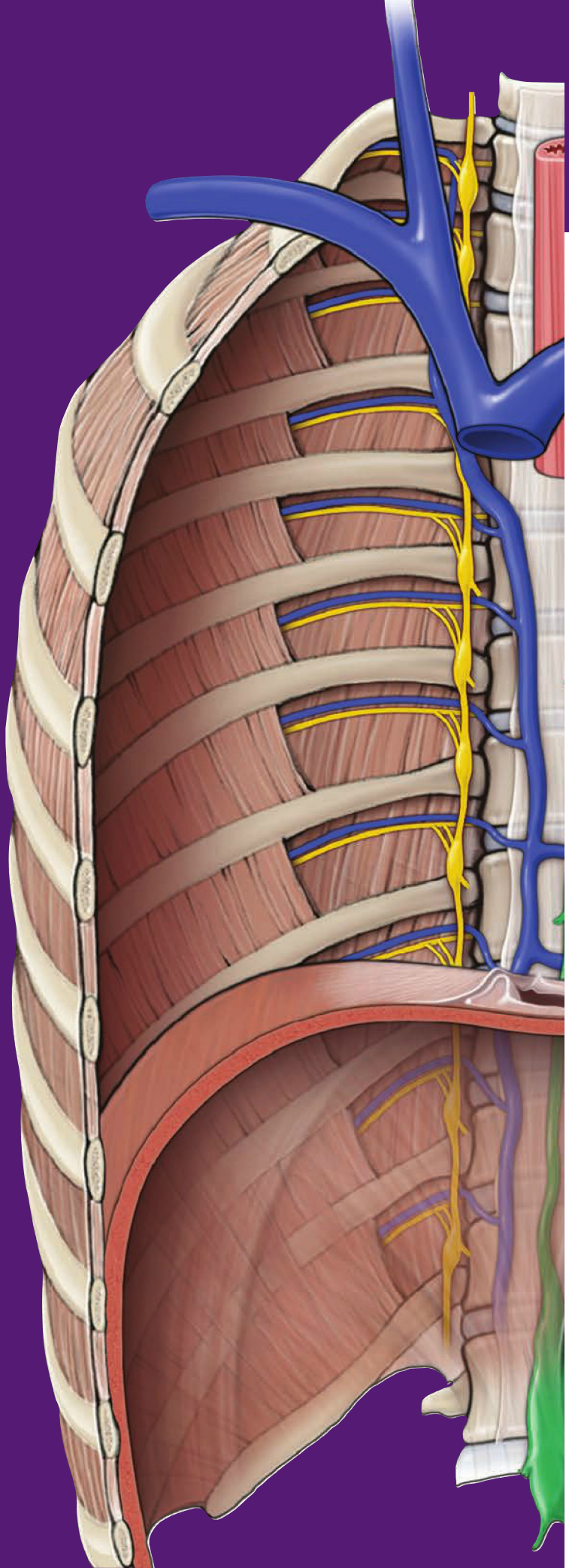

CHAPTER 14

FEMALE REPRODUCTIVE SYSTEM

Female Reproductive System 152
The Female Sexual Responses 156
Study Questions 157
Answers 160

FEMALE REPRODUCTIVE SYSTEM

BIG PICTURE

The female reproductive system consists of the ovaries, uterine tubes, uterus, vagina, and external genitalia. These organs remain underdeveloped for about the first 10 years of life. During adolescence, sexual development occurs and menses first occur (menarche). Cyclic changes occur throughout the reproductive period, with an average cycle length of approximately 28 days. These cycles cease at about the fifth decade of life (menopause), at which time the reproductive organs become atrophic.

INTERNAL FEMALE ORGANS

The following genital organs and glands comprise the female reproductive system (Figure 14-1A and B):

- **Ovaries.** The ovaries are the primary female sex organ because they produce eggs (ovum or oocytes) and sex hormones (e.g., estrogen).
  - **Topography.** Located within the posterior region of the broad ligament, near the lateral wall of the pelvic cavity.
  - **Ovulation.** The release of oocytes from the ovary, through the tunica albiginea and peritoneum into the peritoneal cavity.
  - **Vascular supply.** Supplied by the ovarian artery (aortic origin), which is contained within the suspensory ligament; blood from the ovary drains into pampiniform plexus of veins (which drain into the left renal vein on the left and IVC on the right).
- **Uterine tubes** (aka Fallopian tubes or oviducts). The luminal diameter of the uterine tubes is very narrow (as wide as a human hair). In contrast to the male reproductive system, where the tubules are continuous with the testes, the uterine tubes are separate from the ovaries. Functions of the uterine tube are as follows:
  - **Transport oocyte.** Conveys the fertilized or unfertilized oocytes to the uterus by ciliary action and muscular contraction.
  - **Transport spermatozoa.** Conveys spermatozoa from the uterine cavity to fertilize the oocyte in the infundibulum or ampulla.
  - **Connection.** Connects the uterine cavity with the peritoneal cavity.

  The parts of the uterine tube are as follows:
- **Infundibulum.** The funnel-shaped, peripheral end of the uterine tube.
  - **Fimbriae.** Finger-like projections of the infundibulum. The beating movement of the fimbriae may create currents in the peritoneal fluid to carry oocytes into the uterine tube lumen.
- **Ampulla.** Region of the uterine tube where fertilization usually occurs.
- **Isthmus.** The constricted region of the uterine tube where each tube attaches to the superolateral wall of the uterus.

▽ **Ectopic pregnancy.** Occurs when a fertilized egg implants in the uterine tube or peritoneal cavity. The uterine tubes are not continuous with the ovaries so a risk is that fertilization and implantation may occur outside of the uterine tubes in the peritoneal cavity. Ectopic pregnancies usually result in loss of the fertilized ovum and in hemorrhage, putting the health of the woman at risk. ▼

- **Uterus.** A hollow organ that resembles an inverted pear; located in the pelvic cavity between the rectum and the urinary bladder.
  - **Function.** Organ of gestation. The uterus receives and nourishes a fertilized oocyte until birth.
  - **Topography.** Normally, the uterus is flexed anteriorly, where it joins the vagina; however, the uterus may also be retroverted (flexed posteriorly). The pelvic and urogenital diaphragms support the uterus.

  The uterus consists of the following subdivisions:
- **Fundus.** The rounded (domed) superior surface between the uterine tubes.
- **Body.** The main part of the uterus located between the uterine tubes and isthmus; uterine body is triangular in coronal section and is continuous with the uterine tube and internal os.
- **Isthmus.** The narrow region between the body and the cervix; corresponds to the internal os.
- **Cervix.** The outlet that projects into the vagina. The **internal os** is the junction of the cervical canal and the uterine body; the **external os** communicates with the vaginal canal.
- **Arterial supply.** Branches of the internal iliac artery (uterine arteries) and aorta (ovarian arteries).

▽ **Cervical cancer.** Form of cancer that occurs in women aged 30 to 55 years. This cancer usually arises from the epithelium that covers the cervix. The most effective method of detecting cervical cancer is by a **Papanicolaou (Pap) smear**, in which cervical epithelial cells are scraped from the cervix and examined to determine if the cells are abnormal. ▼

- **Broad ligament.** A double layer of peritoneum that covers the anterior, superior, and posterior surfaces of the uterus, uterine tubes, and ovaries (Figure 14-1C). Has the following parts:
  - **Mesosalpinx.** Fold of the broad ligament that suspends the uterine tubes.
  - **Mesovarium.** Part of the broad ligament by which the ovary is suspended.
  - **Mesometrium.** Covers the anterior and posterior regions of the fundus and body of the uterus.
  - **Suspensory ligament of the ovary.** Region of the broad ligament surrounding the ovarian arteries and veins.
  - **Round ligament.** A fibrous cord that courses from the uterus through the deep inguinal ring and inguinal canal, exits the superficial inguinal ring, and attaches to the labia majora.
  - **Ovarian ligament.** A fibrous cord that connects the ovary to the uterine body.
  - **Transverse cervical (cardinal) ligament.** Condensations of extraperitoneal fascia around the cervix to support the uterus.

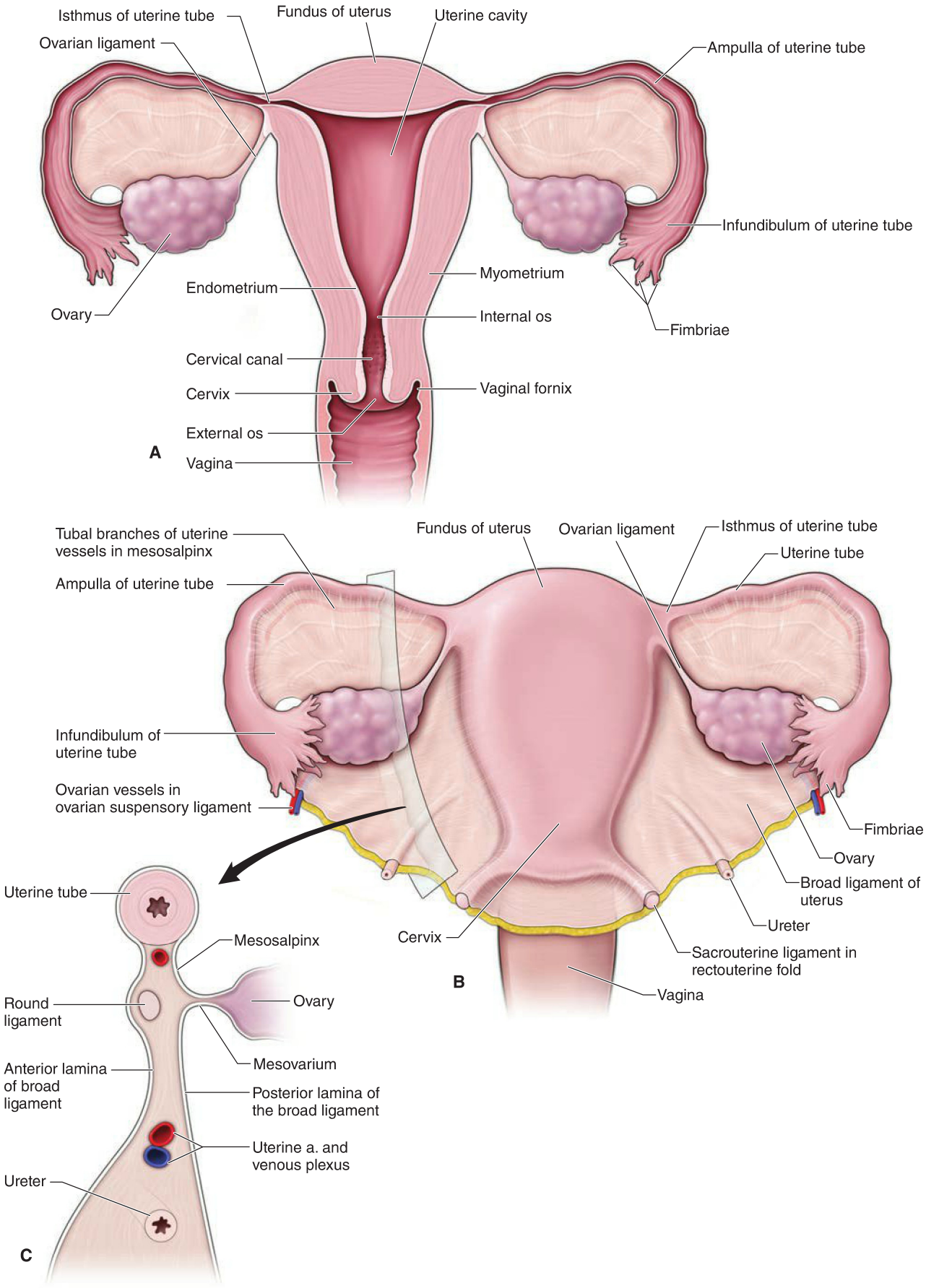

Figure 14-1: A. Coronal section of the uterus and uterine tubes. **B**. Uterus, uterine tubes, and peritoneum. **C**. Sagittal section through the broad ligament of the uterus.

- **Vagina.** Serves as the birth canal, the passageway for the sloughed endometrium from menstruation and is the receptacle for the penis during sexual intercourse. The recesses between the cervix and the vaginal wall are known as the **fornices**. The vascular and lymphatic supply for the vagina is as follows (Figure 14-2A and B):
  - **Vascular supply.** Vaginal branches of the uterine artery and the internal iliac artery.
  - **Lymphatic drainage.** Lymph drains in two directions. The lymphatics from the upper region drain into the internal iliac nodes. Lymphatics from the lower region of the vagina drain into the superficial inguinal nodes.

FEMALE EXTERNAL GENITALIA

The external genitalia, also known as the vulva, have the following structures (Figure 14-2A–D):

- **Mons pubis.** A rounded area of adipose tissue overlying the pubic symphysis.
- **Labia majora.** Paired longitudinal ridges of skin that are inferior and posterior to the mons pubis. The outer surfaces are covered with pubic hair.
- **Labia minora.** Paired hairless skin ridges flanking a midline space known as the vestibule.
- **Vestibule.** The space between the labia minora containing the external urethral orifice, vagina, and ducts from the greater vestibular glands.
- **Clitoris.** An erectile organ that is highly innervated by perineal nerve branches; becomes engorged with blood and erects during stimulation. The clitoris is a multiplanar structure composed of the following structures:
  - **Glans clitoris.** A midline structure that contains thousands of sensory nerve endings forming the female's most erogenous zone. The glans is formed by the union of both corpora cavernosa and is the only external manifestation of the clitoris.
  - **Body of the clitoris.** Composed of both corpora cavernosa situated side by side. The two corpora cavernosa contain erectile tissue and are enclosed in dense fibrous tissue.
  - **Crura of the clitoris.** The body of the clitoris extends up a couple of centimeters before reversing direction. At this point the corpora cavernosa separate from each other and resemble an inverted "V" shape that continues as a pair of crura ("legs"). The crura are anchored to their associated ischiopubic ramus and are covered by the ischiocavernosus muscles.
- **Bulb of vestibule.** Bodies of erectile tissue situated on either side of the vestibule and anchored to the perineal membrane. The bulbospongiosus muscle covers each bulb. During sexual arousal, the bulbs of the vestibule fill with blood, thus contributing to the female erection. The anterior ends taper and attach to the clitoris as two thin bands of erectile tissue.
- **Greater vestibular glands (Bartholin glands).** Glands located deep to the labia minora; release mucus into the vestibule to lubricate the vagina during sexual arousal.
- **Vascular supply of the perineum.** Primarily supplied by internal pudendal artery branches (internal iliac artery origin) and some from external pudendal arterial branches (femoral artery origin).
- **Innervation of the perineum.** Perineal branches from the pudendal nerve (S2–S4).

FEMALE PERINEAL MUSCLES

The following voluntary skeletal muscles reside in the perineum and are innervated by perineal nerve branches:

- **Ischiocavernosus muscles.** Arise from the ischiopubic rami and surround the crura of the clitoris and corpora cavernosa.
- **Bulbospongiosus muscle.** Arises from the perineal body and bulb of the clitoris and inserts into the corpus spongiosum; compresses the erectile tissue of the vestibular bulbs.
- **Superficial transverse perineal muscle.** Arises from the ischial tuberosities and attaches to and supports the perineal body.
- **External urethral sphincter.** Located within the deep perineal space and encircles the membranous urethra to inhibit or enhance the voiding of the bladder during urination.

PERINEAL BODY

A fibromuscular mass located at the center of the perineum, between the anus and vagina. Serves as an attachment site for the superficial perineal, deep perineal, levator ani, and external anal sphincter muscles.

▼ **Episiotomy.** A surgical incision made between the posterior edge of the vagina and the perineal body to enlarge the superficial opening of the birth canal. The incision can be midline or at an angle. An episiotomy is made to minimize random tearing of the perineal structures, particularly across the external anal sphincter during childbirth. If the external anal sphincter is torn, rectal incontinence can occur. ▼

INNERVATION OF THE FEMALE REPRODUCTIVE SYSTEM

Innervation of the female reproductive system is as follows:

- **Somatic innervation.** The pudendal nerve provides motor and sensory innervation to the female genitalia:
  - **Motor.** Superficial perineal muscles (ischiocavernosus, bulbospongiosus, superficial transverse perineal) and deep perineal muscles (external urethral sphincter).
  - **Sensory.** Sensation of the perineum.
- **Sympathetic innervation.** The sympathetic pathways begin in the L1–L2 spinal cord levels and course through the lumbar and sacral splanchnic nerves to the inferior hypogastric plexus, which innervates the smooth muscle of pelvic organs (uterus, uterine tubes, vagina).
- **Parasympathetic innervation.** The parasympathetic pathway begins in the S2–S4 spinal cord levels and courses through the pelvic splanchnic nerves to the inferior hypogastric plexus, which innervates the smooth muscle of perineal arteries and the vestibular glands.

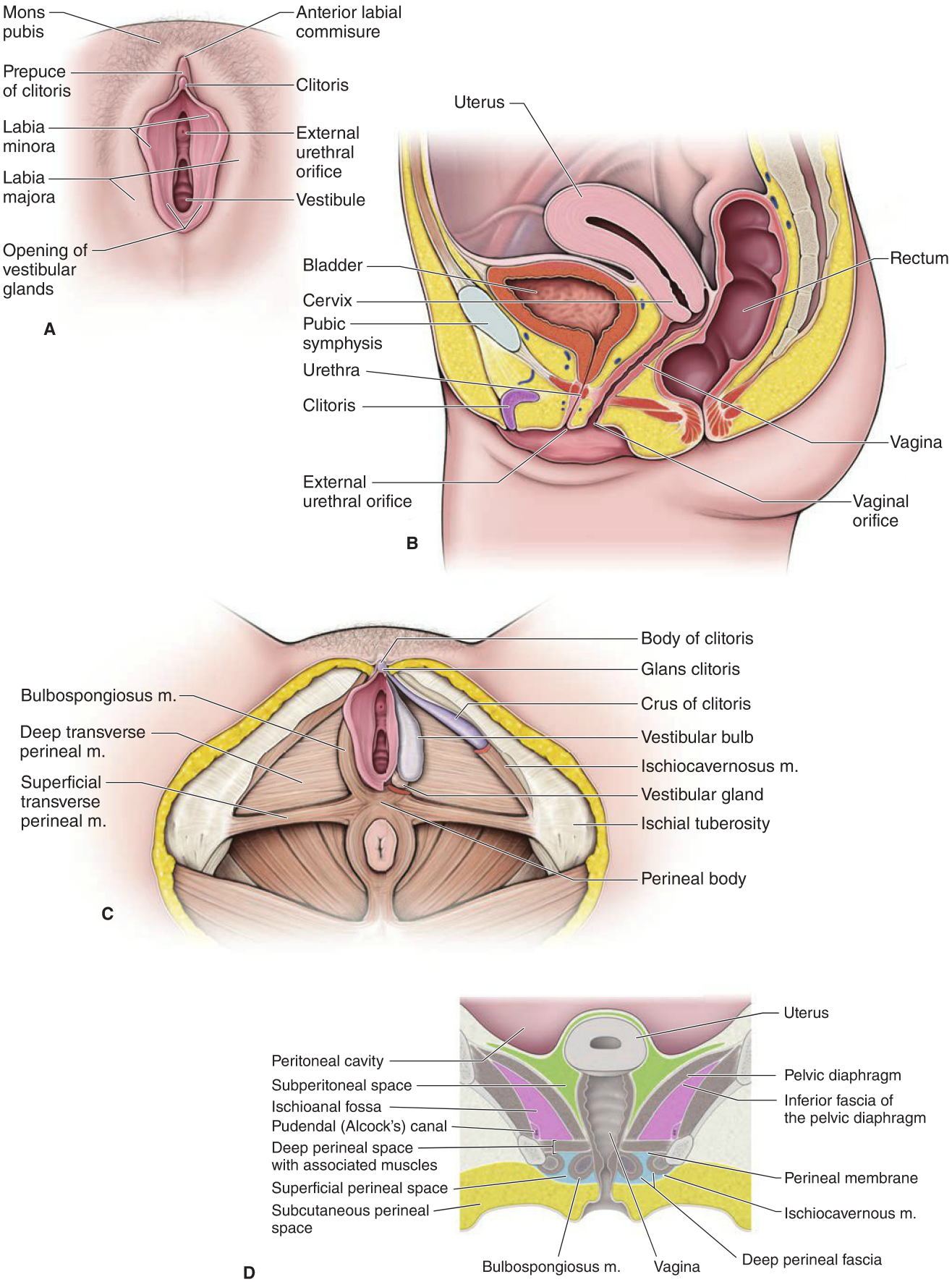

Figure 14-2: A. External female genitalia. **B**. Sagittal section as seen through the female pelvis. **C**. Erectile muscles and tissues in the female. **D**. Coronal section of the female perineum.

THE FEMALE SEXUAL RESPONSES

BIG PICTURE

The female sexual response begins with sexual stimulation. Physical stimulation of the genitals is relayed by the somatic sensory nerves (pudendal nerve) to the central nervous system. Parasympathetic impulses (S2–S4 spinal cord levels) cause blood to flow from the central arteries into the erectile tissue of the clitoris (resulting in clitoral erection) and vestibular glands (resulting in lubrication of the vestibule). During orgasm, sympathetic impulses (T10–L2 spinal cord levels) cause rhythmic contractions of genital organ smooth muscle and pudendal motor innervation cause rhythmic contractions of perineal muscles.

FEMALE SEXUAL RESPONSES

The female sexual responses are similar to those of males in many respects, where touch and psychological stimuli promote sexual excitement. During sexual excitement, parasympathetic innervation from the pelvic splanchnic nerves (S2–S4 spinal cord levels) causes the following to occur:

- **Increased blood flow.** Relaxation of smooth muscle in the internal pudendal artery branches cause the clitoris, vaginal mucosa, and bulbs of the vestibule to swell and become erect due to increased blood volume in the erectile tissues.
  - As long as the stimulation continues, the erection is maintained.
- **Lubrication of vestibule.** Vestibular glands secrete mucus, which lines and lubricates the vestibule, facilitating entry of the penis during intercourse.

When the stimulation reaches maximum intensity, reflexes are initiated that cause the female orgasm (analogous to ejaculation in the male). During orgasm, the following occur:

- **Rhythmic contraction of perineal muscles.** Somatic motor neurons within the pudendal nerve trigger rhythmic contractions of perineal skeletal muscles (bulbocavernosus, ischiocavernosus, and external anal sphincter muscles).
- **Rhythmic contraction of pelvic organs.** Sympathetic neuronal impulses from lumbar and sacral splanchnic nerves (L1–L2 spinal cord origin) cause rhythmic contractions of smooth muscle in the uterus, uterine tubes, and vagina. Research in this field indicates that rhythmic contractions may help transport the sperm upward through the uterus and uterine tubes toward the ovum.
- **Systemic effects.** During female orgasm, sensations of intense pleasure and increased blood pressure, pulse rate, and overall muscle tone occur throughout the body.

The following two events are unique to the female orgasm:

1. No refractory period follows the female orgasm and, as such, a female may have more than one orgasm immediately in succession.
2. No ejaculatory event occurs during female orgasm.

Relaxation of general skeletal muscle tone follows the female orgasm.

STUDY QUESTIONS

Directions: Each of the numbered items or incomplete statements is followed by lettered options. Select the **one** lettered option that is **best** in each case.

1. Which of the following structures most likely converts the greater sciatic notch to the greater sciatic foramen?

A. Obturator membrane
B. Obturator internus muscle
C. Piriformis muscle
D. Sacrospinous ligament
E. Sacrotuberous ligament

2. The ischiopubic or conjoint ramus is formed when the ischial ramus joins which of the following structures?

A. Inferior pubic ramus
B. Ischial spine
C. Pubic symphysis
D. Pubic tubercle
E. Superior pubic ramus
F. Sciatic notch

3. The typical female pubic arch differs from the typical male pubic arch to facilitate childbirth. When compared to the male, the typical female pubic arch can best be described as:

A. Narrower
B. Shorter
C. Taller
D. Wider

4. Diagnosis of an indirect inguinal hernia is determined when intestine protrudes lateral to the inferior epigastric artery through the abdominal body wall. During the physical examination of a male patient, a physician will assess for an indirect hernia by inserting a finger in the scrotum and feeling for bowel that protrudes, as the patient is instructed to turn his head and cough. If an indirect inguinal hernia is present, the physician will most likely feel bowel at which of the following sites?

A. Anterior superior iliac spine
B. Deep inguinal ring
C. McBurney's point
D. Pubic symphysis
E. Superficial inguinal ring

5. During the initial examination of a 3.6 kg (8 lb) male infant delivered at term, urine is found to be leaking from the umbilicus. This infant most likely has an abnormality of which of the following fetal structures?

A. Umbilical arteries
B. Umbilical vein
C. Urachus
D. Urogenital sinus
E. Urorectal septum

6. The external oblique, internal oblique, and transversus abdominis aponeuroses all have a common insertion into which structure?

A. Arcuate line
B. Inguinal ligament
C. Linea alba
D. Pectineal line
E. Pubic tubercle

7. Collateral circulation between the subclavian and external iliac arteries is created by an anastomosis between which of the following structures?

A. Epigastric arteries
B. Lumbar arteries
C. Posterior intercostal arteries
D. Round ligament of the liver
E. Superficial epigastric arteries

8. When performing gastric bypass surgery on a 36-year-old woman, the surgeon identifies the hepatogastric and hepatoduodenal ligaments. Together, both ligaments create which of the following structures?

A. Greater omentum
B. Lesser omentum
C. Mesentery
D. Parietal peritoneum
E. Omental bursa
F. Visceral peritoneum

9. A 38-year-old man with a history of "heartburn" suddenly experiences excruciating pain in the epigastric region of his abdomen. Surgery is performed immediately, and evidence of a perforated ulcer in the posterior wall of the stomach is noted. Stomach contents that have seeped out will most likely be found in which of the following structures?

A. Between the parietal peritoneum and the posterior body wall
B. Greater peritoneal sac
C. Ischioanal fossa
D. Lesser peritoneal sac
E. Paracolic gutter

10. A 20-year-old woman is involved in a vehicular accident and struck on the driver's side of the automobile she is driving. She is taken to the emergency department, where physical examination shows low blood pressure and tenderness on the left midaxillary line. Upon further examination of the patient, the physician also notes a large swelling that protrudes downward and medially below the left costal margin. Which of the following abdominal organs in this patient was most likely injured?

A. Descending colon
B. Left kidney
C. Liver
D. Pancreas
E. Spleen
F. Stomach

11. A 55-year-old man who has alcoholic cirrhosis of the liver is brought to the emergency department because he has been vomiting blood for the past 2 hours. He has a 2-month history of abdominal distention, dilated veins over the anterior abdominal wall, and internal hemorrhoids. Which of the following veins is the most likely origin of the hematemesis?

A. Esophageal veins
B. Inferior mesenteric veins
C. Paraumbilical veins
D. Superior mesenteric vein
E. Superior vena cava

12. A 70-year-old-man has a blockage at the origin of the inferior mesenteric artery. He does not have ischemic pain because of collateral arterial supply. Which of the following arteries is the most likely additional source of blood to the descending colon?

A. Left gastroepiploic
B. Middle colic
C. Sigmoid
D. Splenic
E. Superior rectal

13. A 65-year-old man is admitted to hospital with symptoms of an upper bowel obstruction. A CT scan reveals that a large vessel is compressing the third (transverse) portion of the duodenum. Which of the following vessels is most likely involved in the obstruction?

A. Gastroduodenal artery
B. Inferior mesenteric artery
C. Portal vein
D. Splenic artery
E. Superior mesenteric artery

14. A 25-year-old medical student in good health develops severe pain in the area around her umbilicus. She complains of nausea and is taken to the emergency department. While there, the pain becomes more localized in the lower right quadrant of her abdomen and the physician diagnoses appendicitis. Which of the following nerves perceived pain in the area around the umbilicus and most likely carried the pain sensations to the central nervous system?

A. Inferior hypogastric nerves
B. Lesser splanchnic nerves
C. Pudendal nerves
D. Superior hypogastric nerves
E. Vagus nerves

15. A 52-year-old man undergoes surgery to biopsy iliac lymph nodes. The physician tells the patient that it is important to identify the peripheral spinal nerves to protect them from being damaged during the surgery. The most likely location to find the genitofemoral nerve is coursing along which of the following surfaces?

A. Anterior surface of the psoas major muscle
B. Anterior surface of the quadratus lumborum muscle
C. Inferior surface of the iliacus muscle
D. Inferior surface of rib 12
E. Medial surface of the quadratus lumborum muscle
F. Medial surface of psoas major muscle

16. Three days after giving birth, a 32-year-old woman develops a fever and right lower abdominal pain. Ultrasonography shows a right ovarian vein thrombosis extending proximally. The thrombus most likely extends into the:

A. Ascending lumbar vein
B. Hepatic portal vein
C. Inferior vena cava
D. Renal vein
E. Right internal iliac vein

17. Parasympathetic innervation to the hindgut originates in the S2–S4 spinal cord segments. Parasympathetic neurons travel to the prevertebral plexus via which of the following nerves?

A. Greater splanchnic nerves
B. Least splanchnic nerves
C. Lesser splanchnic nerves
D. Lumbar splanchnic nerves
E. Pelvic splanchnic nerves
F. Sacral splanchnic nerves

18. Sweat glands within the S2 dermatome along the posterior region of the thigh most likely receive innervation via preganglionic sympathetic neurons originating from which of the following central nervous system levels?

A. Brainstem
B. C2 spinal cord level
C. L2 spinal cord level
D. S2 spinal cord level
E. T2 spinal cord level

19. A 56-year-old man who is diagnosed with rectal cancer is undergoing biopsy of several lymph nodes. The nodes most likely to be sampled from this patient will be from the inferior mesenteric nodes, inguinal nodes, and the:

A. Gonadal nodes
B. Internal iliac nodes
C. Portal vein nodes
D. Renal nodes
E. Superior mesenteric nodes

20. A potential complication of multiple term gestational births and vaginal deliveries is a prolapsed uterus. To prevent this condition, Kegel exercises may be advised for supporting the uterus. Which pelvic floor muscle is most likely targeted in Kegel exercises?

A. External anal sphincter
B. Bulbospongiosus muscle
C. Obturator internus muscle
D. Pelvic diaphragm
E. Superficial transverse perineal muscle

21. A 30-year-old woman sustains a stage 4 tear in the perineum during a difficult delivery. In preparation to repair the tear, an anesthetic nerve block is administered to the pudendal nerve as it courses around the sacrospinous ligament. Which of the following areas is most likely blocked by the anesthetic?

A. L2–L4 cutaneous field
B. S1 cutaneous field
C. S2–S4 cutaneous field
D. L2–L4 dermatomes
E. S1 dermatome
F. S2–S4 dermatomes

22. During sexual arousal, an erection is caused by a dilation of arteries filling the erectile tissue of the penis. Innervation of the penile arteries is provided by which of the following nerves?

A. Genitofemoral nerves
B. Ilioinguinal nerves
C. Pelvic splanchnic nerves
D. Pudendal nerves
E. Sacral splanchnic nerves

23. A 42-year-old man has a vasectomy. The physician explains to him that 3 to 4 months after the procedure, when he has an orgasm during sexual intercourse, most likely he will:

A. No longer produce an ejaculate.
B. Still produce an ejaculate and the ejaculate will contain sperm.
C. Still produce an ejaculate but the ejaculate will not contain sperm.

24. Which structure can be palpated anterior to the cervix during a pelvic examination?

A. Cardinal ligament
B. Ovary
C. Pelvic diaphragm
D. Bladder
E. Uterine tube

25. During radical hysterectomy of a 52-year-old woman, the surgeon is careful to avoid damaging the ureters when removing the uterus. The landmark relationship that the surgeon should look for adjacent to the uterus to ensure preservation of each ureter is the ureter coursing:

A. Inferior to the ovarian artery
B. Superior to the ovarian artery
C. Inferior to the uterine artery
D. Superior to the uterine artery
E. Inferior to the uterine tube
F. Superior to the uterine tube

26. A 17-year-old girl is brought to a refugee camp and has significant blood loss. She recently underwent a form of genital mutilation called excision, where the clitoris and labia minora were removed. Direct branches of which of the following arteries are most likely responsible for the blood loss?

A. External iliac
B. Inferior rectal
C. Internal pudendal
D. Ovarian
E. Uterine

ANSWERS

1—D: The sacrospinous ligament courses from the sacrum to the ischial spine and encloses the greater sciatic notch to form a foramen. The obturator membrane and obturator internus muscle cover the obturator foramen. The piriformis muscle courses through the greater sciatic foramen, but does not form it.

2—A: The inferior pubic ramus joins the ischial ramus along the inferior aspect of the os coxa to form the ischiopubic ramus.

3—D: The typical female pubic arch is wider than the typical male pubic arch. The female pubic arch is about 85 degrees compared to 60 degrees in the male.

4—E: An indirect hernia results from bowel protruding through the deep inguinal ring, and through the inguinal canal and into the scrotum via the superficial inguinal ring. Therefore, during the physical examination, the physician will attempt to feel for herniation by digitally palpating the superficial inguinal ring through the scrotal sac.

5—C: The obliterated urachus is a fetal structure that functions by draining urine from the bladder through the umbilicus into the amniotic sac. If the urachus remains patent, it is possible that urine may be leaking out of the umbilicus.

6—C: The aponeuroses from the external oblique, internal oblique, and transversus abdominis muscles create the rectus sheath and then insert on the linea alba between the two rectus abdominis muscles.

7—A: The inferior epigastric artery branches off the external iliac artery and forms an anastomosis with the superior epigastric artery on the posterior surface of the rectus abdominis muscle. The superior epigastric artery branches off the internal thoracic artery, a branch of the subclavian artery.

8—B: The hepatogastric and hepatoduodenal ligaments are the two components of the lesser omentum. They are named for their attachments to the liver, stomach, and duodenum.

9—D: The ulcer in this patient is located on the deep surface of the stomach. Therefore, gastric contents that have seeped out will most likely be found in the lesser peritoneal sac. Recall how the greater peritoneal sac occupies the entire peritoneal cavity, with the exception of the region deep to stomach that is accessed via the epiploic foramen.

10—E: The spleen is located in the upper left quadrant of the abdomen, deep to the left costal margin. The descending colon is posterior to the midaxillary line in the retroperitoneal position, as is the left kidney. The liver is located in the upper right quadrant. The pancreas is in the retroperitoneal position in the midline. The stomach is in the upper left quadrant, but it would not create a swelling as would the damaged spleen.

11—A: A cirrhotic liver prevents all portal blood from flowing through the liver sinusoids. Therefore, portal hypertension occurs with blood backing up to the sites of portocaval anastomoses, including the esophageal veins. Chronic portal hypertension will result in swelling of the esophageal veins and potential hemorrhaging, causing hematemesis.

12—B: The marginal artery of Drummond consists of contributions from the inferior mesenteric artery as well as branches from the superior mesenteric artery via the right and middle colic arteries. Therefore, if the inferior mesenteric artery is blocked, blood flowing from the middle colic artery would provide the additional source of blood to the descending colon.

13—E: The superior mesenteric artery (and vein) course over the third portion of the duodenum.

14—B: The T10 dermatome is associated with the umbilical region. Sensory neurons course from the umbilical skin to the T10 spinal cord level. Visceral sensory neurons course from the appendix to the T10 spinal cord level as well as via the lesser splanchnic nerves. Therefore, the referred pain comes from the lesser splanchnic nerves.

15—A: The genitofemoral nerve courses along the anterior surface of the psoas major muscle.

16—C: The right ovarian vein courses from the right ovary to the inferior vena cava. Therefore, if the thrombosis extends proximally, it will course into the inferior vena cava. If the thrombosis were in the left ovarian vein, it would extend into the left renal vein.

17—E: Pelvic splanchnic nerves exit the ventral rami of spinal nerves S2–S4 and contain preganglionic parasympathetic neurons to the prevertebral plexus, such as the inferior hypogastric plexus. The other splanchnic nerves listed in the choices (i.e., greater, least, lesser, lumbar, and sacral splanchnic nerves) contain only sympathetic neurons.

18—C: Preganglionic sympathetic neurons originate between the T1 and L2 spinal cord levels. Dermatomes within the sacral region, such as the S2 dermatome described in this question, are supplied by sympathetics from the L2 spinal cord level, the lowest of all sympathetic innervation origin.

19—B: Lymphatics in the abdomen generally follow their associated arteries. Clusters of lymph nodes, which are important in monitoring the immune system, are found along the course of the regional arteries. The rectum is supplied by the following:

- Superior rectal artery—branch off the inferior mesenteric artery.
- Middle rectal artery—branch off the internal iliac artery.
- Inferior rectal artery—branch off the internal pudendal artery.

Therefore, if the rectal cancer spreads, it can potentially do so parallel to all three arterial origins. The lymph nodes for the superior and inferior rectal arteries are provided in the stem of the question. The only nodes not mentioned are the internal iliac nodes for the origin of the middle rectal artery.

20—D: The pelvic diaphragm, consisting of the levator ani and coccygeus muscles, forms a hammock-like support to the pelvic floor. In females, it supports the bladder, uterus, and rectum. As such, Kegel exercises, which contract and relax pelvic floor muscles, give strength to the pelvic diaphragm in hopes of preventing tears during childbirth.

21—C: The pudendal nerve carries sensory axons from the genital region to the S2–S4 spinal cord levels. Therefore, the pudendal nerve it supplies sensory distribution for a region of the S2, S3, and S4 dermatomes, but not all of the parts of each dermatome. Therefore, the anesthetic blocked a cutaneous field, not a dermatome.

22—C: Dilation of penile arteries resulting in blood filling erectile tissue is under parasympathetic innervation. Therefore, the pelvic splanchnic nerves carry parasympathetic nerves to the penile arteries. The genitofemoral, ilioinguinal, and pudendal nerves are all somatic and do not cause an erection. The sacral splanchnics are responsible for transporting the sympathetics and will result in ejaculation. Remember, "point" and "shoot" ("p" parasympathetic; "s" sympathetic).

23—C: A vasectomy (a surgical procedure in which the ductus deferens is cut for the purpose of sterilization) will eventually sterilize the male by inhibiting sperm from entering the ejaculate. However, seminal contributions from the seminal vesicles, prostate, and bulbourethral gland will continue. Therefore, ejaculation eventually will result in an ejaculate but without any sperm.

24—D: The bladder is anterior to the vagina.

25—C: The uterine artery courses superiorly over the ureter; in other words, "the water (ureter) courses under the bridge (uterine artery)."

26—C: The internal pudendal artery supplies all of the perineum, including the clitoris and labia minora.

This page intentionally left blank

SECTION 4

HEAD

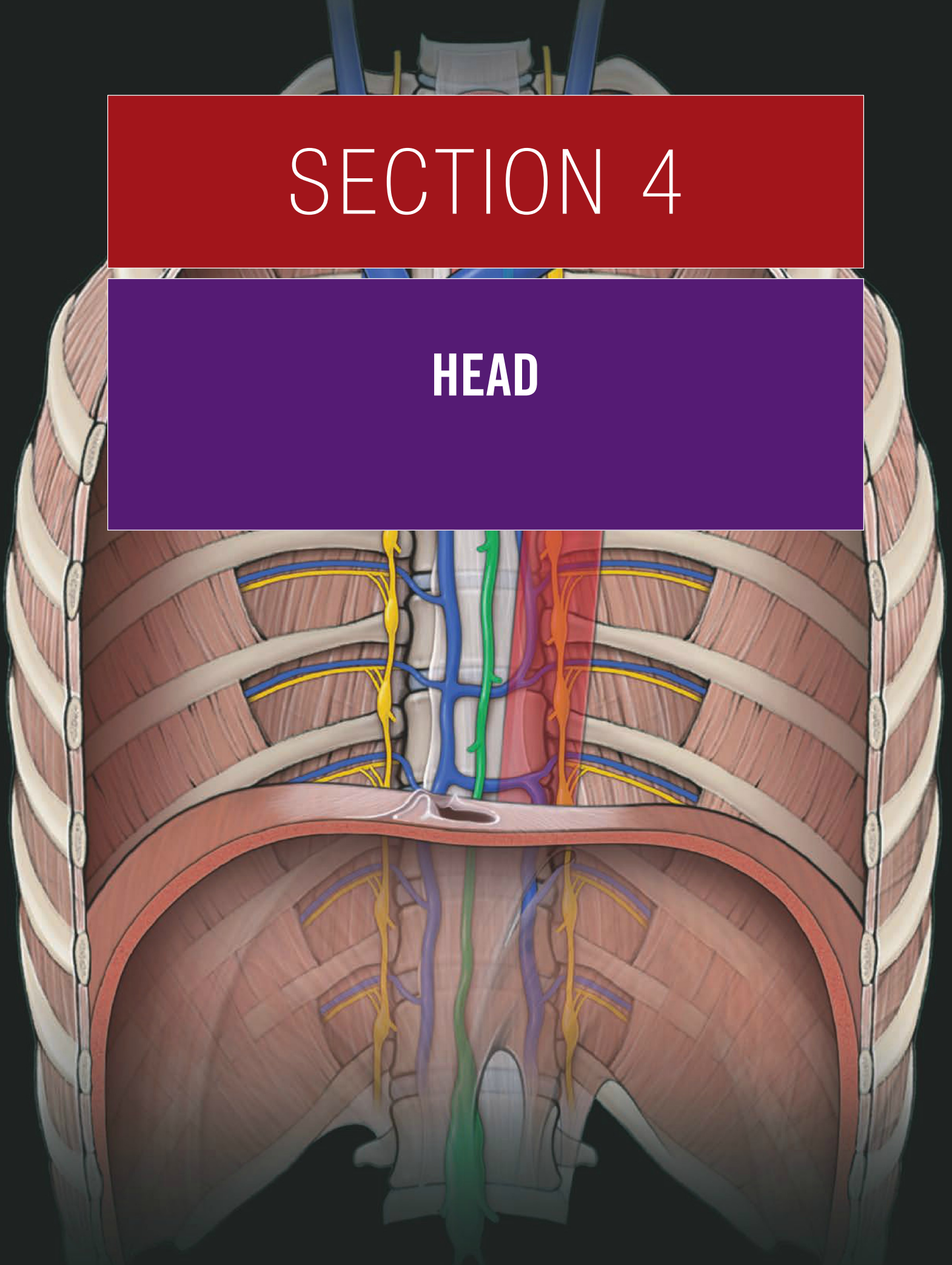

This page intentionally left blank

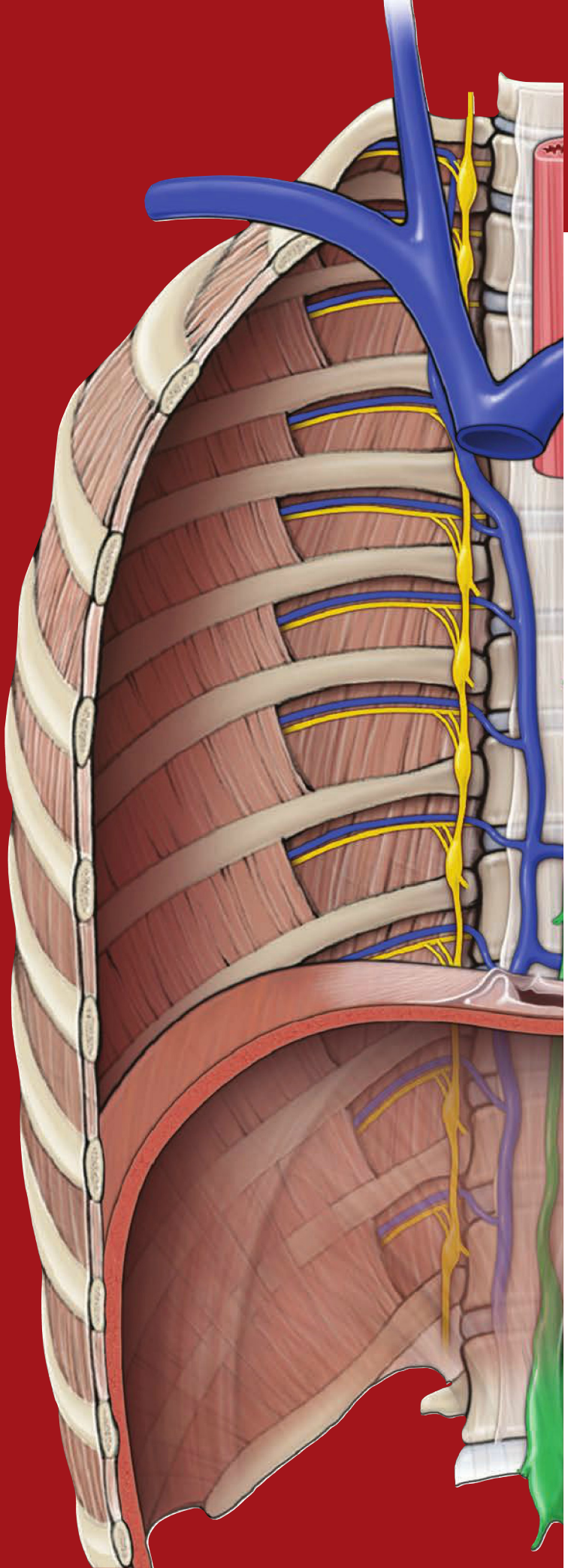

CHAPTER 15

SCALP, SKULL, AND MENINGES

Anatomy of the Scalp 166
Skull 168
Cranial Fossae 170
Meninges 172

ANATOMY OF THE SCALP

BIG PICTURE

The scalp consists of five layers of tissue (from superficial to deep): skin, subcutaneous connective tissue, muscular aponeurosis, loose connective tissue, and pericranium.

LAYERS OF THE SCALP

The layers of the scalp can best be remembered by the acronym "**SCALP**," with each letter representing the tissue layer associated with it (Figure 15-1A).

- **Skin.** Contains sweat and sebaceous glands and usually numerous hair follicles.
- **Connective tissue.** Composed of dense collagenous connective tissue and contains the arteries, veins, and nerves supplying the scalp.
  - Scalp lacerations bleed profusely because the severed arteries do not contract when they are cut because the vessel lumens are held open by this dense connective tissue.
- **Aponeurosis.** Consists of the **frontalis muscle** connected to the **occipitalis muscle via** an aponeurosis known as the **galea aponeurotica**. The galea continues into the temples, investing the auricular muscles, and terminates by attaching to the mastoid processes and the zygomatic arch.
  - If this aponeurosis is lacerated in the coronal plane the frontalis and occipitalis muscles contract in opposite directions and may result in a large gaping wound.
- **Loose connective tissue.** Forms a subaponeurotic layer containing emissary veins.
  - Considered a danger area because infection within this layer can spread easily in all directions. For example, blood in this area easily spreads into the eyelids resulting in "black-eyes." Additionally, blood can course into the cranial cavity via emissary veins.
- **Pericranium.** Is the periosteum over the external surface of the skull; knits into the sutures.

INNERVATION OF THE SCALP

The scalp receives its cutaneous innervation as follows (Figure 15-1B):

- **Posterior region of the scalp.** Lesser occipital and greater occipital nerve branches (C2 spinal nerve level).
- **Anterior region of the scalp. Supraorbital and supratrochlear nerves** (ophthalmic division of the trigeminal nerve; CN V-1).
- **Lateral region of the scalp.** Maxillary (CN V-2) and mandibular (CN V-3) divisions of the trigeminal nerve (the zygomaticotemporal and auriculotemporal nerves, respectively).

ARTERIAL SUPPLY OF THE SCALP

The scalp receives a rich arterial supply via external and internal carotid branches (Figure 15-1C).

- **External carotid artery.** Branches include the occipital, posterior auricular, and superficial temporal arteries.
- **Internal carotid artery.** Branches include the supraorbital and supratrochlear arteries.

▽ **Scalp arterial anastomoses.** Scalp lacerations often bleed profusely because arteries bleed from both ends of the laceration due to the abundant anastomose. Additionally, it is important to wear a hat in the winter because a lot of body heat is lost through the rich arterial network in the scalp. ▼

VENOUS DRAINAGE OF THE SCALP

Blood from the scalp drains via the following veins:

- **Supraorbital and supratrochlear veins.** Drain into the facial vein.
- **Superficial temporal vein.** Joins with the maxillary vein to form the retromandibular vein in the parotid salivary gland.
- **Posterior auricular vein.** Joins with the posterior division of the retromandibular vein to form the external jugular vein.

Additionally, scalp veins connect with diploic and emissary veins:

- **Diploic veins.** Course in the diploë cranial bones of the skull and connect with the dural venous sinuses via emissary veins.
- **Emissary veins.** Connect veins of the scalp and skull with the dural venous sinuses.

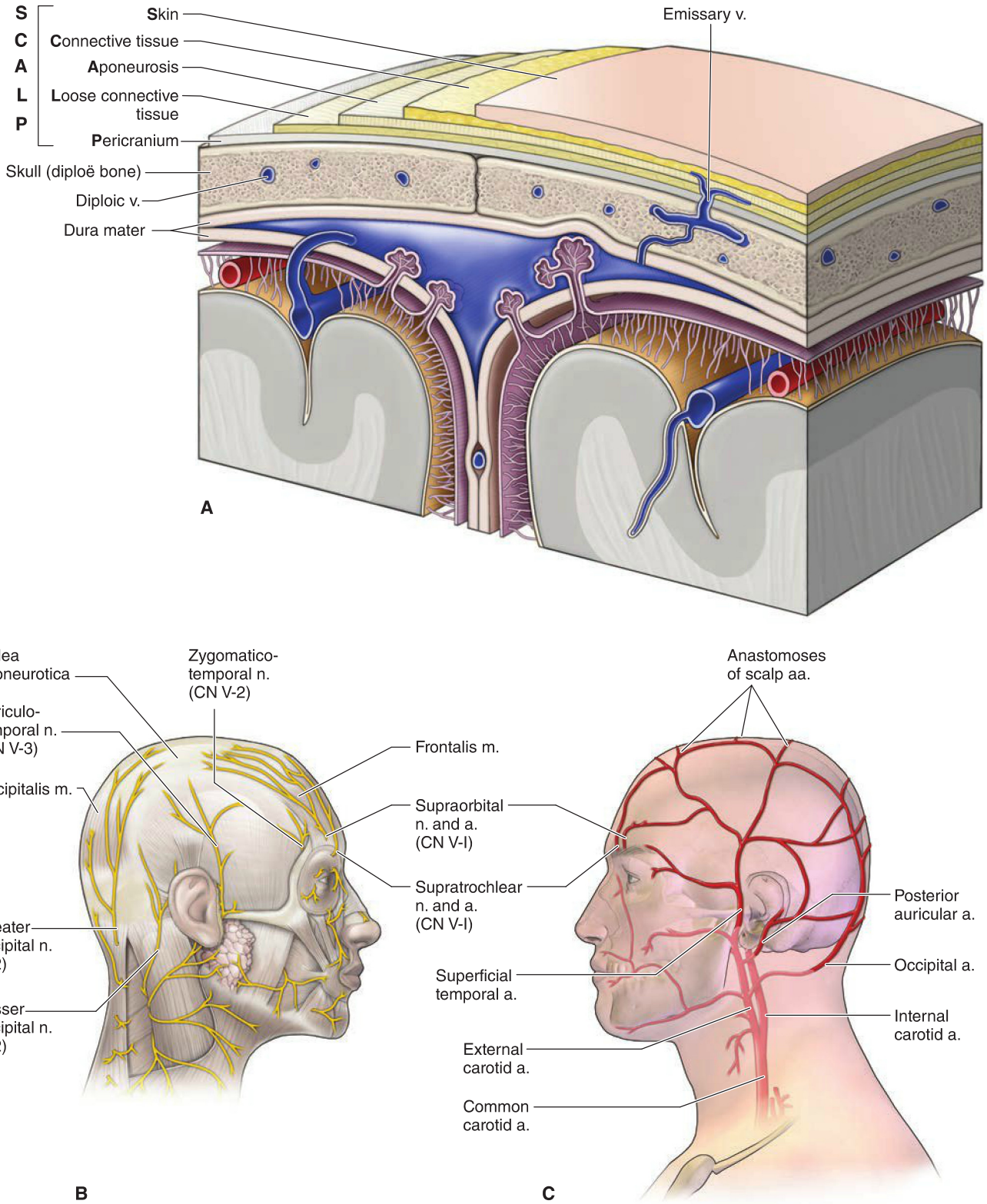

Figure 15-1: A. Coronal section of the head. Cutaneous innervation (**B**) and arterial supply (**C**) to the scalp.

SKULL

BIG PICTURE

The skull is made of 8 cranial bones and 14 facial bones.

BONES OF THE SKULL

The cranial bones of the skull and its surrounding meninges protect the brain (Figure 15-2A). The outer and inner surfaces of the skull are covered by periosteum, known respectively as the pericranium and the endocranium. The periosteum is continuous at the sutures of the skull. The cranial bones consist of spongy bone "sandwiched" between two layers of compact bone. The bones of the skull are as follows (Figure 15-2B–E):

- **Frontal bone.** The unpaired frontal bone underlies the forehead, roof of the orbit, and a smooth median prominence called the **glabella**.
- **Parietal bone.** The paired parietal bones form the superior and lateral aspects of the skull.
- **Temporal bone.** The paired temporal bones consist of the following parts:
  - **Squamous part.** Forms the lateral portion of the skull.
  - **Petrous part.** Forms the most dense bone in the body and encloses the internal ear (cochlea and semicircular canals) and middle ear (malleus, incus, and stapes).
  - **Mastoid part.** Forms the substance within the mastoid process; contains the mastoid air cells.
  - **Tympanic part.** Houses the external auditory meatus and tympanic cavity.
- **Occipital bone.** The occipital bone encloses the foramen magnum, which transmits the spinal cord and vertebral arteries.
- **Sphenoid bone.** The sphenoid bone consists of a body, which houses the sphenoid sinus, and the greater and lesser wings and the pterygoid processes.
- **Ethmoid bone.** The ethmoid bone is located between the orbits and consists of the cribriform plate, the perpendicular plate, and the ethmoid air cells.

SUTURES OF THE SKULL

Sutures are immovable fibrous joints between the bones of the skull. The principal sutures of the skull are as follows:

- **Coronal suture.** Joins the frontal bone and the two parietal bones. The coronal suture courses in the coronal plane.
- **Sagittal suture.** Joins the paired parietal bones. The sagittal suture courses in the sagittal plane.
- **Squamous suture.** Joins the parietal and temporal bones.
- **Lambdoid suture.** Joins the parietal bones with the occipital bone.
- **Pterion.** Junction of the frontal, parietal, and temporal bones in the lateral aspect of the skull.

▽ The anterior division of the middle meningeal artery courses deep to the pterion on the inner surface of the skull. A blow to the pterion, therefore, could rupture the middle meningeal artery and result in an **epidural (extradural) hematoma**, which is a buildup of blood between the dura mater and the skull. On a radiograph, an epidural hematoma appears as a convex shape because sutures at the sites where the periosteal dura is more firmly attached to the skull stop the hematoma from expanding. As a result, epidural hematomas expand inward toward the brain instead of along the side of the skull, which occurs in a subdural hematoma. Unconsciousness and death occur rapidly because of the bleeding that dissects a wide space as it strips the dura from the inner surface of the skull, causing pressure on the brain. ▼

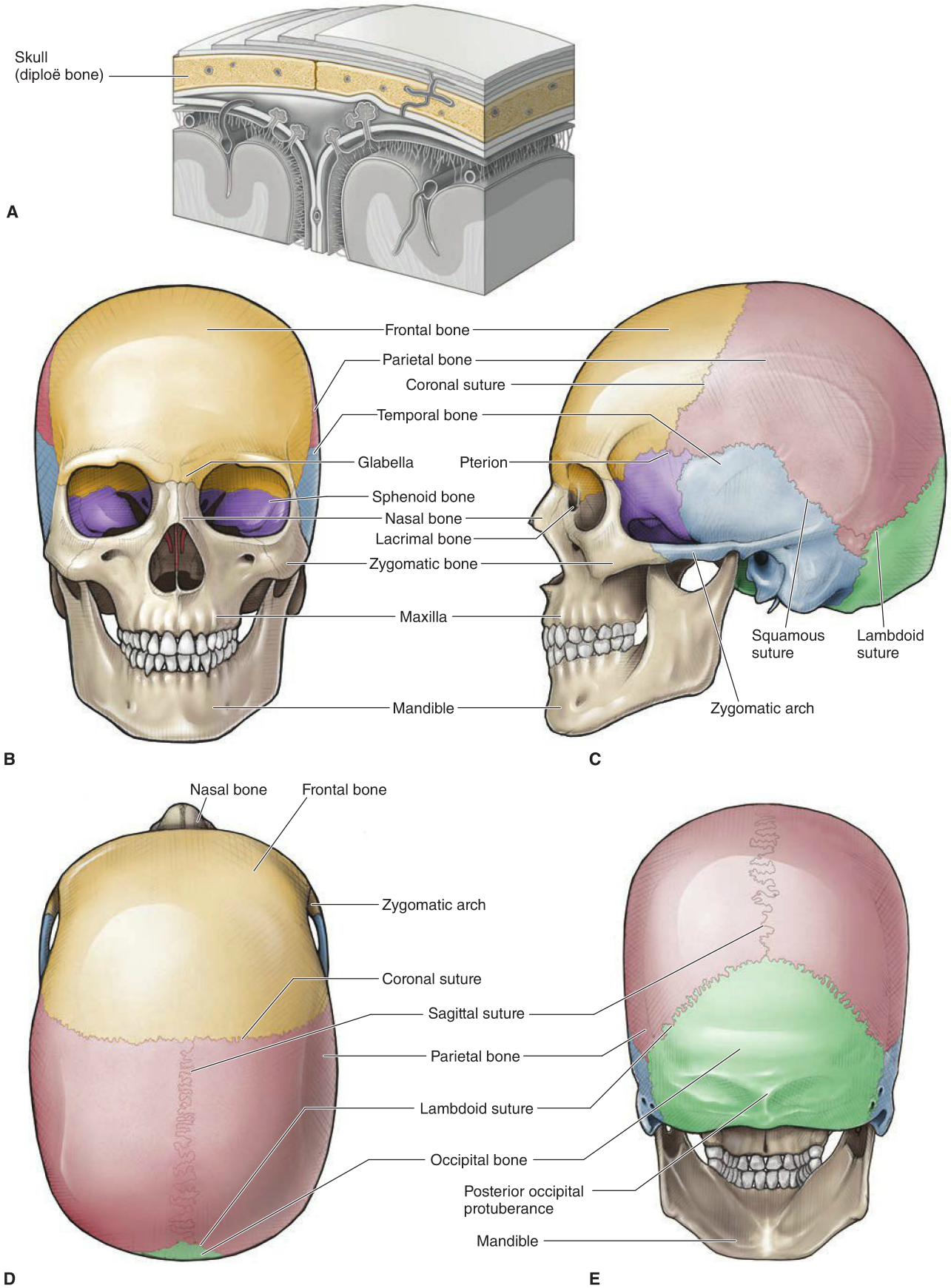

Figure 15-2: A. Coronal section of the head; anterior (**B**), anterior (**C**), lateral (**D**), superior (**E**), and posterior views.

CRANIAL FOSSAE

BIG PICTURE

The base of the skull forms the floor on which the brain lies and consists of three large depressions that lie on different levels known as the anterior, middle, and posterior cranial fossae (Figure 15-3A).

ANTERIOR CRANIAL FOSSA

The anterior cranial fossa houses the frontal lobes of the cerebrum and has the following bony landmarks (Figure 15-3B and C):

- **Cribriform plate.** Transmits the olfactory nerves (CN I) from the nasal cavity to the olfactory bulbs.
- **Crista galli.** Projects superiorly from the cribriform plate and serves as an attachment for the falx cerebri.
- **Lesser wing of the sphenoid bone.** Forms a ridge separating the anterior and the middle cranial fossae.

MIDDLE CRANIAL FOSSA

The middle cranial fossa is deeper than the anterior cranial fossa and is separated from the posterior cranial fossa by the clivus. The middle cranial fossa supports the temporal lobes of the cerebrum and has the following bony landmarks (Figure 15-3B and C):

- **Sella turcica.** A deep central depression in the sphenoid bone that houses the pituitary gland. The sella turcica is located superior to the sphenoid sinus.
- **Optic canal.** A passage that transmits the optic nerve (CN II) and ophthalmic artery.
- **Superior orbital fissure.** A longitudinal fissure in the orbit that transmits the oculomotor nerve (CN III), trochlear nerve (CN IV), ophthalmic division of the trigeminal nerve (CN V-1), abducens nerve (CN VI), and the superior ophthalmic veins.
- **Carotid canal.** Transmits the internal carotid artery from the neck into the cranium. In addition, the carotid plexus of sympathetic nerves accompanies the internal carotid artery to provide innervation to the superior tarsal muscle, the dilator pupil muscle, the sweat glands of the face and scalp, and the blood vessels in the head.
- **Foramen rotundum.** Located posterior to the medial end of the superior orbital fissure. The foramen rotundum transmits the maxillary nerve (CN V-2) en route to the pterygopalatine fossa. CN V-2 supplies the skin, teeth, and mucosa associated with the maxillary bone.
- **Foramen ovale.** A large ovale foramen posterolateral to the foramen rotundum. The foramen ovale communicates with the infratemporal fossa and transmits the mandibular nerve (CN V-3).
- **Foramen spinosum.** Transmits the middle meningeal artery from the maxillary artery in the infratemporal fossa into the cranial vault.
- **Foramen lacerum.** A triangular hole located on the sides of the sphenoid body. In a dried skull (e.g., such as that found in an anatomy laboratory), this foramen is patent; however, in vivo, the foramen is occluded by cartilage. After exiting the carotid canal, the internal carotid artery travels over the roof of the foramen lacerum. The greater petrosal nerve courses through the foramen lacerum en route to the pterygoid canal.

POSTERIOR CRANIAL FOSSA

The posterior cranial fossa is the lowest and deepest of the fossae and houses the cerebellum, pons, and medulla oblongata and has the following bony landmarks (Figure 15-3B and C):

- **Internal acoustic (auditory) meatus.** Transmits the facial nerve (CN VII) and the vestibulocochlear nerve (CN VIII) along with the labyrinthine artery.
- **Jugular foramen.** Transmits the glossopharyngeal (CN IX), vagus (CN X), and spinal accessory (CN XI) nerves as well as the internal jugular vein. The temporal and occipital bones form the jugular foramen.
- **Hypoglossal canal.** Transmits the hypoglossal nerve (CN XII).
- **Foramen magnum.** The largest foramen of the skull. The medulla oblongata, an extension of the spinal cord, enters and exits the cranial vault, along with the vertebral arteries, through the foramen magnum.
- **Mastoid foramen.** Transmits a branch of the occipital artery to the dura mater and mastoid emissary vein.

FORAMINA IN THE BASE OF THE SKULL

- **Petrotympanic fissure.** Located posterior to the mandibular fossa and serves as the opening of the chordae tympani nerve, a branch of CN VII, entering the infratemporal fossa.
- **Stylomastoid foramen.** An opening between the styloid and mastoid processes of the temporal bone. The facial nerve proper (CN VII) exits the foramen en route to innervate muscles of facial expression.
- **Incisive canal.** Located anteriorly on the hard palate; traverses the nasopalatine nerve, artery and vein.
- **Greater and lesser palatine canals.** Located posteriorly on the hard palate; traverses the greater and lesser palatine nerves, arteries and veins.

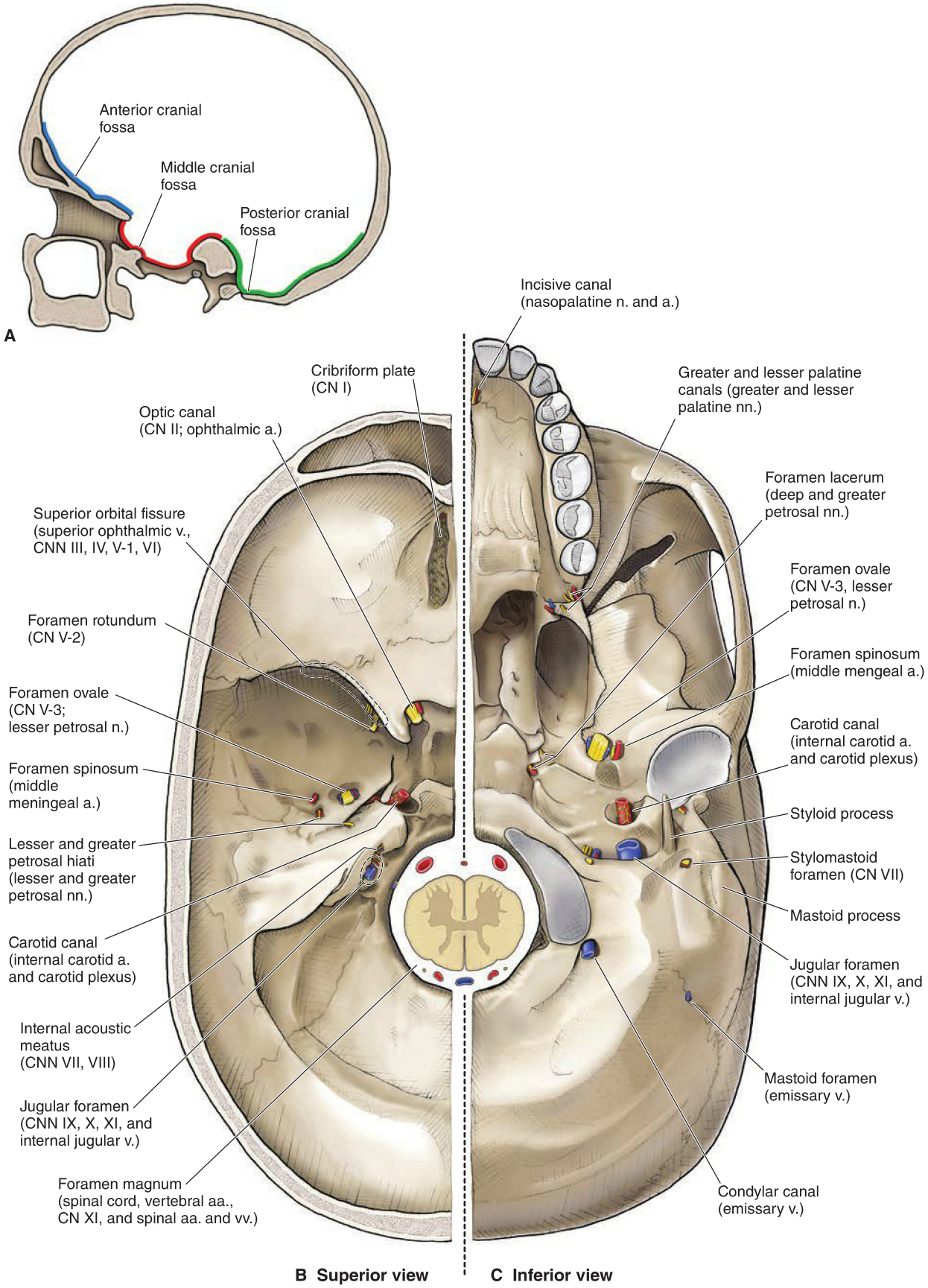

Figure 15-3: A. Sagittal section of the skull showing the cranial fossae. Superior (**B**) and inferior (**C**) views of the cranial base.

MENINGES

BIG PICTURE

The brain is surrounded and protected by three connective tissue layers called meninges. These meninges, from superficial to deep, are the dura mater, arachnoid mater, and pia mater.

DURA MATER

The dura mater is composed of the following two layers (Figure 15-4A):

- **Periosteal layer.** The periosteal layer of the dura mater is the periosteum lining the internal surface of the skull and, as such, is intimately attached to the cranial bones and sutures.
- **Meningeal layer.** The meningeal layer is the dura mater proper and is composed of dense collagenous connective tissue that is continuous with the dura mater of the spinal cord. The dura mater envelopes the cranial nerves like a sleeve, which then fuse with the epineurium of the nerves outside the skull.

The two layers of dura mater are bound together. However, the layers separate at numerous locations to form dural septae or dural venous sinuses.

DURAL SEPTAE Much like a seat belt assists in protecting a passenger from hitting the inside of the vehicle during an accident, four dural septae restrict displacement of the brain during everyday movements (Figure 15-4B):

- **Falx cerebri.** A sickle-shaped layer of dura mater that separates the cerebral hemispheres. The falx cerebri is attached anteriorly to the crista galli and posteriorly to the tentorium cerebelli. The superior and inferior sagittal sinuses form the superior and inferior margins. The inferior edge of the falx cerebri courses along the superior surface of the corpus callosum.
- **Tentorium cerebelli.** Separates the occipital lobes of the cerebrum from the cerebellum. The tentorium cerebelli encloses the transverse sinuses posteriorly and the superior petrosal sinuses anteriorly (Figure 15-4C).
- **Falx cerebelli.** A small triangular extension of the tentorium cerebelli containing the occipital sinus. The falx cerebelli descends, separating the cerebellar lobes, and terminates at the foramen magnum.
- **Diaphragma sellae.** A circular horizontal fold of dura that covers the pituitary by forming a roof over the sella turcica.

DURAL VENOUS SINUSES The dural venous sinuses are venous channels located between the periosteal and the meningeal layers of the dura mater.

- The dural venous sinuses are similar to veins in that they contain venous blood and are lined with endothelium but they lack valves and a tunica media.
- They serve as a receptacle for blood from the cerebral, diploic, and emissary veins.
- They also receive the cerebrospinal fluid (CSF), drained by the arachnoid granulations.
- Blood in the dural venous sinuses primarily drains into the internal jugular veins.

The following are the primary dural venous sinuses:

- **Superior sagittal sinus.** Courses along the superior border of the falx cerebri; joins with the confluence of sinuses.
- **Inferior sagittal sinus.** Course along the inferior border of the falx cerebri; joins with the **great cerebral vein (of Galen)** to form the straight sinus.
- **Straight sinus.** Courses along the line of attachment of the falx cerebri to the tentorium cerebelli.
- **Occipital sinus.** Courses within the falx cerebelli.
- **Confluence of sinuses.** Forms the union of the superior sagittal straight and occipital sinuses and is located deep to the internal occipital protuberance.
- **Transverse sinus.** Courses laterally from the confluence of sinuses within the tentorium cerebelli.
- **Sigmoid sinus.** A continuation of the transverse sinus and descends in an S-shaped groove to join with the **inferior petrosal sinus** at the jugular foramen, forming the **internal jugular vein**.
- **Cavernous sinus.** Located on each side of the sella turcica.
  - Cranial nerves (CNN) III, IV, V-1, and V-2 course anteriorly through the lateral walls of the sinus.
  - The internal carotid artery and CN VI course through the middle of the sinus.
  - The cavernous sinus communicates with the pterygoid venous plexus via emissary veins and the superior and inferior ophthalmic veins.
- **Superior petrosal sinus.** Courses superiorly along the petrous part of the temporal bone; drains into the transverse sinus.
- **Inferior petrosal sinus.** Courses inferiorly along the petrous part of the temporal bone; drains into the cavernous sinus.
- **Diploic veins.** Course within the spongy portion of cranial bones.
- **Emissary veins.** Course between the scalp and dural venous sinuses.

▽ **Carotid-cavernous sinus fistula.** The cavernous sinus is the only location in the body where an artery courses through a venous structure. A carotid-cavernous sinus fistula forms when the internal carotid artery ruptures within the cavernous sinus. ▼

▽ **Pituitary tumors.** A pituitary tumor can expand in the direction of least resistance and compress cavernous sinus structures (CNN III, IV, V-1, V-2, and VI). When this occurs symptoms may include paralysis of the extraocular muscles and sensory loss in the forehead and maxillary region. ▼

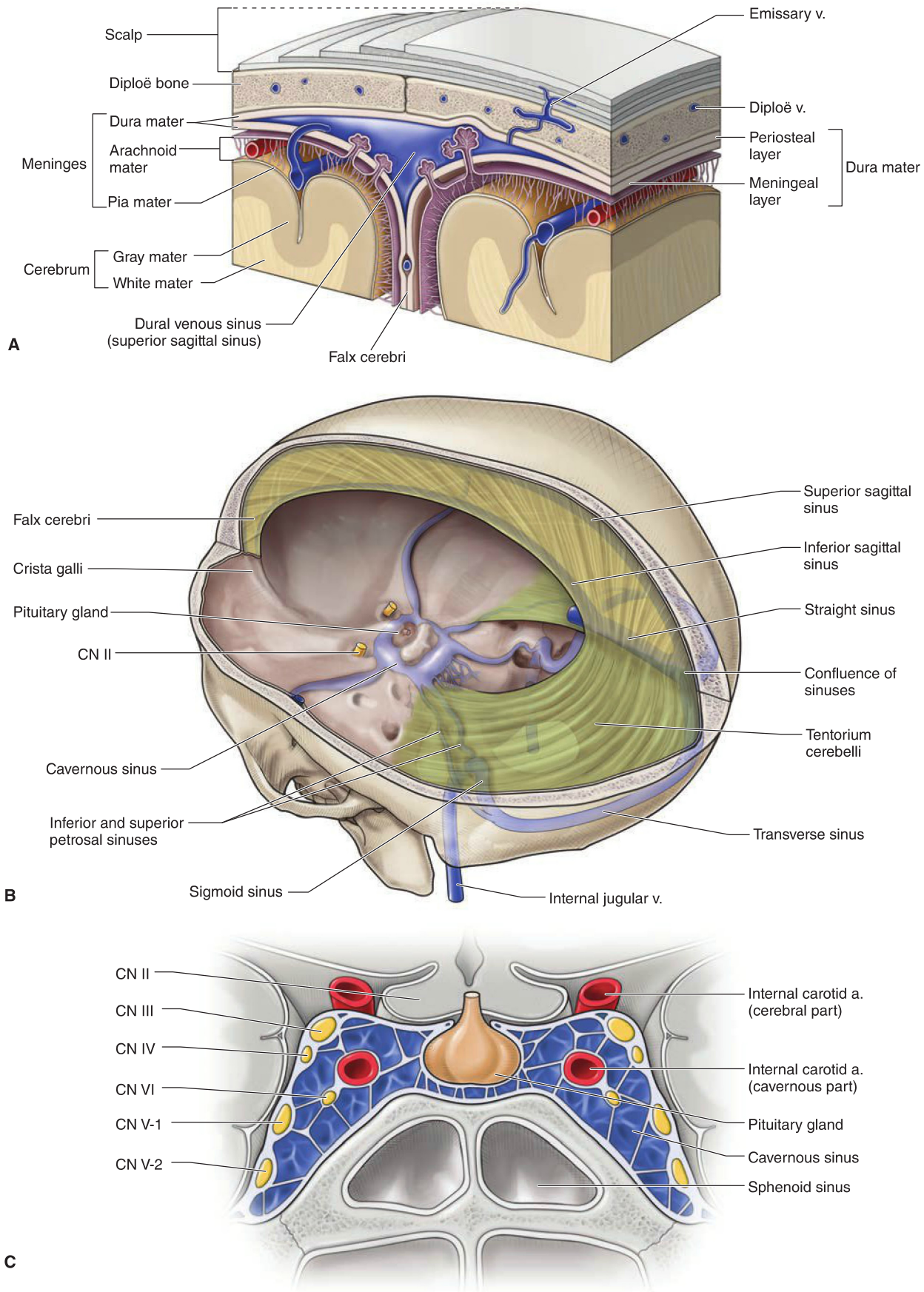

Figure 15-4: A. Coronal section of the head. **B**. Posterosuperior view of the dural septae and dural venous sinuses. **C**. Coronal section through the sphenoid bone highlighting the cavernous sinuses.

ARACHNOID MATER

The arachnoid mater is a thin, transparent layer that surrounds the brain and spinal cord. The arachnoid mater is connected to the pia mater by web-like connective tissue filaments, hence the name "arachnoid" mater (Figure 15-4D).

- **Subarachnoid space.** The space between the arachnoid mater and the pia mater in which CSF circulates. Many cerebral vessels course around the surface of the brain within the subarachnoid space.
- **Arachnoid villi (granulations).** Highly folded arachnoid mater that projects into the superior sagittal sinus and lateral lacunae (lateral extensions of the superior sagittal sinus).
  - Arachnoid villi serve as sites where CSF diffuses into the superior sagittal sinus.
  - Arachnoid villi often produce indentations in the inner surface of the calvarium.

Subdural hematoma. Generally, there is no space between the dura mater and the arachnoid mater. However, trauma to the head may stretch and rupture a bridging (cerebral) vein, resulting in bleeding into the subdural space (**subdural hematoma**). Because the damaged vessel is a vein, the increase in intracranial pressure and the effect of compressing the brain is much slower when compared to an epidural hematoma, which is caused by tearing of an artery. As a result, a subdural hematoma may develop over a period of days or even a week. Enlarging the subdural space is one factor that increases the risk of a subdural hematoma. As the subdural space enlarges, the bridging veins that traverse the space travel over a wider distance, causing them to be more vulnerable to tears. As a result, infants (who have smaller brains), the elderly (whose brains atrophy with age), and alcoholics (whose brains atrophy from alcohol use) are at increased risk of developing a subdural hematoma because of the tension of traversing vessels from the shrinking brain to the dural venous sinus. Subdural hematomas spread along the internal surface of the skull, creating a concave shape that follows the curve of the brain. The spread of blood is limited to one side of the brain due to dural reflections such as the tentorium cerebelli and falx cerebri. Contrast the spread of subdural hematomas to that of epidural hematomas that are limited in their spread due to the sutures.

Subarachnoid hemorrhage. Defined as bleeding into the subarachnoid space usually due to a ruptured cerebral artery.

PIA MATER

The pia mater is the most internal and delicate of the meninges surrounding the brain and spinal cord (Figure 15-4D).

- Forms a sheath around blood vessels as they course into the fissures and sulci and penetrate the brain.
- The pia mater joins with the ependymal cells that line the ventricles of the brain to form choroid plexuses that produce CSF.

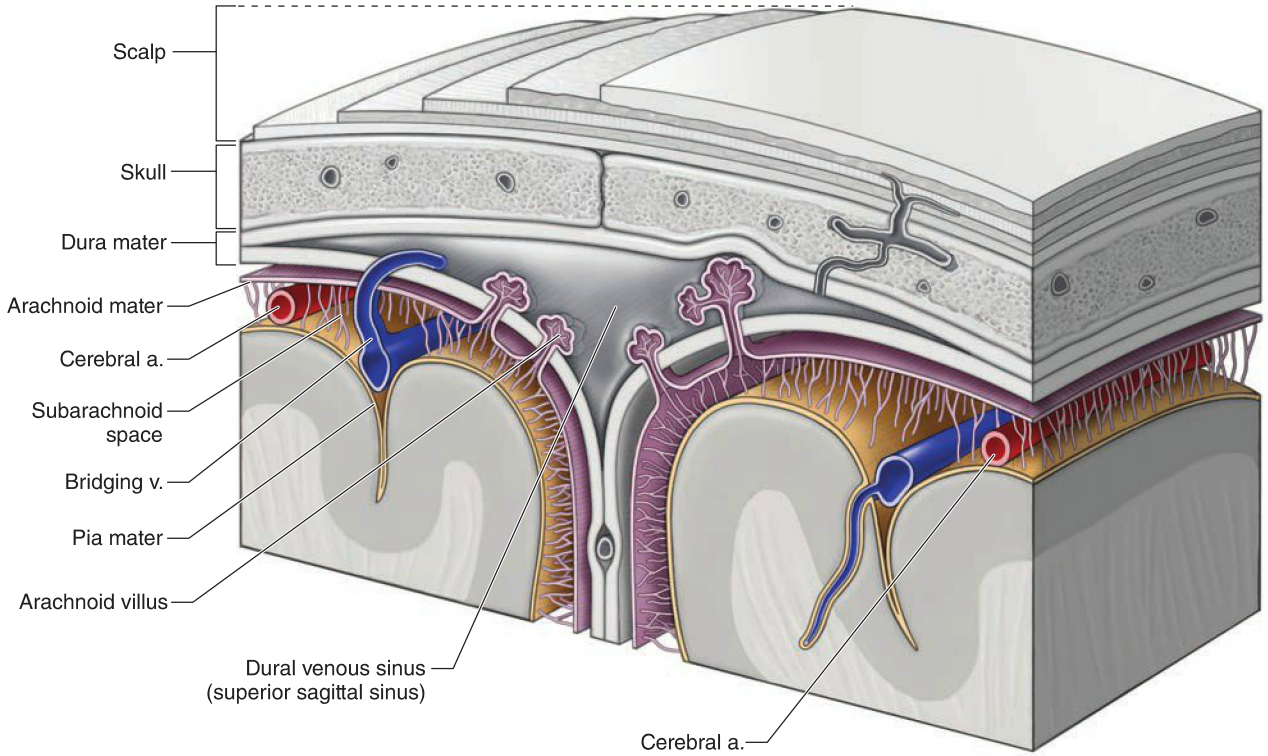

D

Figure 15-4: (*continued*) **D**. Coronal section of the head highlighting the arachnoid and pia mater.

This page intentionally left blank

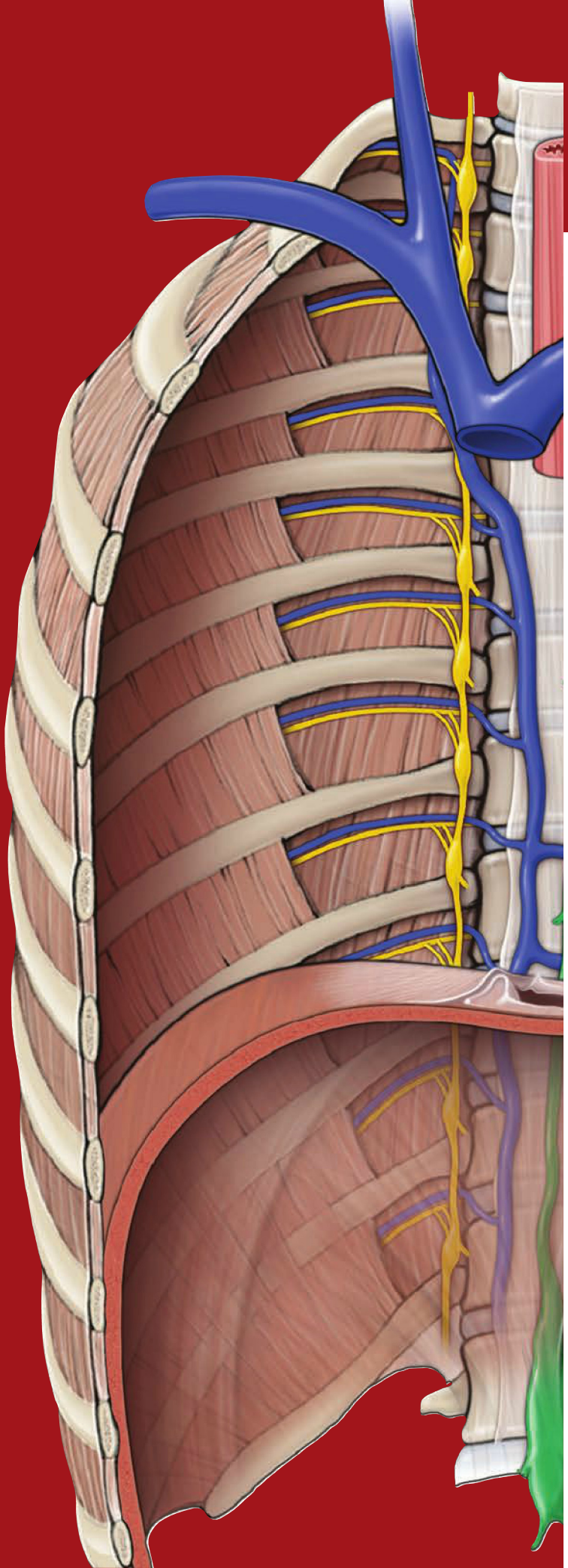

CHAPTER 16

BRAIN

Anatomy of the Brain 178
Ventricular System of the Brain 180
Blood Supply to the Brain 182

ANATOMY OF THE BRAIN

BIG PICTURE

The brain contains millions of neurons arranged in a vast array of synaptic connections that provide seemingly unfathomable circuitry. Through that circuitry the brain directs movement, processes sensory input, and processes language and communication, learning, and memory.

DIVISIONS OF THE BRAIN

The brain is divided into the cerebrum, diencephalon, brainstem, and cerebellum (Figure 16-1A and B).

CEREBRUM The organ of thought, and serves as the control site of the nervous system, enabling us to possess the qualities associated with consciousness such as perception, communication, understanding, and memory. The **cerebral hemispheres** consist of elevations (**gyri**) and valleys (**sulci**), with a **longitudinal cerebral fissure** separating the two cerebral hemispheres. Each cerebral hemisphere is divided into lobes, which correspond roughly to the overlying bones of the skull.

- **Frontal lobe.** Located in the anterior cranial fossa; contains the primary motor cortex, which regulates motor output (voluntary movement). Additional functions include hypothesizing future consequences from current actions, conscience, short-term memory, planning, and motivation.
- **Central sulcus.** Separates frontal and parietal lobes in the coronal plane.
- **Parietal lobe.** Positioned between the frontal and occipital lobes above the lateral sulcus; contains the primary sensory cortex, which directs the integrating of sensory input. Additionally plays an important role in visuospatial processing.
- **Occipital lobe.** Located in the posterior cranial fossa above the tentorium cerebelli; contains the primary visual cortex, which is the visual processing center of the brain.
- **Lateral sulcus.** Separates frontal and parietal lobes from the temporal lobe.
- **Temporal lobe.** Located in the middle cranial fossa below the lateral sulcus; functions include auditory processing, language recognition, interpretation of visual stimuli, and the formation of new and long-term memories.

DIENCEPHALON Consists of the **thalamus, hypothalamus, epithalamus**, and **subthalamus**, and is situated between the cerebrum and the brainstem.

PITUITARY GLAND Called the "master gland" because it orchestrates the activities of many other endocrine glands. It is small and bean-shaped.

- Suspended from the hypothalamus by the infundibulum and housed in the sella turcica (a depression in the sphenoid bone).

BRAINSTEM Consists of the midbrain, pons, and medulla oblongata.

- **Midbrain (mesencephalon).** Contains the nuclei for the oculomotor (CN III) and trochlear (CN IV) nerves. The **cerebral aqueduct** is a portion of the ventricular system and courses through the center of the midbrain to connect the third and fourth ventricles.
- **Pons.** Positioned against the clivus and the dorsum sellae; contains the nuclei for the trigeminal (CN V), abducens (CN VI), facial (CN VII), and vestibulocochlear (CN VIII) nerves.
- **Medulla oblongata.** Located at the level of the foramen magnum; serves as a major autonomic reflex center that relays visceral motor control to the heart, blood vessels, swallowing, respiratory system, and gastrointestinal tract. The medulla oblongata has the nuclei for the glossopharyngeal (CN IX), vagal (CN X), and hypoglossal (CN XII) nerves.

CEREBELLUM Lies in the posterior cranial fossa and assists in the coordination of skeletal muscle contraction; functions at a subconscious level and provides skeletal muscles with precise timing and appropriate patterns of contraction needed for smooth, coordinated movements.

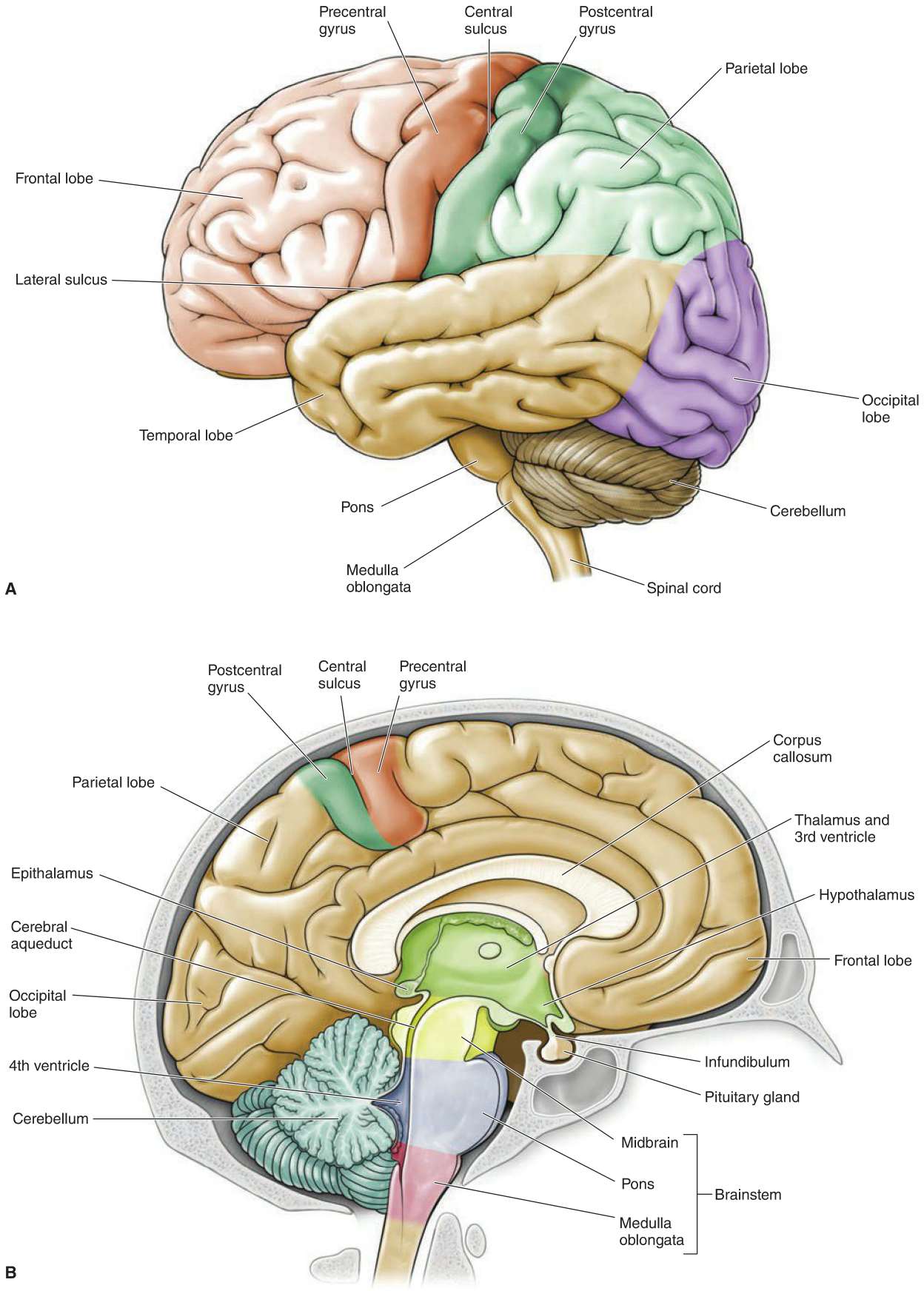

Figure 16-1: A. Lateral view of the brain. **B**. Medial view of the sagittal section of the brain.

VENTRICULAR SYSTEM OF THE BRAIN

BIG PICTURE

The ventricular system of the brain is a set of four chambers within the brain. Cerebrospinal fluid (CSF) flows within these chambers and serves as a liquid cushion, providing buoyancy to the brain and spinal cord.

VENTRICLES

The four connected ventricles form chambers within the brain and are filled with CSF (Figure 16-2A and B).

- **Lateral ventricles.** These paired, C-shaped chambers are located deep within each cerebral hemisphere. Each lateral ventricle communicates via the **interventricular foramen (of Monro)** with the third ventricle.
- **Third ventricle.** A midline narrow space located between the left and right diencephalon below the lateral ventricles. The third ventricle communicates with the fourth ventricle via the **cerebral aqueduct (of Sylvius)**.
- **Fourth ventricle.** Located posterior to the pons and the medulla oblongata.

CEREBROSPINAL FLUID

The CSF is produced by the choroid plexuses, located within each of the ventricles, and flows from the **lateral** and **third ventricles** to the fourth ventricle via the **cerebral aqueduct** (Figure 16-2C). From the fourth ventricle, CSF enters an enlarged part of the subarachnoid space (**cisterna magna**) via the central **median aperture (of Magendie)** and the **lateral apertures (of Luschka)**. The CSF circulates around the spinal cord and brain in the subarachnoid space to empty into the superior sagittal sinus via the **arachnoid granulations**. Arachnoid granulations are projections of the arachnoid mater along the superior sagittal sinus.

PROTECTING THE CNS

The brain and spinal cord are very delicate and, as such, are susceptible to damage. Therefore, they are well protected by the following:

- **Bone.** The bony encasement of the skull and vertebral column serve as armor to the CNS.
- **Meninges.** The connective tissue coverings of the meninges protect the CNS like a seatbelt.
- **CSF.** The CSF enables the brain and spinal cord to float in fluid; protects the delicate tissue as a shock absorber.

Despite all of these protections, trauma to the brain and spinal cord can still occur and can result in devastating injuries and deficits.

Hydrocephalus. The lumen of the cerebral aqueduct or the fourth ventricular apertures may become obstructed. When either of these conditions occurs, CSF continues to be secreted, producing excessive pressure within the ventricles. In children, this results in hydrocephalus, a condition in which the head enlarges because the skull bones have not yet fused. In adults, however, hydrocephalus is a different challenge because the skull is rigid. Therefore, the accumulating CSF compresses the brain tissue. In most cases, hydrocephalus is treated by inserting a shunt into the ventricles to drain the excess CSF into either a jugular vein or the peritoneal cavity.

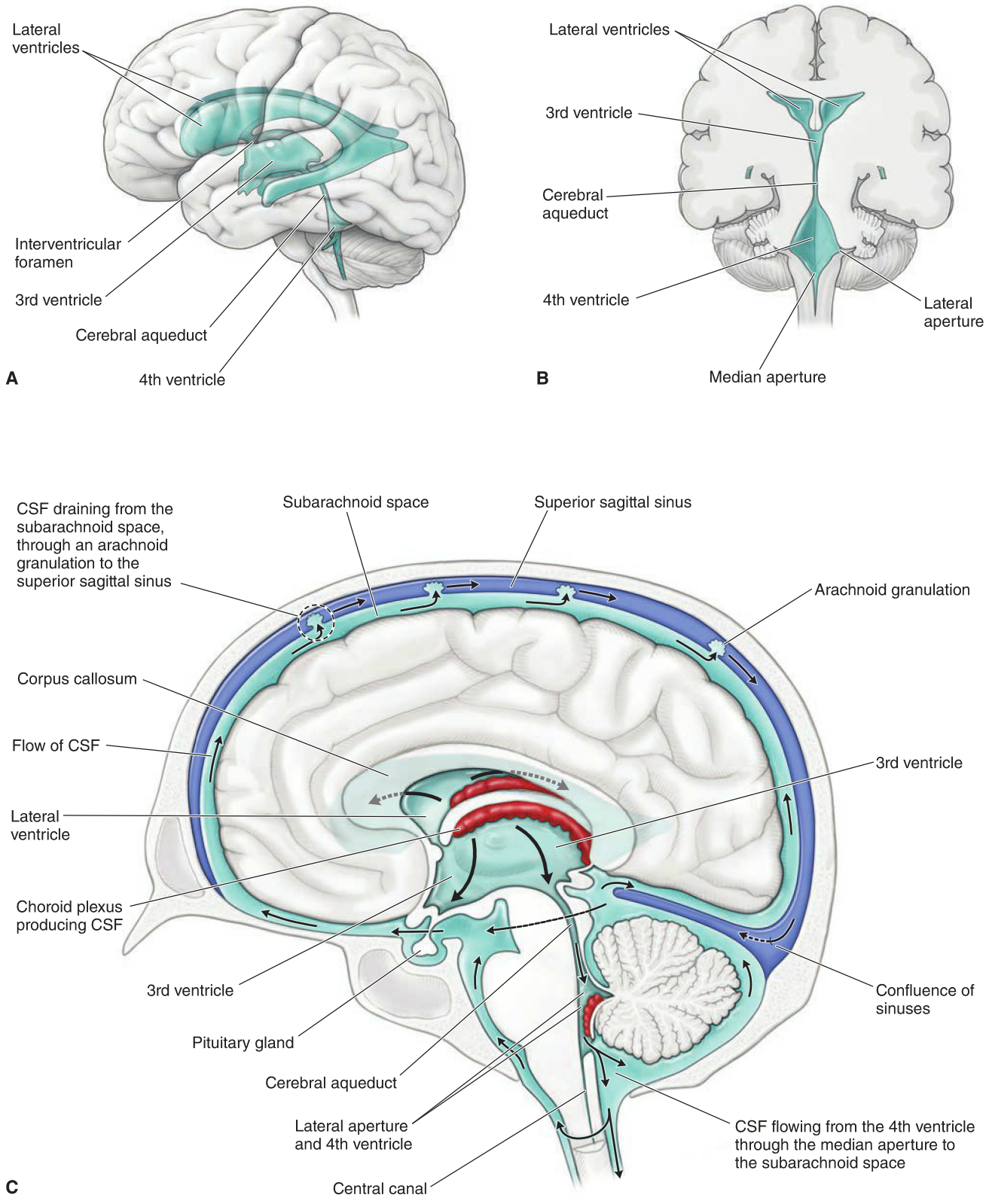

Figure 16-2: A. Three-dimensional lateral view of the ventricles of the brain. **B**. Coronal section of the brain showing the ventricles. **C**. Formation, location, and circulation of CSF.

BLOOD SUPPLY TO THE BRAIN

BIG PICTURE

The brain receives its arterial supply from two sources, the **internal carotid** and the **vertebral arteries** (Figure 16-3A–C).

INTERNAL CAROTID ARTERY

Arises from the common carotid artery at the level of the thyroid cartilage and ascends within the carotid sheath in company with the IJV and vagus nerve. The internal carotid artery traverses the carotid canal within the petrous part of the temporal bone. After coursing over the foramen lacerum and ascending through the cavernous sinus it gives rise to the following branches:

- **Ophthalmic artery.** Courses through the optic canal to supply the retina, orbit, and part of the scalp.
- **Posterior communicating artery.** Joins the posterior cerebral artery with the internal carotid artery.
- **Anterior cerebral artery.** Courses superior to the optic chiasma into the **longitudinal cerebral fissures** and courses along the corpus callosum, providing blood supply to the medial sides of both cerebral hemispheres.
  - **Anterior communicating artery.** A very short artery that connects the two anterior cerebral arteries.
- **Middle cerebral artery.** Courses into the lateral fissure between the parietal and temporal lobes. The middle cerebral artery sends many branches to the lateral sides of the cerebral hemispheres and central branches into the brain.

VERTEBROBASILAR SYSTEM OF ARTERIES

Each vertebral artery arises from the subclavian artery, ascends through the transverse foramina of C1–C6, and courses horizontally across C1 within the suboccipital triangle before entering the skull via the **foramen magnum**. After penetrating the dura mater, the vertebral arteries then course along the inferior aspect of the medulla oblongata before converging into the basilar artery on the pons. The two vertebral arteries and the basilar artery are often referred to as the "vertebrobasilar system of arteries." The major branches are as follows:

- **Posterior inferior cerebellar arteries (PICA).** Arises from the vertebral arteries and courses between the origins of CN X and CN XI en route to the inferior surface of the cerebellum.
- **Anterior spinal artery.** Arises from the vertebral arteries, courses along, and supplies the anterior region of the spinal cord.
- **Basilar artery.** Formed by the union of the two vertebral arteries; ascends along the ventral surface of the pons and gives rise to the following branches:
  - **Anterior inferior cerebellar artery.** Courses along and supplies the inferior surface of the cerebellum.
  - **Superior cerebellar artery.** Courses along and supplies the superior surface of the cerebellum.
  - **Posterior cerebral arteries.** The terminal branches of the basilar artery provide vascular supply to the part of the brain base that is superior to the tentorium cerebelli. CN III and CN IV exit the brain between the superior cerebellar and the posterior cerebral arteries.

CIRCLE OF WILLIS

The circle of Willis forms around the infundibulum and consists of the following:

- **Anterior communicating artery.** Connects the two anterior cerebral arteries.
- **Posterior communicating arteries.** Connect the internal carotid and posterior cerebral arteries.

This configuration of arteries in the circle of Willis provides redundancy for collateral circulation. In other words, if one of the arteries supplying the circle or a section of the circle becomes narrowed or blocked, blood flow from collateral vessels can often preserve blood supply to the brain well enough to avoid the symptoms of ischemia. However, numerous arteries arising from this circle and penetrating the brain substance are small and are considered end arteries (without collateral circulation). Therefore, if an end artery becomes narrowed or blocked, ischemia may occur in the region of the brain that is uniquely supplied by that end artery.

Berry aneurysm. A balloon-like outpouching of a cerebral arterial wall that is berry shaped (hence, the name). This outpouching most often reflects a gradual weakening of the arterial wall as a result of chronic hypertension or arteriosclerosis and places the artery at risk to rupture, causing a **stroke**. Some cerebral vessels are inherently weak and susceptible to berry aneurysms, such as the arteries associated with the circle of Willis, where small communicating arteries connect larger cerebral arteries (internal carotid, vertebral, and basilar arteries). A ruptured berry aneurysm bleeds into the subarachnoid space.

Arteriovenous malformation (AVM). An abnormal collection of blood vessels where a direct connection exists between a supplying artery and a draining vein. Vascular malformation allows high-pressure arterial blood to enter the lower pressure venous structures, causing both structures to dilate. These anomalous connections cause blood to bypass the normal capillary bed (shunting). The normal tissue near the AVM may become ischemic, which can be seen with brain lesions. Bleeding may occur because the thin-walled veins rupture due to the elevated pressures.

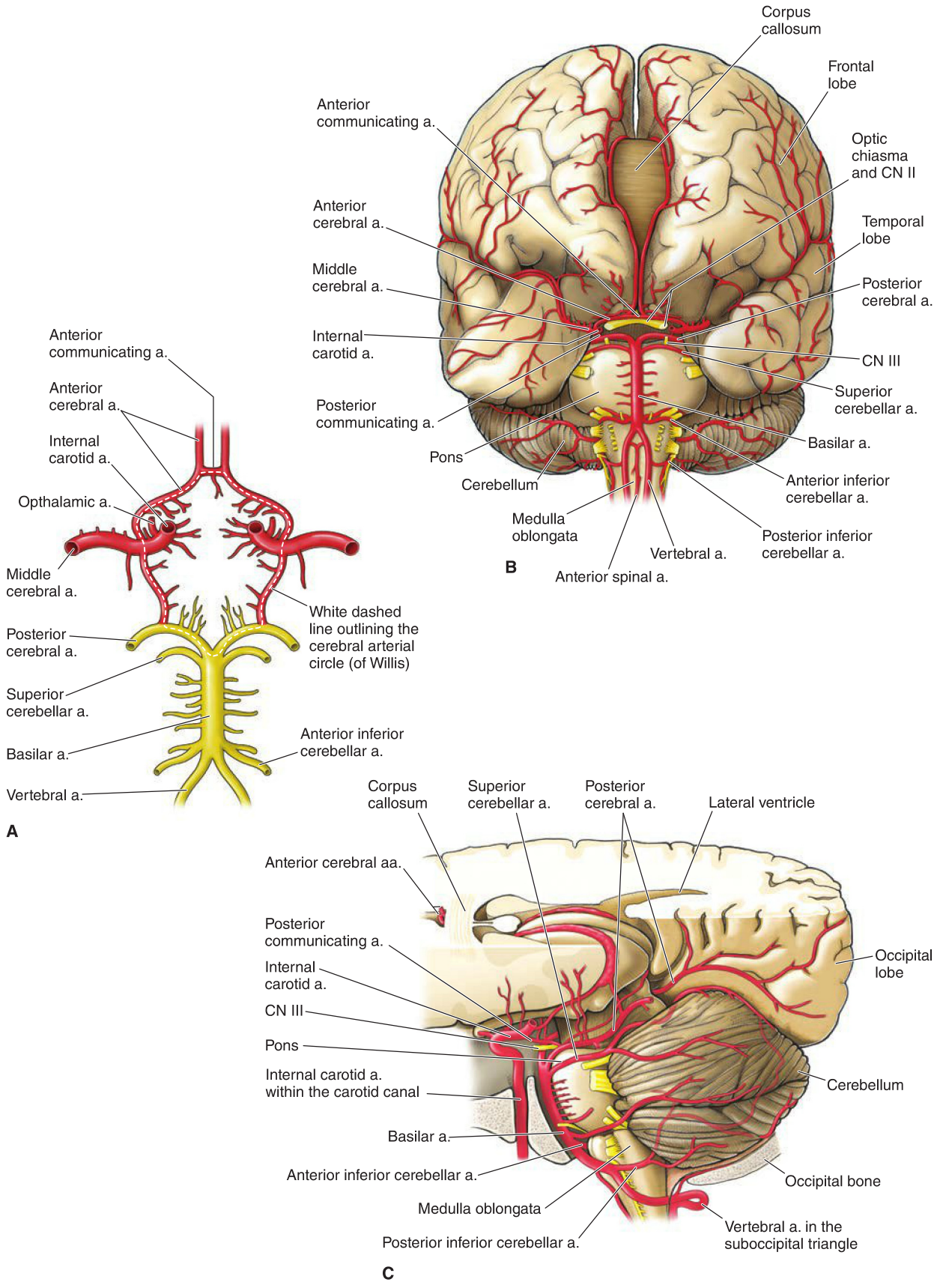

Figure 16-3: **A**. Cerebral arterial circle (of Willis). **B**. Anterior view of the brain showing the arteries (cerebral hemispheres separated). **C**. Lateral view of the brain showing the arteries.

This page intentionally left blank

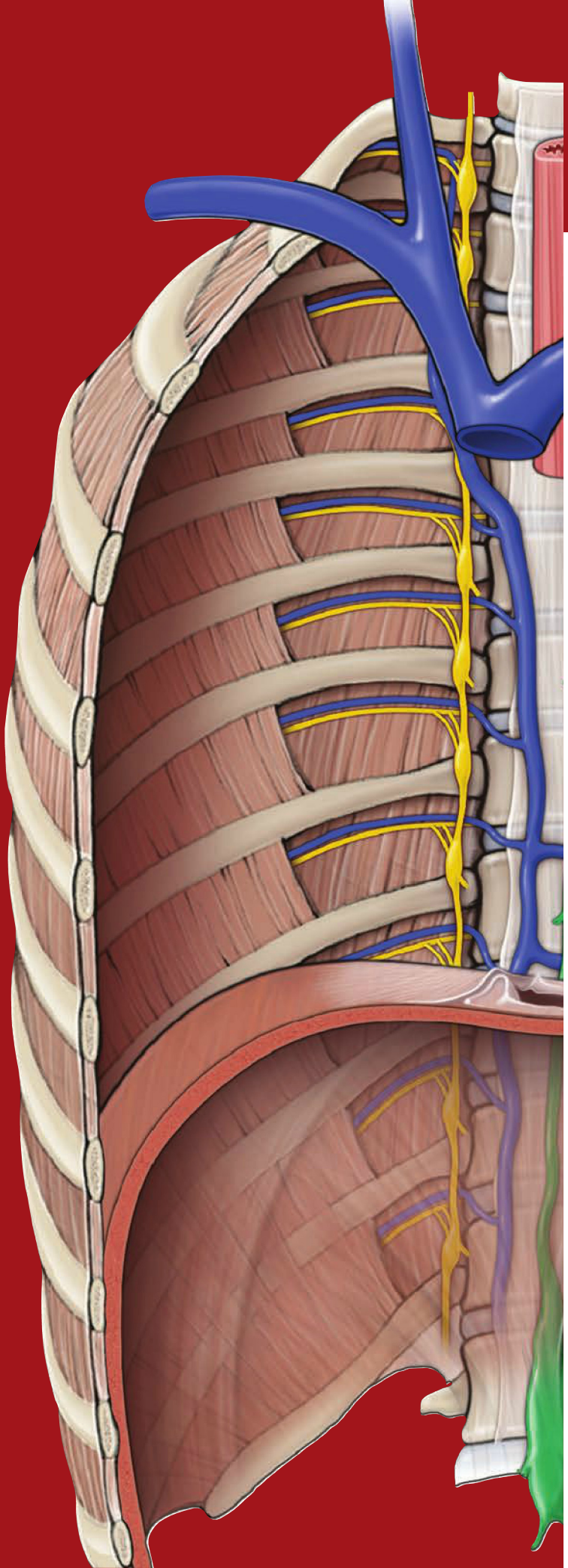

CHAPTER 17

CRANIAL NERVES

Overview of the Cranial Nerves 186
CN I: Olfactory Nerve 188
CN II: Optic Nerve 188
CN III: Oculomotor Nerve 190
CN IV: Trochlear Nerve 190
CN VI: Abducens Nerve 190
CN V: Trigeminal Nerve 192
CN VII: Facial Nerve 194
CN VIII: Vestibulocochlear Nerve 194
CN IX: Glossopharyngeal Nerve 196
CN X: Vagus Nerve 198
CN XI: Spinal Accessory Nerve 200
CN XII: Hypoglossal Nerve 200
Autonomic Innervation of the Head 202

OVERVIEW OF THE CRANIAL NERVES

BIG PICTURE

Cranial nerves (CNN) emerge through openings in the skull and are covered by tubular sheaths of connective tissue derived from the cranial meninges. Twelve pairs of cranial nerves are numbered I to XII from rostral to caudal, according to their attachment to the brain. The names of the cranial nerves reflect their general distribution and function. Like spinal nerves, cranial nerves are bundles of sensory and motor neurons that conduct impulses from sensory receptors and innervate muscles or glands.

RAPID REVIEW OF THE NERVOUS SYSTEM

To best understand the cranial nerves the following information is helpful to remember:

- **Neuron versus nerve.** A neuron is a single sensory or motor nerve cell, whereas a nerve is a bundle of neuronal fibers (axons). Cranial nerves have three types of sensory and three types of motor neurons, known as modalities. Therefore, a nerve may be composed of a combination of sensory or motor neurons (e.g., the facial nerve possesses sensory and motor neurons).
- **Ganglion.** A ganglion is a collection of nerve cell bodies in the peripheral nervous system.
- **Nucleus.** A nucleus is a collection of nerve cell bodies in the central nervous system (CNS).

CRANIAL NERVE MODALITIES

The 12 pairs of cranial nerves may have one or a combination of the following sensory and motor modalities (Figure 17-1; Table 17-1):

- **Sensory (afferent) neurons.** Carry information from the body tissues to the CNS.
  - **General sensory (general somatic afferent) neurons.** Transmit sensory information (e.g., pain, temperature, and touch), carried mainly by CN V but also by CNN VII, IX, and X.
  - **Special sensory (special visceral afferent) neurons.** Include special sensory neurons (e.g., smell, vision, taste, hearing, and equilibrium) that are carried by CNN I, II, VII, VIII, IX, and X.
  - **Visceral sensory (general visceral afferent) neurons.** Transmit visceral sensory information (e.g., stretch and baroreceptors) from the heart, lungs, GI tract, carotid body, and carotid sinus mainly within CNN IX and X.
- **Motor (efferent) neurons.** Carry information from the CNS to body tissues.
  - **Somatic motor (general somatic efferent) neurons.** Innervate skeletal muscles derived from somites, including the extraocular and tongue muscles. Innervation is accomplished via CNN III, IV, VI, and XII.
  - **Branchial motor (special visceral efferent) neurons.** Innervate skeletal muscles derived from the branchial arches, including the muscles of mastication and facial expression, and the palatal, pharyngeal, laryngeal, trapezius, and sternocleidomastoid muscles. Innervation is accomplished via CNN V, VII, IX, X, and XI.
  - **Visceral motor (general visceral efferent) neurons.** Innervate involuntary (smooth) muscles or glands, including visceral motor neurons that constitute the cranial outflow of the parasympathetic division of the autonomic nervous system. The preganglionic neurons originate in the brainstem and synapse outside the brain in parasympathetic ganglia. The postganglionic neurons innervate smooth muscles and glands via CNN III, VII, IX, and X.

The nuclei of the cranial nerves are located in the brainstem, with the exception of CNN I and II, which are extensions of the telencephalon and diencephalon, respectively.

CRANIAL NERVE TARGETS

The specific functions of cranial nerves depend on the nature of the anatomic targets of the cranial nerves (Table 17-2).

- **CNN V, VII, IX, and X.** Innervate almost all of the structures of the head and neck, such as the skin, mucous membranes, muscle, and glands derived from the pharyngeal arches. Of these four nerves, CN V and CN VII innervate most of these structures, whereas CN IX innervates only a few structures of the head, oral cavity, pharynx, and neck. Almost all targets of CN X are in the trunk.
- **CNN III, IV, and VI.** Innervate only structures in the orbit.
- **CNN I, II, and VIII.** Have only special sensory neurons for smell, sight, balance, and hearing.
- **CN XII.** Innervates only the tongue muscles.
- **CNN III, VII, IX, and X.** The cranial nerves that carry parasympathetic (visceral motor) neurons.

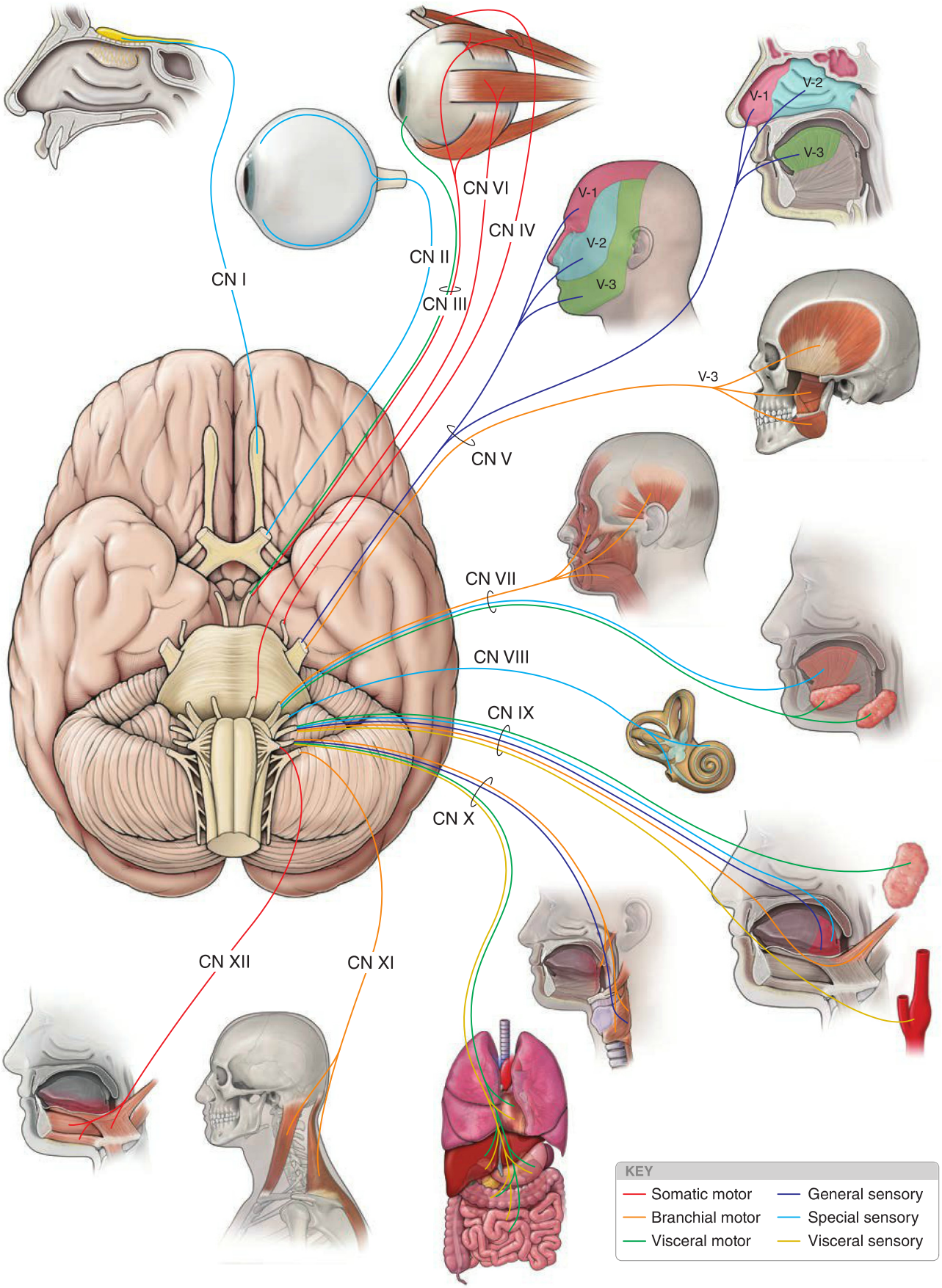

Figure 17-1: Overview of the cranial nerves.

CN I: OLFACTORY NERVE

BIG PICTURE

The olfactory nerve contains only special sensory neurons concerned with **smell** (Figure 17-2A).

PATHWAYS

Olfactory neurons originate in the olfactory epithelium in the superior part of the lateral and septal walls of the nasal cavity. The nerves ascend through the **cribriform foramina** of the ethmoid bone to reach the **olfactory bulbs**. The olfactory neurons synapse with neurons in the bulbs, which course to the primary and association areas of the cerebral cortex.

Anosmia. A fracture to the base of the cranium at the ethmoid bone may result in tearing of the meninges, leak of CSF and injury to CN I, which can result in anosmia (loss of smell).

CN II: OPTIC NERVE

BIG PICTURE

The optic nerve contains only special sensory neurons concerned with **vision** (Figure 17-2B).

PATHWAYS

Visual information from each retina courses to the optic nerve, optic chiasma, optic tract, thalamus (lateral geniculate nucleus), and optic radiations to terminate in the primary visual cortex of the occipital lobe.

- **Optic nerve (CN II).** Formed by the axons of ganglion cells of the retina that converge at the **optic disc**; conveys visual information from the retina, leaves the orbit by way of the **optic canal,** and courses to the optic chiasm.
- **Optic chiasm.** Each optic nerve carries axons from the entire retina of the eye. However, after coursing through their respective optic canals, the right and left optic nerves engage in a redistribution of axons at the optic chiasma, located just anterior to the pituitary stalk. The optic chiasma is created by neurons from the nasal half of each retina crossing over to the opposite side.
- **Optic tracts.** The two optic tracts emerge from the optic chiasma and course to the associated lateral geniculate nucleus of the thalamus. The right optic tract contains axons from the temporal half of the right retina and the nasal half of the left retina. The left optic tract contains neurons from the temporal half of the left retina and the nasal half of the right retina.

Injury to CN II. Injury to the optic nerve (CN II) may result in **monocular blindness** as well as loss of the sensory limb of the **pupillary light reflex**. Injury to the optic chiasm may result in a reduction in peripheral vision (bitemporal hemianopsia) due to the damage of the crossing fibers entering the chiasm from each optic nerve.

Multiple sclerosis and CN II. Most cranial nerves are peripheral nerves and therefore myelinated by Schwann cells. However, CN II is an extension of the forebrain and as such is myelinated by oligodendrocytes. Multiple sclerosis is an autoimmune disorder that attacks myelin in oligodendrocytes. Therefore, CN II is the only cranial nerve affected by multiple sclerosis.

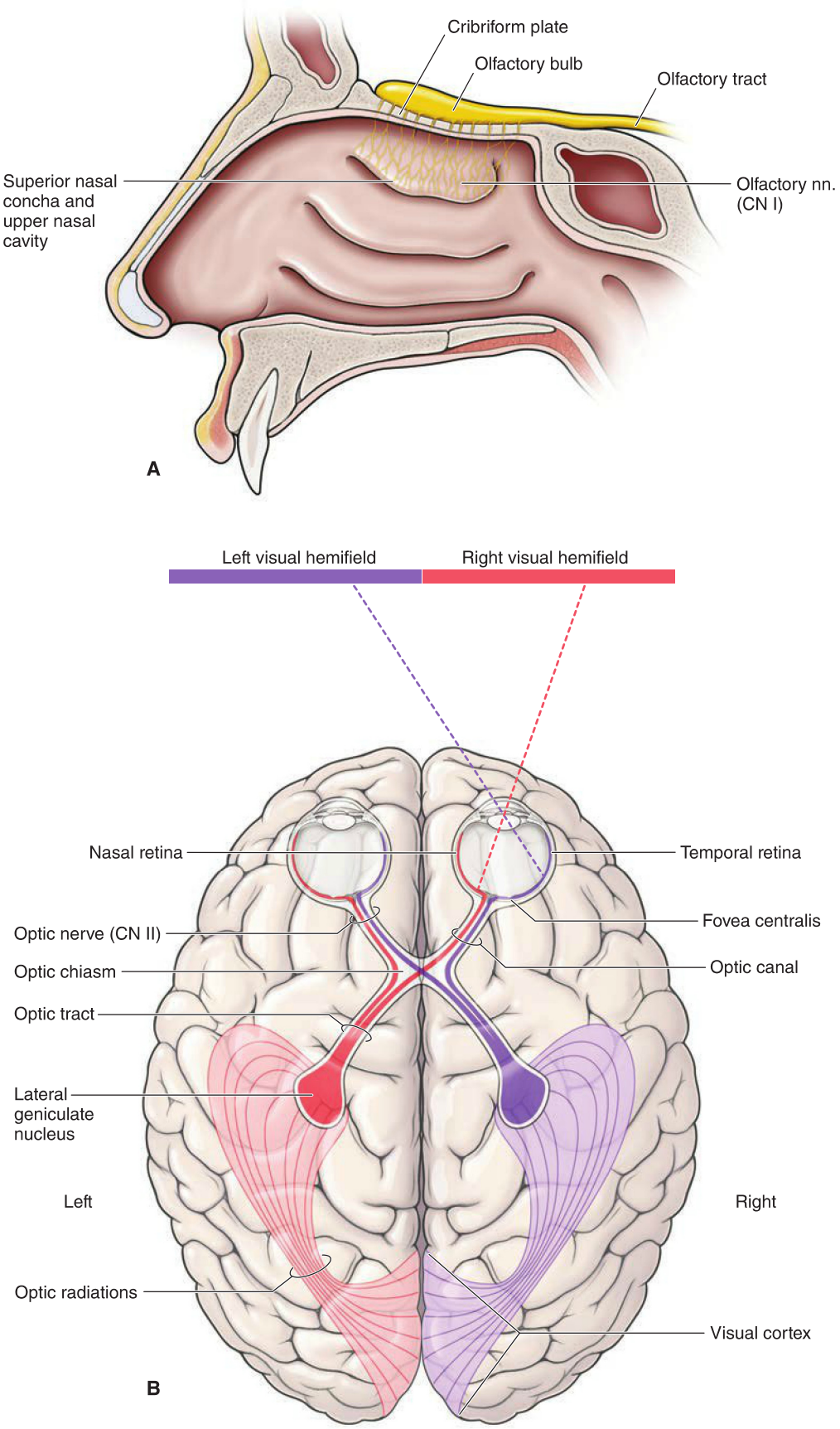

Figure 17-2: A. Special sensory innervation from the olfactory nerve (CN I). **B**. Special sensory innervation from the optic nerve (CN II) and visual fields.

CN III: OCULOMOTOR NERVE

BIG PICTURE

The oculomotor nerve innervates the levator palpebrae superioris muscle, four of the six extraocular muscles, as well as the pupillary constrictor and ciliary muscles (Figure 17-3A and B).

PATHWAYS

Upon exiting the midbrain, the oculomotor nerve courses between the posterior cerebral and superior cerebellar arteries to run along the lateral wall of the cavernous sinus, superior to CN IV. CN III enters the orbit through the **superior orbital fissure**, where CN III divides into superior and inferior divisions. CN III has the following **modalities**:

- **Somatic motor neurons.** CN III innervates four of the six **extraocular muscles** (superior rectus, medial rectus, inferior rectus, and inferior oblique) and the **levator palpebrae superioris muscle**. The somatic motor component of CN III plays a major role in controlling the muscles responsible for the precise movements of the eyes.
- **Visceral motor neurons.** Preganglionic parasympathetic neurons of CN III originate in the **Edinger–Westphal nucleus** and synapse in the **ciliary ganglion**, providing innervation to the **ciliary body** (lens accommodation) and **sphincter pupillae muscle** (pupil constriction).

Injury to CN III. Injury to CN III may result in the following symptoms: **mydriasis** (fixed, dilated pupil) because the dilator pupillae muscle no longer has an antagonistic muscle counteracting its force; **loss of the pupillary light reflex** due to loss of innervation to the constrictor pupillae muscle; **loss of the accommodation reflex** (lens) due to loss of innervation to the ciliary muscles; **ptosis** (droopy eyelid) due to loss of innervation to the levator palpebrae superioris muscle; **eye positioned down and out** due to the unopposed action of the lateral rectus and superior oblique muscles.

CN IV: TROCHLEAR NERVE

BIG PICTURE

The trochlear nerve innervates the superior oblique muscle (Figure 17-3A and B).

PATHWAYS

The trochlear nerve is the only cranial nerve that originates from the dorsal aspect of the brainstem. CN IV courses around the brainstem in the free edge of the tentorium cerebelli, through the lateral wall of the cavernous sinus, and enters the orbit via the superior orbital fissure. The trochlear nerve supplies somatic motor innervation to the **superior oblique muscle**, which causes the eyeball to move down and out.

CN IV lesion. Injury to CN IV (e.g., a fracture of the orbit or stretching of the nerve during its course around the brainstem) can result in the **inability to look down when the eyeball is adducted**. The patient may also tilt the head away from the side of the lesion to accommodate for the torsion caused by the loss of the superior oblique muscle.

CN VI: ABDUCENS NERVE

BIG PICTURE

The abducens nerve innervates the lateral rectus muscle (Figure 17-3A and B).

PATHWAYS

The abducens nerve originates from the pons and courses through the cavernous sinus, entering the orbit via the superior orbital fissure. The abducens nerve supplies somatic motor innervation to the **lateral rectus muscle**, which abducts the eye.

Double vision. Injury to CN VI may result in paralysis of the lateral rectus muscle. As such, the inability to move the lateral rectus muscle results in double vision (**diplopia**) when looking laterally on the side of the lesion.

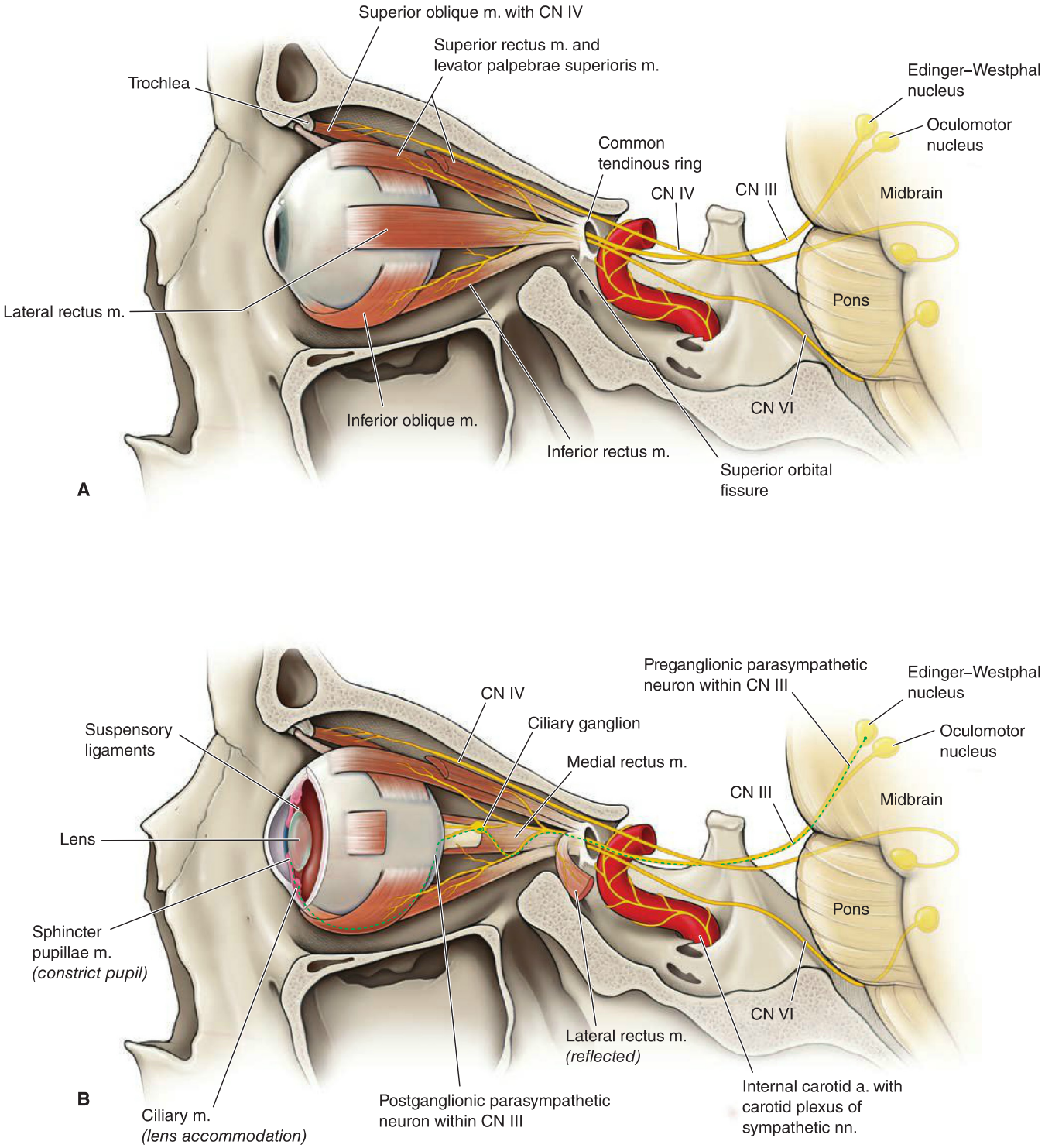

Figure 17-3: A. Somatic motor innervation from the oculomotor, trochlear, and abducens nerves (CNN III, IV, and VI, respectively). **B**. Visceral motor parasympathetic component of CN III.

CN V: TRIGEMINAL NERVE

BIG PICTURE

The trigeminal nerve innervates muscles of mastication and is the principal general sensory supply to the head (Figure 17-4A–C).

PATHWAYS

CN V originates from the lateral surface of the pons as a large sensory root and a smaller motor root. These roots enter the **trigeminal (Meckel's) cave** of the dura, lateral to the body of the sphenoid bone and the cavernous sinus.

- **Sensory.** Sensory neurons within CN V lead to the **trigeminal (semilunar) ganglion**, which houses the cell bodies for the general sensory neurons.
- **Motor.** The motor root runs parallel to the sensory root, bypassing the ganglion and becoming part of the mandibular nerve (CN V-3).
- **Transporting visceral motor neurons.** CN V also aids in distributing visceral motor (parasympathetic) neurons of the head to their destinations for CNN III, VII, and IX.

The trigeminal ganglion gives rise to three divisions, named for the cranial location to the eyes (**ophthalmic**), the maxilla (**maxillary**), and the mandible (**mandibular**).

CN V-1: OPHTHALMIC DIVISION

CN V-1 courses along the lateral wall of the cavernous sinus and enters the **orbit** via the superior orbital fissure. CN V-1 provides general sensory innervation to the orbit, cornea, and the skin of the bridge of the nose, scalp, and forehead (above the lateral corners of the eye).

Injury to branches of CN V-1. Results in a loss of sensation in the skin of the forehead, bridge of the nose and anterior scalp. CN V-1 also provides sensory innervation to the cornea via the nasociliary branch. As such, injury to CN V-1 may abolish the corneal reflex.

CN V-2: MAXILLARY DIVISION

CN V-2 passes through the lateral wall of the cavernous sinus and through the foramen rotundum into the **pterygopalatine fossa**. This nerve provides general sensory innervation to the skin between the lateral corners of the eye and corners of the mouth. Additionally CN V-2 provides general sensory innervation to the palate, nasal cavity, paranasal sinuses and the maxillary teeth and gums.

Injury to branches of CN V-2. Results in a loss of sensation in the skin over the maxilla, maxillary teeth, and palate.

CN V-3: MANDIBULAR DIVISION

CN V-3 courses through the foramen ovale into the **infratemporal fossa**.

- **Sensory.** CN V-3 provides general sensory innervation to the lower part of the face (below the lateral corners of the mouth), including the anterior two-thirds of the tongue, the mandibular teeth, the mandibular face, and even part of the scalp.
- **Motor.** CN V-3 provides general sensory innervation to the skin of the face below the lateral corners of the mouth as well as the anterior two-thirds of the tongue, the mandibular teeth and lateral sides of the scalp.

Injury to branches of CN V-3. Results in a **loss of sensation** in the mandibular skin and teeth as well as the anterior two-thirds of the tongue. Because the motor division of CN V-3 innervates the muscles of mastication (e.g., temporalis and masseter muscles), the patient may experience weakness in chewing and deviation of the mandible on the side of the lesion when the mouth is opened.

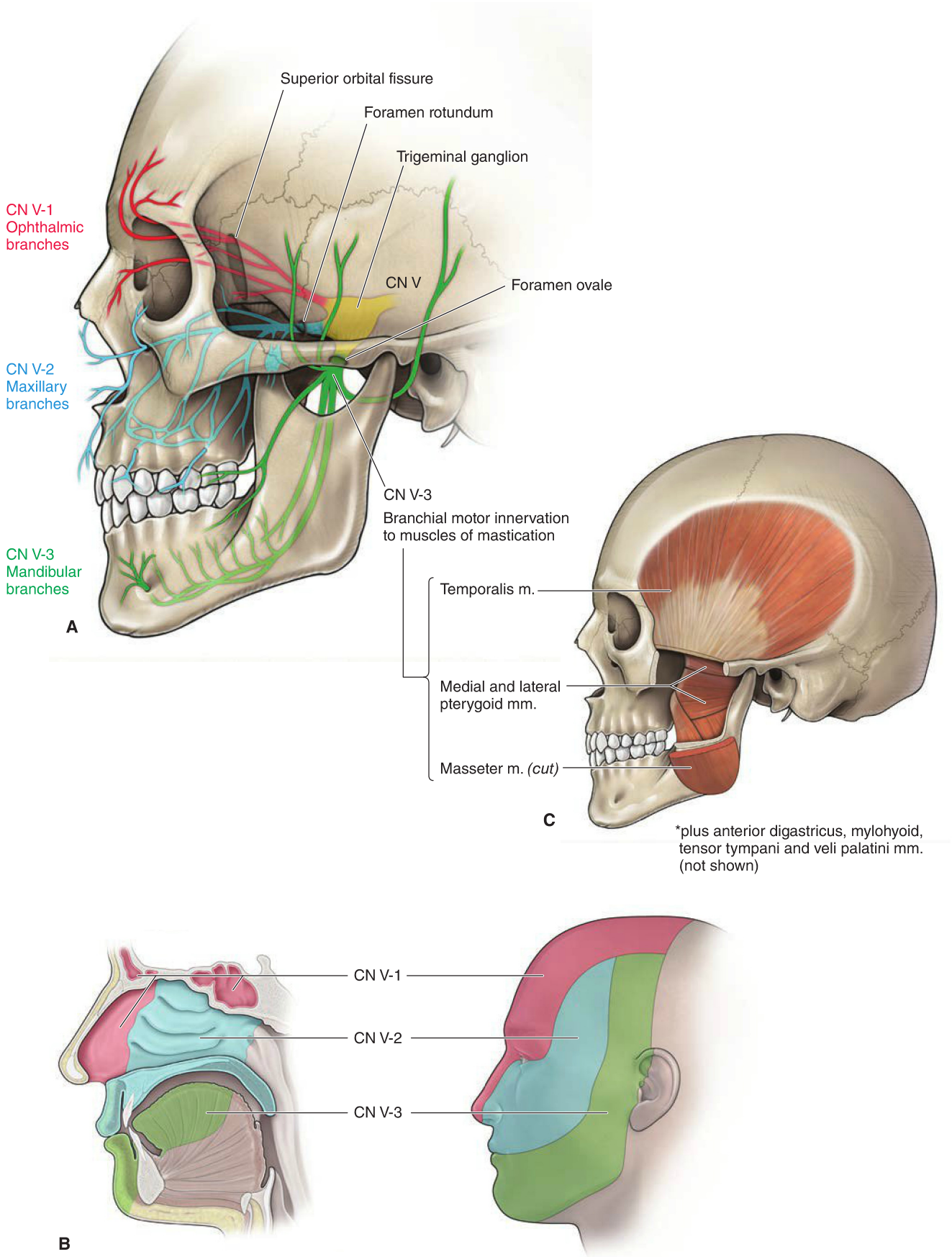

Figure 17-4: A. General sensory innervation from the trigeminal nerve (CN V). **B**. General sensory distribution of CN V. **C**. Branchial motor distribution of the mandibular division of the trigeminal nerve (CN V-3) to muscles of mastication.

CN VII: FACIAL NERVE

BIG PICTURE

The facial nerve provides motor innervation to the muscles of facial expression, lacrimal gland, and submandibular and sublingual salivary glands, as well as taste to the anterior two-thirds of the tongue.

CN VII MODALITIES

The facial nerve traverses the internal acoustic meatus carrying four modalities (Figure 17-5A):

- **Branchial motor neurons.** Supply muscles derived from the second branchial arch, including the muscles of facial expression as well as the stapedius, posterior belly of the digastricus, and stylohyoid muscles via the facial nerve proper.
- **Visceral motor neurons.** Provide parasympathetic innervation to most glands in the head, including the lacrimal and nasopalatal glands (via the greater petrosal nerve) and submandibular and sublingual glands (via the chorda tympani nerve). An exception is the parotid gland, which receives its parasympathetic innervation from CN IX.
- **Special sensory neurons.** Transmit taste sensation from the anterior two-thirds of the tongue via the chorda tympani nerve.
- **General sensory neurons.** Transmit general sensation from a portion of the external acoustic meatus and auricle.

CN VII BRANCHES

Two distinct fascial sheaths package the four modalities carried by CN VII, with branchial motor neurons in one sheath (facial nerve proper) and visceral motor, special sensory, and general sensory neurons in another sheath (nervus intermedius). The nervous intermedius contains the axons destined for the greater petrosal and chorda tympani nerves.

FACIAL NERVE PROPER The branchial motor components constitute the largest portion of CN VII. After entering the temporal bone via the internal acoustic meatus, a small branch of CN VII courses to the stapedius muscle, and the rest of the branchial motor neurons course through the facial canal to exit the skull via the stylomastoid foramen. In the parotid gland, five terminal branches (i.e., **temporal**, **zygomatic**, **buccal**, **mandibular**, **and cervical**) provide voluntary control of the muscles of facial expression, including the buccinator, occipitalis, platysma, posterior digastricus, and stylohyoid muscles.

GREATER PETROSAL NERVE Contains preganglionic parasympathetic neurons that synapse in the **pterygopalatine ganglion** and innervate the **lacrimal glands** (produces tears that wash the eye) and **palatonasal glands** (produces mucus to line the nasal cavity and palate).

CHORDA TYMPANI NERVE Arises in the descending part of the facial canal and crosses the medial aspect of the tympanic membrane, passing between the malleus and incus. The chorda tympani exits the skull through the petrotympanic fissure and joins the lingual nerve from CN V-3 in the infratemporal fossa. The chorda tympani nerve contains the following:

- Preganglionic parasympathetic neurons that synapse in the submandibular ganglion en route to innervate the submandibular and the sublingual salivary glands (produces saliva).
- Special sensory neurons (taste) from the anterior two-thirds of the tongue, with cell bodies located in the geniculate ganglion.

AURICULAR BRANCHES Arise from the external acoustic meatus and auricle and carry general sensory neurons through the geniculate ganglion to the brainstem.

- **Geniculate ganglion.** A knee-shaped ganglion in CN VII, located within the temporal bone and housing sensory cell bodies for the special sensory neurons for taste and general sensory neurons from the ear.

▽ **Lesions of the facial nerve.** Injury to CN VII, after it exits the brainstem, results in paralysis of the facial muscles (**Bell's palsy**) on the ipsilateral side. Fracture of the temporal bone can result in the abnormalities just described, plus increased sensitivity to noise (**hyperacusis**) due to the lack of innervation to the stapedius muscle, dry mouth due to a decrease in salivation, dry corneas due to the lack of lacrimal gland activity, dry mucous membranes due to loss of palatonasal glands, and a loss of taste on the anterior two-thirds of the tongue. A supranuclear injury to the facial motor nucleus results in paralysis of the contralateral facial muscles below the eye, with sparing of the forehead (i.e., a stroke). ▼

CN VIII: VESTIBULOCOCHLEAR NERVE

BIG PICTURE

The vestibulocochlear nerve provides special sensory innervation for hearing and equilibrium.

PATHWAYS

The vestibulocochlear nerve traverses the internal acoustic meatus with CN VII and has the following **modalities** (Figure 17-5B):

- **Special sensory neurons.** CN VIII originates from the grooves between the pons and the medulla oblongata. CN VIII divides into the **cochlear branch** to the **cochlea** (hearing) and the **vestibular branch** to the **semicircular canal (equilibrium)**.

▽ **Lesion of CN VIII.** Injury to CN VIII can result in ipsilateral deafness, tinnitus (ringing in the ear), and vertigo (loss of balance). ▼

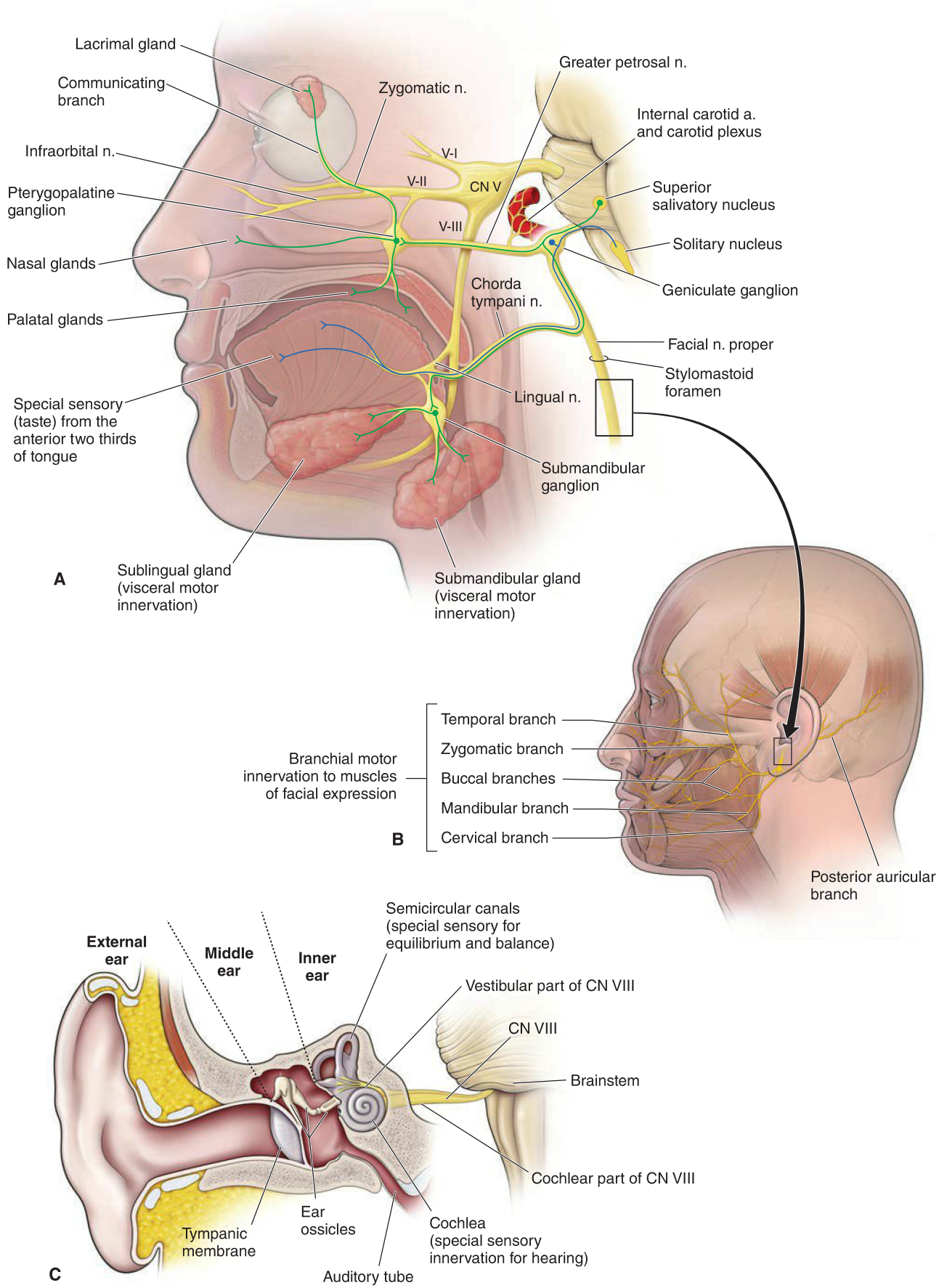

Figure 17-5: A. The facial nerve (CN VII). **B**. Branchial motor innervation for CN VII. **C**. Special sensory distribution of the vestibulocochlear nerve (CN VIII).

CN IX: GLOSSOPHARYNGEAL NERVE

BIG PICTURE

The glossopharyngeal nerve provides motor innervation to the stylopharyngeus muscle and parotid gland, and sensory innervation from the carotid body and sinus, posterior one-third of the tongue, and the auditory tube.

BRAINSTEM ORIGIN

The glossopharyngeal nerve emerges from the lateral aspect of the medulla oblongata and traverses the **jugular foramen**, where the nerves superior and inferior sensory ganglia are located (Figure 17-6).

MODALITIES

CN IX consists of the following five modalities:

- **Branchial motor neurons.** Course in a pharyngeal branch to innervate the **stylopharyngeus muscle,** the only skeletal muscle derived from the third branchial arch.
- **Visceral motor neurons.** Parasympathetic neurons from CN IX innervate the **parotid gland** via the following pathway:
  - ***Pre*ganglionic parasympathetic neurons** arise in the inferior salivatory nucleus of the medulla oblongata, traverse the jugular foramen, and then enter the petrous part of the temporal bone via the **tympanic canaliculus** to the tympanic cavity.
  - The tympanic nerve forms the **tympanic plexus** on the promontory of the middle ear to provide general sensation to the tympanic membrane.
  - The tympanic plexus emerges from the temporal bone at the lesser petrosal hiatus as the **lesser petrosal nerve** and exits the skull via the **foramen ovale** with CN V-3.
  - The preganglionic parasympathetic neurons synapse in the **otic ganglion**.
  - ***Post*ganglionic parasympathetic neurons** exit the otic ganglion and travel with the auriculotemporal branch of CN V-3 to provide visceral motor innervation the parotid gland.
- **General sensory neurons.** Course within the tympanic plexus, providing innervation to the internal surface of the tympanic membrane, the middle ear, and the auditory tube. General sensory neurons also course in the pharyngeal branch from the posterior third of the tongue and the oropharynx.
- **Special sensory neurons.** Course from the posterior third of the tongue within the pharyngeal branch of CN IX, providing taste sensation.
- **Visceral sensory neurons.** Course from the carotid sinus (baroreceptor) and carotid body (chemoreceptor) and ascend in the sinus nerve, joining CN IX. The cell bodies of the visceral sensory neurons reside in the inferior ganglion.

▽ **Lesion of CN IX.** Injury to CN IX may result in **loss of the gag reflex**, alteration in taste to the posterior third of the tongue, and interruption of the **baroreceptor reflex**. ▼

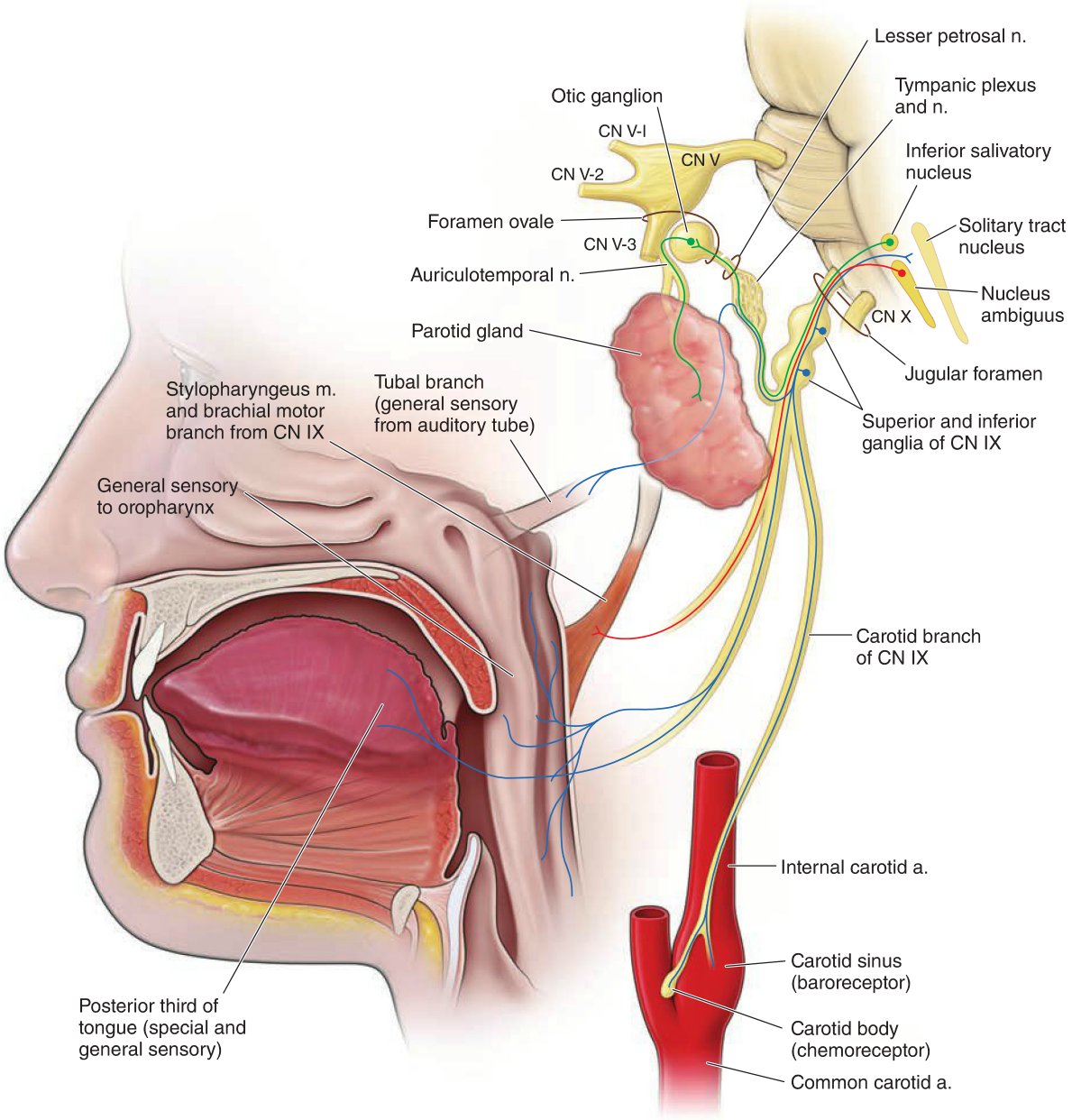

Figure 17-6: The glossopharyngeal nerve (CN IX).

CN X: VAGUS NERVE

BIG PICTURE

The vagus nerve innervates muscles of the larynx, pharynx, and palate and provides the primary parasympathetic innervation to the heart, lungs, and GI tract (Figure 17-7A and B).

BRAINSTEM ORIGIN

The vagus nerve emerges from the lateral aspect of the medulla oblongata and traverses the **jugular foramen,** where the superior and inferior sensory ganglia are located. The vagus nerve travels between the internal jugular vein and internal carotid artery within the carotid sheath.

CN X MODALITIES

The vagus nerve exits the medulla oblongata and travels with CNN IX and XI through the jugular foramen. CN X consists primarily of the following **four modalities:**

- **Visceral sensory neurons.** Provide visceral sensory information from the larynx (below the vocal folds), trachea, and esophagus, and the thoracic and abdominal viscera as well as chemoreceptors from the carotid bodies and stretch and chemoreceptors from the aortic arch.
- **General sensory neurons.** Provide general sensory information from part of the external acoustic meatus, the pinna, and the laryngopharynx.
- **Branchial motor neurons.** Supply the palatal, laryngeal, and pharyngeal muscles.
  - **Exceptions.** Tensor veli palatini (supplied by CN V-3) and stylopharyngeus muscle (supplied by CN IX).
- **Visceral motor neurons.** Provide parasympathetic innervation to the smooth muscle and the glands of the respiratory system, foregut, and midgut. In general, CN X increases secretion from glands and smooth muscle contraction. CN X slows the heart rate, stimulates bronchiolar secretions, bronchoconstriction, and peristalsis, and increases secretions.

BRANCHES OF CN X

The **branchial motor fibers** exit the vagus nerve as the following branches:

- **Pharyngeal branch.** The pharyngeal branch enters the middle pharyngeal constrictor muscle where the branch forms the pharyngeal plexus. The pharyngeal plexus innervates the following:
  - Pharyngeal constrictor muscles (superior, middle, and inferior).
  - Other pharyngeal muscles (salpingopharyngeus and palatopharyngeus).
  - Palatal muscles (palatoglossus and levator veli palatini).
- **Superior laryngeal branch.** Arises below the pharyngeal nerve and gives rise to the following:
  - **External laryngeal nerve.** Provides branchial motor innervation to part of the inferior pharyngeal constrictor muscle and the cricothyroideus muscle.
  - **Internal laryngeal nerve.** Pierces the thyrohyoid membrane and provides general sensory innervation of the larynx above the vocal folds.
- **Recurrent laryngeal branch.** The path of the recurrent laryngeal nerve differs on the right and left sides of the body.
  - **Left recurrent laryngeal nerve.** Branches from the vagus nerve at the level of the aortic arch. The nerve loops posteriorly around the aortic arch by the ligamentum arteriosus and ascends through the superior mediastinum to enter the groove between the esophagus and the trachea.
  - **Right recurrent laryngeal nerve.** Branches from the vagus nerve before entering the superior mediastinum at the level of the right subclavian artery. The nerve hooks posteriorly around the subclavian artery and also ascends in the groove between the esophagus and trachea.
  - Both recurrent laryngeal nerves pass deep to the lower margin of the inferior constrictor muscle to innervate the intrinsic laryngeal muscles and visceral sensory innervation below the vocal folds.

Lesion to vagus nerve. Injury to CN X may result in **hoarseness** (due to paralysis of the intrinsic laryngeal muscles) and **difficulty swallowing** (due to paralysis of pharyngeal muscles). On examination, the soft palate droops on the affected side, and the uvula deviates opposite the affected side as a result of the unopposed action of the intact levator veli palatini muscle. Loss of the gag reflex may occur where CN IX provides the sensory limb and CN X provides the motor limb through innervation of the pharyngeal muscles.

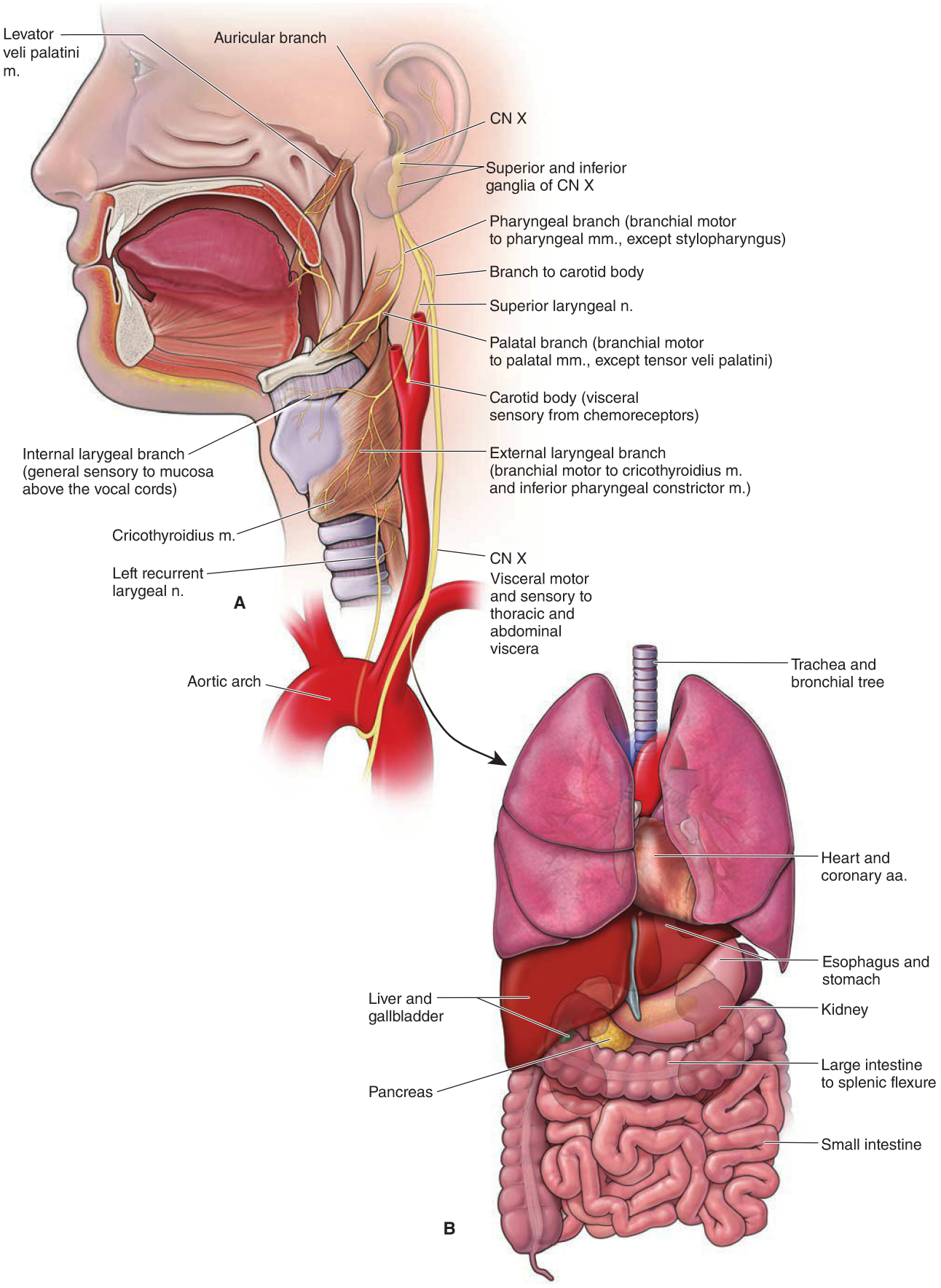

Figure 17-7: Distribution of the vagus nerve (CN X) to the head and neck (**A**) and the thorax and abdomen (**B**).

CN XI: SPINAL ACCESSORY NERVE

BIG PICTURE

The spinal accessory nerve innervates the trapezius and sternocleidomastoid muscles.

PATHWAYS

The spinal accessory nerve originates from the upper spinal cord, ascends through the foramen magnum, then descends through the jugular foramen, and provides branchial motor innervation to the **trapezius** and **sternocleidomastoid muscles** (Figure 17-8).

Injury to CN XI. Injury to CN XI may result in weakness in shrugging shoulders against resistance and weakness in turning the head to the opposite side.

CN XII: HYPOGLOSSAL NERVE

BIG PICTURE

The hypoglossal nerve innervates the tongue muscles.

PATHWAYS

The hypoglossal nerve exits the medulla oblongata in the groove between the pyramid and the olive (Figure 17-8). Upon exiting the hypoglossal canal, CN XII courses along the lateral surface of the hyoglossus muscle, deep to the mylohyoid muscle. CN XII provides somatic motor innervation to all **intrinsic** and **extrinsic tongue muscles** such as genioglossus, hyoglossus, and styloglossus (but not palatoglossus, which is supplied by CN X).

Lesion to CN XII. To test CN XII, have the patient stick their tongue straight out of their mouth. This movement tests both genioglossus muscles and thus testing CN XII. If there is a nerve lesion, the genioglossus muscle on that side will be paralyzed. With unilateral weakness or paralysis of a genioglossus muscle, the tongue will point to the affected side due to unopposed action of the normal genioglossus. A way to remember this is that a patient with a lesion of CN XII will "lick his wound."

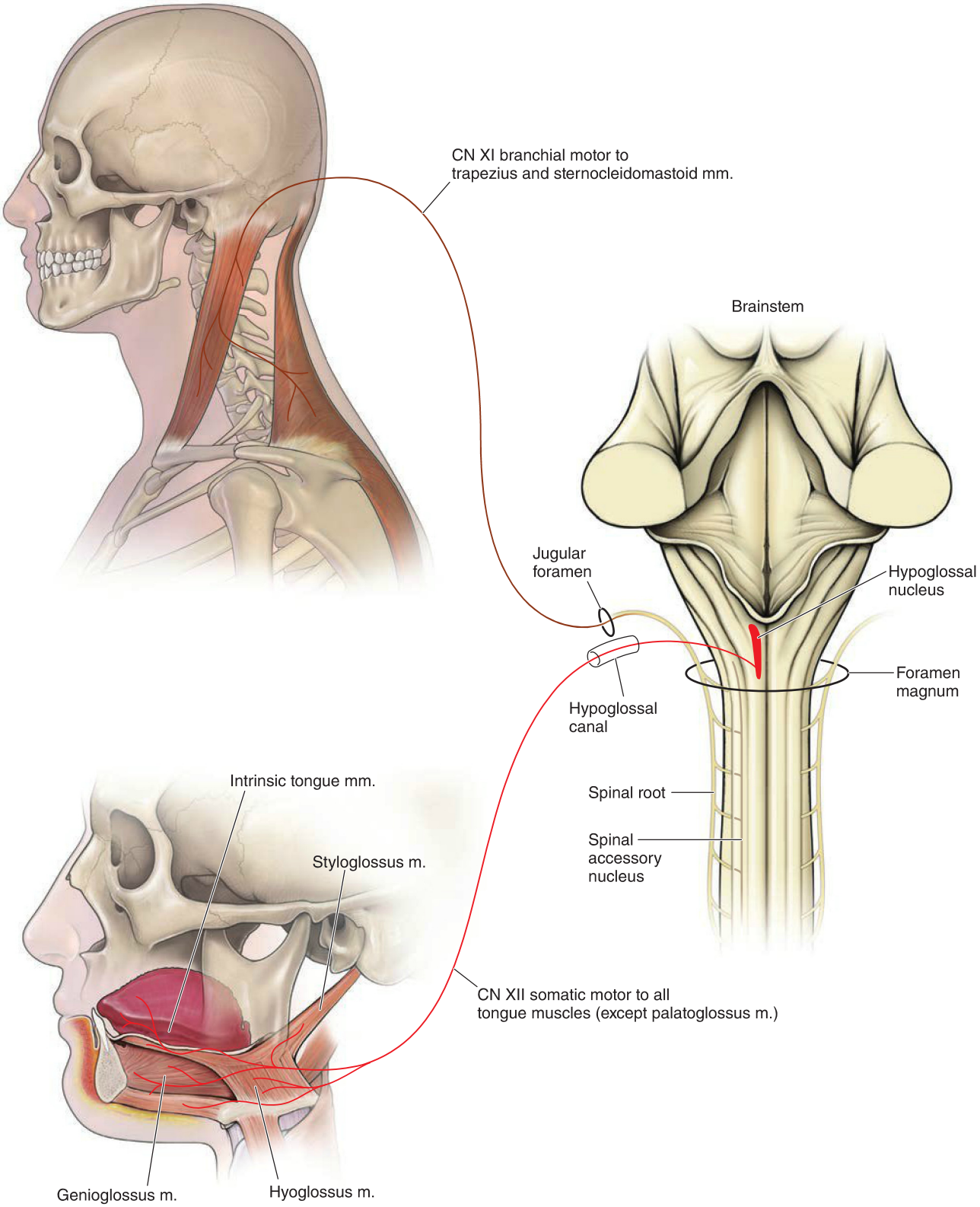

Figure 17-8: The spinal accessory nerve (CN XI) and the hypoglossal nerve (CN XII).

AUTONOMIC INNERVATION OF THE HEAD

BIG PICTURE

All preganglionic **sympathetic** neurons destined for the head originate at the T1 level of the spinal cord and synapse in the superior cervical ganglion. Postganglionic sympathetic neurons course along cranial arteries to the end organs such as the superior tarsal muscle, dilator pupillae muscle, blood vessels, and sweat glands.

Preganglionic **parasympathetic** neurons originate in the brainstem, course in CNN III, VII, IX, or X, and synapse in one of four ganglia (i.e., ciliary, pterygopalatine, submandibular, or otic). Postganglionic parasympathetic neurons then course along nerves to their end organs (e.g., salivary glands and pupillary sphincter muscle).

SYMPATHETIC INNERVATION

Remember that all preganglionic sympathetic neurons in the body originate at spinal cord levels T1–L2 (Figure 17-9). Sympathetic innervation to the head originates in the T1 spinal cord.

- ***Pre*ganglionic sympathetic fibers.** Originate from T1 of the spinal cord, ascend in the **sympathetic trunk**, and synapse with postganglionic fibers in the superior cervical ganglion.
- ***Post*ganglionic sympathetic fibers.** Exit the superior cervical ganglion and follow the arteries throughout the head to innervate the blood vessels, sweat glands, superior tarsal muscle (elevates the upper eyelid), and the dilatator pupillae muscle (dilates the pupil).

PARASYMPATHETIC INNERVATION

Four parasympathetic ganglia are associated with the cranial nerves (Figure 17-9; Table 17-3).

- **Ciliary ganglion.** Located posterior to the eyeball between the optic nerve and the lateral rectus muscle. Preganglionic parasympathetic neurons from the inferior division of CN III synapse in the ciliary ganglion and send postganglionic parasympathetic neurons to the sphincter pupillae and the ciliary muscles via the short ciliary nerves.
- **Pterygopalatine ganglion.** Located in the pterygopalatine fossa, just inferior to CN V-2 and lateral to the sphenopalatine foramen. Preganglionic parasympathetic neurons from CN VII synapse in the pterygopalatine ganglion and send postganglionic parasympathetic neurons to the lacrimal, nasal, and palatal glands.
- **Submandibular ganglion.** Suspended from the lingual nerve of CN V-3. Preganglionic parasympathetic neurons from CN VII synapse in the submandibular ganglion and send postganglionic parasympathetic neurons to supply the submandibular and sublingual salivary glands.
- **Otic ganglion.** Located in the infratemporal fossa inferior to the foramen ovale adjacent to CN V-3. Preganglionic parasympathetic neurons from CN IX synapse in the otic ganglion and send postganglionic neurons in the auriculotemporal nerve of CN V-3 to supply the parotid gland.

Four cranial nerves carry visceral motor parasympathetic innervation to the head:

- **CN III (oculomotor nerve).** Preganglionic parasympathetic neurons synapse in the ciliary ganglion, with postganglionic parasympathetic neurons serving the ciliary muscles and sphincter pupillae for light accommodation and constriction of the pupil.
- **CN VII (facial nerve).** Preganglionic neurons traveling in the greater petrosal nerve synapse in the pterygopalatine ganglion, with postganglionic parasympathetic neurons coursing to serve the lacrimal, nasal, and palatal glands. Preganglionic neurons from CN VII also travel within the chorda tympani nerve to synapse in the submandibular ganglion, with postganglionic neurons serving the submandibular and sublingual salivary glands.
- **CN IX (glossopharyngeal nerve).** Preganglionic parasympathetic neurons synapse in the otic ganglion, with postganglionic parasympathetic neurons serving the parotid gland.
- **CN X (vagus nerve).** Preganglionic parasympathetic neurons synapse at or near the target organ, with postganglionic parasympathetic neurons serving smooth muscle and glands of the gastrointestinal tract to the transverse colon, heart and lungs.

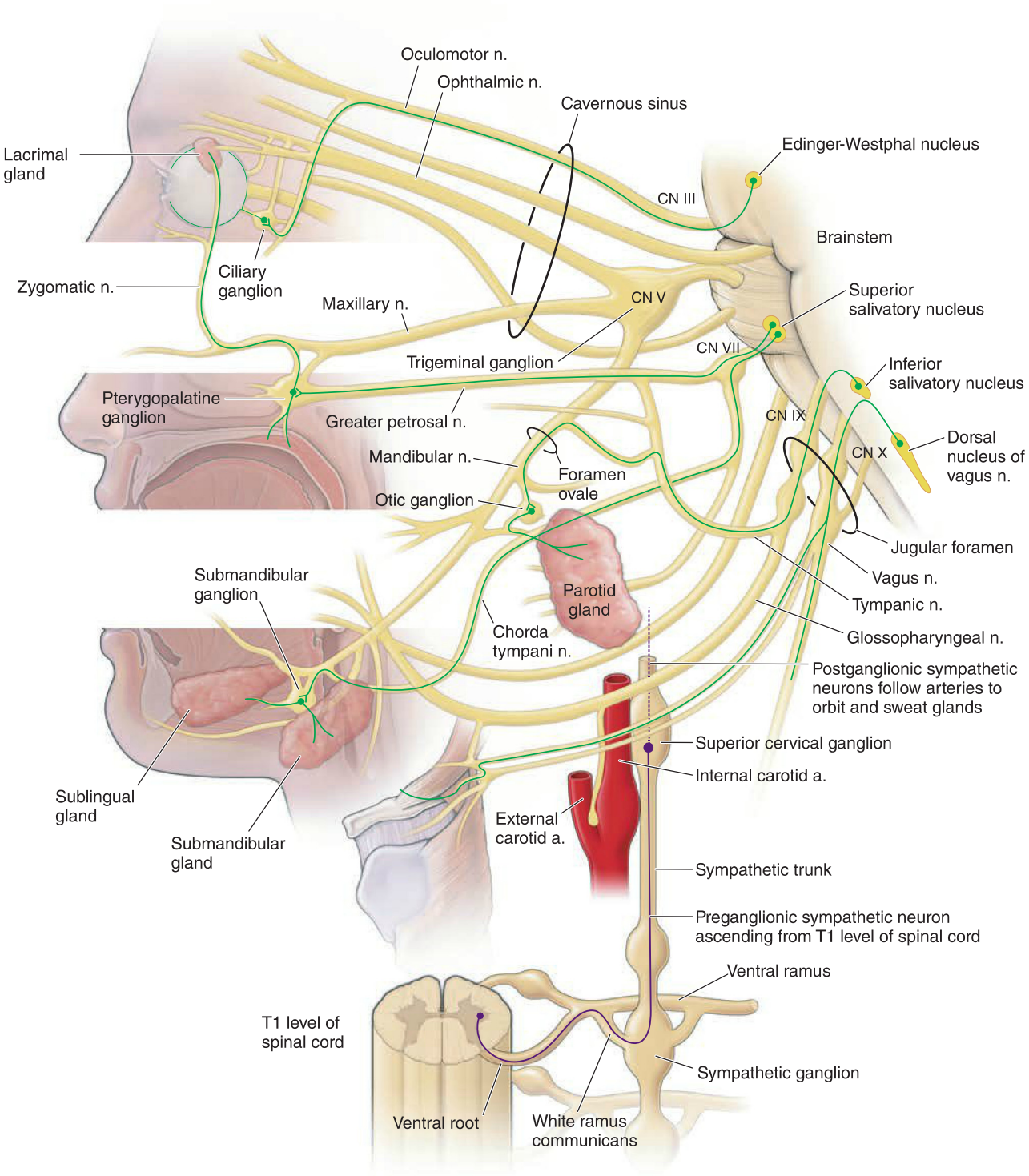

Figure 17-9: Autonomic innervation of the head.

TABLE 17-1. Modalities of the Cranial Nerves

Modality	General Function	CNN Containing the Modality
General sensory	Perception of pain, temperature, and touch	CN V (trigeminal), CN VII (facial), CN IX (glossopharyngeal), CN X (vagus)
Special sensory	Vision, smell, hearing, balance, and taste	CN I (olfactory), CN II (optic), CN VII (facial), CN IX (glossopharyngeal)
Visceral sensory	Sensory input from viscera	CN IX (glossopharyngeal), CN X (vagus)
Branchial motor	Motor innervation to skeletal muscle derived from branchial arches	CN V-3 (mandibular), CN VII (facial), CN IX (glossopharyngeal), CN X (vagus), CN XI (spinal accessory)
Somatic motor	Motor innervation to skeletal muscle derived from somites	CN III (oculomotor), CN IV (trochlear), CN VI (abducens), CN XII (hypoglossal)
Visceral motor	Motor innervation to smooth muscle, organs, and glands	CN III (oculomotor), CN VII (facial), CN IX (glossopharyngeal), CN X (vagus)

TABLE 17-2. Overview of the Cranial Nerves

CN	Modalities and Function	Exit from Skull
CN I (olfactory)	Special sensory: smell	Cribriform plate of the ethmoid bone
CN II (optic)	Special sensory: sight	Optic canal
CN III (oculomotor)	Somatic motor: levator palpebrae superioris m.; superior, medial, and inferior rectus mm.; inferior oblique mm. Visceral motor: sphincter pupillae m. (pupil constriction), and ciliary mm. (lens accommodation)	Superior orbital fissure
CN IV (trochlear)	Somatic motor: superior oblique m.	Superior orbital fissure
CN V (trigeminal)	General sensory: CN V-1: orbit and forehead CN V-2: maxillary region CN V-3: mandibular region, tongue Branchial motor: CN V-3: muscles of mastication, mylohyoid, anterior digastricus, tensor tympani, and tensor veli palatine mm.	CN V-1: superior orbital fissure CN V-2: foramen rotundum CN V-3: foramen ovale
CN VI (abducens)	Somatic motor: lateral rectus m.	Superior orbital fissure
CN VII (facial)	General sensory: external acoustic meatus and auricle Special sensory: anterior two-thirds of tongue Branchial motor: muscles of facial expression and stylohyoid, posterior digastricus, stapedius mm. Visceral motor: lacrimal, submandibular, sublingual, palatal, and nasal glands	Internal acoustic meatus

TABLE 17-2. Overview of the Cranial Nerves *(continued)*

CN	Modalities and Function	Exit from Skull
CN VIII (vestibulocochlear)	Special sensory: hearing, balance, and equilibrium	Internal acoustic meatus
CN IX (glossopharyngeal)	General sensory: posterior third of tongue, oropharynx, tympanic membrane, middle ear, and auditory tube Special sensory: taste from posterior one-third of tongue Visceral sensory: carotid sinus (baroreceptor) and carotid body (chemoreceptor) Branchial motor: stylopharyngeus m. Visceral motor: parotid gland	Jugular foramen
CN X (vagus)	General sensory: skin of the posterior ear and external acoustic meatus Visceral sensory: aortic and carotid bodies (chemoreceptors) and aortic arch (baroreceptor) Branchial motor: palatal muscles (except tensor tympani); pharyngeal muscles (except stylopharyngeus m.) and laryngeal mm. Visceral motor: heart, smooth muscle, and glands of the respiratory tract, gastrointestinal tube, and viscera of the foregut and midgut	Jugular foramen
CN XI (spinal accessory)	Branchial motor: trapezius and sternocleidomastoid mm.	Jugular foramen
CN XII (hypoglossal)	Somatic motor: tongue mm. (except palatoglossus m.)	Hypoglossal canal

Key: m., muscle; mm., muscles.

TABLE 17-3. Parasympathetic Innervation of the Head

CN	Preganglionic Parasympathetic Cell Body Origin	Postganglionic Parasympathetic Cell Body Origin	Function
CN III (oculomotor)	Edinger–Westphal nucleus	Ciliary ganglion	Sphincter pupillae m. (constricts pupil) and ciliary m. (lens accommodation for near vision)
CN VII (facial)	Superior salivatory nucleus	Pterygopalatine ganglion Submandibular ganglion	Lacrimal, nasal, and palatal glands Submandibular and sublingual salivary glands
CN IX (glossopharyngeal)	Inferior salivatory nucleus	Otic ganglion	Parotid gland
CN X (vagus)	Posterior vagal nucleus	Intramural ganglia	Innervates heart, smooth muscle of respiratory tract, gastrointestinal tract (up to splenic flexor), and viscera associated with foregut and midgut

This page intentionally left blank

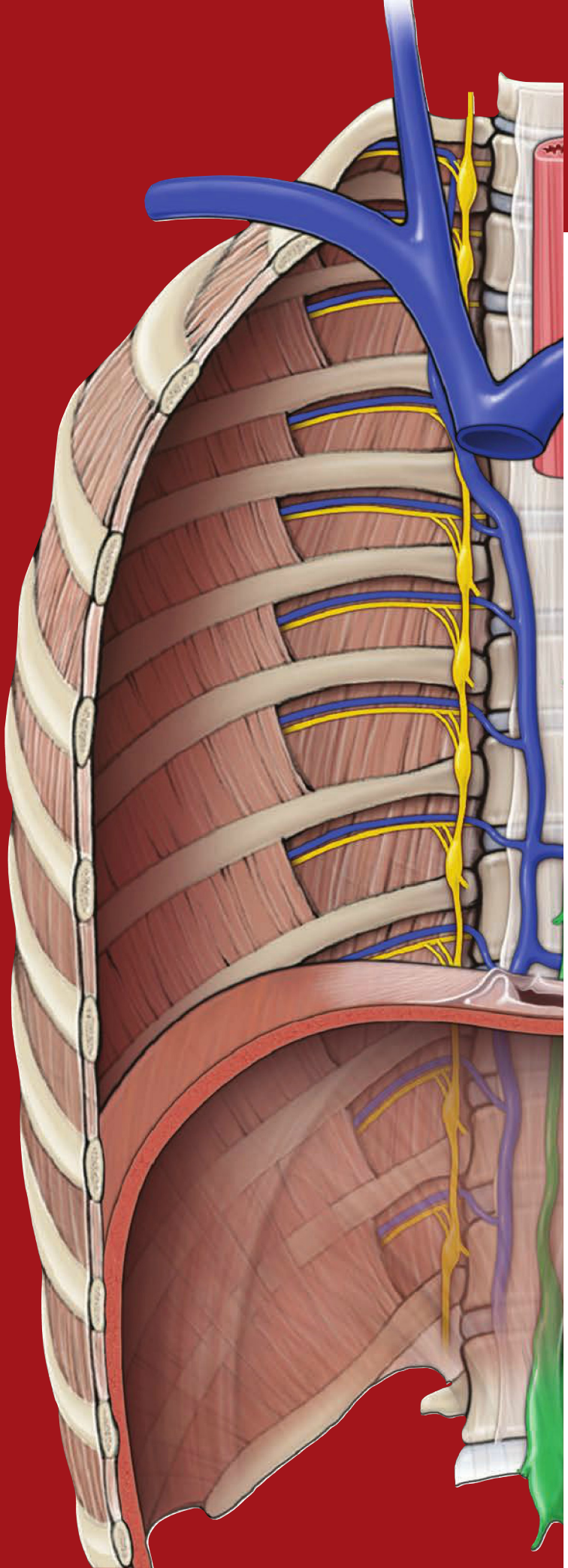

CHAPTER 18

ORBIT

Orbital Region 208
The Eye 210
Extraocular Muscle Movement 212
Innervation of the Orbit 216

ORBITAL REGION

BIG PICTURE

The primary organ responsible for vision is the eye. The eyeball is located within a bony orbital encasement, which protects it. The lacrimal apparatus keeps the eye moist and free of dust and other irritating particles through the production and drainage of tears. Eyelids protect the eye from external stimuli such as dust, wind, and excessive light.

BONY ORBIT

The bony orbit is the region of the skull that surrounds the eye and is composed of the following structures and openings (Figure 18-1A):

- **Bones.** Formed by parts of the parietal, frontal, lacrimal, ethmoid, maxilla, zygomatic, and sphenoid bones.
- **Supraorbital foramen.** Transmits the supraorbital nerve [cranial nerve (CN) V-1] and vessels to the scalp.
- **Infraorbital foramen.** Transmit the infraorbital nerve (CN V-2) and vessels to the maxillary region of the teeth and face.
- **Anterior and posterior ethmoidal foramina.** Transmits the anterior and posterior ethmoidal nerves and vessels to the nasal cavity and the sphenoid and ethmoid sinuses.
- **Nasolacrimal canal.** Drains tears from the eye to the inferior meatus in the nasal cavity.
- **Optic canal.** Transmits the optic nerve (CN II) and the ophthalmic artery.
- **Superior orbital fissure.** Transmits CNN III, IV, V-1, and VI and superior ophthalmic veins.
- **Inferior orbital fissure.** Communicates with the infratemporal and pterygopalatine fossae and maxillary sinus; transmits CN V-2 and the infraorbital artery and vein.

LACRIMAL APPARATUS

The **lacrimal gland** lies in the superolateral corner of the orbit (Figure 18-1B).

- **Tears.** The lacrimal gland secretes tears that spread evenly over the eyeball through blinking and cleanse the eye of dust and foreign particles.
- **Drainage.** Tears drain from the eyeball, via the nasolacrimal duct, into the inferior nasal meatus of the nasal cavity.
- **Innervation.** The lacrimal gland is innervated by the greater petrosal nerve (a branch from CN VII) (Figure 18-4C).

▽ **Watery eyes.** The mucosa of the nasal cavity is continuous with the mucosa of the nasolacrimal duct system and as such a cold or "stuffy" nose often causes the lacrimal mucosa to become inflamed and swollen. Swelling constricts the ducts and prevents tears from draining from the eye surface, causing "watery" eyes. ▼

EYELIDS

Eyelids protect the eye from foreign particles and from bright light (Figure 18-1C). The external surface of the eyelids is covered by skin, whereas the conjunctiva covers the internal surface.

CONJUNCTIVA A mucous membrane that lines the internal surface of the eyelids. The conjunctiva is reflected at the superior and inferior fornices onto the anterior surface of the eyeball and forms the conjunctival sac when the eyes are closed.

EYELID MUSCLES Tears produced by the lacrimal gland are secreted continually and are spread over the conjunctiva and cornea by movement of the eyelids (blinking). The eyelids move through the action of three different muscles innervated by three different nerves:

- **Orbicularis oculi muscle.** A circular muscle that closes the eye; innervated by the facial nerve proper (CN VII).
- **Levator palpebrae superioris muscle.** Skeletal muscle that elevates the upper eyelid; innervated by CN III.
- **Superior tarsal (Müller's) muscle.** Smooth muscle that elevates the eyelid; attaches between the levator palpebrae superioris muscle and the upper eyelid; innervated by sympathetic nerves.

▽ **Corneal reflex.** Elicited by touching the cornea and results in bilateral blinking in both eyes. The nasociliary nerve (CN V-1) mediates the sensory portion of this reflex, the pons mediates the CNS relay center, and facial nerve proper (CN VII) initiates the motor response by innervating the orbicularis oculi muscle. ▼

▽ **Horner's syndrome.** Caused by damage to the sympathetic innervation to the head (Figure 18-1D). Signs of Horner's syndrome are observed on the ipsilateral side of the injury as follows:

- **Ptosis** (drooping upper eyelid). Results from loss of sympathetic innervation to the superior tarsal muscle.
- **Anhidrosis** (loss of sweating). Results from loss of sympathetic innervation to sweat glands.
- **Miosis** (excessively constricted pupil). Results from loss of sympathetic innervation to the dilator pupillary muscle.

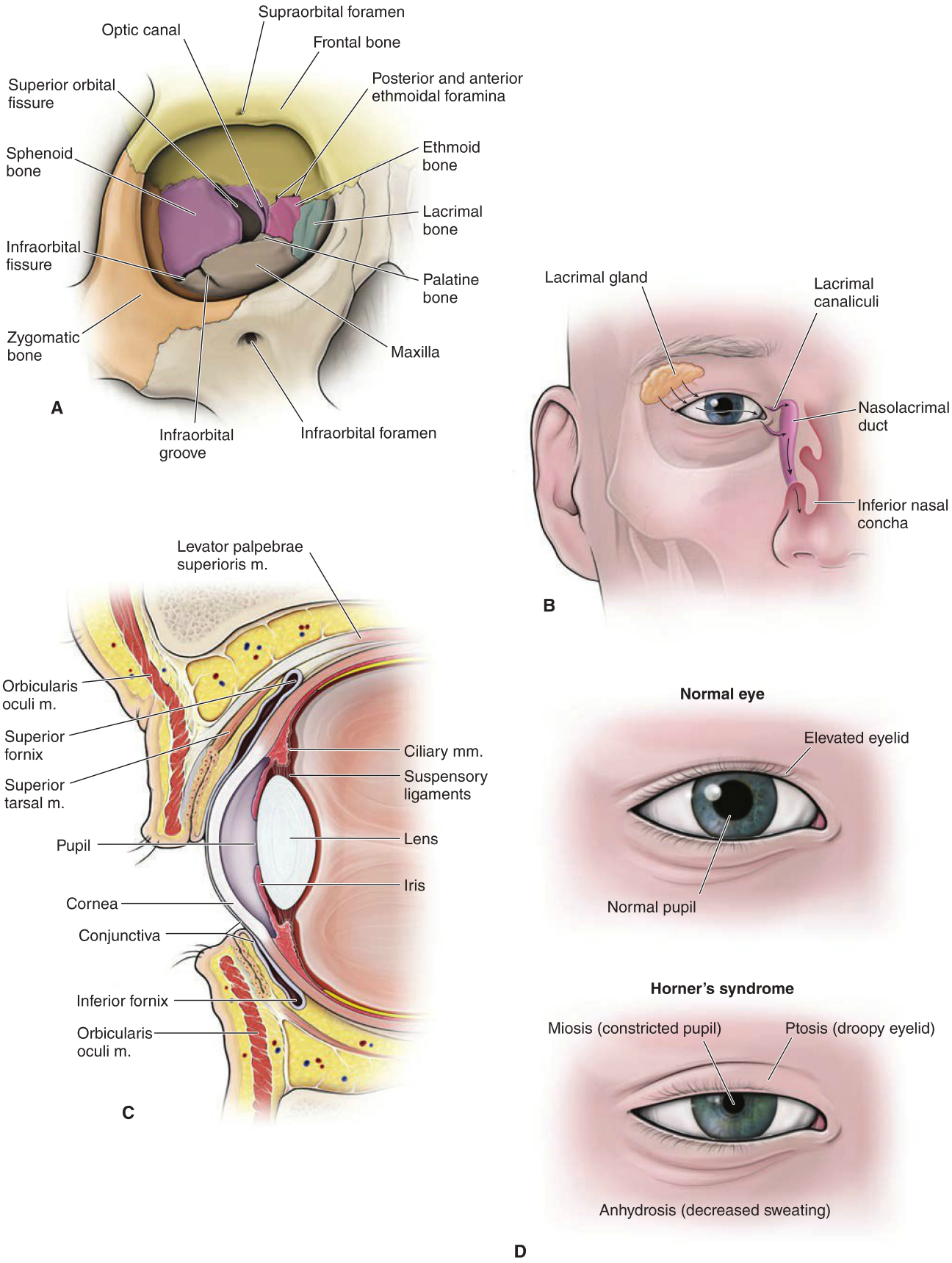

Figure 18-1: A. Bony orbit. **B**. Lacrimal apparatus. **C**. Sagittal section of the eyelid. **D**. A normal right eye in contrast to an eye with Horner's syndrome.

THE EYE

BIG PICTURE

The eyeball consists of the sclera, choroid, and retina.

SCLERA

The sclera is the white, fibrous covering of the eye into which muscles insert (Figure 18-2A).

- **Cornea.** The sclera is continuous anteriorly as the **cornea**, which forms a bulging, transparent region specialized for refracting light as it enters the eye. The cornea receives general sensory innervation from the nasociliary nerve (CN V-1).

CHOROID

The choroid is the vascular, middle layer of the eye and is composed of the following (Figure 18-2A and B):

CILIARY APPARATUS The anterior region of the choroid consists of the ciliary muscle, which is composed of smooth muscle and is innervated by parasympathetic neurons from CN III (Figure 18-2B).

- **Ciliary muscle.** This circular muscle surrounds the periphery of the lens. Contraction causes the diameter of the muscle to decrease, whereas relaxation causes the diameter of the muscle to increase. Understanding this concept is essential to understanding how the lens focuses on images near and far.
- **Lens.** A transparent biconvex structure enclosed in an elastic covering. The lens is held in position by radially arranged **suspensory ligaments**, which are attached medially to the lens capsule and laterally to the ciliary muscles.

ACCOMMODATION Process by which the lens changes shape to maintain a focused image from distant or near objects.

- **Distant vision.** Light rays from distant objects are nearly parallel and do not need as much refraction to bring them into focus (Figure 18-2C). Therefore, to focus on distant objects, the ciliary muscle relaxes, which stretches the suspensory ligaments and flattens the lens. When the lens is flat (least rounded), it is at optimal focal length for distant viewing.
- **Near vision.** Light rays from close objects diverge and require more refraction to focus (Figure 18-2D). To focus on near objects, parasympathetic neurons in CN III cause ciliary muscle contraction and thus relaxation of the tension on the suspensory ligaments, allowing the lens to become more rounded. When the lens is round, it is at optimal focal length for near viewing.

IRIS The iris is the visible colored part of the eye (Figure 18-2B). The round central opening of the iris is the **pupil**, which allows light to enter the eye. The iris consists of smooth muscles under autonomic control, which contract reflexively and vary the size of the pupil.

- **Sphincter pupillae muscle.** Causes pupil constriction in bright light and close vision via visceral motor (parasympathetic) innervation from CN III.
- **Dilator pupillae muscle.** Causes pupil dilation in dim light and distant vision to enable more light to enter the eye via sympathetic innervation.

▽ **Pupillary light reflex.** Regulates the intensity of light entering the eye by controlling the diameter of the pupil. Greater intensity of light causes the pupil to become smaller, thus allowing less light to reach the retina. CN II is responsible for the sensory limb of the pupillary reflex by sensing the incoming light. Visceral motor innervation from CN III is responsible for the motor response by constricting the pupil. Light entering one eye should produce constriction of both pupils. An abnormal pupillary light reflex reveals potential problems with CN II, CN III, or the brainstem. ▼

RETINA

The retina is the innermost layer of the eyeball (Figure 18-2A).

- **Optic disc.** Consists of the nerve fibers from CN II and thus has no photoreceptors and is insensitive to light, hence the nickname "the blind spot."
- **Macula lutea.** A structure lateral to the optic disc that is specialized for high-acuity vision. Within the macula is the **fovea centralis**, which contains high concentration of photoreceptors. The eye is positioned such that light rays from the object in the center of the view fall upon this region.
- **Photoreceptors (rods and cones).** Rods are specialized cells for vision in dim light (black, gray, white vision), whereas cones are associated with visual acuity and color vision.

CHAMBERS OF THE EYE

The eye is divided into the following segments (Figure 18-2B).

- **Posterior segment.** Known as the **vitreous chamber**, the posterior segment is filled with a clear gel called **vitreous humor**, which contributes to the intraocular pressure.
- **Anterior segment.** Subdivided by the iris into the **anterior chamber** (between the cornea and iris) and the **posterior chamber** (between the iris and lens). The anterior segment is filled with **aqueous humor**, which has a composition similar to plasma. Unlike vitreous humor, which is constant and is never replaced, aqueous humor forms and drains continually into the venous system via the canal of Schlemm.

▽ **Glaucoma.** Aqueous humor is produced and drained at a constant rate, and as a result, a constant intraocular pressure is maintained. If drainage of aqueous humor is impaired, the pressure within the eye may increase and cause compression of the retina and damage the optic nerve, resulting in a condition known as glaucoma. ▼

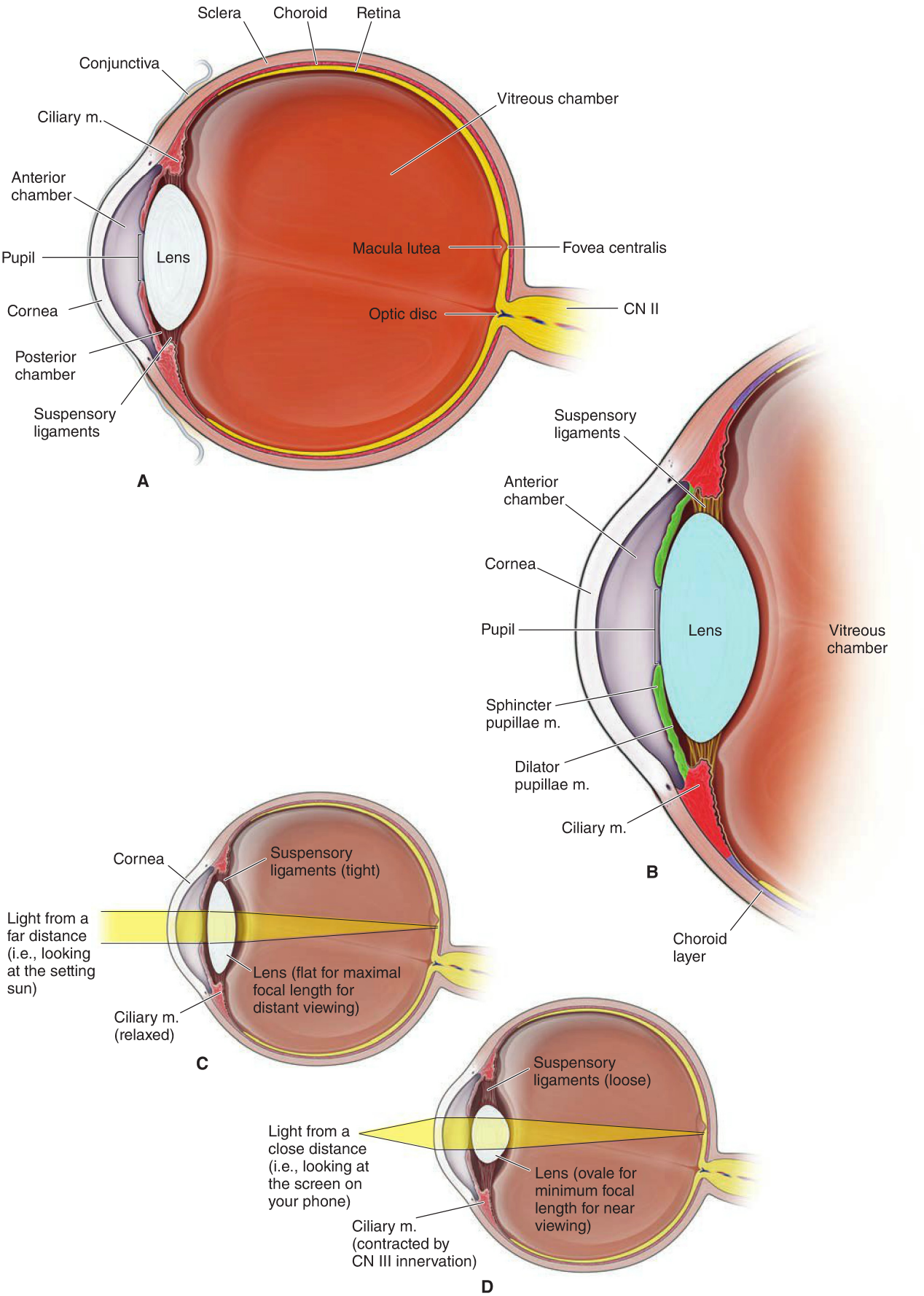

Figure 18-2: A. Axial section of the eye. **B**. Close-up of the axial section of the anterior portion of the eye. **C**. Light from a distance is bent by the stretched lens to strike the retina. **D**. Light from a source nearby is bent even more sharply by the relaxed lens to strike the retina.

EXTRAOCULAR MUSCLE MOVEMENT

BIG PICTURE

Six strap-like extraocular muscles (four rectus and two oblique) control the movement of the eye (elevation, depression, abduction, adduction, intorsion, and extorsion).

EYE MOVEMENT

The eye moves in the following **three axes of rotation** (Figure 18-3A):

- ***X*-axis.** A horizontal axis in the axial plane resulting in abduction and adduction.
- ***Y*-axis.** A vertical axis in the sagittal plane resulting in elevation and depression.
- ***Z*-axis.** A horizontal axis in the sagittal plane resulting in intorsion and extorsion.

The extraocular muscles act upon the eye in these three axes to cause the eye to move in the following dimensions:

- **Elevation** and **depression.** An upward and downward gaze, respectively.
- **Abduction** and **adduction.** A lateral and medial gaze, respectively.
- **Intorsion (medial rotation).** An inward medial rotation of the upper pole of the vertical meridian caused by the superior oblique and superior rectus muscles.
- **Extorsion (lateral rotation).** An outward lateral rotation of the upper pole of the vertical meridian caused by the inferior oblique and inferior muscles rectus.

Each of the six extraocular muscles exerts rotational forces in all three axes (elevation–depression, abduction–adduction, and intorsion–extorsion) to varying degrees, providing fine motor control to direct gaze.

EXTRAOCULAR MUSCLES

The movement of each eyeball is controlled by the six extraocular muscles innervated by CNN III, IV, and VI (Figure 18-3B and C). The muscles arise from a **common tendinous ring** in the posterior part of the orbit (except the inferior oblique muscle). To determine the action of each realize that the **apex of the orbit** is not parallel with the **optical axis** (when looking directly forward) (Figure 18-3D). Therefore, when the superior and inferior rectus muscles and the oblique muscles contract, secondary actions occur on the eyeball's movement, as follows (Figure 18-3E):

- **Superior rectus muscle (CN III).** Elevation of the eye, with adduction and intorsion.
- **Inferior rectus muscle (CN III).** Depression of the eye, with adduction and extorsion.
- **Lateral rectus muscle (CN VI).** Only action is abduction of the eye.
- **Medial rectus muscle (CN III).** Only action is adduction of the eye.
- **Superior oblique muscle (CN IV).** Courses along the medial wall of the orbit, traverses a fibrous sling (**trochlea**), courses backward, and inserts on the superolateral region of the eyeball. Moves the eyeball down and out (depression and abduction), with intorsion.
- **Inferior oblique muscle (CN III).** Originates on the medial wall of the bony orbit and courses laterally and obliquely to insert on the inferolateral surface of the eyeball. Moves the eyeball up and out (elevation and abduction), with extorsion.

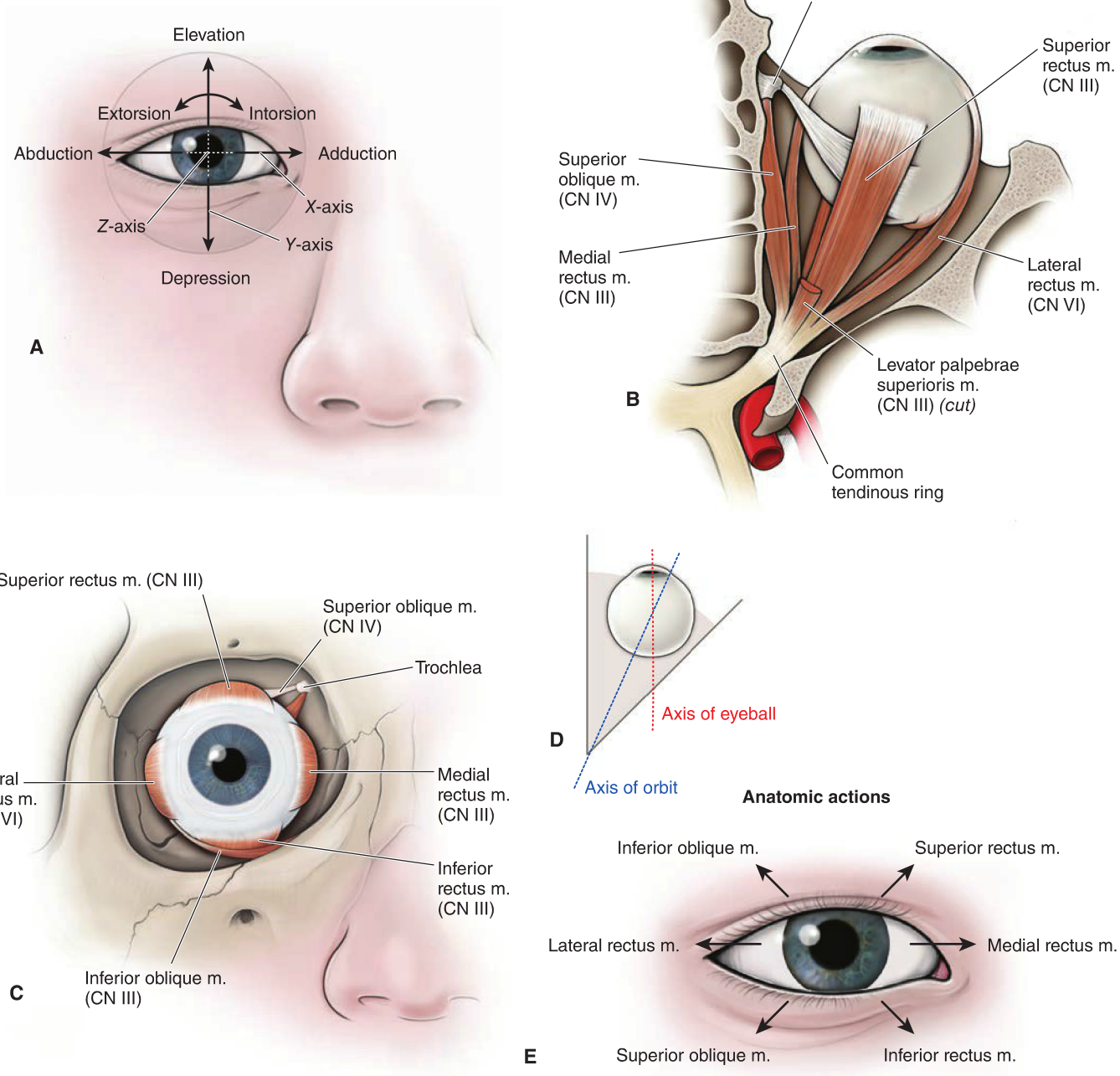

Figure 18-3: A. Movements of the eyeball. Extraocular muscles of the right eye; **(B)** superior and **(C)** anterior views. **D**. Axes of the eyeball and orbit. **E**. Anatomic actions of the right extraocular muscles.

CLINICAL EXAMINATION OF THE EXTRAOCULAR MUSCLES

When performing a physical examination of the eye, a physician will test each of the extraocular muscles and their associated cranial nerves by drawing an "H" pattern in the air in front of the patient's face (Figure 18-3F). The patient is instructed to follow the physician's finger with their eyes only.

- **Horizontal line of the "H."** The medial and lateral rectus muscles are the only muscles that move the eye in the horizontal plane and are therefore straightforward to test.
  - **Medial rectus.** Adduct the eye.
  - **Lateral rectus.** Abduct the eye.
- **Vertical lines of the "H."** The vertical motion of the eye is a little more complex than the horizontal motion. When a patient's gaze is up, it occurs as a result of the combined action of the superior rectus and inferior oblique muscles. When the gaze is down, it is from the combined action of the inferior rectus and superior oblique muscles. Therefore, when clinically testing the extraocular muscles, one muscle is tested at a time, without influence from another extraocular muscle. To test any of these four muscles that move the eyeball in the *Y*-axis, each muscle must be isolated from the others.
  - **Lateral vertical line tests the rectus muscles.** When the right eye is fully abducted, only the superior and inferior rectus muscles elevate and depress the eye, respectively. This is purely a mechanical property because of the axis of the eye lining up parallel to the line of contraction of the superior and inferior rectus muscles.
    - **Superior rectus.** Abduct the eye and then elevate. Abduction removes the biomechanical advantage of the inferior oblique muscle to elevate the eye. Therefore, when the eye is abducted the only muscle that can elevate the eye is the superior rectus muscle.
    - **Inferior rectus.** Abduct the eye and then depress. Abduction removes the biomechanical advantage of the superior oblique muscle to depress the eye. Therefore, when the eye is abducted the only muscle that can depress the eye is the inferior rectus muscle.
  - **Medial vertical line tests the oblique muscles.** When the right eye is fully adducted, only the inferior and superior oblique muscles elevate and depress the eye, respectively. Again, this is due to the axis of the muscles paralleling the axis of the eye.
    - **Inferior oblique muscle.** Adduct the eye and then elevate. Adduction removes the biomechanical advantage of the superior rectus to elevate the eye. Therefore, when the eye is adducted, the only muscle that can elevate the eye is the inferior oblique muscle.
    - **Superior oblique muscle.** Adduct the eye and then depress. Adduction removes the biomechanical advantage of the inferior rectus to depress the eye. Therefore, when the eye is adducted, the only muscle that can depress the eye is the superior oblique muscle.

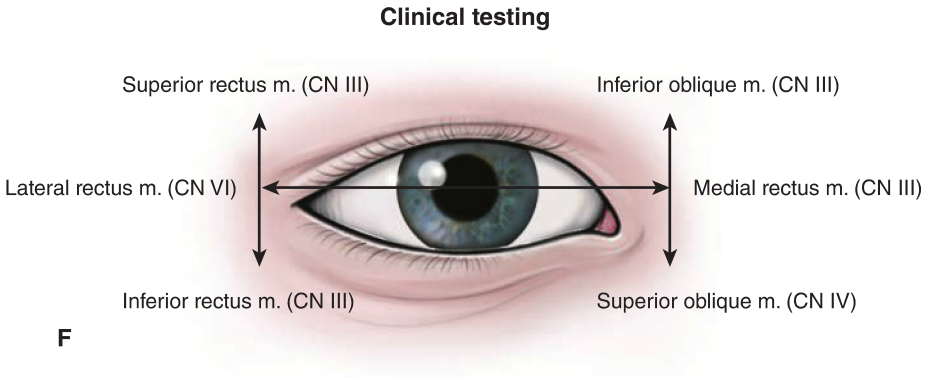

F

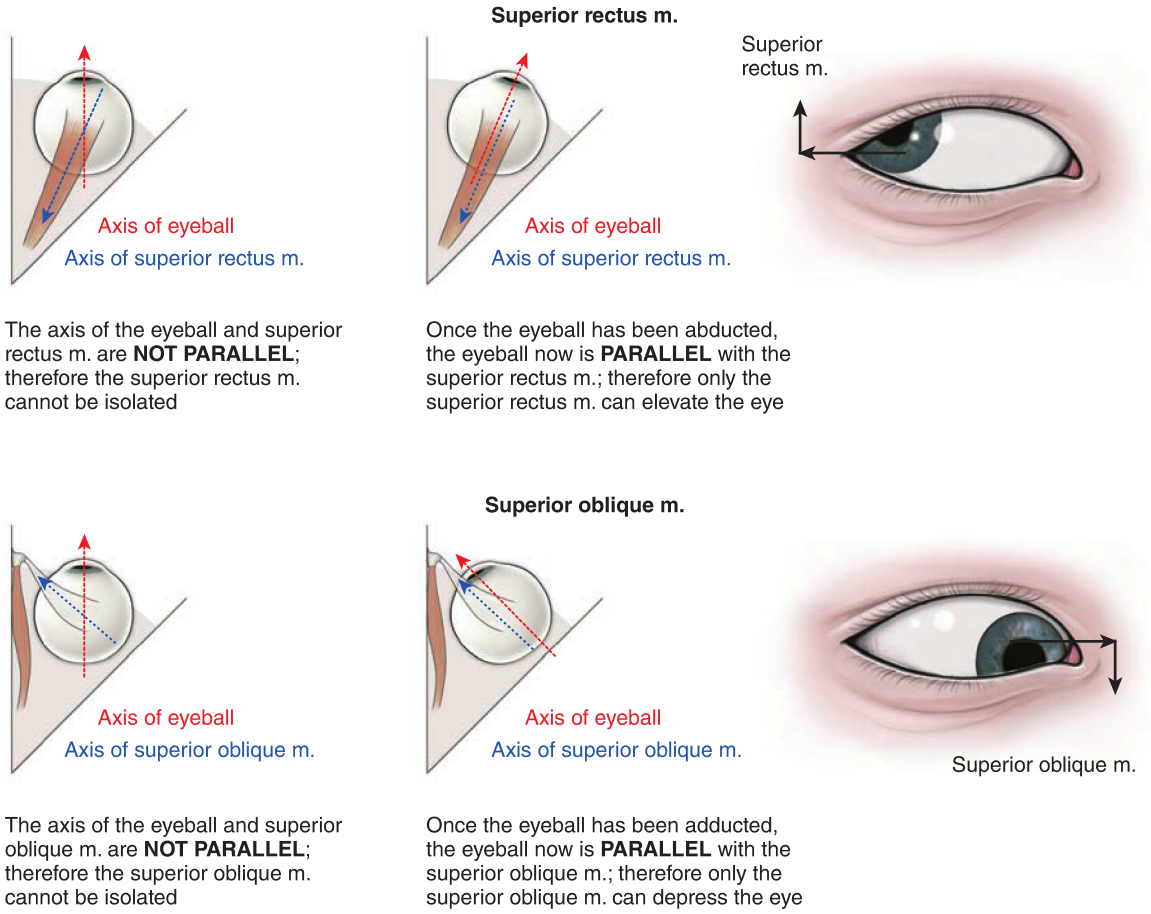

Figure 18-3: (*continued*) **F**. Clinical examination of the extraocular muscles and associated Cranial Nerves. The superior rectus and superior oblique muscles are highlighted.

INNERVATION OF THE ORBIT

BIG PICTURE

The cranial nerves associated with the orbit are CN II (vision), CN III (eye movement), CN IV (eye movement), CN V-1 (general sensory to eye and scalp), CN VI (eye movement), and CN VII (crying and closing the eyes).

CN II: OPTIC NERVE

The optic nerve enters the orbit through the optic canal along with the ophthalmic artery and provides **special sensory innervation (vision)** from the **retina** to the brain. CN II from one eye joins CN II from the corresponding eye to form the **optic chiasma**.

CN III: OCULOMOTOR NERVE

The oculomotor nerve emerges from the midbrain and courses anteriorly between the posterior cerebral and the superior cerebellar arteries, through the lateral wall of the cavernous sinus and superior orbital fissure into the orbit, where the nerve bifurcates into superior and inferior divisions (Figure 18-4B and C).

- **Superior division.** Provides somatic motor innervation to the levator palpebrae superioris and superior rectus muscles.
- **Inferior division.** Provides somatic motor innervation to the medial rectus, inferior rectus, and inferior oblique muscles. CN III also provides visceral motor innervation. Preganglionic parasympathetic neurons originate in the Edinger–Westphal nucleus and course in the inferior division of CN III and synapse in the ciliary ganglion (between CN II and the lateral rectus muscle). Postganglionic parasympathetic neurons course in the short ciliary nerves to enter the eyeball and innervate the ciliary muscles (lens accommodation) and pupillary sphincter muscles (pupil constriction).

CN IV: TROCHLEAR NERVE

The trochlear nerve arises from the posterior surface of the midbrain and courses through the lateral wall of the cavernous sinus to enter the orbit via the superior orbital fissure (Figure 18-4A). CN IV provides somatic motor innervation to the superior oblique muscle.

CN V-1: OPHTHALMIC BRANCH OF THE TRIGEMINAL NERVE

The ophthalmic nerve arises from the pons as a branch of the trigeminal nerve and enters the orbit via the superior orbital fissure; provides general sensory innervation to the orbit via the following three branches (Figure 18-4A–C):

- **Lacrimal nerve.** Lacrimal gland (sensory not motor), conjunctiva, and skin of the upper eyelid.
- **Frontal nerve.** Courses superior to the levator palpebrae superioris muscle and bifurcates into the supraorbital and supratrochlear nerves to innervate the skin of the forehead and scalp.
- **Nasociliary nerve.** Provides general sensory innervation via the following branches:
  - **Long ciliary nerves.** Cornea (sensory limb of the corneal reflex).
  - **Posterior ethmoidal nerve.** Sphenoid and ethmoidal sinuses.
  - **Anterior ethmoidal nerve.** Ethmoid air cells, nasal septum, and tip of the nose.
  - **Infratrochlear nerve.** Upper eyelid, conjunctiva, and bridge of the nose.

CN VI: ABDUCENS NERVE

The abducens nerve arises ventrally from the pons and enters the orbit via the superior orbital fissure and provides somatic motor innervation to the lateral rectus muscle (Figure 18-4B).

CN VII: FACIAL NERVE

In the orbit, the facial nerve "makes you cry" (parasympathetic innervation of lacrimal gland) and "closes your eye" (branchial motor innervation of orbicularis oculi muscle) (Figure 18-4C).

- **Lacrimal gland.** Preganglionic parasympathetic neurons arise from the superior salivatory nucleus (pons) and exit the cranial cavity through the internal acoustic meatus. At the geniculate ganglion, CN VII gives off the greater petrosal nerve, which joins with the deep petrosal nerve (sympathetics from the carotid plexus), becoming the nerve of the pterygoid canal (Vidian nerve). The nerve of the pterygoid canal enters the pterygopalatine fossa, where preganglionic parasympathetic neurons synapse in the pterygopalatine ganglion. Postganglionic parasympathetic neurons join with the zygomatic nerve (CN V-2) and then with the lacrimal nerve (CN V-1) to innervate the lacrimal gland (produces tears).
- **Orbicularis oculi muscle.** Branchial motor neurons arise from the facial motor nucleus in the pons, traverse the internal acoustic meatus, descend the facial canal, exit the stylomastoid foramen, permeate through the parotid gland, and innervate the orbicularis oculi muscle (closes eyelid).

ORBITAL SYMPATHETICS

Sympathetics to the orbit course in the following pathways (Figure 18-4C):

- Postganglionic sympathetic neurons originating in the superior cervical ganglion ascend along the internal carotid artery up to the ophthalmic artery.
- Sympathetic nerves innervate the superior tarsal muscle (keeping the eyelid elevated) and the dilator pupillae muscles (dilates the pupil).

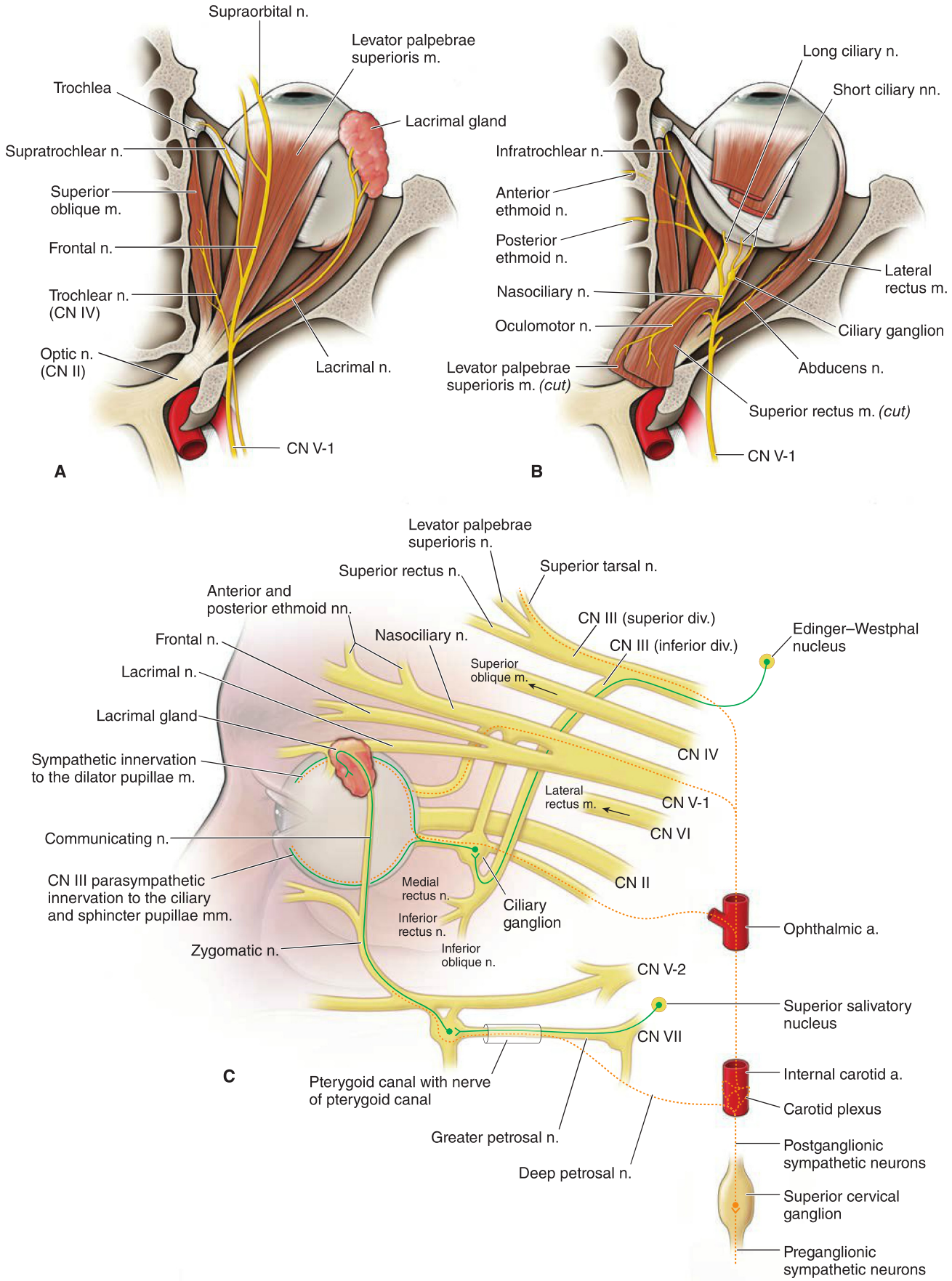

Figure 18-4: Superior view of the nerves of the orbit: (**A**) superficial; (**B**) deep. **C**. Comprehensive innervation of the orbit highlighting autonomics.

This page intentionally left blank

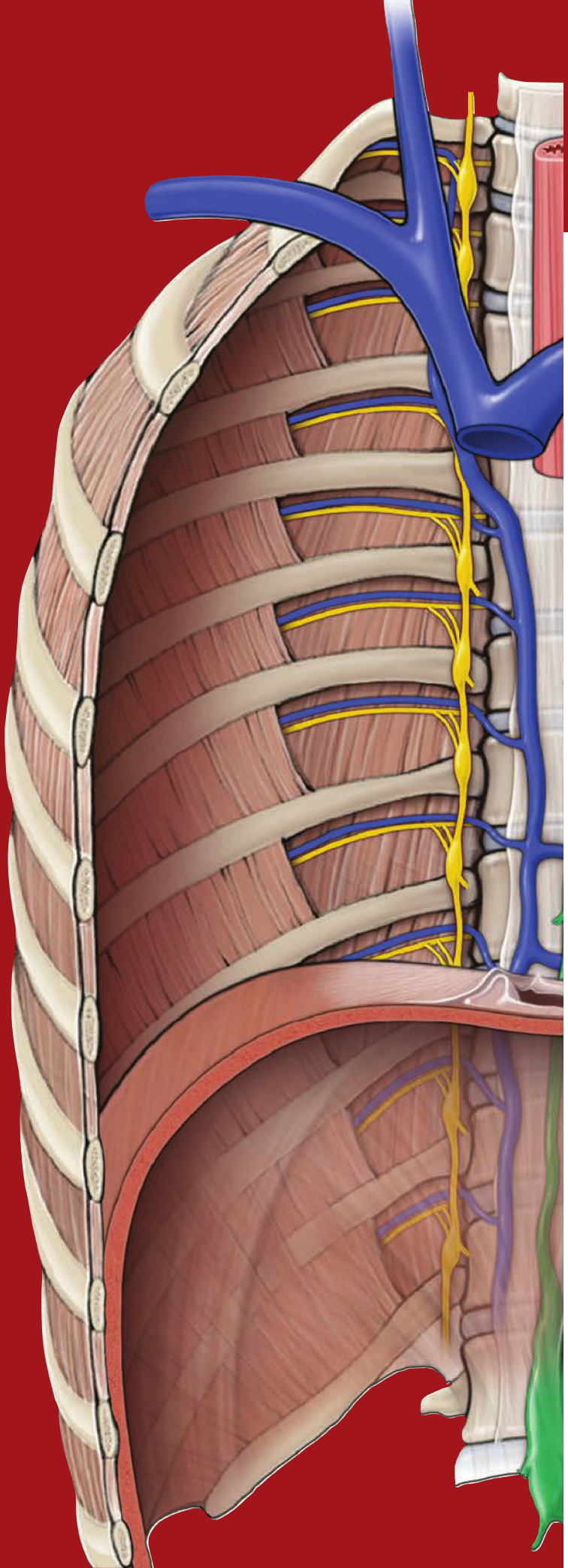

CHAPTER 19

EAR

The Ear 220

THE EAR

BIG PICTURE

The **external ear** collects sound waves and transports them through the external acoustic meatus to the tympanic membrane. The tympanic membrane vibrates, setting three tiny ear ossicles (malleus, incus, and stapes) in the **middle ear** into motion. The stapes attaches to the lateral wall of the **inner ear**, where the vibration is transduced into fluid movement. The fluid causes the basilar membrane in the cochlea to vibrate. The vestibulocochlear nerve [cranial nerve (CN) VIII] receives and conducts the impulses to the brain, where there is integration of sound and equilibrium.

EXTERNAL EAR

The external ear consists of the **auricle**, or pinna, which lies at the outer end of a short tube called the **external acoustic meatus** (Figure 19-1A). The auricle funnels sound waves through the external acoustic meatus to the **tympanic membrane**. The external ear receives general sensory innervation from trigeminal, facial, and vagus nerves, and the great auricular nerve.

TYMPANIC MEMBRANE The **tympanic membrane**, or "eardrum," is a three-layered circular structure (Figure 19-1A–C).

- **Outer (skin) layer.** Composed of modified skin that is continuous with the external acoustic meatus.
- **Middle (fibrous) layer.** Composed of connective tissue through which the **chorda tympani nerve (CN VII)** passes.
- **Inner (mucosa) layer.** Lined with the mucosa of the middle ear, and receives general sensory innervation via the **tympanic plexus (CN IX)**.

MIDDLE EAR

The middle ear is an air-filled chamber that transmits sound waves from air (external ear) to the auditory ossicles (middle ear) and then to the fluid-filled inner ear (Figure 19-1A). The middle ear consists of the tympanic cavity proper, auditory tube, ear ossicles, and branches of CNN VII and IX.

TYMPANIC CAVITY PROPER The tympanic cavity proper is the space between the **tympanic membrane** and the **vestibular window**. Its mucosa receives general sensory innervation from the **tympanic nerve** and **the tympanic plexus (CN IX)** (Figure 19-1A–D). In addition, visceral motor preganglionic parasympathetic fibers from CN IX branch from the tympanic plexus to exit the middle ear as the **lesser petrosal nerve** en route to innervate the **parotid gland**.

- **Vestibular (oval) window.** A membrane-covered opening between the middle ear and the **vestibule** of the inner ear. The oval window is pushed back and forth by the footplate of the stapes and transmits the vibrations of the ossicles to the **perilymph** at the origin of the **scala vestibuli** in the inner ear.
- **Cochlear (round) window.** A membrane-covered opening that accommodates the pressure waves transmitted to the perilymph at the end of the **scala tympani**.

AUDITORY TUBE An osseous–cartilaginous tube that connects the nasopharynx and middle ear (Figure 19-1A); receives general sensory innervation from the tympanic plexus (CN IX) and serves as an attachment for the **tensor tympani muscle**. Also known as the Eustachian or pharyngotympanic tube.

Equalizing air pressure. The auditory tube normally is collapsed, but yawning or swallowing can open the tube, allowing air to enter, which equalizes the pressure between the middle ear and the atmosphere. When air enters, which can occur when in an airplane or at a high elevation, a soft "pop" sound may be felt.

Otitis media. A patient with otitis media (middle ear infection) may present with a red bulging tympanic membrane, which is usually due to a buildup of fluid or mucus. This inflammation is often the result of a pharyngeal infection transmitted via the auditory tube to the middle ear. Because the auditory tube is shorter and more horizontal in children, it is easier for infection to spread from the nasopharynx to the middle ear, resulting in a higher prevalence of otitis media in children compared to adults. Hearing may be diminished because of the pressure on the eardrum, and taste may be altered due to the effect on the chorda tympani nerve. Infection may also spread from the tympanic cavity to the mastoid air cells, causing **mastoiditis**.

EAR OSSICLES Three small bones known as **malleus, incus,** and **stapes** transmit vibrations from the tympanic membrane to the inner ear (Figure 19-1A–D). The ossicles function as amplifiers to overcome the impedance mismatch at the air–fluid interface of the middle and inner ear.

- **Malleus.** Attached to the internal surface of the tympanic membrane and articulates with the incus (Figure 19-1B). The **tensor tympani muscle** attaches between the auditory tube and malleus and serves to reduce the movement of the tympanic membrane. It is innervated by **CN V-3**.
- **Incus.** Articulates with the malleus and stapes.
- **Stapes.** Attaches to the incus and vestibular window (separates the air environment of the middle ear from the fluid environment of the inner ear).
  - **Stapedius muscle.** The smallest skeletal muscle in the body; prevents excess movement of the stapes and controls the amplitude of sound waves from the external environment to the middle ear. The stapedius is innervated by CN VII.

Hyperacusis. A lesion of CN VII may cause paralysis of the stapedius muscle, resulting in wider oscillation of the stapes; consequentially, there is a heightened reaction of the auditory ossicles to sound vibration. This condition is known as hyperacusis and results in an increased sensitivity to loud sounds.

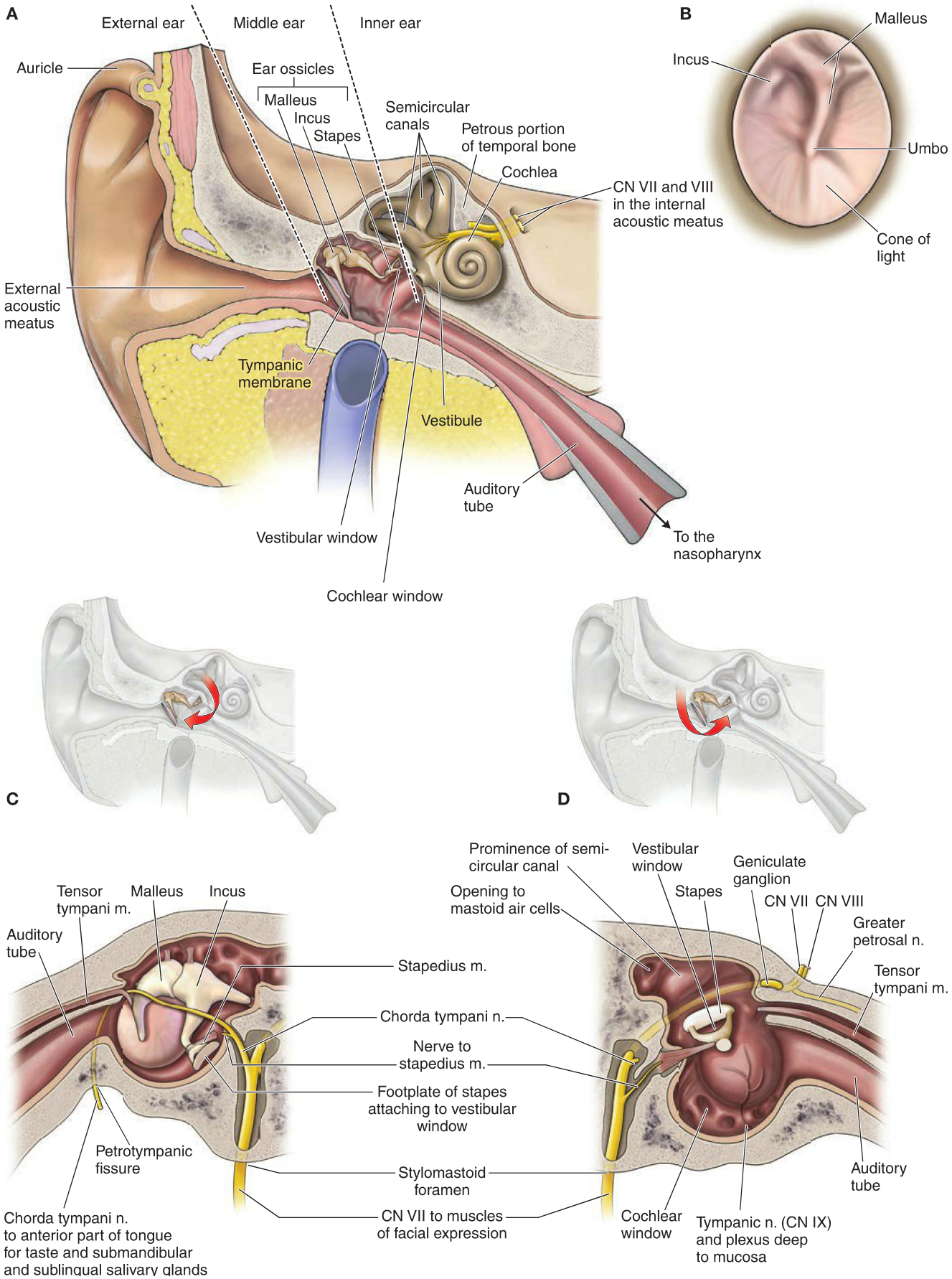

Figure 19-1: A. Coronal section of the temporal bone showing the hearing apparatus. **B**. Right tympanic membrane viewed through an otoscope. Lateral (**C**) and medial (**D**) wall of the middle ear.

BRANCHES OF THE FACIAL NERVE The facial nerve (CN VII) enters the internal acoustic meatus along with CN VIII. CN VII enters the facial canal and continues laterally between the internal and middle ear. It is at this point that the sensory **geniculate ganglion** forms a bulge in CN VII and gives rise to the following branches (Figure 19-1C and D):

- **Greater petrosal nerve.** Provides visceral motor innervation to the lacrimal, nasal, and palatal glands.
- **Nerve to the stapedius muscle (branchial motor).** Provides innervation to the stapedius muscle.
- **Chorda tympani nerve.** Arises before CN VII, courses through the middle layer of the tympanic membrane, continues between the malleus and stapes, and exits the skull at the petrotympanic fissure. The chorda tympani innervates the submandibular and sublingual salivary glands, and conveys taste sensation (special sensory) from the anterior two-thirds of the tongue.

INNER EAR

The inner ear contains the functional organs for hearing and equilibrium. The inner ear consists of a series of bony cavities (**bony labyrinth**), within which is a series of membranous ducts (**membranous labyrinth**), all within the **petrous part of the temporal bone**. The space between the bony and membranous labyrinths is filled with a fluid called **perilymph**. The tubular chambers of the membranous labyrinth are filled with **endolymph**. These two fluids provide a fluid-conducting medium for the vibrations involved in hearing and equilibrium.

BONY LABYRINTH The bony labyrinth is structurally and functionally divided into the vestibule, the semicircular canals, and the cochlea (Figure 19-2A).

Vestibule. The vestibule is the central portion of the bony labyrinth.

- **Vestibular window.** Serves as a membranous interface between the stapes from the middle ear and the vestibule of the inner ear.
- **Utricle and saccule.** The membranous labyrinth within the vestibule consists of two connected sacs called the utricle and saccule. Both the utricle and saccule contain receptors that are sensitive to gravity and linear movements of the head.
- **Semicircular canals.** The three bony semicircular canals of the inner ear are at right angles to each other. The narrow semicircular ducts of the membranous labyrinth are located within the semicircular canals. Receptors within the semicircular ducts are sensitive to angular acceleration and deceleration of the head, as occurs in rotational movement.

Cochlea. The cochlea is a coiled tube divided into three chambers (Figure 19-2B).

- **Scala vestibuli.** Forms the upper chamber of the cochlea; begins at the vestibular window, where the scala vestibuli is continuous with the vestibule, and contains perilymph.
- **Scala tympani.** Forms the lower chamber of the cochlea. The scala tympani terminates at the **cochlear window** and contains perilymph.
  - **Helicotrema.** The scala vestibuli and the scala tympani are separated completely, except at the narrow apex of the cochlea called the helicotrema, where they are continuous.
- **Cochlear duct (scala media).** Forms the middle chamber of the cochlea. The roof of the cochlear duct is called the **vestibular membrane**, and the floor is called the **basilar membrane**. The cochlear duct is filled with endolymph and ends at the helicotrema. The cochlear duct houses the **spiral organ (of Corti)**, where sound receptors transduce mechanical vibrations into nerve impulses.

VESTIBULOCOCHLEAR NERVE The vestibulocochlear nerve (CN VIII) courses through the internal acoustic meatus and divides into the vestibular and cochlear nerves (Figure 19-2A).

- **Vestibular nerve.** Special sensory innervation of the utricle and saccule of the semicircular canals (equilibrium and balance), with sensory cell bodies in the **vestibular ganglion**.
- **Cochlear nerve.** Special sensory innervation of the spiral organ (of Corti) in the cochlea (hearing), with sensory cell bodies in the **spiral ganglion**.

Hearing. Sound waves travel in all directions from their source, similar to ripples in water after a stone is dropped (Figure 19-2C). Sound waves are characterized by their pitch (high or low frequency) and intensity (loudness or quietness).

1. A sound wave enters the external acoustic meatus and strikes the tympanic membrane.
2. The sound wave transfers its energy into the vibration of the tympanic membrane.
3. As the tympanic membrane vibrates, it causes the malleus to move medially, which in turn causes the incus and stapes to move sequentially, amplifying the sound wave.
4. The stapes is attached to the vestibular window; thus, the vestibular window also moves, resulting in a wave forming in the perilymph within the scala vestibuli of the cochlea.
5. The fluid wave in the perilymph progresses from the scala vestibuli of the cochlea, resulting in an outward bulging of the cochlear window at the end of the scala tympani.
6. This bulging causes the basilar membrane in the cochlea to vibrate, which in turn results in stimulation of the receptor cells in the spiral organ (of Corti).
7. The receptor cells conduct impulses to the brain through the cochlear division of CN VIII, where the brain interprets the wave as sound.

The difference between a **sound wave** and **sound** can best be explained by the age-old question, "If a tree falls in a forest and no one is around to hear it, does it make a sound?"

Sound, as we interpret it, results from transduction and perception of amplitude, frequency, and complexity of a sound wave by the brain. The falling tree produces sound waves, but there is no perception of sound without the brain interpreting the sound wave. Therefore, a falling tree does not make a sound unless someone's auditory apparatus is there to hear it.

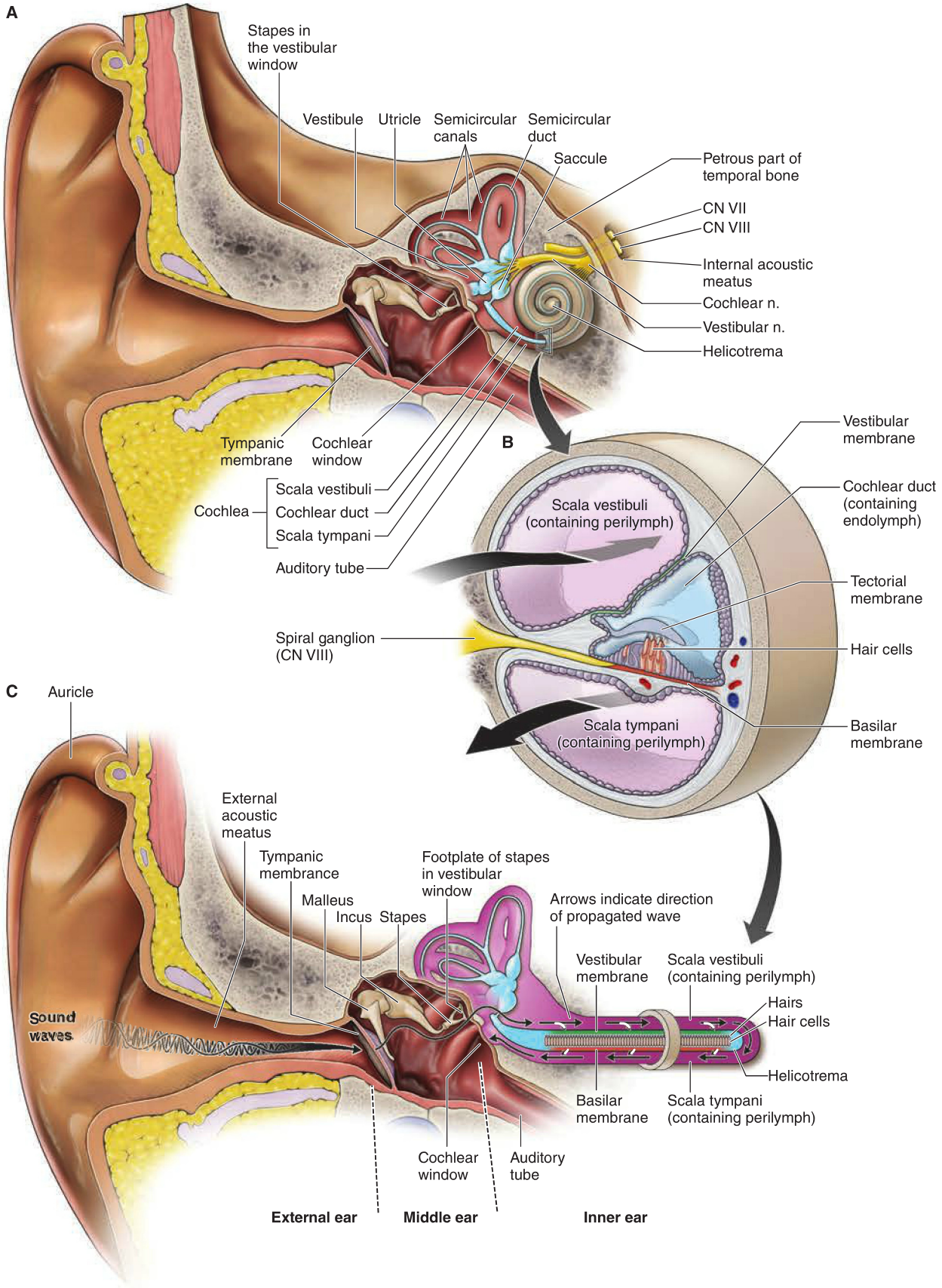

Figure 19-2: A. Coronal section of the internal ear. **B**. Cross-section of the cochlea. **C**. Pathway for the transmission of sound.

This page intentionally left blank

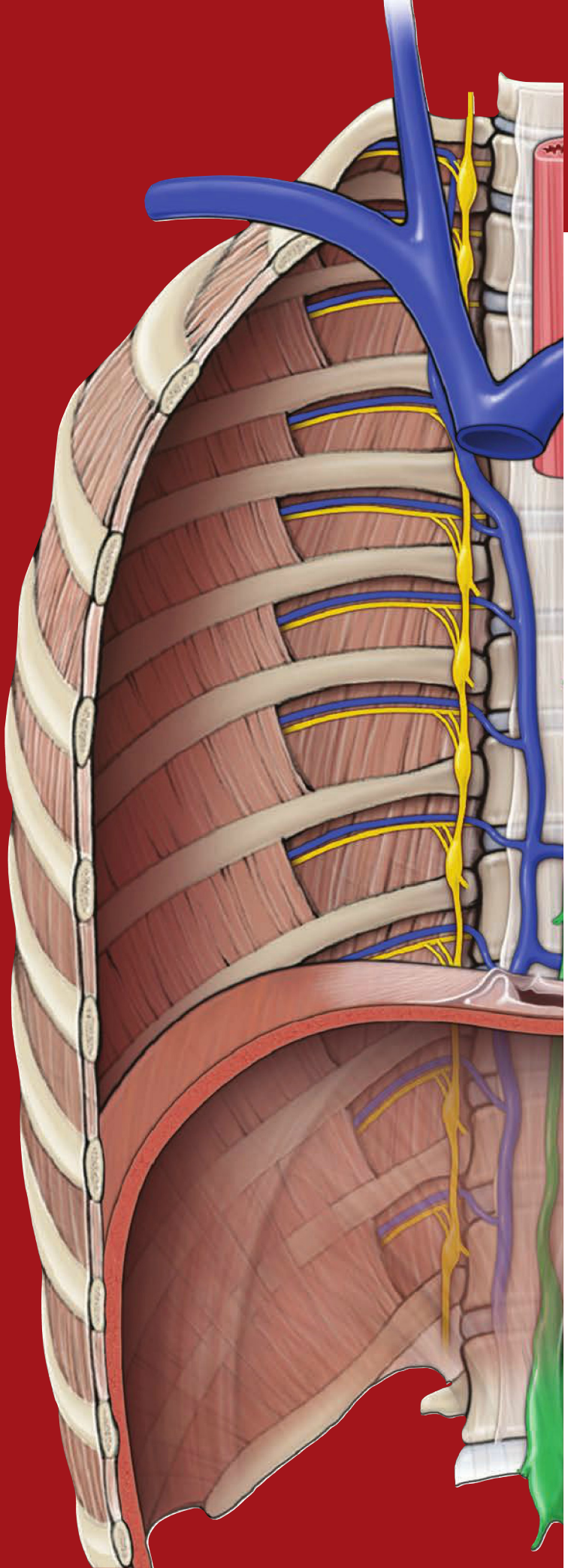

CHAPTER 20

SUPERFICIAL FACE

Cutaneous Innervation and Vasculature of the Face 226

Muscles and Innervation of the Face 228

CUTANEOUS INNERVATION AND VASCULATURE OF THE FACE

BIG PICTURE

The sensory innervation of the face is provided by the three divisions of the trigeminal nerve (cranial nerve [CN] V), with each division supplying the upper, middle, and lower third of the face. The facial artery and the superficial temporal artery provide vascular supply. The parotid gland resides on the masseter muscle, produces and secretes saliva into the oral cavity, and is innervated by the glossopharyngeal nerve (CN IX).

CUTANEOUS INNERVATION OF THE FACE

The skin of the face and scalp receives general sensory innervated from cutaneous branches of the three divisions of CN V and by some nerves from the cervical plexus (Figure 20-1A and B).

- **CN V-1 (ophthalmic nerve).** Anterior region of the scalp via the supraorbital and supratrochlear nerves, skin of the upper eyelid via the lacrimal nerve, and bridge of the nose via the external nasal and infratrochlear nerves.
- **CN V-2 (maxillary nerve).** Along the zygomatic arch, via the zygomaticofacial and zygomaticotemporal nerves, and the skin of the maxillary region, lower eyelid, and upper lip via infraorbital nerve branches.
- **CN V-3 (mandibular nerve).** Lateral aspect of the scalp and face, anterior to the external acoustic meatus via the auriculotemporal nerve, the skin covering the mandible via the buccal nerve, and the skin of the lower lip via the mental nerve.
- **Great auricular nerve (C2–C3) (cervical plexus).** Skin over the angle of the mandible just in front of the ear.

Trigeminal neuralgia (tic douloureux). A condition marked by paroxysmal pain within the cutaneous distribution of CN V. Sectioning the sensory root of CN V at the trigeminal ganglion may alleviate the pain.

VESSELS OF THE FACE

The face has a very rich blood supply provided primarily from the following vessels (Figure 20-1C):

- **Facial artery.** Arises from the external carotid artery and courses deep to the submandibular gland; winds around the inferior border of the mandible, anterior to the masseter muscle, and supplies the face via the inferior labial, superior labial, lateral nasal, and angular arteries.
- **Supraorbital** and **supratrochlear arteries.** Terminal branches of the ophthalmic artery, a branch of the internal carotid artery, which supply the anterior portion of the scalp.
- **Superficial temporal artery.** A terminal branch of the external carotid artery provides arterial supply to the lateral surface of the face and scalp.
- **Facial vein.** Formed by the union of the supraorbital and supratrochlear veins. The facial vein descends in the face and receives tributaries corresponding to the branches of the facial artery. The facial vein drains into the internal jugular vein.

Danger triangle. Unlike other systemic veins, the facial and superior ophthalmic veins lack valves. Therefore, the medial angle of the eye, nose, and lips form a triangular area of potential danger in the face. The blood in this region usually drains inferiorly via the facial vein. However, blood can also drain superiorly through the facial vein to the superior ophthalmic vein to the cavernous sinus. Therefore, an infection of the face may spread to the cavernous sinus resulting in a cavernous sinus thrombosis or meningitis. This is highly unlikely but possible.

PAROTID GLAND

The parotid gland is situated on the posterolateral surface of the masseter muscle. A dense fascia covers the gland (Figure 20-1C).

- **Function.** Produces and secretes saliva into the oral cavity, which helps moisten food and initiate chemical digestion of carbohydrates.
- **Parotid duct.** Courses from the parotid gland, across the masseter muscle, pierces the buccinator muscle, and opens into the oral cavity adjacent to the second maxillary molar.
- **Innervation.** Parasympathetic innervation from the glossopharyngeal nerve (CN IX):
  - **Preganglionic parasympathetic neurons** from CN IX originate in the inferior salivatory nucleus of the medulla and exit the jugular foramen (along with CNN X and XI).
  - A branch of CN IX, the tympanic nerve, reenters the skull via the tympanic canaliculus, enters the middle ear, and forms the **tympanic plexus**.
  - CN IX gives rise to the **lesser petrosal nerve**, which exits the middle ear and the skull via the foramen ovale to synapse in the otic ganglion.
  - **Postganglionic parasympathetic neurons** exit the **otic ganglion** and course within the auriculotemporal nerve en route to the parotid gland.

Mumps. Mumps is a viral infection characterized by inflammation and swelling of the parotid gland, resulting in pain within the tight parotid fascia that covers the gland. Symptoms include discomfort in swallowing and chewing. The disease will usually run its course, with analgesics given to treat the pain and fever that is associated with the infection.

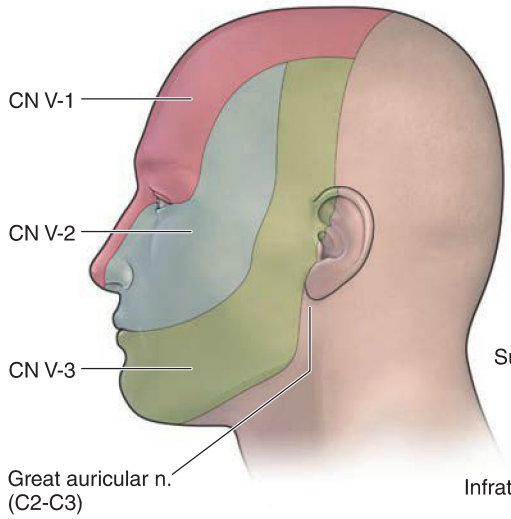

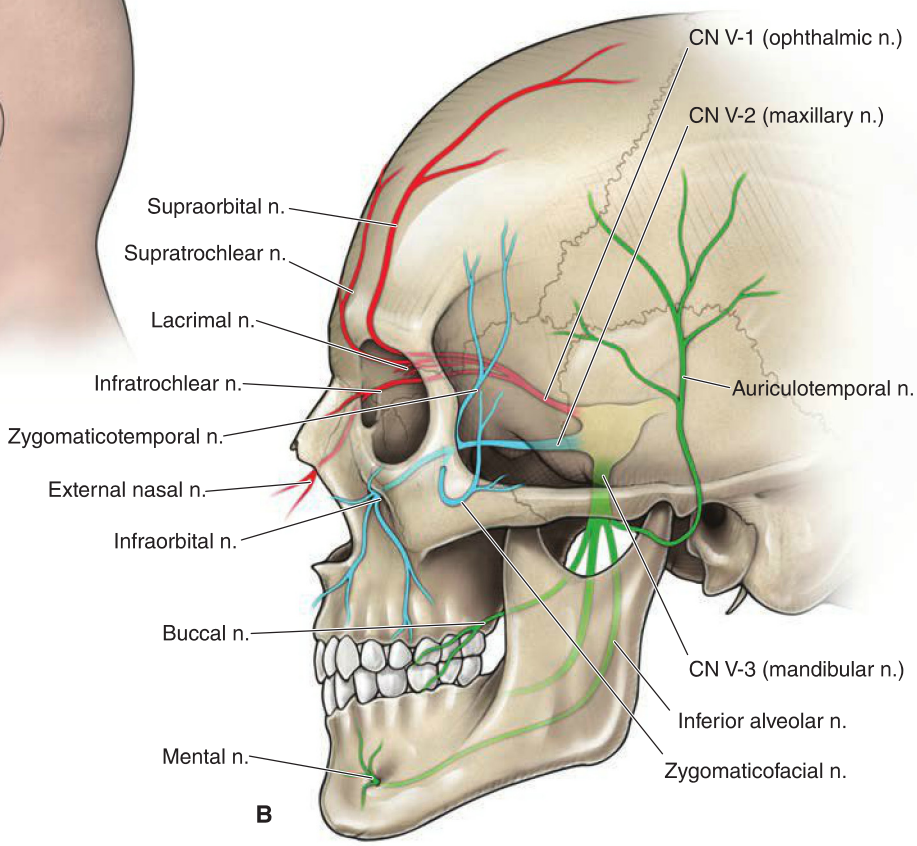

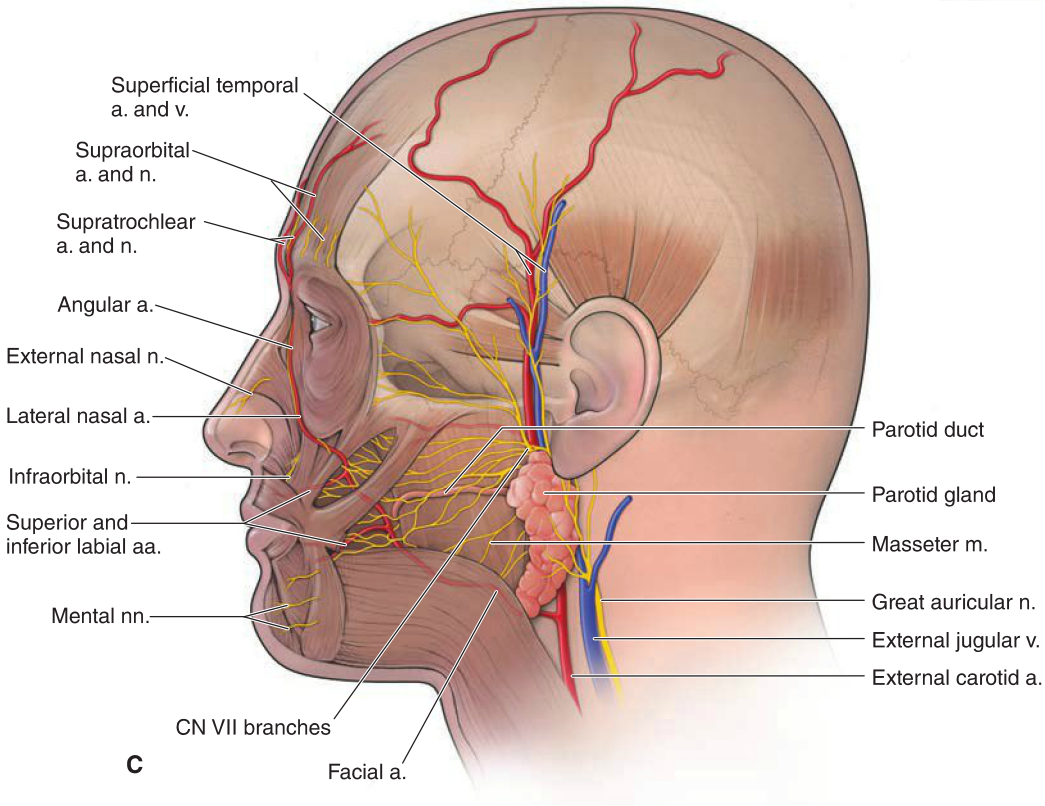

Figure 20-1: A. CN V and its cutaneous fields of the face. **B**. Branches of CN V in the face. **C**. Facial vessels and nerves and the parotid gland.

MUSCLES AND INNERVATION OF THE FACE

BIG PICTURE

Muscles of facial expression are located in the superficial fascia, control facial expression, and are innervated by the facial nerve proper (CN VII).

MUSCLES OF FACIAL EXPRESSION

The muscles of facial expression are voluntary muscles that arise from bones or fascia of the skull and insert into the skin, which enables a wide array of facial expression. These muscles develop embryologically from a continuous sheet of musculature derived from the second branchial arch and therefore innervated by CN VII.

The muscles of facial expression are be organized into the following groups (Figure 20-2A):

- **Scalp and forehead** (see Chapter 15)
  - **Frontalis.** Connects with the **occipitalis muscle** by a cranial aponeurosis (**galea aponeurotica**); wrinkles the forehead.
- **Muscles of the orbit**
  - **Orbicularis oculi.** A sphincter muscle that closes the eyelids.
  - **Corrugator supercilii.** Located deep to the orbicularis oculi; draws the eyebrows medially.
- **Muscles of the nose**
  - **Procerus.** Wrinkles the skin over the root of the nose.
  - **Nasalis** and **levator labii superioris alaquae nasi.** Flare the nostrils.
- **Muscles of the mouth**
  - **Orbicularis oris.** A sphincter muscle that closes the mouth.
  - **Levator labii superioris** and **levator anguli oris**. Raise the upper lip.
  - **Zygomaticus major** and **minor**. Raise the corners of the mouth (smile).
  - **Risorius.** Draws the corners of the lips laterally.
  - **Depressor labii inferioris** and **depressor anguli oris**. Lower the bottom lip.
  - **Buccinator.** Compresses the cheek when whistling, blowing, or sucking; holds food between the teeth during chewing.
- **Neck**
  - **Platysma.** Tenses the skin of the neck.

Corneal (blink) reflex. This reflex is tested by touching the cornea with a piece of cotton, which results in bilateral contraction of the orbicularis occuli muscles (blinking). The afferent limb is the nasociliary nerve of CN V-1, the CNS processing level is the pons, and the efferent limb of the reflex is the facial nerve proper (CN VII).

INNERVATION OF FACIAL MUSCLES

The facial nerve proper (CN VII) provides motor innervation to the muscles of facial expression (Figure 20-2B). The facial nerve proper:

- Enters the internal acoustic meatus and descends through the facial canal.
- Exits the skull through the stylomastoid foramen and immediately gives off the posterior auricular nerve and other branches that supply the occipitalis, stylohyoid, and posterior digastricus muscles and the posterior auricular muscle.
- Enters the parotid gland, and divides into the following five terminal branches: **temporal, zygomatic, buccal, mandibular**, and **cervical nerves**, which in turn supply the muscles of facial expression.

Other muscles of the face include muscles of mastication (temporalis, masseter, and the medial pterygoid and lateral pterygoid muscles), which are innervated by the motor division of CN V-3.

Bell's (facial) palsy. One problem of the facial nerve proper occurs in the facial canal, proximal to the stylomastoid foramen. Here, an inflammatory disease of unknown etiology causes a condition known as Bell's palsy, where all of the facial muscles on one side of the face are paralyzed. Bell's palsy is characterized by facial drooping on the affected side, typified by the inability to close the eye, a sagging lower eyelid, and tearing. In addition, the patient has difficulty smiling, and saliva may dribble from the corner of the mouth. If the inflammation spreads, the chorda tympani and nerve to the stapedius muscle may be involved.

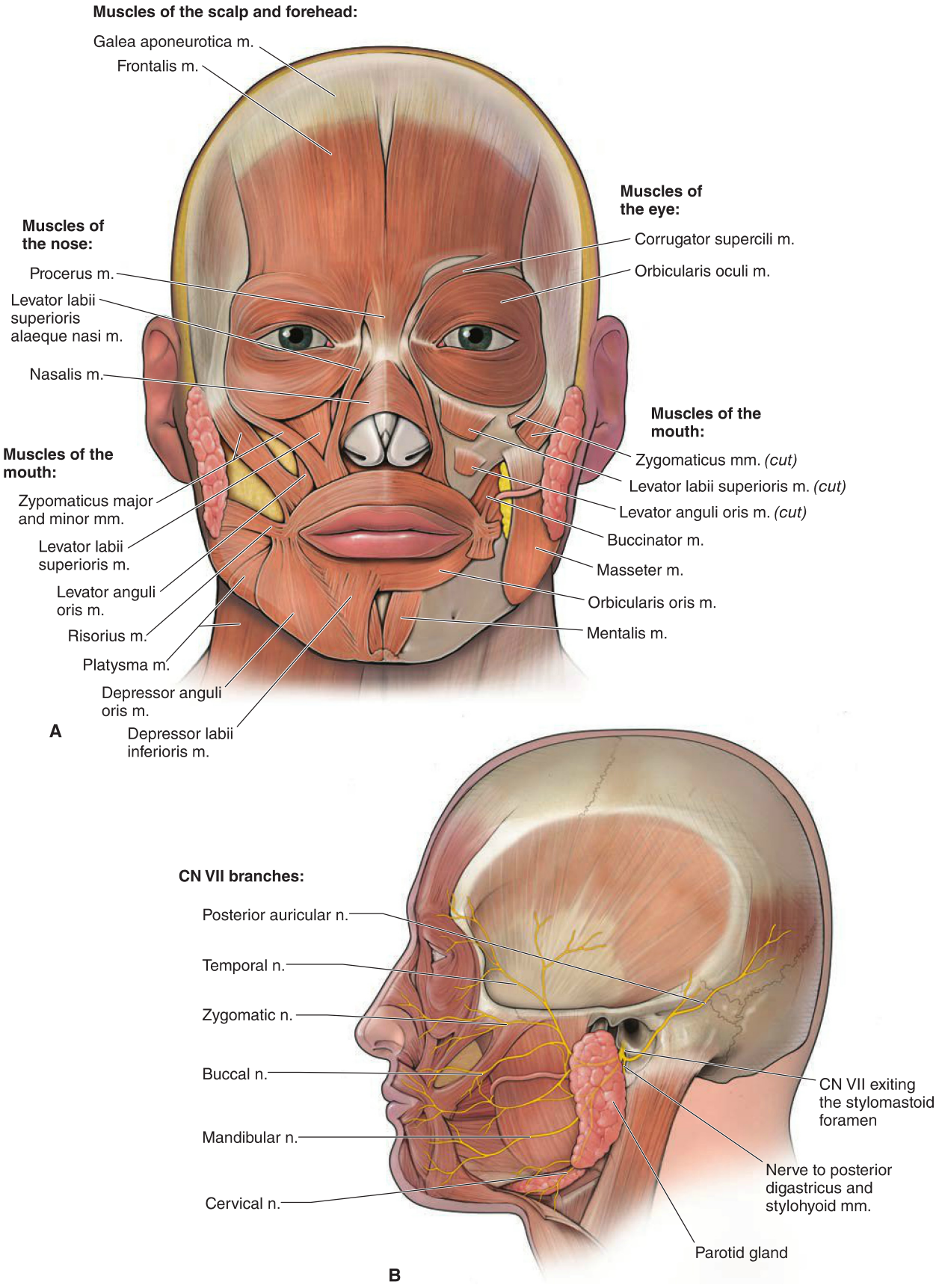

Figure 20-2: A. Muscles of facial expression. **B**. Branches of the facial nerve (CN VII) to facial muscles.

This page intentionally left blank

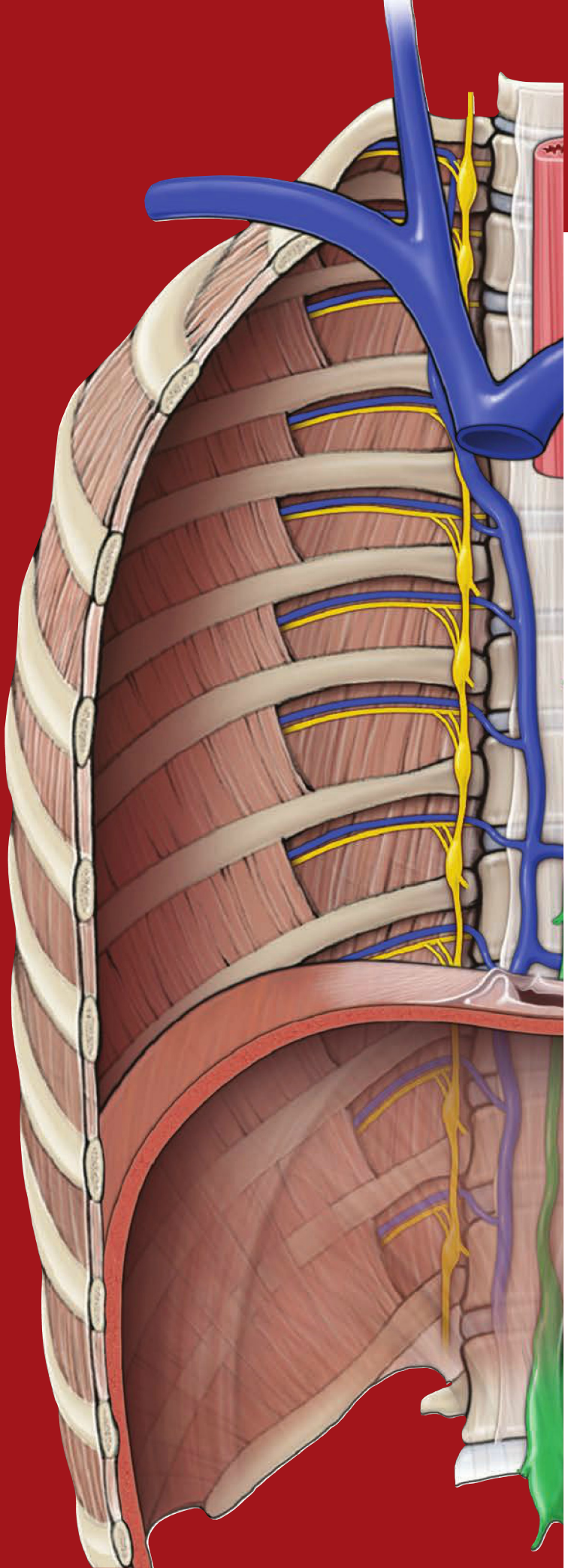

CHAPTER 21

INFRATEMPORAL FOSSA

Overview of the Infratemporal Fossa 232

Innervation and Vascular Supply of the Infratemporal Fossa 234

OVERVIEW OF THE INFRATEMPORAL FOSSA

BIG PICTURE

The infratemporal fossa is an anatomical region deep to the ramus of the mandible that accommodates some muscles of mastication (temporalis, medial, and lateral pterygoid), nerves (mandibular nerve, otic ganglion, and chorda tympani nerve), and vessels (maxillary artery and pterygoid plexus of the veins).

BOUNDARIES

The infratemporal fossa has the following boundaries (Figure 21-1A):

- Anterior to the mastoid and styloid processes of the temporal bone.
- Posterior to the maxilla.
- Medial to the ramus of the mandible.
- Lateral to the pterygoid plate and the pterygomaxillary fissure (a communication between the infratemporal fossa and the pterygopalatine fossa).

TEMPOROMANDIBULAR JOINT

The articulations between the **temporal bone (mandibular fossa)** and the **mandibular condyle** form a **synovial joint**, known as the temporomandibular joint (**TMJ**).

- **TMJ movements.** The left and right TMJs work together, enabling the mandible to move as follows:
  - **Elevation (up).** Generated by the temporalis, masseter, and medial pterygoid muscles.
  - **Depression (down).** Generated by the digastricus, geniohyoid, and mylohyoid muscles, and assisted by gravity.
  - **Protraction.** Generated primarily through the lateral pterygoid muscle. Involves the anterior movement of the mandibular condyle and the articular disc.
  - **Retraction.** Generated by the geniohyoid, digastricus, and temporalis muscles.
  - **Side to side.** Generated by the pterygoid muscles.
- **TMJ structure.** A unique feature of the TMJ is the fibrocartilaginous **articular disc**, located within the joint capsule between the mandibular fossa and condyle. The disc divides the joint capsule into two distinct compartments.
  - **Inferior compartment.** Enables the hinge-like rotation of the mandibular condyle, corresponding to the first 2 cm of opening the mouth (depression) (Figure 21-1B).
  - **Superior compartment.** For the mouth to be opened more than 2 cm, the superior compartment within the joint capsule enables both the mandibular condyle and the articular disc to slide anteriorly (protrusion), incorporating a translational movement anteriorly when opening the mouth wider (Figure 21-1C).

TMJ disorder. TMJ disorder is associated with painful and limited movement of the jaw. The disorder is poorly understood because of the complexity of the TMJ, which incorporates hinge-like movements along with movements that slide anteriorly and from side to side. Symptoms of TMJ disorder include pain and tenderness in and around the jaw, difficulty and painful chewing, headache, and clicking sounds when the jaw opens and closes. TMJ disorder can occur when the articular disc is damaged, eroded, or slipped out of alignment.

- **Muscle movement of the TMJ.** The muscles acting upon the TMJ are primarily the muscles that generate the various movements associated with chewing; hence, these muscles are often called the **muscles of mastication** (Table 21-1). The branchial motor division of **CN V-3** innervates each of the following muscles (Figure 21-1D and E):
  - **Temporalis muscle.** Originates in the temporal fossa and courses deep to the zygomatic arch, inserting on the coronoid process of the mandible; elevates the mandible.
  - **Masseter muscle.** Attaches between the zygomatic arch and external surface of the ramus of the mandible. It elevates the mandible. The masseter muscle is not located in the infratemporal fossa; however, it is a muscle of mastication and elevates the mandible.
  - **Lateral pterygoid muscle.** Attaches between the lateral pterygoid plate and the mandibular condyle. Contraction causes the mandibular condyle and the articular disc to move anteriorly, resulting in both protraction and depression of the mandible; works synergistically with the medial pterygoid muscle to move the mandible from side to side.
  - **Medial pterygoid muscle.** Attaches between the medial and lateral pterygoid plates and the internal surface of the ramus of the mandible; elevates the mandible and moves it from side to side.

Clinically testing CN V-3. During a physical examination, the physician palpates the muscles of mastication to test the function of CN V-3. The physician will instruct the patient to clench his jaw as the temporalis and masseter muscles are palpated to determine if there is equal bilateral contraction in each muscle. The patient is then instructed to open and close his mouth against resistance. If there is muscle weakness of the medial or lateral pterygoid muscles, the jaw will deviate toward the weak side.

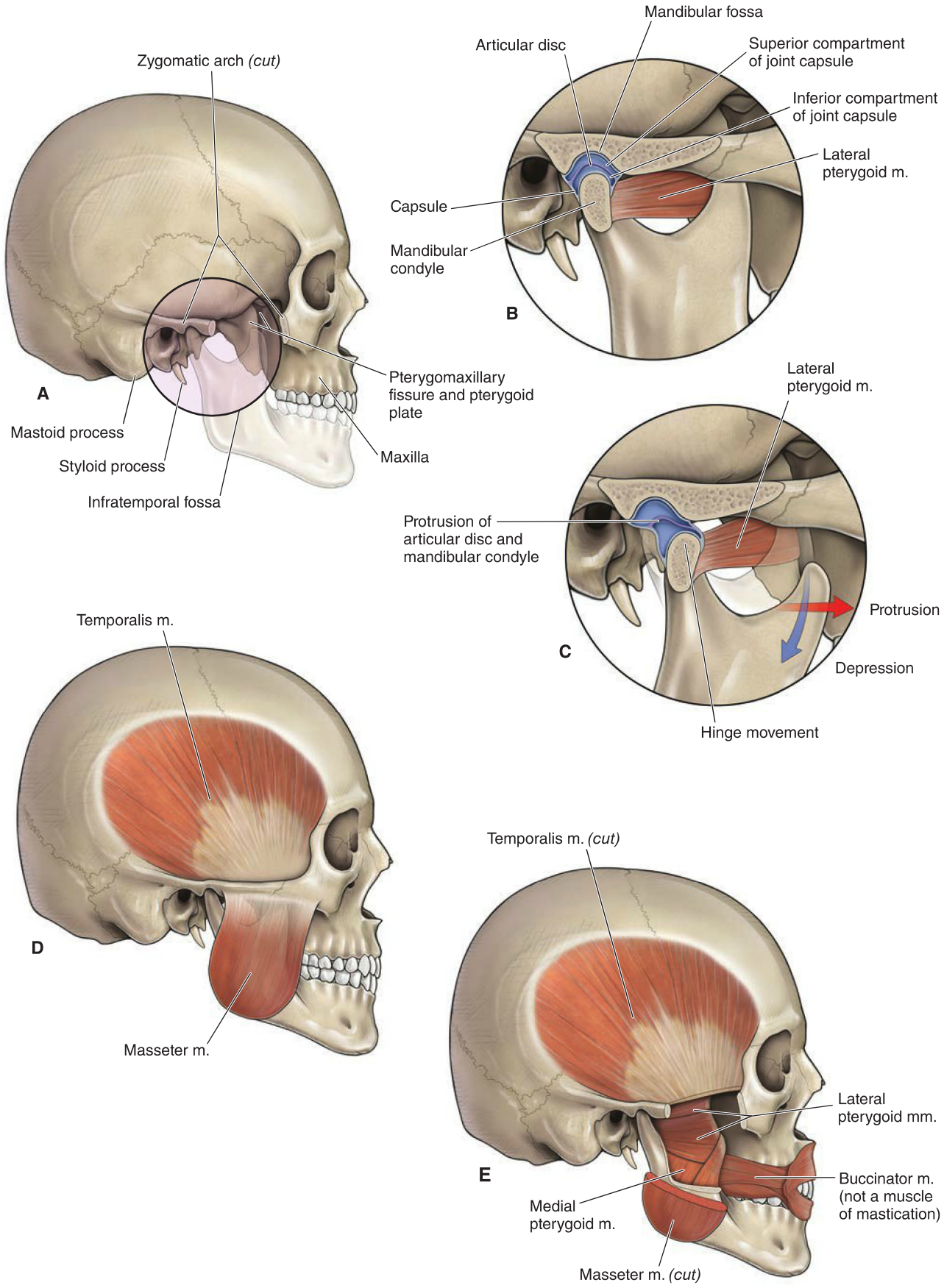

Figure 21-1: A. Boundaries of the infratemporal fossa. **B**. Compartments of the temporomandibular joint (TMJ). **C**. Opening of the TMJ. Superficial (**D**) and deep (**E**) views of muscles of mastication.

INNERVATION AND VASCULAR SUPPLY OF THE INFRATEMPORAL FOSSA

BIG PICTURE

The trigeminal nerve (CN V) provides most of the general sensory innervation to the head. Branches of the ophthalmic nerve (CN V-1) and the maxillary nerve (CN V-2) provide only general sensory innervation. In contrast, CN V-3 enters the infratemporal fossa and has both a general sensory and a branchial motor root. Branches of the maxillary artery provide the vascular supply to the infratemporal fossa.

NERVES OF THE INFRATEMPORAL FOSSA

The sensory and motor roots of CN V-3 fuse together as a trunk and descend into the infratemporal fossa via the foramen ovale (Figure 21-2A). Once in the infratemporal fossa, CN V-3 bifurcates into anterior and posterior divisions.

- **Trunk.** Provides branchial motor innervation to the medial pterygoid, tensor veli palatine, and tensor tympani muscles.
- **Anterior division**
  - **Motor branches.** Provides branchial motor innervation to the temporalis, masseter, and lateral pterygoid muscles.
  - **Buccal nerve.** Provides general sensory innervation from the skin of the cheek, passing between the two heads of the lateral pterygoid muscle. The buccal nerve is also referred to as the long buccal nerve to distinguish it from the buccal branch of CN VII.
- **Posterior division**
  - **Auriculotemporal nerve.** Splits around the middle meningeal artery to provide general sensory innervation to the temporal region of the face and scalp.
  - **Otic ganglion.** Preganglionic parasympathetic neurons from CN IX exit the middle ear as the lesser petrosal nerve and enter the infratemporal fossa through the foramen ovale and synapse in the otic ganglion. Postganglionic parasympathetic neurons "hitch-hike" along with the auriculotemporal nerve and innervate the parotid gland.
- **Inferior alveolar nerve.** Enters the mandibular foramen and provides general sensory innervation from the mandibular teeth, gingivae, lower lip, and chin.
- **Lingual nerve.** Provides general sensory innervation from the anterior two-thirds of the tongue (Figure 21-2A and B).
  - **Chorda tympani nerve (CN VII).** Enters the infratemporal fossa via the petrotympanic fissure, where it joins with the lingual nerve. The chorda tympani nerve provides special sensory taste from the anterior two-thirds of the tongue, as well as visceral motor parasympathetic innervation to the submandibular and sublingual salivary glands.
  - **Submandibular ganglion.** Suspended from the lingual nerve, where preganglionic and postganglionic parasympathetic neurons from the chorda tympani nerve (CN VII) synapse en route to innervating the submandibular and sublingual salivary glands.
- **Nerve to the mylohyoid.** Provides branchial motor innervation to the mylohyoid and anterior digastricus muscles.

VASCULAR SUPPLY OF THE INTRATEMPORAL FOSSA

The external carotid artery terminates as the maxillary artery and superficial temporal arteries, posterior to the neck of the mandible (Figure 21-2C).

- **Maxillary artery.** Arises from the external carotid artery and divides into three parts: (1) mandibular part (before the lateral ptyergoid muscle), (2) pterygoid part (superficial or deep to the lateral pterygoid muscle), and (3) pterygopalatine part (traverses the pterygomaxillary fissure into the pterygopalatine fossa). Although the maxillary artery gives off numerous branches, two primary arteries are as follows:
  - **Middle meningeal artery.** Ascends through the foramen spinosum, coursing between the roots of the auriculotemporal nerve; provides the principal blood supply to intracranial dura mater.
  - **Inferior alveolar artery.** Accompanies the inferior alveolar nerve into the mandibular foramen.
- **Pterygoid plexus of veins.** Situated between the pterygoid muscles; communicates with veins in the orbit, cavernous sinus, and facial region.

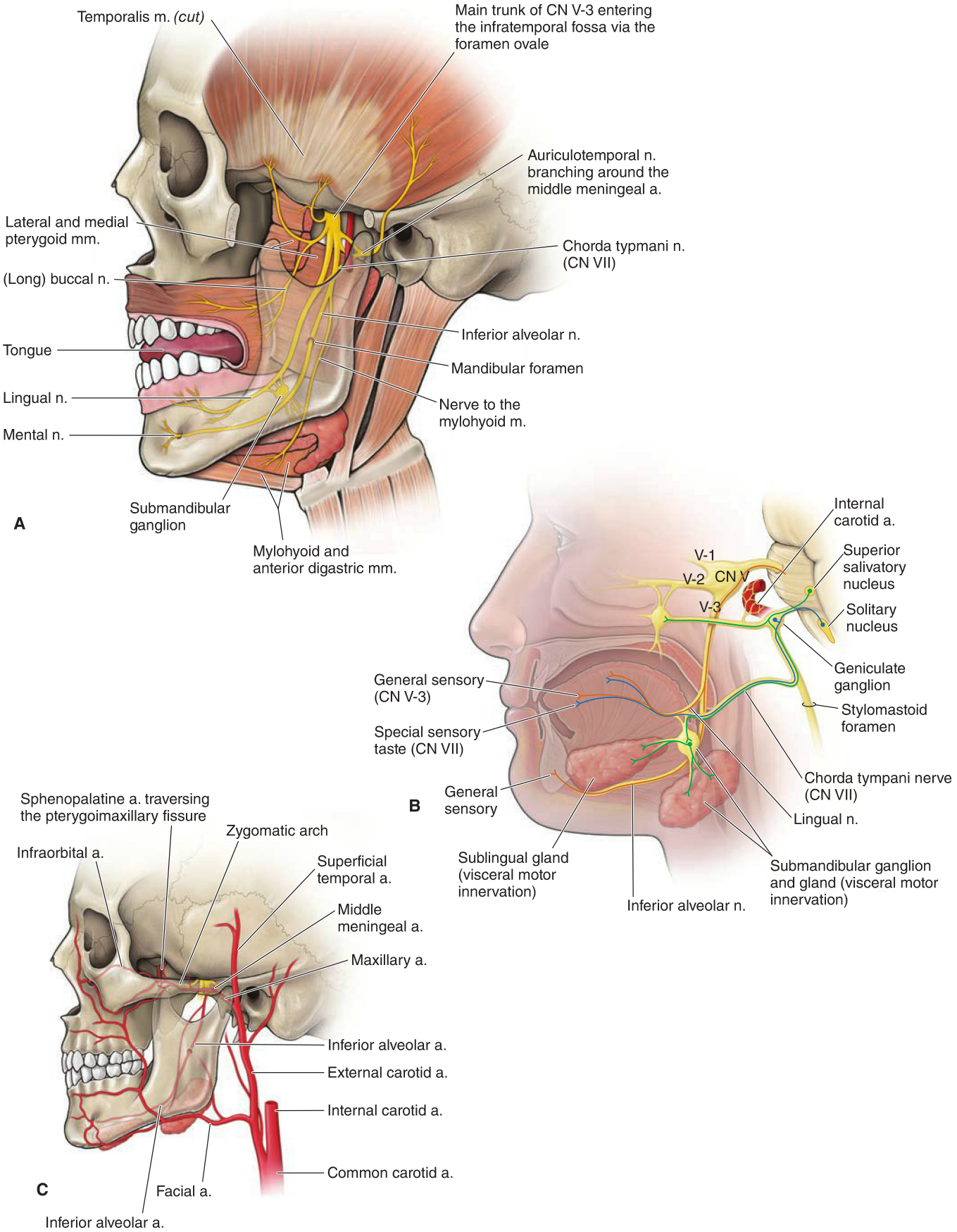

Figure 21-2: A. Nerves of the infratemporal fossa. **B**. Parasympathetic and special sensory pathways of the infratemporal fossa. **C**. Arteries of the infratemporal fossa.

TABLE 21-1. Muscles of Mastication

Muscle	Origin	Insertion	Action	Innervation
• **Temporalis**	Temporal fossa, temporal and parietal bones	Coronoid process of mandible	Elevates and retracts mandible	
• **Masseter**	Zygomatic arch	Ramus of mandible (external surface)	Elevates mandible	
• **Lateral pterygoid**	Lateral pterygoid plate	Coronoid process of mandible	Protracts and laterally moves mandible	
• **Medial pterygoid**	Medial and lateral pterygoid plate	Ramus of mandible (internal surface)	Elevates and laterally moves mandible	CN V-3 (mandibular n.)
Anterior digastricus	Hyoid bone	Mandible	Depresses mandible	
Mylohyoid	Mandible	Hyoid bone	Depresses mandible	
Tensor veli palatini	Sphenoid bone	Soft palate	Tenses soft palate	
Tensor tympani	Auditory tube	Auditory tube	Dampens ossicles during chewing	

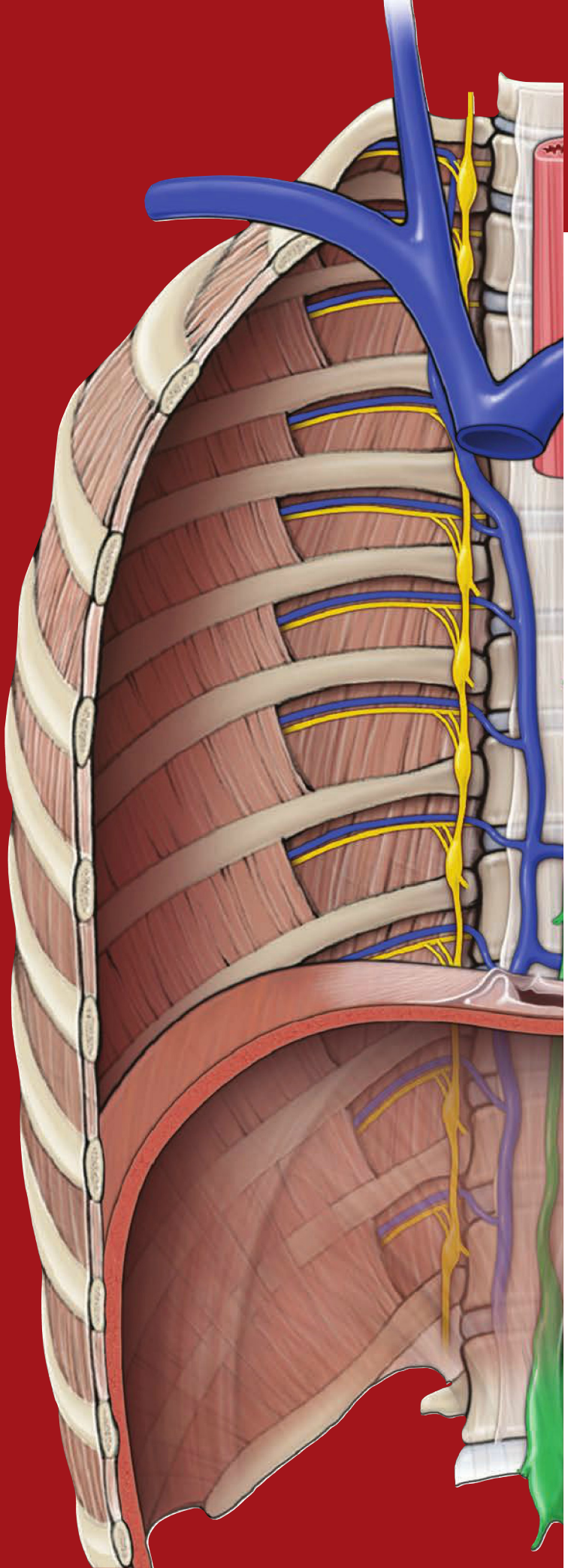

CHAPTER 22

PTERYGOPALATINE FOSSA

Overview of the Pterygopalatine Fossa 238

OVERVIEW OF THE PTERYGOPALATINE FOSSA

BIG PICTURE

The pterygopalatine fossa is the region between the pterygomaxillary fissure and the nasal cavity. The fossa accommodates branches of the maxillary nerve (CN V-2), the pterygopalatine ganglion, and the terminal branches of the maxillary artery.

BOUNDARIES OF THE PTERYGOPALATINE FOSSA

The pterygopalatine fossa is an irregular space where neurovascular structures course through to the nasal cavity, palate, pharynx, orbit, and face (Figure 22-1A and B). The neurovascular structures enter and exit the fossa through the following boundaries:

- **Anterior boundary.** Posterior surface of the maxilla.
- **Posterior boundary.** Pterygoid processes and the greater wing of the sphenoid bone, with openings for the following structures:
  - **Foramen rotundum.** For the maxillary nerve (CN V-2).
  - **Pterygoid canal.** For the nerve of the pterygoid canal (Vidian nerve).
  - **Pharyngeal (palatovaginal) canal.** For the pharyngeal branch of CN V-2.
- **Medial boundary.** Perpendicular plate of the palatine bone containing the **sphenopalatine foramen**, which transmits the nasopalatine nerve (CN V-2 branch) and the sphenopalatine artery.
- **Lateral boundary. Pterygomaxillary fissure**, which communicates with the infratemporal fossa.
- **Superior boundary.** Greater wing and body of the sphenoid bone, **with the infraorbital fissure** transmitting the infraorbital nerve and the vessels in the orbit.
- **Inferior boundary.** Palatine process of the maxilla and the pterygoid process of the sphenoid bone **with the greater and lesser palatine canals and foramina**, which transmit the greater and lesser palatine nerves and vessels.

NERVES OF THE PTERYGOPALATINE FOSSA

Branches of CN V-2 form most of the nerves that enter and exit the pterygopalatine fossa (Figure 22-1C and D). CN V-2 enters the fossa via the foramen rotundum and branches as follows:

- **Posterior superior alveolar nerves.** Enters the posterior superior alveolar canals, providing general sensation to the maxillary molar teeth and gingivae.
- **Infraorbital nerve.** Courses through the infraorbital fissure, groove, canal, and ultimately the foramen providing general sensation to the inferior eyelid, the lateral nose, and the superior lip. The infraorbital nerve also gives rise to the **middle** and **anterior superior alveolar nerves**, which supply the maxillary premolars, canines, and incisors, and the gingivae and maxillary sinus.
- **Zygomatic nerve.** Enters the orbit via the infraorbital fissure, dividing into the **zygomaticotemporal** and **zygomaticofacial nerves**, which supply the skin over the zygomatic arch and the temporal region. In addition, the zygomatic nerve communicates with the lacrimal nerve in the orbit and carries parasympathetic neurons from the pterygopalatine ganglion to the lacrimal gland.
- **Pharyngeal nerve.** Courses through the pharyngeal canal, supplying part of the nasopharynx.
- **Greater and lesser palatine nerves.** Descend through the palatal canals, emerging through the greater and lesser palatine foramina to innervate the hard and soft palates.
- **Nasopalatine nerve.** Traverses the sphenopalatine foramen, supplying the nasal septum before coursing through the incisive canal to supply part of the hard palate.
- **Pterygopalatine ganglion.** Lies inferior to CN V-2 and receives preganglionic parasympathetic neurons from the greater petrosal nerve (CN VII) and traverses the pterygoid canal. The pterygopalatine ganglion sends postganglionic parasympathetic neurons to the **lacrimal gland**, via communicating branches between the zygomatic nerve and the lacrimal nerve (CN V-1), and the **nasal and palatal glands**, via the nasopalatine, greater palatine, and lesser palatine nerves (CN V-2).
  - **Sympathetics.** Postganglionic sympathetic neurons from the superior cervical ganglion course along the internal carotid artery and give rise to the **deep petrosal nerve**. The deep petrosal nerve joins with the greater petrosal nerve (CN VII) at the foramen lacerum to become the **nerve of the pterygoid canal** (Vidian nerve). The postganglionic sympathetic neurons course through but do not synapse in the pterygopalatine ganglion and inhibit lacrimal and nasal gland secretion.

ARTERIES OF THE PTERYGOPALATINE FOSSA

The maxillary artery is a terminal branch of the external carotid artery, courses anteriorly through the infratemporal fossa, traverses the pterygomaxillary fissure, and enters the pterygopalatine fossa (Figure 22-1E and F). The maxillary artery supplies the maxilla, maxillary teeth, and palate before traversing the sphenopalatine foramen to terminate in the nasal cavity. The major branches of the maxillary artery in the pterygopalatine fossa are as follows:

- **Posterior superior alveolar artery.** Supplies the maxillary molar teeth.
- **Descending palatine artery.** Gives rise to the greater and lesser palatine arteries, which supply the soft and hard palates.
- **Infraorbital artery.** Supplies the maxillary tooth and skin of the face.
- **Sphenopalatine artery.** Traverses the sphenopalatine foramen to supply the nasal cavity.

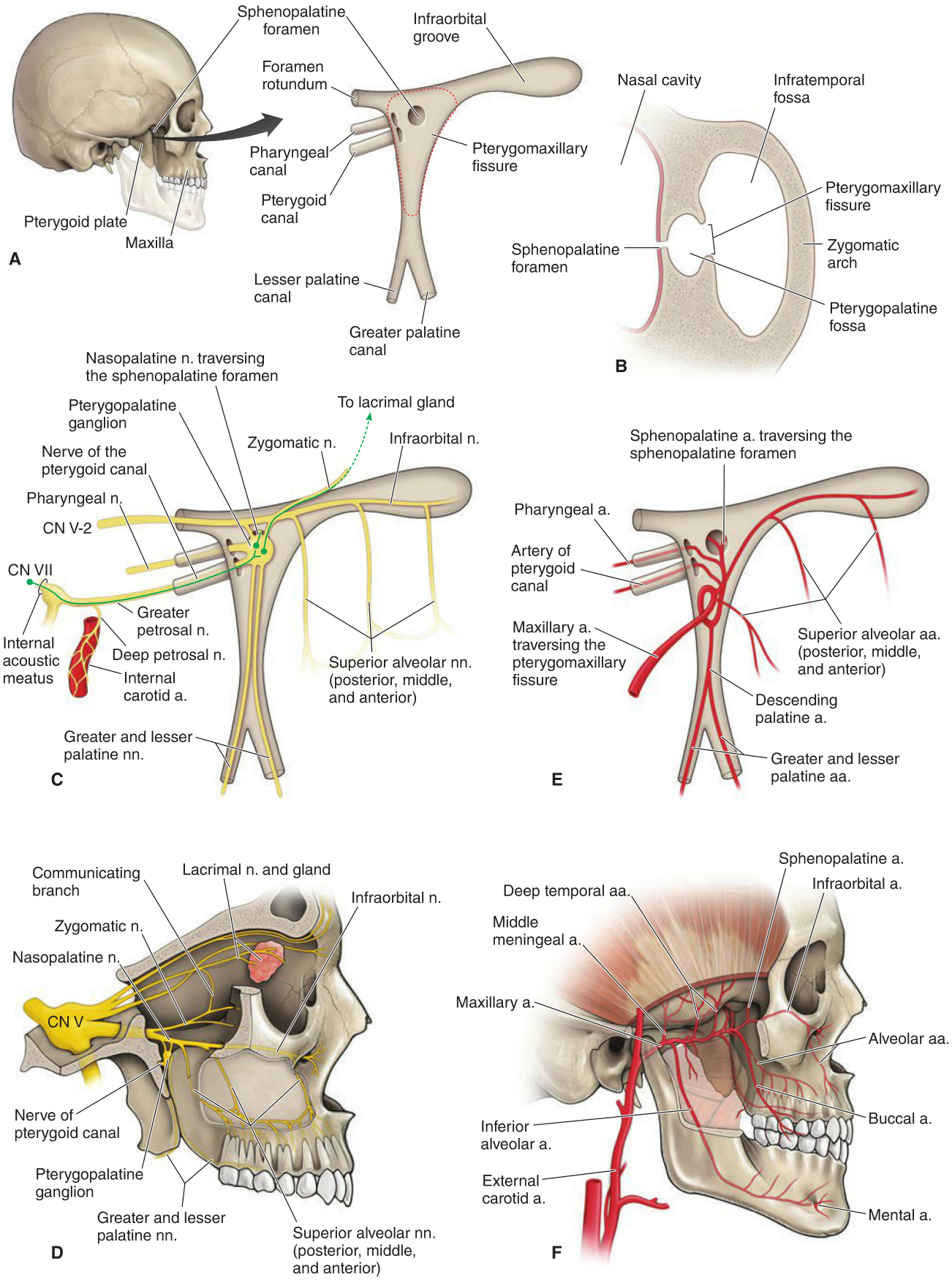

Figure 22-1: A. Outline of the pterygopalatine fossa. **B**. Axial section of the pterygopalatine fossa. **C.** and **D**. Nerves of the pterygopalatine fossa. **E.** and **F**. Arteries of the pterygopalatine fossa.

This page intentionally left blank

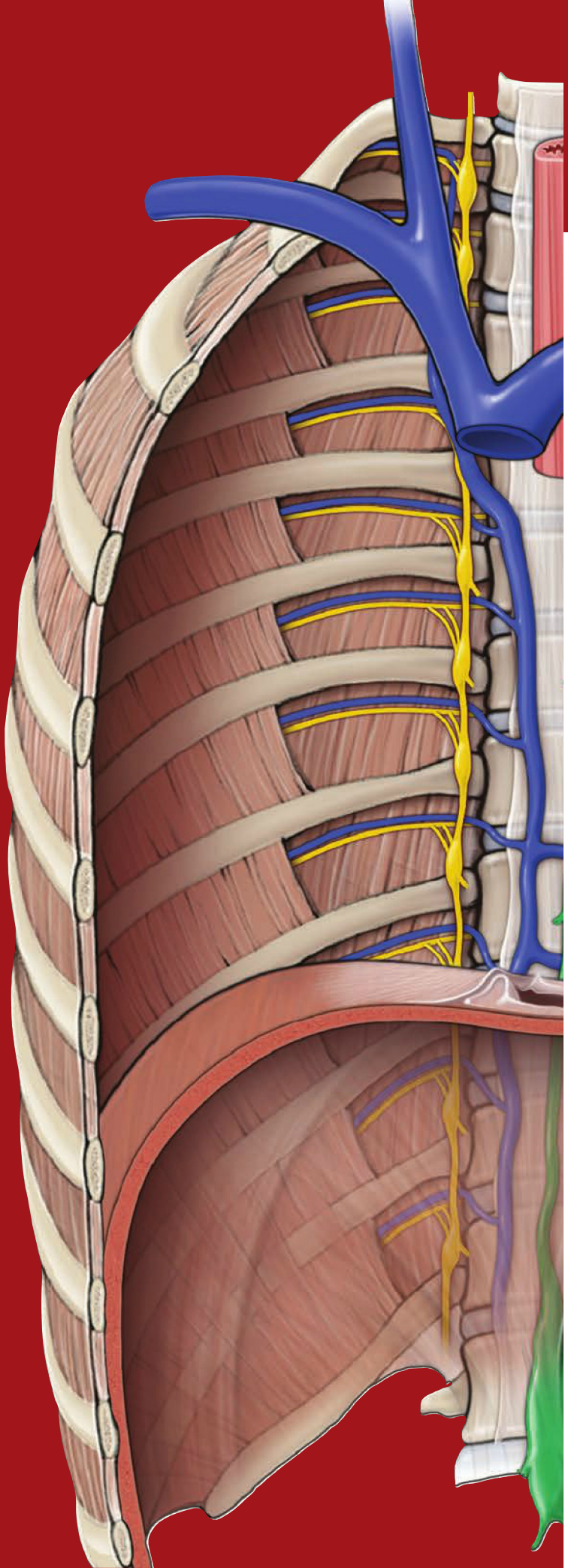

CHAPTER 23

NASAL CAVITY

Overview of the Nasal Cavity 242
Paranasal Sinuses 246

OVERVIEW OF THE NASAL CAVITY

BIG PICTURE

The nasal cavity is divided into two lateral compartments separated down the middle by the nasal septum. The nasal cavity communicates anteriorly through the nostrils and posteriorly with the nasopharynx through openings called choanae. The nasal cavities and septum are lined with a mucous membrane and are richly vascularized by branches of the maxillary, facial, and ophthalmic arteries. The nasal cavity receives innervation from CNN I, V-1, and V-2, and CN VII.

BOUNDARIES OF THE NASAL CAVITY

The nasal cavity is bordered by the following structures (Figure 23-1A–C):

- **Roof.** Formed by the nasal, frontal, sphenoid, and ethmoid bones (**cribriform foramina**, which transmits CN I for smell).
- **Floor.** Formed by the maxilla and the palatine bones. The **incisive foramen** transmits branches of the sphenopalatine artery and the nasopalatine nerve for general sensation from the nasal cavity and palate.
- **Medial wall (nasal septum).** Formed by the perpendicular plate of the ethmoid bone, the vomer bone, and the septal cartilage.
- **Lateral wall.** Formed by the superior, middle, and inferior nasal conchae. In addition, the maxillary, sphenoid, and palatine bones contribute to the lateral wall. The lateral wall contains the following openings:
  - **Sphenoethmoidal recess.** The space between the superior nasal concha and the sphenoid bone, with openings from the sphenoid sinus.
  - **Superior meatus.** The space inferior to the superior nasal concha, with openings from the posterior ethmoidal air cells.
  - **Middle meatus.** The space inferior to the middle nasal concha, with openings for the frontal sinus via the **nasofrontal duct**, the middle ethmoidal air cells on the **ethmoidal bulla**, and the anterior ethmoidal air cells and maxillary sinus in the **hiatus semilunaris**.
  - **Inferior meatus.** The space inferior to the inferior nasal concha, with an opening for the **nasolacrimal duct**, which drains tears from the eye into the nasal cavity.
  - **Sphenopalatine foramen.** An opening posterior to the middle nasal concha receives the nasopalatine nerve and the sphenopalatine artery from the **pterygopalatine fossa** into the nasal cavity.

Rhinorrhea. Rhinorrhea ("runny nose") is evident by clear fluid that leaks out of the nostrils. A runny nose results from an overproduction of mucus due to conditions such as the common cold, sinusitis, and allergies. However, rhinorrhea that occurs after an accident involving head trauma may indicate a basilar skull fracture, resulting in leakage of cerebrospinal fluid from the subarachnoid space through the fracture (often the ethmoid bone) into the nasal cavity and out of the nostrils.

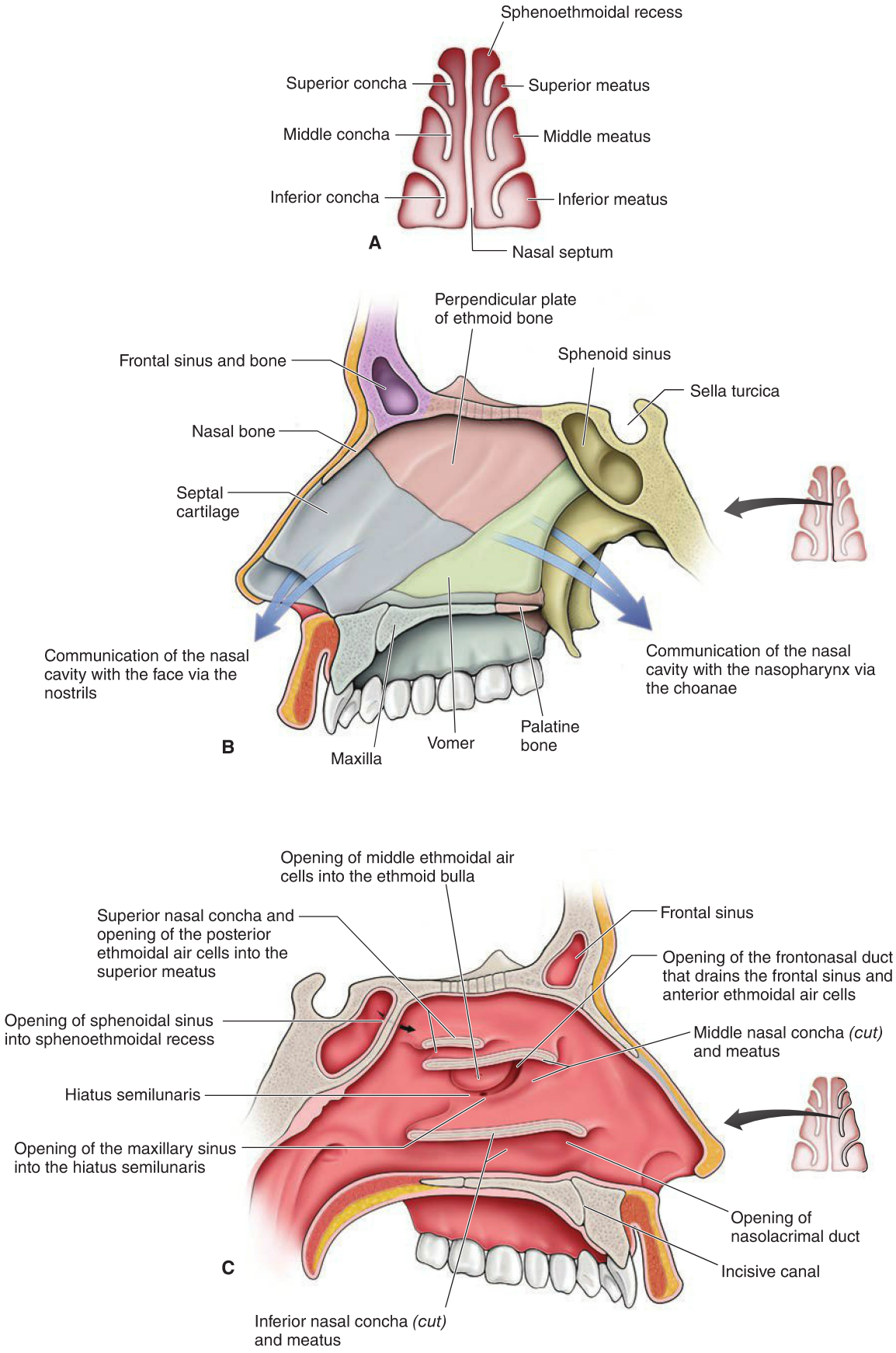

Figure 23-1: A. Coronal section through the nasal cavity. **B**. Nasal septum from the left side. **C**. Lateral nasal wall of the left nasal cavity.

NERVE OF THE NASAL CAVITY

The nasal cavity contains the following nerves (Figure 23-1D):

- **CN I.** Originates in the mucosa lining the superior nasal concha and the superior septum, where the nerve provides special sensation for smell. Neurons from CN I course from the nasal cavity into the anterior cranial fossa and through the numerous foramina of the cribriform plate of the ethmoid bone. The neurons enter the olfactory bulb, where they synapse with interneurons that course along the olfactory tract, transporting information to the brain.
- **CN V-1.** Provides general sensation to the superior aspect of the nasal cavity via the **anterior ethmoidal nerve**, a branch of the **nasociliary nerve**.
- **CN V-2.** Provides general sensation to most of the nasal cavity via **branches of the nasopalatine** and **lateral nasal nerves**.
- **CN VII (facial nerve).** Provides parasympathetic innervation to the nasal glands. CN VII:
  - Gives rise to the greater petrosal nerve in the temporal bone and transports preganglionic parasympathetic neurons en route to the nasal cavity.
  - Joins up with the deep petrosal nerve to form the nerve of the pterygoid canal (Vidian nerve).
  - The nerve of the pterygoid canal enters the pterygopalatine fossa, where pre- and postganglionic parasympathetic neurons synapse.
  - Postganglionic parasympathetic neurons exit the ganglion and "hitch-hike" along CN V-2 branches to the nasal mucosa, where the nasopalatal mucosal glands are innervated.

VASCULAR SUPPLY OF THE NASAL CAVITY

The nasal cavity receives its vascular supply via the following arteries (Figure 23-1E):

- **Sphenopalatine artery.** Supplies blood principally to the septum and the lateral nasal wall.
- **Anterior** and **posterior ethmoidal arteries.** Supply the superior portion of the nasal cavity.
- **Greater palatine artery.** Supplies the inferior nasal septum via the incisive canal.
- **Facial artery.** Supplies the anterior portion of the nasal septum and the lateral nasal wall.

Epitaxis (nosebleed). Kiesselbach's area (plexus) is a region in the anteroinferior region of the nasal septum where branches of the sphenopalatine, anterior ethmoidal, greater palatine, and facial arteries anastamose. Most nosebleeds (epistaxis) usually occur in this area.

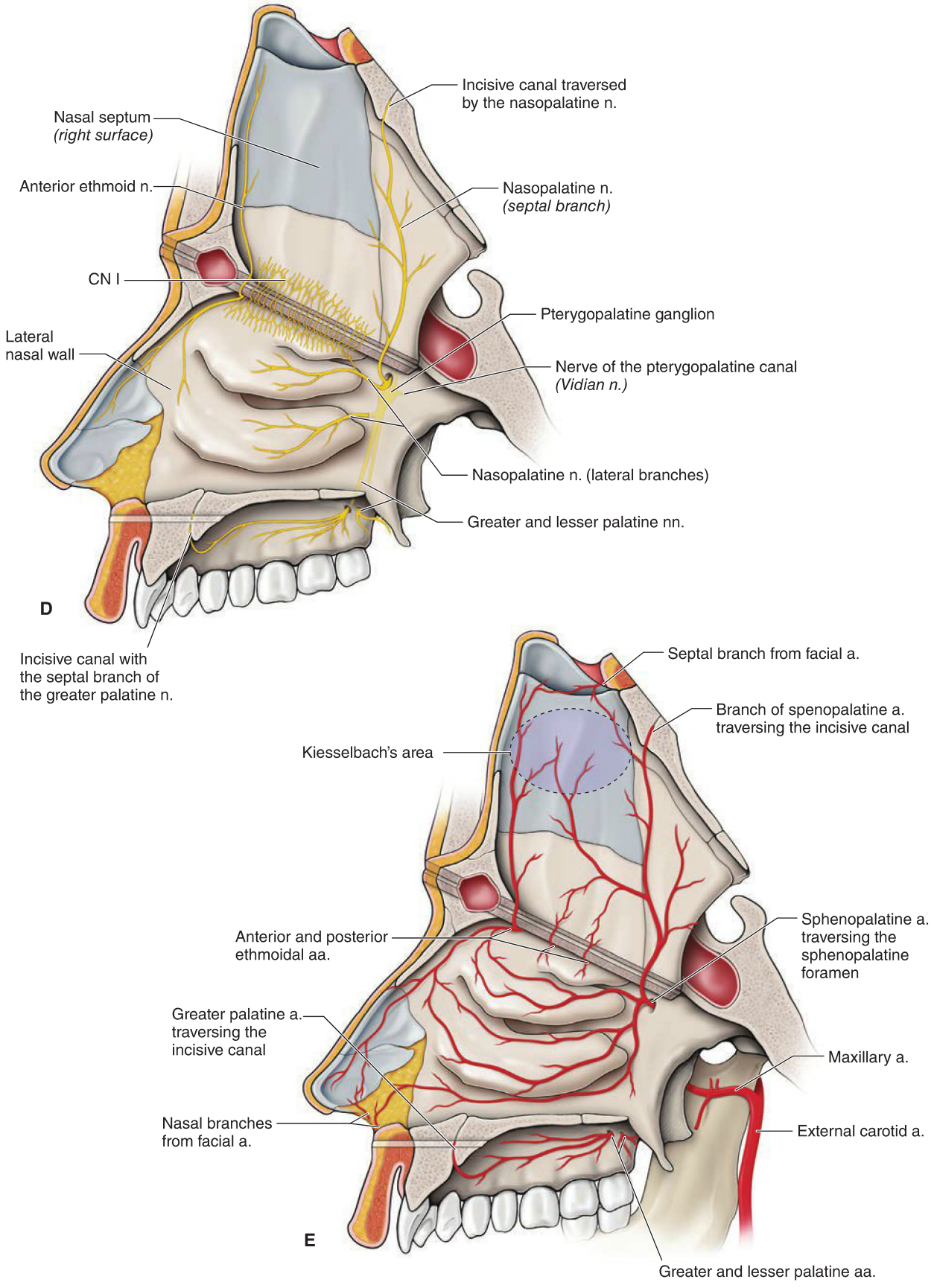

Figure 23-1: (*continued*) Nasal septum reflected superiorly to demonstrate the nerves (**D**) and the arteries (**E**) of the nasal cavity.

PARANASAL SINUSES

BIG PICTURE

The paranasal sinuses are hollow cavities within some bones surrounding the nasal cavity: ethmoid, frontal, maxillary, and sphenoid bones (Figure 23-2A and B). They help decrease the weight of the skull, resonate sound produced through speech, and produce mucus. The paranasal cavities communicate with the nasal cavity, where mucus is drained. Branches of CN V provide general sensory innervation and branches from the greater petrosal nerve (CN VII) travel within CN V to provide parasympathetic innervation. The paranasal sinuses are easily recognizable on an x-ray because the sinuses are filled with air and thus appear as darker shadows on the radiograph.

ETHMOIDAL SINUS

Unlike the frontal, maxillary, and sphenoid paranasal sinuses, the ethmoidal sinus consists of numerous small cavities (air cells) within the bone, as opposed to one or two large sinuses. The subdivisions of the ethmoidal air cells (anterior, middle, and posterior) communicate with the nasal cavity.

- **Subdivisions of the ethmoidal air cells.** The following subdivisions drain into the nasal cavity:
  - **Anterior ethmoidal air cells.** Drain through tiny openings in the hiatus semilunaris of the middle meatus.
  - **Middle ethmoidal air cells.** Drain through the ethmoidal bulla of the middle meatus.
  - **Posterior ethmoidal air cells.** Drain through openings in the superior meatus.
- **Innervation.** Posterior ethmoidal nerve (CN V-1).

FRONTAL SINUS

The frontal sinus is located in the frontal bone and opens into the anterior part of the middle meatus via the **frontonasal duct**.

- **Innervation.** Supraorbital nerve (CN V-1).

MAXILLARY SINUS

The maxillary sinus is the largest of the paranasal sinuses and is located in the maxilla, lateral to the nasal cavity and inferior to the orbit. The maxillary sinus opens into the posterior aspect of the hiatus semilunaris in the middle meatus.

- **Innervation.** Infraorbital nerve (CN V-2).

Maxillary sinusitis. Results from inflammation of the mucous membrane lining the maxillary sinus and is a common infection because of its pattern of drainage. The maxillary sinus drains into the nasal cavity through the hiatus semilunaris, which is located superiorly in the sinus (Figure 23-2C). As a result, infection has to move against gravity to drain. Infection from the frontal sinus and the ethmoidal air cells potentially can pass into the maxillary sinus, compounding the problem. In addition, the maxillary molars are separated from the maxillary sinus only by a thin layer of bone. Therefore, if an infecting organism erodes the bone, infection from an infected tooth can potentially spread into the sinus. The infraorbital nerve (CN V-2) innervates the maxillary teeth and sinus; therefore, pain originating from a tooth or the sinus may be difficult to differentiate.

SPHENOID SINUS

The sphenoid sinus is inferior to the sella turcica of the sphenoid bone and communicates with the nasal cavity via the **sphenoethmoidal recess**.

- **Innervation.** Posterior ethmoidal nerve (CN V-1) and branches from CN V-2.

Pituitary tumor surgery. The pituitary gland is important for the production and release of hormones targeting the gonads, adrenals, thyroid, kidney, uterus, and the mammary glands. Tumors of the pituitary gland may cause an overproduction of these hormones or may affect vision by compressing CN II. If surgery is necessary the pituitary gland can be approached by going through the nasal cavity into the sphenoid sinus and then into the sella turcica, where the pituitary gland is located (transsphenoidal hypophysectomy).

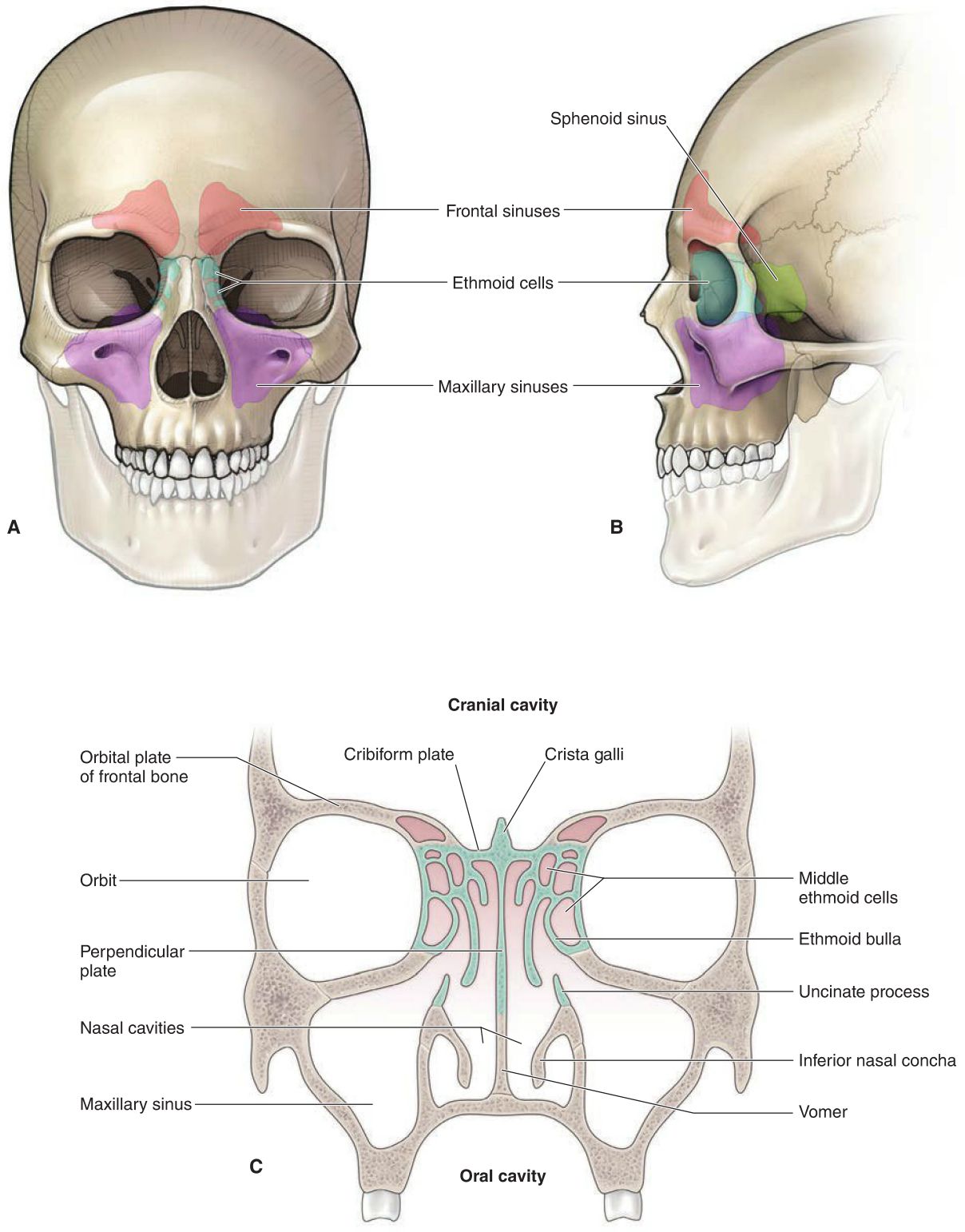

Figure 23-2: Anterior (**A**) and lateral (**B**) views of the paranasal sinuses. **C**. Coronal section of the skull revealing the cranial, orbital, and nasal cavities and their relationships to the paranasal sinuses.

This page intentionally left blank

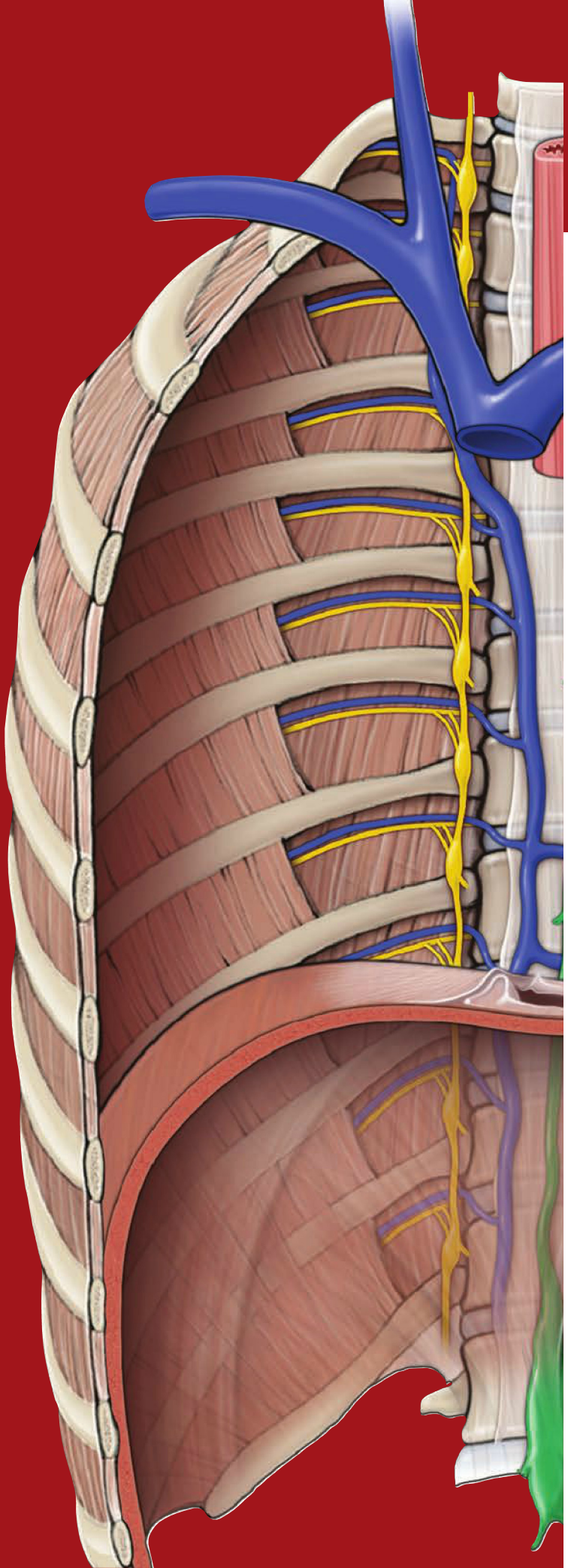

CHAPTER 24

ORAL CAVITY

Palate 250
Tongue 252
Salivation 252
Teeth and Gingivae 254
Study Questions 256
Answers 260

PALATE

BIG PICTURE

The palate consists of a hard and soft palate, which separates the oral and nasal cavities. The muscles that act upon the soft palate are innervated by CN X, with the exception of the tensor veli palatini (CN V-3). The difference in innervation reflects the embryologic origins of the branchial arches.

HARD PALATE

The hard palate consists of the palatine process of the maxillary bone and the horizontal plate of the palatine bone. The incisive canal is in the anterior midline and transmits the following (Figure 24-1B):

- **Innervation.** Nasopalatine and greater palatine nerves (CN V-2); provides general sensory innervation.
- **Vascular supply.** Sphenopalatine and greater palatine arteries (arise from the maxillary artery within the infratemporal fossa).

SOFT PALATE

The soft palate forms the soft, posterior segment of the palate and consists of muscle fibers sheathed within a mucous membrane (Figure 24-1A–C).

- **Uvula.** A projection from the posterior midline of the soft palate; helps close the nasopharynx during swallowing.
- **Palatoglossal and palatopharyngeal folds.** The soft palate is continuous with the palatoglossal and palatopharyngeal muscles/folds.
- **Palatine tonsil.** A collection of lymphoid tissue between the palatoglossal and palatopharyngeal folds; aids the immune system in combating pathogens entering the oral cavity.
- **Functions.** The soft palate acts like a flap valve by moving posteriorly against the pharynx, and separating the oropharynx from the nasopharynx during swallowing. This movement ensures food moves down into the esophagus when swallowing, rather than up into the nasal cavity.
- **Vascular supply.** Lesser palatine artery (maxillary artery), ascending palatine artery (facial artery), and palatine branch of the ascending pharyngeal artery.
- **Innervation.** Sensory innervation is from the lesser palatine nerves (CN V-2).
- **Soft palate muscles.** The muscles of the soft palate are as follows:
  - **Tensor veli palatini muscle.** Courses from the pterygoid plate of the sphenoid bone, hooks around the hamulus, and inserts in the soft palate; tenses the soft palate and is innervated by CN V-3.
  - **Levator veli palatini muscle.** Originates along the cartilaginous portion of the auditory tube and inserts into the superior aspect of the soft palate; elevates the soft palate and is innervated by CN X.
  - **Palatoglossus muscle.** Attaches between the soft palate and the tongue and is innervated by CN X; depresses soft palate.

Lesion of CN X. To test the function of CN X, the physician will ask the patient to open his mouth wide to determine if the palate deviates to one side or the other during a yawning motion. A lesion of CN X causes paralysis of the ipsilateral levator veli palatini muscle, resulting in the uvula being pulled superiorly to the opposite side of the lesion.

Tonsillitis. Inflammation of the palatine tonsils (tonsillitis) is associated with difficulty swallowing and sore throat. Because the palatine tonsils are visible when inspecting the oral cavity, the tonsils of a patient who has tonsillitis will appear enlarged and red. In cases of chronic tonsillitis, the tonsils may be surgically removed (tonsillectomy) to ensure that the patient can swallow and breathe properly.

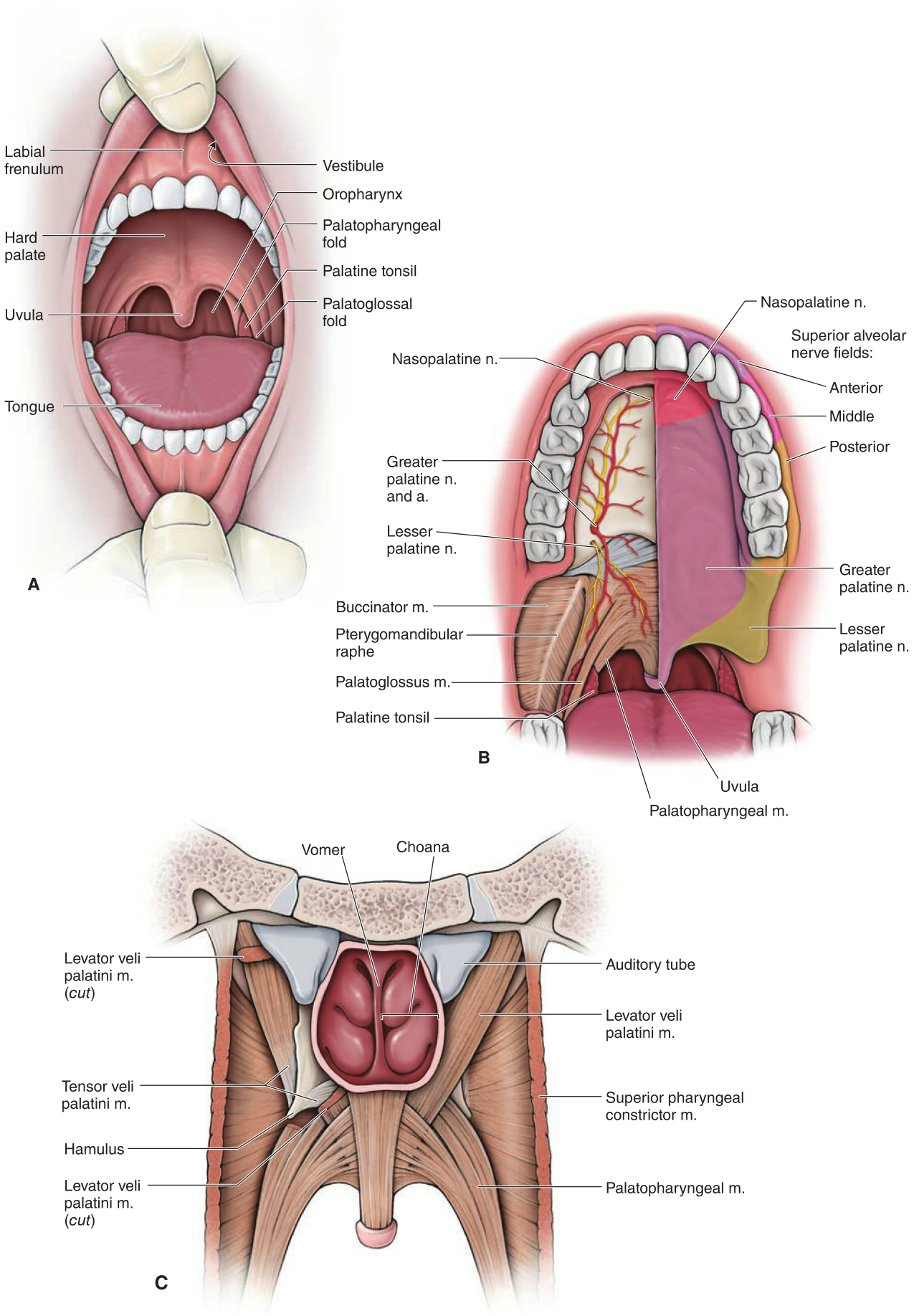

Figure 24-1: **A**. Open mouth showing the palatal arches. **B**. Anterior view of the innervation of the palate. **C**. Posterior view of the palate.

TONGUE

BIG PICTURE

The tongue consists of skeletal muscle covered with taste buds (special sensory) and general sensory nerve endings. The V-shaped sulcus terminalis divides the tongue into anterior and posterior divisions, which differ developmentally, structurally, and by innervation. The foramen cecum is located at the apex of the "V" and indicates the site of origin of the embryonic thyroglossal duct.

MUSCLES OF THE TONGUE

Tongue muscles are bilaterally paired and innervated by the hypoglossal nerve (CN XII) (Figure 24-2A and C):

- **Genioglossus muscle.** Attaches between the internal surface of the mandible and the tongue; protrudes tongue out of the oral cavity ("sticking out your tongue").
- **Hyoglossus muscle.** Courses lateral to the genioglossus muscle, with attachments from the hyoid bone to the tongue; depresses and retracts the tongue.
- **Styloglossus muscle.** Originates on the styloid process of the temporal bone and courses between the superior and middle pharyngeal constrictors to insert on the lateral surface of the tongue; elevates and retracts the tongue.

INNERVATION OF THE TONGUE

The following nerves innervate the tongue (Figure 24-2B and C):

- **Lingual nerve (CN V-3).** Provides general sensory innervation of the anterior two-thirds of the tongue; courses inferior to the submandibular duct.
- **Chorda tympani nerve (CN VII).** Provides special sensory innervation (taste) from anterior two-thirds of the tongue.
- **Glossopharyngeal nerve (CN IX).** Provides special sensory innervation (taste) and general sensory innervation from posterior third of the tongue.
- **Hypoglossal nerve (CN XII).** Provides somatic motor innervation to all of tongue muscles (except the palatoglossus, which is innervated by CN X).

VASCULAR SUPPLY OF THE TONGUE

The vascular supply of the tongue is as follows:

- **Lingual artery.** Arises from the external carotid artery at the level of the tip of the greater horn of the hyoid bone in the carotid triangle.
  - Courses anteriorly between the hyoglossus and the genioglossus muscles, giving rise to the dorsal lingual and sublingual branches and terminating as the deep lingual artery.
- **Lingual vein.** Arises from the deep surface of the tongue and terminates in the internal jugular vein; clinically important as it absorbs medicines that are introduced sublingually into the body (i.e., nitroglycerine).

SALIVATION

BIG PICTURE

Saliva is essential for maintaining healthy oral tissue. It is composed primarily of water as well as mucins, enzymes, and immune components. Saliva initiates the chemical digestion of carbohydrates (the enzyme salivary amylase), cleans teeth, and lubricates masticated food into a bolus. The three glands that produce saliva are the parotid, submandibular, and sublingual glands.

- **Salivary glands.** The bilateral openings of ducts of the salivary glands into the oral cavity are as follows:
  - **Parotid gland.** The duct opens opposite the second maxillary molar.
  - **Submandibular gland.** The duct courses medial to the lingual nerve and opens into the area adjacent to the lingual frenulum (Figure 24-2B).
  - **Sublingual gland.** The duct opens at the base of the tongue.
- **Innervation.** The parasympathetic nervous system innervates the salivary glands (Figure 24-2C):
  - **Parotid gland.** Lesser petrosal nerve (CN IX), via the otic ganglion.
  - **Submandibular and sublingual glands.** Chorda tympani nerve (CN VII), via the submandibular ganglion.

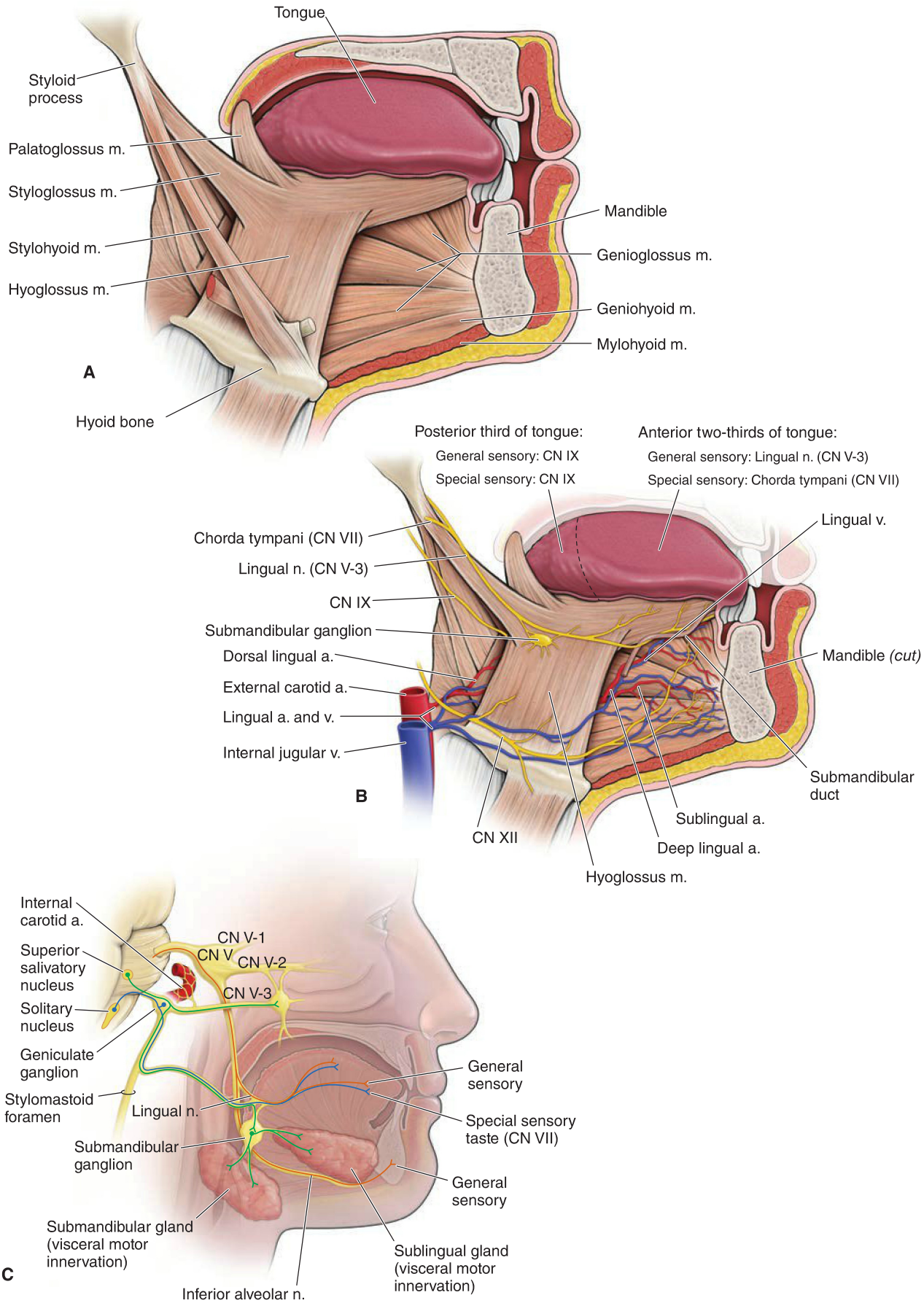

Figure 24-2: **A**. Tongue muscles. **B**. Neurovascular supply of the tongue. **C**. Innervation of the tongue.

TEETH AND GINGIVAE

BIG PICTURE

The teeth cut, grind, and mix food during mastication. In adults, there are 16 teeth in the maxilla and 16 in the mandible. Branches of CN V-2 and the maxillary artery and veins supply the maxillary teeth and gingivae. Branches of CN V-3, and the inferior alveolar artery and veins supply the mandibular teeth and gingivae.

TYPES OF TEETH

There are 20 teeth in a child and 32 in an adult (Figure 24-3A).

- **Tooth numbers.** Adult teeth are typically numbered in a progressing clockwise fashion, with tooth number 1 (upper right maxillary molar) across to tooth number 16 (upper left maxillary molar). Tooth number 17 is the left third mandibular molar and continues to tooth number 32, the right third mandibular molar.
- **Tooth types.** The teeth are divided into four quadrants with eight teeth located in the upper left, upper right, lower left, and lower right halves of the maxilla and mandible. Each quadrant consists of the following teeth:
  - **Incisors (2).** Chisel-shaped teeth ideal for cutting or biting.
  - **Canine (1).** A single pointed tooth used for tearing food.
  - **Premolars (2).** Have two cusps, which are used for grinding.
  - **Molars (3).** Have three cusps, which also are used for grinding. The third and most posterior molar tooth emerges last, usually in the late adolescent years, and is often referred to as the **wisdom tooth**.

Cavities (dental caries). Cavities are holes in the teeth formed through the deposit of food products on teeth, known as plaque. Bacteria inhabit the plaque and metabolize carbohydrates into acids. Over time, the acids dissolve the outer protection of the tooth, the enamel, resulting in cavities.

INNERVATION OF THE TEETH

The innervation of the teeth and gingivae are as follows (Figure 24-3B and C):

- **Maxillary teeth.** The maxillary nerve (CN V-2) enters the pterygopalatine fossa via the foramen rotundum and gives rise to the **anterior**, **middle**, and **posterior superior alveolar nerves**, which provide general sensory innervation to the maxillary teeth.
  - **Maxillary gingivae.** The posterior, middle, and anterior superior alveolar nerves innervate the buccal surface of the gingivae, whereas the **greater palatine** and **nasopalatine nerves** innervate the lingual surface.
- **Mandibular teeth.** The inferior alveolar nerve enters the mandibular foramen and provides general sensory innervation to the mandibular teeth. The inferior alveolar nerve exits the mandibular canal as the **mental nerve** by traversing the **mental foramen** and providing general sensory innervation to the bottom lip.
  - **Mandibular gingivae.** The buccal and mental nerves innervate the buccal surface of the gingivae, whereas the lingual nerve innervates the lingual surface.

Inferior alveolar nerve block. An inferior alveolar nerve block is administered to patients who require dental work in the mandible. Injection of local anesthetics into the oral mucosa at the lingula of the mandible will anesthetize the inferior alveolar nerve (resulting in anesthesia of mandibular teeth and lower lip) and potentially the lingual nerve (resulting in anesthesia of the tongue).

Maxillary nerve blocks. A plexus formed by the anterior superior, middle superior, and posterior superior alveolar nerves supplies the maxillary teeth. Unlike the mandibular teeth, where anesthesia can be administered in one location to effectively block all the teeth on that side, the maxillary teeth must be considered separately. The palate must also be considered. Therefore, a greater palatine as well as a nasopalatine nerve block is often administered during dental procedures.

- **Maxillary molars.** Injection is given at the region of the second molar.
- **Maxillary premolars.** Injection is given at the region of the second premolar.
- **Maxillary canine and incisors.** Injection can be given above the roots of the anterior teeth or via an infraorbital nerve block.

VASCULAR SUPPLY TO THE TEETH

The arteries supplying the teeth mirror their accompanying nerves.

- **Posterior superior alveolar artery.** Originates from the infraorbital artery, which arises from the maxillary artery in the pterygopalatine fossa. The infraorbital artery exits the fossa and enters the infraorbital canal, where branches supply the maxillary molars and premolars.
- **Anterior superior alveolar artery.** Originates from the infraorbital artery, where branches course through the maxilla to supply the incisor and canines.
- **Inferior alveolar artery.** Originates from the maxillary artery and courses with the inferior alveolar nerve through the mandibular canal to supply the mandibular teeth.

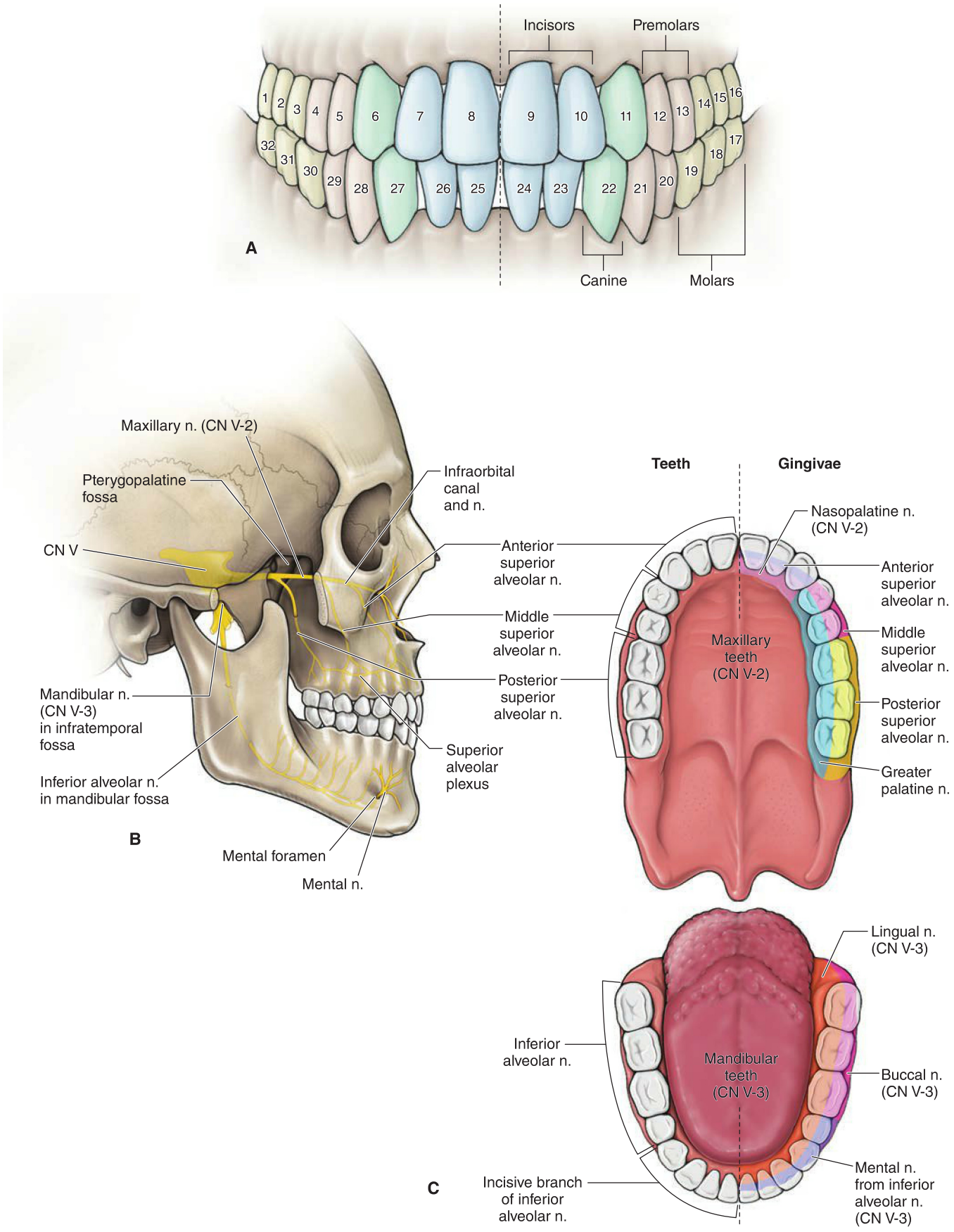

Figure 24-3: **A**. Teeth. Lateral (**B**) and anterior (**C**) views of the innervation of the teeth and gingiva.

STUDY QUESTIONS

Directions: Each of the numbered items or incomplete statements is followed by lettered options. Select the **one** lettered option that is **best** in each case.

1. During a rugby match, a 22-year-old player experiences a violent blow to the side of his head, resulting in a loss of consciousness. The player regains consciousness approximately 30 seconds later and sits on the sideline recuperating. A half-hour later, he becomes nauseous, disoriented, and falls over unconscious. He is taken to the hospital where a CT scan of the head reveals a discoid-shaped collection of blood confined by the suture lines of the skull, consistent with an epidural hematoma. Which vascular structure is most likely associated with this injury?

A. Bridging cerebral vein hemorrhaging into the subarachnoid space
B. Bridging cerebral vein hemorrhaging into the subdural space
C. Middle meningeal artery hemorrhaging into the epidural space
D. Middle meningeal artery hemorrhaging into the subdural space
E. Superior sagittal sinus hemorrhaging into the epidural space
F. Superior sagittal sinus hemorrhaging into the subdural space

2. A 19-year-old woman is taken to the emergency department after falling and lacerating her scalp. The scalp bleeds profusely when cut because the arteries most likely:

A. Are held open due to the course of the arteries through the spongy bone of the skull.
B. The diameter of a pencil eraser.
C. Bleed from both cut ends due to rich anastomoses of scalp vessels.
D. Collapse and contract within the surrounding connective tissue.
E. Course side to side over the vertex of the skull.

3. A 31-year-old man is brought to the emergency department after being involved in a motor vehicle collision that resulted in head trauma. Radiographic imaging reveals a fracture to the bone deep to the man's moustache. Which of the following bones is most likely fractured in this patient?

A. Frontal
B. Mandible
C. Maxilla
D. Temporal
E. Zygomatic

4. Radiographic imaging of the brain of an 84-year-old woman reveals a berry aneurysm in the anterior communicating cerebral artery. Rupture of this aneurysm would most likely result in what type of hemorrhage?

A. Epidural hemorrhage
B. Intraparenchymal hemorrhage
C. Intraventricular hemorrhage
D. Subarachnoid hemorrhage
E. Subdural hemorrhage

5. A newborn infant is diagnosed with hydrocephalus, a condition where cerebrospinal fluid (CSF) builds up within the ventricular system of the brain. The skull bones have not yet fused because of the fontanelles; therefore, when the brain swells, the cranium swells as well. One cause of hydrocephalus would be a blockage of the flow of CSF within the ventricular system. Identify the most likely location of blockage that would result in this infant's hydrocephalus.

A. Choroid plexus
B. Cerebral aqueduct
C. Lateral aperture
D. Medial aperture
E. Central canal of the spinal cord

6. An 81-year-old woman complains of slow onset of headache, dizziness, and nausea. Her history of the present illness reveals that 5 days ago she slipped on ice and hit her head on the pavement. She still has a bump on her head. Radiographic imaging of the brain reveals diffuse extracerebral bleeding. Which of the following is the most likely hematoma identified in this patient?

A. Epidural hematoma because of a torn middle meningeal artery
B. Subarachnoid hematoma because of a ruptured aneurism of the anterior communicating artery
C. Subdural hematoma because of a torn bridging vein between the brain and superior sagittal sinus

7. A 56-year-old man develops a paraganglioma and is diagnosed with Vernet's syndrome. The tumor compresses structures that enter or exit the jugular foramen. The tumor would most likely compress which of the following?

A. Abducens n.	Facial n.	Vestibulocochlear n.	Internal carotid a.
B. Abducens n.	Facial n.	Vestibulocochlear n.	Sigmoid sinus
C. Abducens n.	Facial n.	Vestibulocochlear n.	Vertebral a.
D. Glossopharyngeal n.	Spinal accessory n.	Vagus n.	Internal carotid a.
E. Glossopharyngeal n.	Spinal accessory n.	Vagus n.	Sigmoid sinus
F. Glossopharyngeal n.	Spinal accessory n.	Vagus n.	Vertebral a.
G. Oculomotor n.	Trigeminal n.	Trochlear n.	Internal carotid a.
H. Oculomotor n.	Trigeminal n.	Trochlear n.	Sigmoid sinus
I. Oculomotor n.	Trigeminal n.	Trochlear n.	Vertebral a.

8. During a physical examination, the motor activity of extraocular muscles is tested along with the associated cranial nerves, which include CN III, CN VI, and

A. CN I.
B. CN II.
C. CN IV.
D. CN V.
E. CN VII.

9. A 5-year-old boy is brought to the pediatrician with a complaint of severe pain, swelling, and redness around his right eye. He is diagnosed with periorbital cellulitis. The pediatrician tells the boy's parents that there is a possibility that the infection could spread to the boy's brain. The most probable route of spread to the brain would be through which of the following structures?

A. Cribriform plate into the meningeal space
B. Facial canal through the internal auditory meatus to the posterior cranial fossa
C. Frontal sinus into the sagittal sinus and into the subarachnoid space
D. Facial vein to the superior ophthalmic vein to the cavernous sinus
E. Orbital lymphatics to superficial cervical lymph nodes to the thoracic duct to the brain

10. When the corneal reflex in a patient is examined, sensory information is conducted from the cornea to the brain via the long ciliary nerve, a branch of CN V-1. The sensory input causes a motor response resulting in the closure of the patient's eyelids. Which motor nerve is being tested when the corneal reflex is being examined?

A. Abducens nerve (CN VI)
B. Facial nerve (CN VII)
C. Maxillary nerve (CN V-2)
D. Oculomotor nerve (CN III)
E. Trochlear nerve (CN IV)

11. A blue dye is placed into the right eye of a patient to assess the patency of the tear duct system. Assuming the lacrimal system is patent, at which structure would the physician see the eventual flow of the dye?

A. Inferior nasal meatus
B. Oral cavity
C. Pharynx
D. Sphenoethmoidal recess
E. Superior nasal meatus

12. A 32-year-old man sees his physician because of complaints of "double vision." On examination, findings in the right eye are consistent with a trochlear nerve injury. During the examination, the patient was most likely unable to accomplish which of the following movements?

A. Abduction
B. Abduction and depression
C. Abduction and elevation
D. Adduction
E. Adduction and depression
F. Adduction and elevation

13. A 42-year-old woman complains of steadily worsening pain and discomfort on the right side of the head. A CT scan shows a discrete tumor immediately lateral to the atlas and axis of the vertebral column that involves the superior cervical ganglion. The loss of autonomic innervation provided by this ganglion would most likely cause which of the following symptoms (assume the right side for each choice)?

	Eyelid	Pupil	Skin
A.	Normal	Miosis	Anhydrosis
B.	Normal	Mydriasis	Normal
C.	Normal	Normal	Oily
D.	Ptosis	Miosis	Anhydrosis
E.	Ptosis	Mydriasis	Normal
F.	Ptosis	Normal	Oily

14. A 42-year-old man sees his physician because of hearing loss and a sensation of the room spinning while he is standing. A lesion to which cranial nerve would most likely result in these symptoms?

A. CN IV
B. CN V
C. CN VI
D. CN VII
E. CN VIII
F. CN IX

15. Radiographic imaging reveals puss building up around the ear ossicles. Which of the following is the most likely location of the puss?

A. External ear
B. Middle ear
C. Internal ear

16. Tic douloureux is a neuropathic disorder characterized by sudden attacks of excruciating, lightening-like jabs of facial pain (paroxysm). Touching the face, brushing the teeth, shaving, or chewing often set off the paroxysms of sudden stabbing pain. The cause of the condition is unknown. Tic douloureux most likely results from deficits in which cranial nerve?

A. Oculomotor nerve
B. Facial nerve
C. Glossopharyngeal nerve
D. Trigeminal nerve
E. Vagus nerve

17. A 26-year-old woman presents with unilateral paralysis of facial muscles consistent with Bell's palsy. Which of the following cranial nerves is most likely affected that would result in this patient's condition?

A. Facial nerve
B. Glossopharyngeal nerve
C. Oculomotor nerve
D. Trigeminal nerve
E. Vestibulocochlear nerve

18. Branches of the maxillary artery gain entrance to the pterygopalatine fossa via which of the following structures?

A. Foramen rotundum
B. Foramen spinosum
C. Mandibular foramen
D. Pterygomaxillary fissure
E. Superior orbital fissure

19. After examination of a 60-year-old man, the dentist determines that the man has a cavity in a mandibular molar that needs to be filled. Which of the following nerves is the dentist most likely attempting to anesthetize to perform this procedure?

A. Chorda tympani
B. Hypoglossal
C. Inferior alveolar
D. Lingual
E. Superior alveolar

20. A herpes zoster virus infects the maxillary nerve of a 52-year-old woman. Blisters have formed on the lower eyelid and skin flanking the woman's nostrils. In addition to the areas observed on this patient, in what other locations would blisters most likely be seen?

A. Anterior portion of the tongue
B. Bridge of the nose
C. Chin
D. Forehead
E. Palatal mucosa
F. Upper eye lid

21. The pterygopalatine ganglion houses postganglionic neuronal cell bodies for visceral motor (parasympathetic) components of which of the following cranial nerves?

A. CN III
B. CN V
C. CN VII
D. CN IX
E. CN X

22. Irrigation of the maxillary sinus through its opening is a supportive measure to accelerate the resolution of a maxillary sinus infection. Which of the following nasal spaces is the approach to the opening of the maxillary sinus?

A. Choana
B. Inferior meatus
C. Middle meatus
D. Sphenoethmoidal recess
E. Superior meatus

23. A 7-year-old boy experiences acute speech difficulties. The findings on physical examination were unremarkable except that each time the boy protruded his tongue it deviated to the left. The results of the clinical and laboratory evaluations were consistent with the presence of infectious mononucleosis. Cranial nerve palsy is a rare complication of acute infectious mononucleosis in childhood. These findings are most likely the result of a deficit on which of the following cranial nerves?

A. Left CN VII
B. Left CN IX
C. Left CN XII
D. Right CN VII
E. Right CN IX
F. Right CN XII

24. The uvula of a 62-year-old patient deviates to the upper left when she is asked to say "Ahhh." This would most likely indicate a lesion on which of the following cranial nerves?

A. Left side of CN V-3
B. Left side of CN X
C. Left side of CN XII
D. Right side of CN V-3
E. Right side of CN X
F. Right side of CN XII

25. A 49-year-old woman presents with loss of sweet sensation on the right side of the anterior part of the tongue. Which additional findings may also be seen on the right side of this patient?

A. Adducted eye
B. Muscle of mastication weakness
C. Loss of corneal reflex
D. Reduced gag reflex
E. Tongue deviation during protrusion

ANSWERS

1—C: The middle meningeal artery courses along the internal surface of the lateral skull along the pterion. This artery courses in the dura mater, and when it ruptures, blood pools in the epidural space. Bridging cerebral veins hemorrhage into the subdural space. The superior sagittal sinus is a vein and, as such, low vascular pressure will require a much longer time to present symptoms. A superior sagittal sinus hemorrhage rarely will occur. However, more likely a superior sagittal sinus thrombosis will occur, which is not what this patient experienced.

2—C: The scalp consists of five layers. The vessels primarily course within the second, subcutaneous connective tissue layer. The rich anastomoses of internal and external carotid artery branches result in blood hemorrhaging from both cut ends. The dense connective tissue surrounding the cut vessels keeps the cut vessels patent. As a result, the scalp bleeds profusely.

3—C: The maxilla is the bone of the upper jaw and, therefore, would be associated with the location of a moustache. The frontal bone is in the forehead; the mandible is the lower jaw; the temporal bone is along the side of the head; and the zygomatic bone is the cheekbone.

4—D: The anterior communicating cerebral artery connects the paired anterior cerebral arteries within the subarachnoid space. Therefore, if the berry aneurysm was to rupture, it would cause an extracerebral hemorrhage in the subarachnoid space. Intraparenchymal and intraventricular hemorrhages are intracerebral (occur within the brain tissue). An epidural hemorrhage occurs between the skull and dura as a result of a ruptured middle meningeal artery. A subdural hemorrhage occurs between the dura and arachnoid mater, usually as a result of a torn bridging vein.

5—B: The cerebral aqueduct serves as the only drainage of CSF from the lateral and third ventricles. The choroid plexus continually filters plasma to create CSF, and therefore, a block in the aqueduct would result in CSF buildup in the lateral and third ventricles and result in hydrocephalus. A blockage in choroid plexus would result in a decrease in CSF production. A blockage in one of the apertures would not result in hydrocephalus because CSF could exit through another aperture. The central canal of the spinal cord would not result in hydrocephalus.

6—C: The patient injured her head 5 days ago. A slow bleed indicates a venous hemorrhage, which often occurs when small bridging veins are torn or sheared as they travel from the brain through the arachnoid mater and meningeal dura to dump into a dural sinus. The diffuse bleeding indicates that the blood is in the subdural space with no limitations to spread around the brain. A ruptured aneurysm of any artery would present in hours, not days, due to the increased blood pressure.

7—E: This patient has a paraganglioma, a jugular glomus tumor. The jugular foramen transmits CNN IX, X, and XI (glossopharyngeal, vagus, and spinal accessory nerves, respectively). In addition, the sigmoid sinus traverses the jugular foramen, where it continues as the internal jugular vein. The internal carotid artery enters the base of the skull through the carotid canal; the vertebral artery enters via the foramen magnum and, therefore, would not be affected by a jugular glomus tumor.

8—C: The seven extraocular muscles are the superior rectus, medial rectus, inferior rectus, and inferior oblique (innervated by CN III, the oculomotor nerve), the lateral rectus (innervated by CN VI, the abducens nerve), and the superior oblique (innervated by CN IV, the trochlear nerve). CN I (olfactory nerve) is for smell; CN II (optical nerve) is for sight; CN V (trigeminal nerve) is for general sensation; and CN VII (facial nerve) closes the eye and innervates the lacrimal gland.

9—D: The facial vein drains blood from the orbital region down to the internal jugular vein. However, blood from the orbit also spreads from the orbit via the superior ophthalmic vein through the superior orbital fissure to the cavernous sinus within the skull.

10—B: The orbicularis oculi muscle, the muscle that closes and blinks the eye, is innervated by CN VII, the facial nerve.

11—A: The nasolacrimal duct drains into the nasal cavity, into the space inferior to the inferior nasal concha called the inferior nasal meatus.

12—E: This patient is complaining of double vision, or diplopia. The superior oblique muscle is innervated by the trochlear nerve (CN IV). To clinically test the superior oblique muscle, the patient adducts his eye and then looks inferiorly. Therefore, Choice E (adduction and depression) is the correct answer. Choice B (abduction and depression) is the position for the anatomic action of the superior oblique muscle; however, outward and downward is the location for clinically testing the inferior rectus muscle.

13—D: The superior cervical ganglion is responsible for distributing postganglionic sympathetic neurons to the head, including sweat glands in the skin, superior tarsal muscle in the upper eyelid, and the pupillary dilator muscle. If sympathetics are absent, the eyelid droops (ptosis) due to losing the superior tarsal muscle. The pupil constricts due to losing tone in the pupillary dilator muscle and skin is red and dry from lack of innervation of sweat and sebaceous glands.

14—E: The vestibulocochlear nerve (CN VIII) is responsible for hearing and equilibrium. CN IV (trochlear nerve) and CN VI (abducens nerve) both innervate muscles in the orbit. CN V (trigeminal nerve) is general sensory to the head. CN VII (facial nerve) provides motor innervation to the facial muscles and to the stapedius muscle in the ear. CN IX (glossopharyngeal nerve) innervates the posterior third of the tongue and oropharynx.

15—B: The middle ear is the location of the three ear ossicles.

16—D: Tic douloureux is a condition that is associated with general sensation to the face, which is associated with CN V (trigeminal nerve). The facial nerve (CN VII) is only associated with branchial motor innervation to muscles of facial expression.

17—A: The facial nerve (CN VII) innervates muscles of facial expression. Therefore, a lesion of CN VII would result in unilateral facial paralysis. The trigeminal nerve (CN V) is responsible for conducting sensory information from the skin of the face, but does not provide motor innervation.

18—D: The maxillary artery branches off the external carotid artery and courses through the infratemporal fossa. The infratemporal fossa communicates with the pterygopalatine fossa via the pterygomaxillary fissure.

19—C: The inferior alveolar nerve provides sensory innervation to the mandibular teeth on the ipsilateral side. The chorda tympani provides taste sensation to the anterior part of the tongue via the lingual nerve. The superior alveolar provides sensory innervation for the maxillary teeth. The hypoglossal nerve provides motor innervation to the tongue muscles.

20—E: The mucosa lining the palate is innervated by the greater and lesser palatine nerves, which are branches of the maxillary nerve (CN V-2). Therefore, this patient with herpes zoster virus will most likely have blisters on the palatal mucosa.

21—C: The pterygopalatine ganglion houses the postganglionic parasympathetic neuronal cell bodies for the facial nerve, CN VII. As CN VII enters the internal acoustic meatus, it gives rise to the greater petrosal nerve, which courses into the pterygopalatine ganglion and synapses. The postganglionic parasympathetics from CN VII then course to the lacrimal gland, nasal glands, and palatal glands.

22—C: The hiatus semilunaris is located in the middle meatus, inferior to the middle nasal concha, and forms a communication with the maxillary sinus.

23—C: In a patient with a lesion on the left side of CN XII (hypoglossal nerve), the left genioglossus muscle will not cause the tongue to protrude, and therefore, the right genioglossus muscle will cause the tongue to stick out of the mouth and deviate to the side of the lesion ("lick your wounds").

24—E: The levator veli palatini muscles bilaterally elevate the soft palate, including the uvula. If the right levator veli palatini muscle is not innervated as a result of a lesion on CN X (vagus nerve), then the left levator veli palatini muscle contracts and pulls the uvula toward the left.

25—C: CN VII (facial nerve) provides special sensory innervation for taste in the anterior part of the tongue. In addition, CN VII also innervates the muscles of facial expression, including the orbicularis oculi muscle, which is the efferent limb of the corneal reflex.

This page intentionally left blank

SECTION 5

NECK

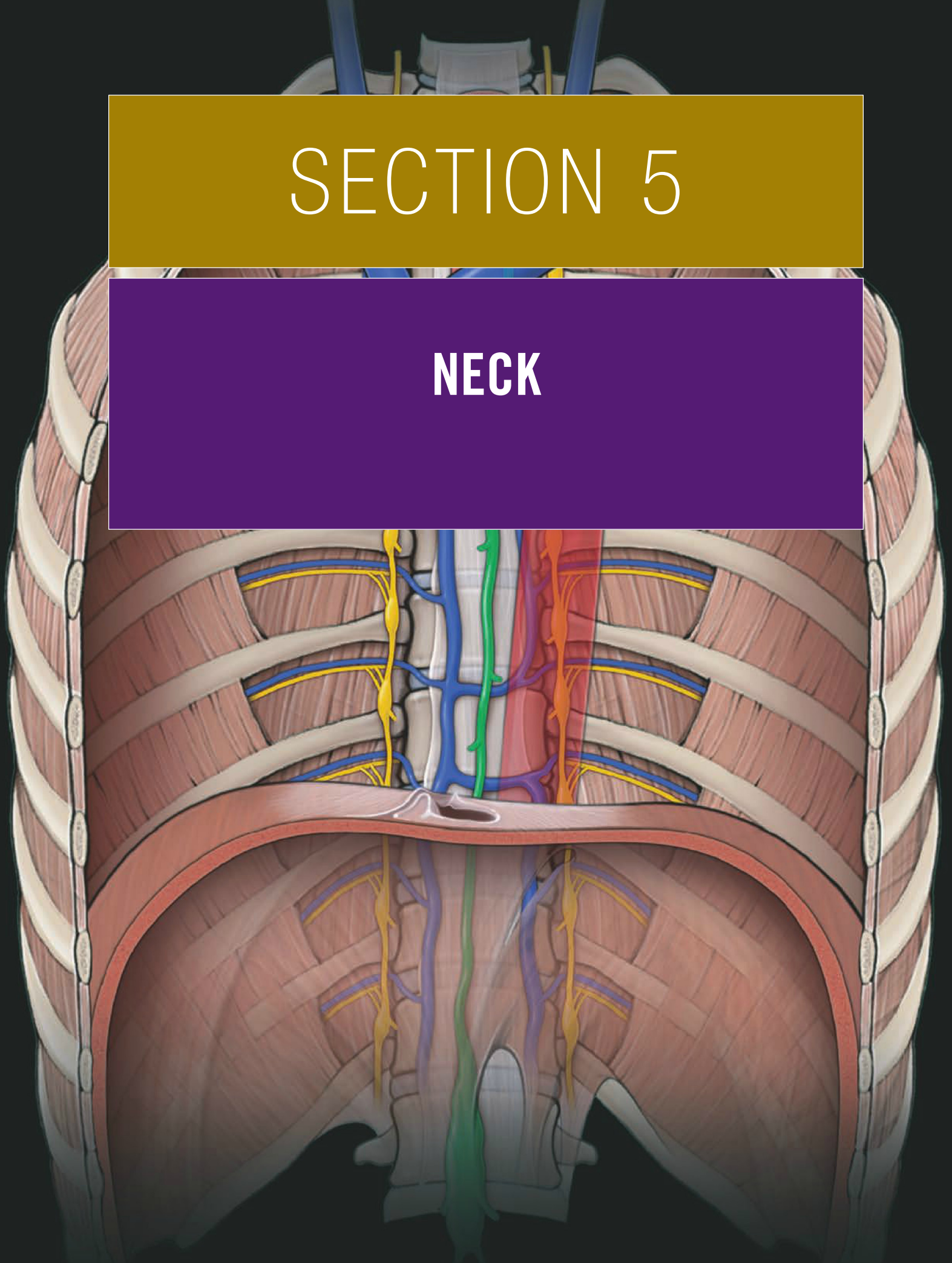

This page intentionally left blank

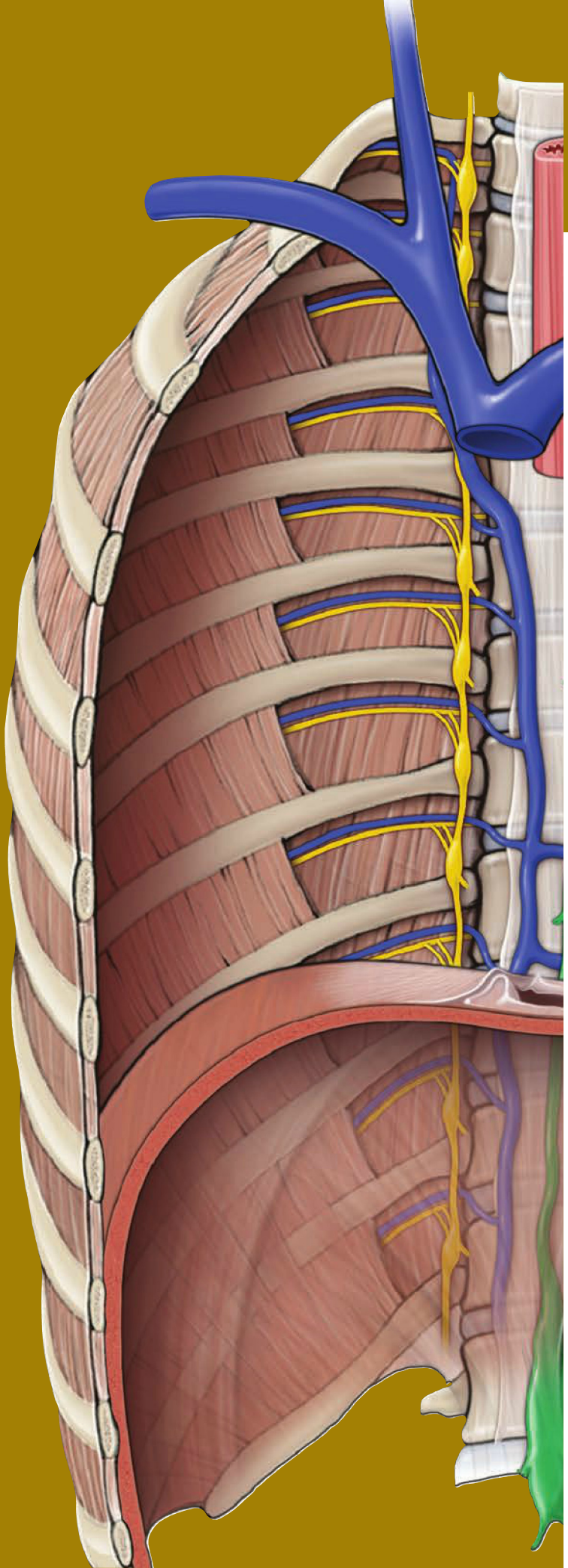

CHAPTER 25

OVERVIEW OF THE NECK

Fascia of the Neck 266
Muscles of the Neck. 268
Vessels of the Neck 272
Innervation of the Neck 274

FASCIA OF THE NECK

BIG PICTURE

The cervical fascia consists of concentric layers of fascia that compartmentalize structures in the neck (Figure 25-1). These fascial layers are defined as the superficial fascia and the deep fascia, with sublayers within the deep fascia. The fascia of the neck can determine the direction in which infection in the neck may spread.

SUPERFICIAL CERVICAL FASCIA

The superficial cervical fascia is the subcutaneous layer of the skin in the neck and contains the platysma muscle, cutaneous nerves from the cervical plexus, and superficial vessels and lymph nodes.

DEEP CERVICAL FASCIA

The deep cervical fascia is deep to the superficial fascia and contains muscles and viscera in compartments to enable structures to slide over each other, and to serve as a conduit for neurovascular bundles; forms the following sublayers:

- **Deep investing fascia.** Completely encircles the neck and splits to enclose the sternocleidomastoid and trapezius muscles; forms the roof of the anterior and posterior triangles of the neck.
- **Pretracheal fascia.** Forms a tubular sheath in the anterior part of the neck and extends from the hyoid bone inferiorly into the thorax to blend with the fibrous pericardium.
  - **Contents.** Thyroid gland, parathyroid glands, trachea, and esophagus.
  - **Buccopharyngeal fascia.** The name of the posterior portion of the pretracheal fascia.
- **Prevertebral fascia.** Forms a tubular sheath around the vertebral column and forms the floor of the posterior triangle of the neck.
  - **Contents.** Sympathetic trunk, phrenic nerve, brachial plexus, cervical vertebrae and prevertebral muscles (i.e., longus colli, longus capitis and scalene muscles).
  - **Alar fascia.** The anterior lamina of prevertebral fascia has two layers; the anterior layer is referred to as alar fascia.
  - **Axillary sheath.** The prevertebral fascia extends laterally as the axillary sheath, which surrounds the axillary vessels and branchial plexus.
- **Carotid sheath.** A tube of fascia that extends from the cranial base to the root of the neck; formed by the investing, pretracheal, and prevertebral layers of fascia.
  - **Contents.** Common and internal carotid arteries, internal jugular vein, vagus nerve, deep cervical lymph nodes, and carotid sinus nerve.
- **Retropharyngeal space.** Located between the buccopharyngeal and alar fascia, extends from the skull base to the upper thoracic vertebrae and is the most clinically important interfascial space in the neck.
  - **Contents.** Lymph nodes, adipose and loose connective tissue; this is a potential space where normally nothing fills it. However, an abscess can spread easily in this location.
  - **Function.** Permits superior and inferior movements of the larynx, pharynx, and esophagus during swallowing relative to the cervical vertebrae.

Retropharyngeal abscess. Abscesses within the retropharyngeal space may bulge anteriorly and compress the pharynx (swallowing compromised) and trachea (breathing compromised) or spread inferiorly into the mediastinum.

Danger space. A potential space located between the alar fascia (anterior lamina of prevertebral fascia) and deep lamina of prevertebral fascia. This potential space extends from the skull base to the diaphragm.

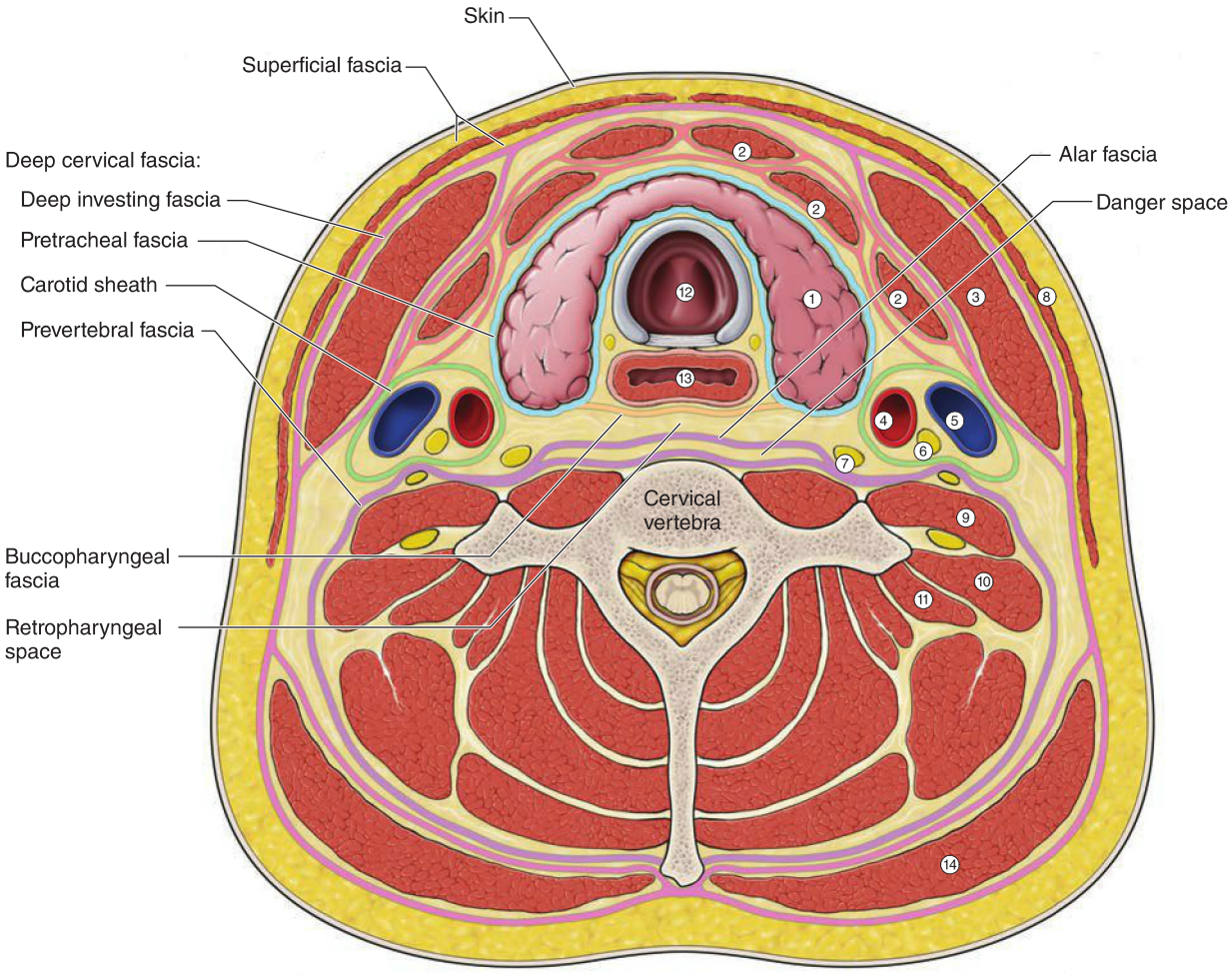

Figure 25-1: Cross-section of the neck through the thyroid gland, showing the layers of the cervical fascia.

MUSCLES OF THE NECK

BIG PICTURE

The muscles of the neck are organized and grouped with the cervical fascia. The platysma muscle is within the superficial fascia, sternocleidomastoid and trapezius muscles are within the deep investing fascia, and the prevertebral muscles within the prevertebral fascia.

PLATYSMA MUSCLE

Located in the superficial cervical fascia (Figure 25-2A).

- Depresses the mandible and wrinkles the skin of neck; is innervated by the cervical branch of the facial nerve (CN VII).

STERNOCLEIDOMASTOID AND TRAPEZIUS MUSCLES

Located within the deep investing fascia (Figure 25-2A).

- **Sternocleidomastoid muscle.** Named according to its bony attachments (sternum, clavicle, and mastoid process); forms a primary border for the anterior and posterior cervical triangles.
  - Flexes the neck, pulls the chin upward, and assists in elevating the rib cage during inspiration; is innervated by the spinal accessory nerve (CN XI).
- **Trapezius muscle.** Creates the anterior border of the posterior cervical triangle.
  - Elevates, retracts, depresses, and superiorly rotates the scapula; innervated by the spinal accessory nerve (CN XI).

▼ **Clinically testing the sternocleidomastoid muscle.** To test the sternocleidomastoid muscle, the physician will place their hand on the patient's chin and instruct them to rotate his head to the opposite side against resistance. If acting normally, the patient's muscle can be seen and palpated. ▼

PREVERTEBRAL MUSCLES

The prevertebral muscles are located between the prevertebral fascia and the cervical vertebrae, and are organized as described below.

- **Longus colli and capitis muscles.** Course superiorly between the anterior aspects of the base of the skull and inferiorly between the cervical and upper thoracic vertebrae (Figure 25-2B). The longus colli and longus capitis muscles help stabilize the cervical vertebrae and flex the neck.
- **Scalene muscles.** The three scalene muscles (anterior, middle, and posterior scalenes), attach between cervical transverse processes and ribs 1 and 2 (Figure 25-2A and B).
  - **Actions.** Elevate the ribs during breathing and laterally flex the neck.
  - **Topography.** The scalene muscles are homologous to the muscles of the body wall in that neurovascular structures course between the middle layer (middle scalene) and the deep layer (anterior scalene). As a result, both the cervical and brachial plexuses exit the vertebral column between the anterior and middle scalenes.

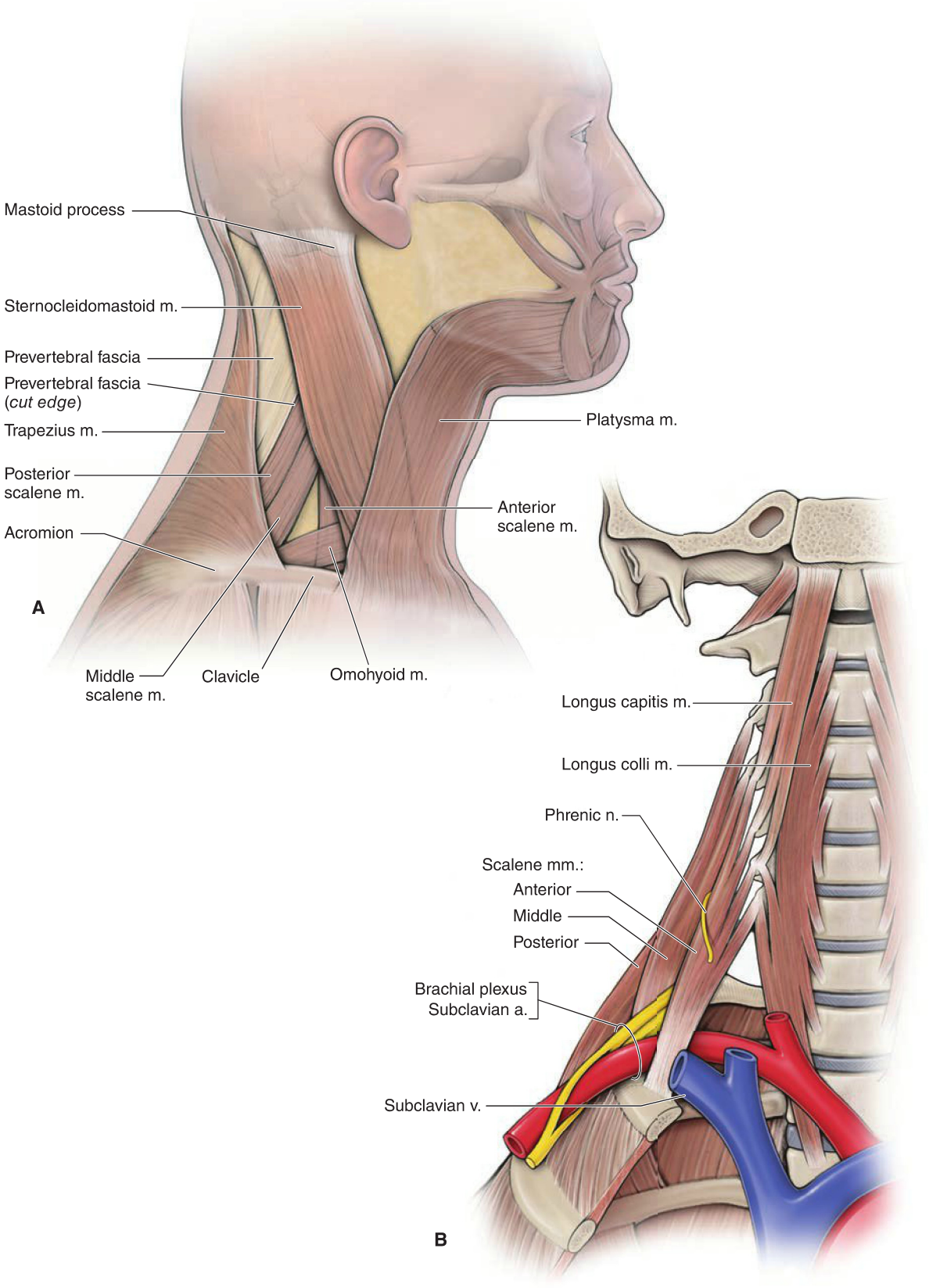

Figure 25-2: **A**. Muscles of the neck. **B**. Anterior view of the scalene and prevertebral muscles.

SUPRAHYOID MUSCLES

The suprahyoid muscles are located within the deep investing fascia (Figure 25-3A). These muscles raise the hyoid bone during swallowing because the mandible is stabilized.

- **Digastric muscle.** A two-bellied muscle attached to the mastoid process (posterior belly) and mandible (anterior belly) and connected by a central tendon at the hyoid bone. Because of the two bellies, the digastric muscle can raise the hyoid bone or open the mouth.
  - **Innervation.** Originates embryologically from both the first and second pharyngeal arches and as such has dual innervation (anterior belly from CN V-3 and posterior belly from CN VII).
- **Stylohyoid muscle.** Arises from the styloid process, bifurcates around the posterior belly of the digastric muscle, and inserts on the hyoid bone; elevates the hyoid bone and is innervated by CN VII.
- **Mylohyoid muscle.** Forms the floor of the mouth; elevates the floor of the mouth and is innervated by CN V-3.
- **Geniohyoid muscle.** Elevates the hyoid bone and is innervated by the cervical plexus (C1) (not shown in the illustration).

INFRAHYOID MUSCLES

Composed of four pairs of muscles inferior to the hyoid bone (hence the name) (Figure 25-3B). Each muscle is innervated by the ansa cervicalis from the cervical plexus (ventral rami C1–C3). Collectively, these muscles function to depress the hyoid bone and larynx during swallowing and speaking. They receive their names according to their attachments.

- **Sternothyroid muscle.** Sternum and thyroid cartilage.
- **Sternohyoid muscle.** Sternum and hyoid bone.
- **Thyrohyoid muscle.** Thyroid cartilage and hyoid bone.
- **Omohyoid muscle.** Superior border of the scapula (“omo” for shoulder) and hyoid bone.

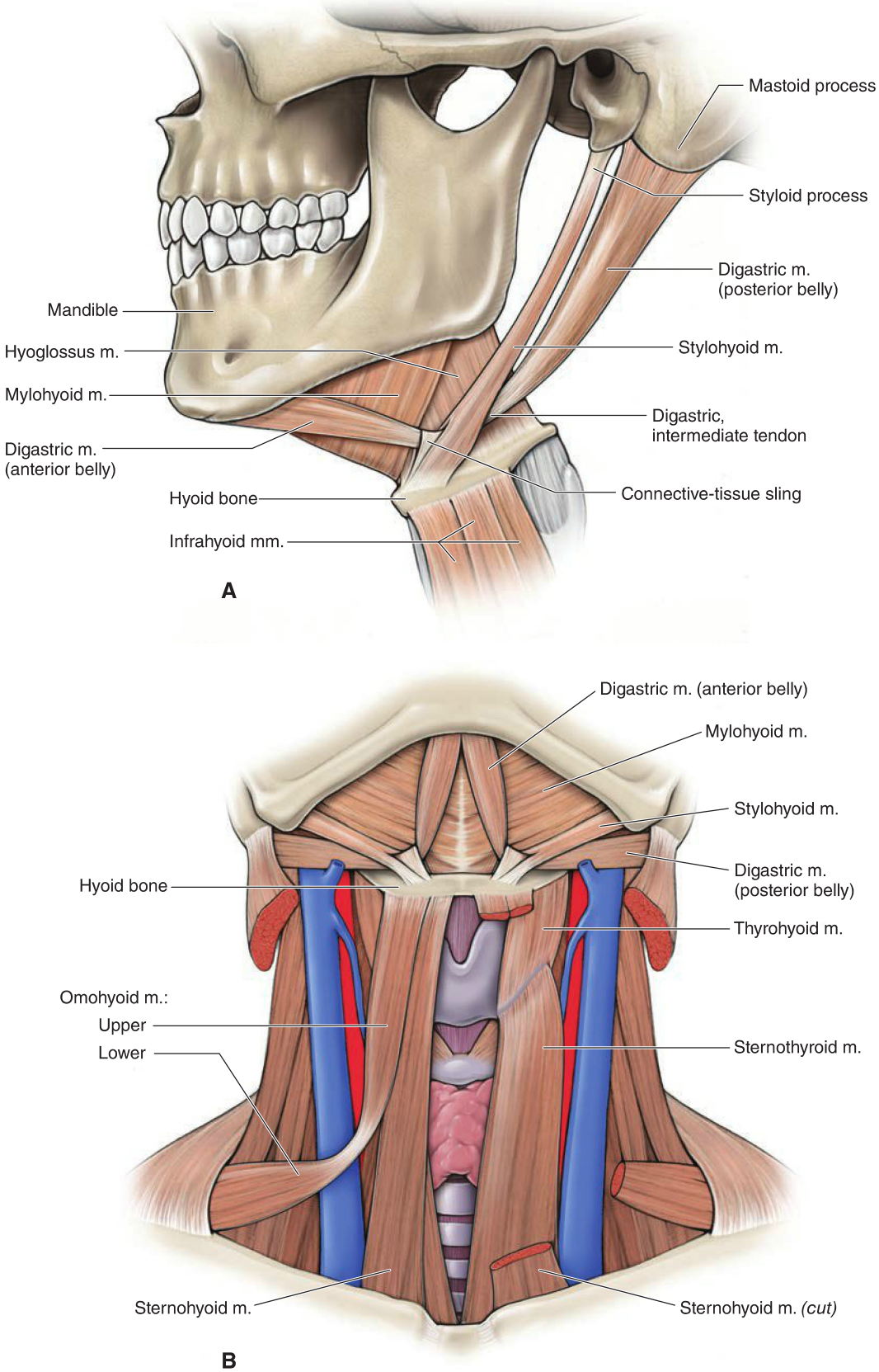

Figure 25-3: A. Lateral view of the floor of the mouth, highlighting the suprahyoid muscles (the geniohyoid muscle is not shown). **B**. Anterior view of a step dissection, highlighting the infrahyoid muscles.

VESSELS OF THE NECK

BIG PICTURE

Branches from the common carotid and subclavian arteries primarily supply the head and neck. The external and anterior jugular veins are the principal venous return for the neck, and the internal jugular vein provides venous return for the head.

SUBCLAVIAN ARTERY

The subclavian arteries branch from the brachiocephalic artery on the right side and directly from the aortic arch on the left side (Figure 25-4A). The subclavian arteries course between the anterior and middle scalene muscles, where each becomes the axillary artery at the lateral edge of the first rib. Branches of the subclavian artery are as follows:

- **Vertebral artery.** Arises from the first part of the subclavian artery, ascends between the anterior scalene and the longus coli muscles and on through the transverse foramina of C6 to C1. At the superior border of C1, the vertebral artery turns medially and crosses the posterior arch of C1, through the foramen magnum and supplies the posterior region of the brain.
- **Thyrocervical trunk.** A short trunk that arises from the first part of the subclavian artery. Branches of the thyrocervical trunk are the **suprascapular, transverse cervical**, and **inferior thyroid arteries**.

COMMON CAROTID ARTERY

The common carotid artery branches from the brachiocephalic artery on the right side and directly from the aortic arch on the left side. The common carotid artery ascends within the carotid sheath and bifurcates at the upper border of the thyroid cartilage into an internal and an external carotid artery (Figure 25-4A).

- **Carotid body.** A chemoreceptor at the bifurcation of the common carotid artery that monitors the partial pressure of oxygen, carbon dioxide, and pH. The carotid body is innervated by visceral sensory neurons from CN IX and the vagus nerve (CN X).

INTERNAL CAROTID ARTERY Ascends into the carotid canal at the base of the skull without giving any branches into the neck; supplies the anterior and middle regions of the brain, the orbit, and the scalp.

- **Carotid sinus.** A swelling in the origin of the internal carotid artery containing baroreceptors that monitor blood pressure. The carotid sinus is innervated by visceral sensory neurons from the glossopharyngeal nerve (CN IX).

EXTERNAL CAROTID ARTERY Supplies the neck and face through the following branches:

- **Superior thyroid artery.** Arises at the level of the hyoid bone and supplies the larynx and the thyroid gland.
- **Lingual artery.** Courses deep to the hyoglossus muscle and supplies the tongue.
- **Facial artery.** Ascends deep to the posterior belly of the digastric and stylohyoid muscles and the submandibular gland, where the facial artery hooks around the mandible along the anterior border of the masseter muscle; supplies the face.
- **Ascending pharyngeal artery.** Supplies the pharynx and palatine tonsils.
- **Occipital artery.** Supplies the occipital region of the scalp.
- **Posterior auricular artery.** Supplies the scalp posterior to the ear.
- **Maxillary artery.** Supplies numerous structures deep in the face.
- **Superficial temporal artery.** Arises as a terminal branch of the external carotid artery within the parotid gland and courses superficial to the zygomatic arch supplying the temporal region.

EXTERNAL JUGULAR VEIN

Formed by the union of the posterior auricular and posterior branch of the retromandibular veins (Figure 25-4B). The external jugular vein descends within the superficial fascia, deep to the platysma muscle. After crossing the sternocleidomastoid muscle, the external jugular vein pierces the deep investing fascia posterior to the clavicular head and enters the subclavian vein.

- **Retromandibular vein.** Formed by the superficial temporal and maxillary veins within the parotid gland; divides into anterior and posterior divisions. The anterior division joins the facial vein to form the common facial vein. The posterior division contributes to the external jugular vein.

INTERNAL JUGULAR VEIN

Originates at the jugular foramen by the union of the sigmoid and inferior petrosal sinuses and serves as the principal drainage of the skull, brain, superficial face, and parts of the neck. After exiting the skull with CNN IX, X, and XI via the jugular foramen, the internal jugular vein descends within the carotid sheath and joins with the subclavian vein to form the brachiocephalic vein.

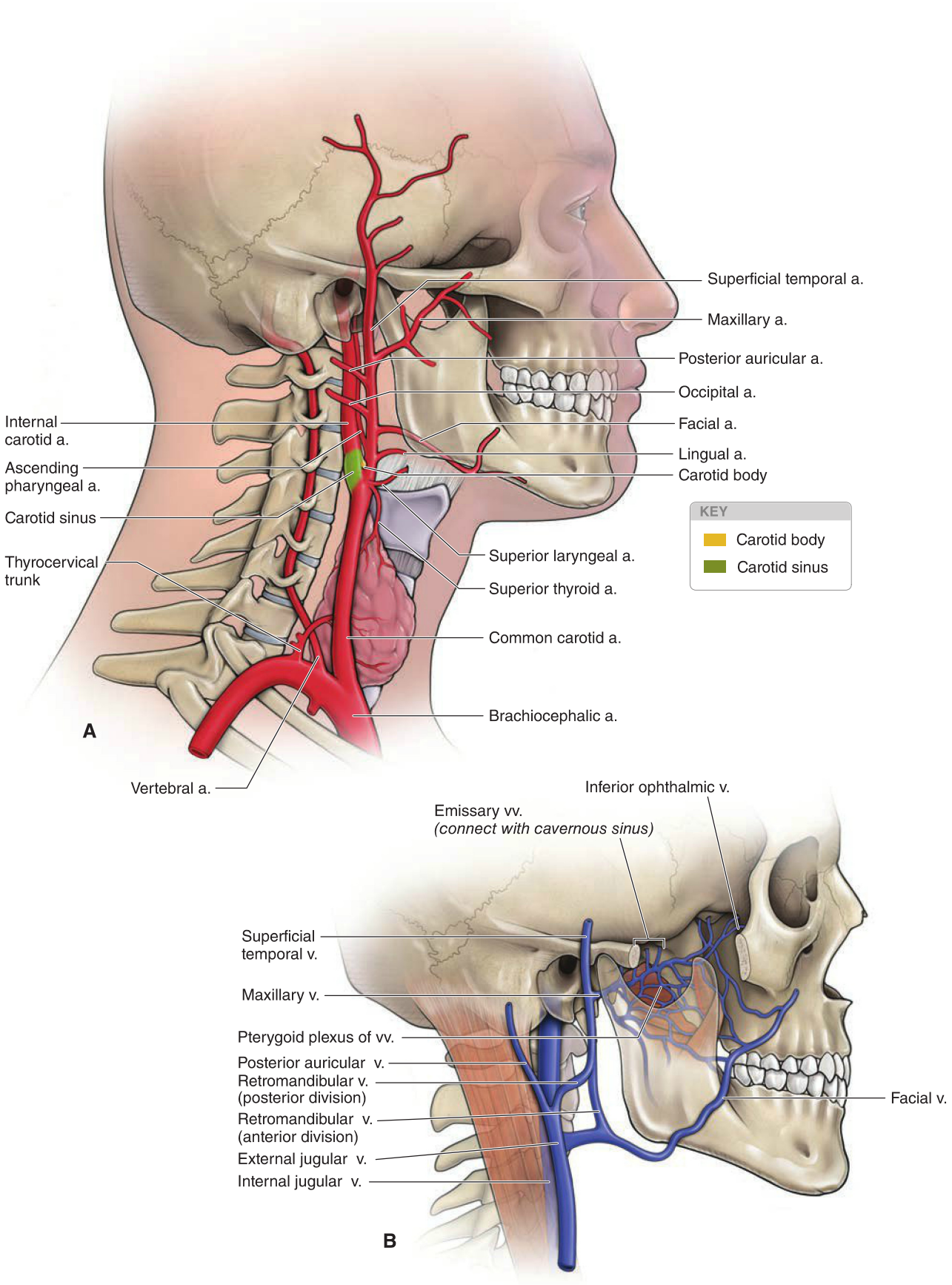

Figure 25-4: **A**. The principal arteries of the head and neck. **B**. The principal venous drainage of the head and neck.

INNERVATION OF THE NECK

BIG PICTURE

The cervical plexus of nerves is responsible for much of the sensory and motor innervation of the neck. CNN VII, IX, X, XI, and XII also play important roles. In addition, sympathetic innervation of the neck and head is via the cervical sympathetic trunk.

CERVICAL PLEXUS

The cervical plexus of nerves arises from the ventral rami of cervical nerves C1 to C4 and exits the vertebral column between the anterior and posterior scalene muscles. Branches of the cervical plexus are as follows (Figure 25-5A):

- **Sensory branches.** Pierce the prevertebral fascia at the central region of the posterior border of the sternocleidomastoid muscle, serving various regions of the skin of the neck. The cutaneous branches of the cervical plexus and their cutaneous distribution are as follows:
  - **Lesser occipital nerve (C2).** Lower, lateral region of the scalp.
  - **Great auricular nerve (C2–C3).** External ear and skin overlying the parotid gland and angle of the mandible (this is the only area of the face not supplied by CN V).
  - **Transverse cervical nerve (C2–C3).** Anterior part of the neck.
  - **Supraclavicular nerve (C3–C4).** Lower portion of the neck, upper part of the chest, and the shoulder.
- **Motor branches.** The deep branches of the cervical plexus innervate muscles.
  - **Ansa cervicalis (C1–C3).** A loop of motor nerves from the cervical plexus that is superficial to the IJV within the carotid triangle; the superior limb arises from the C1 ventral ramus and merges with the inferior root, which arises from the C2–C3 ventral rami.
    - Branches innervate the infrahyoid muscles (sternothyroid, sternohyoid, and omohyoid).
  - **Phrenic nerve (C3–C5).** Descends vertically along the anterior scalene muscle en route to the diaphragm; contains motor and sensory components:
    - **Motor.** Innervates the diaphragm. ("C3, 4 and 5, keep the diaphragm alive" is a pneumonic to remember the phrenic nerve spinal nerve levels.)
    - **Sensory.** General sensory innervation of mediastinal parietal pericardium, parietal pleura, and diaphragmatic parietal peritoneum.

CRANIAL NERVES IN THE NECK

The following cranial nerves travel through the neck (Figure 25-5B):

- **Glossopharyngeal nerve (CN IX).** CN IX exits the skull with CNN X and XI, via the jugular foramen, and provides visceral sensory innervation to the **carotid sinus** (baroreceptor) and **carotid body** (chemoreceptor) monitoring blood pressure.
- **Vagus nerve (CN X).** CN X exits the skull with CN IX and CN XI, via the jugular foramen, and descends within the carotid sheath; branches in the neck are as follows:
  - **Superior laryngeal nerve.** Divides into the external laryngeal nerve (motor to inferior pharyngeal constrictor and cricothyroideus muscles) and internal laryngeal nerve (sensory superior to the vocal folds).
  - **Recurrent laryngeal nerve.** Motor innervation to laryngeal muscles.
  - **Nerve to carotid body.** Visceral sensory innervation from the **carotid body** (chemoreceptor) for monitoring blood oxygen, carbon dioxide, and pH.
- **Spinal accessory nerve (CN XI).** Exits the jugular foramen with CN IX and CN X, courses along the floor of the posterior triangle and supplies the sternocleidomastoid and trapezius muscles.

SYMPATHETIC NERVES OF THE NECK

The sympathetic trunk (chain) ascends from the thorax into the cervical region along the longus colli and longus capitis muscles and receives only gray rami communicantes (no white rami) (Figure 25-5B). The sympathetic trunk innervates the sweat and sebaceous glands, blood vessels, arrector pili, dilator pupillae, and superior tarsal muscles.

The sympathetic trunk gives rise to the following three cervical ganglia:

- **Inferior cervical ganglion.** Fuses with the first thoracic paravertebral ganglion to become the cervicothoracic (stellate) ganglion at the level of rib 1; gives rise to cardiopulmonary splanchnic nerves.
- **Middle cervical ganglion.** Lies at the C6 vertebral level; gives rise to the cardiopulmonary splanchnic nerves.
- **Superior cervical ganglion.** Lies anterior to the C1–C2 transverse processes, between the internal carotid artery and the longus capitis muscle; gives rise to the internal and external carotid plexuses and cardiopulmonary splanchnic nerves.

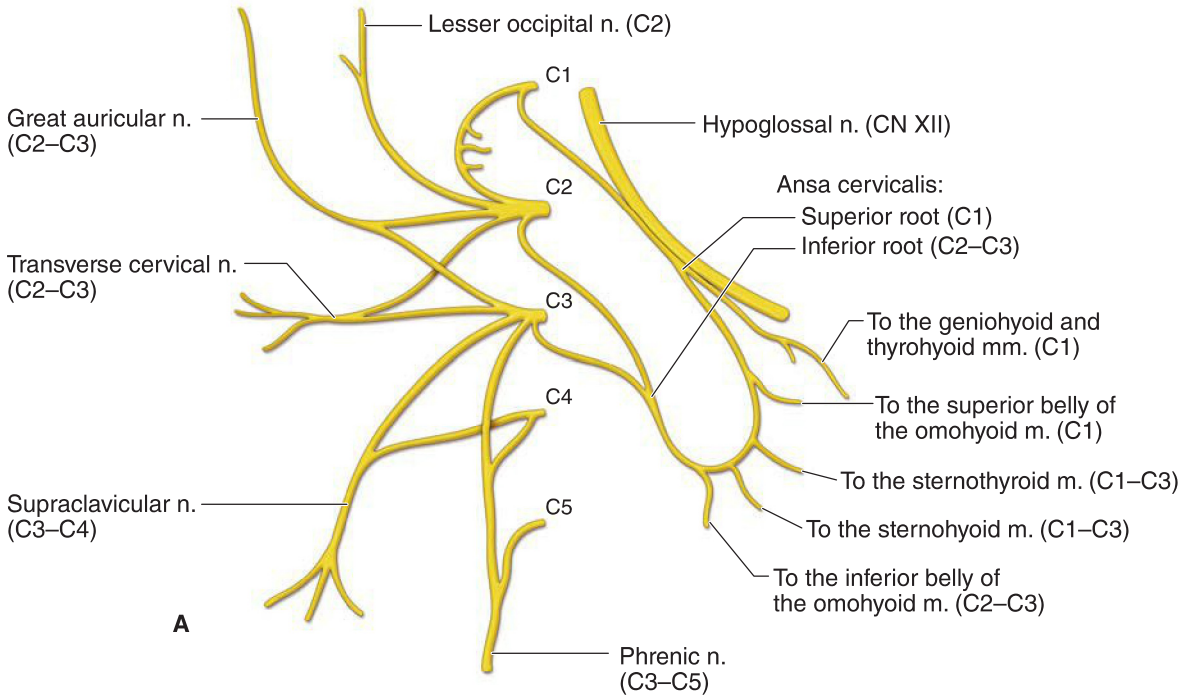

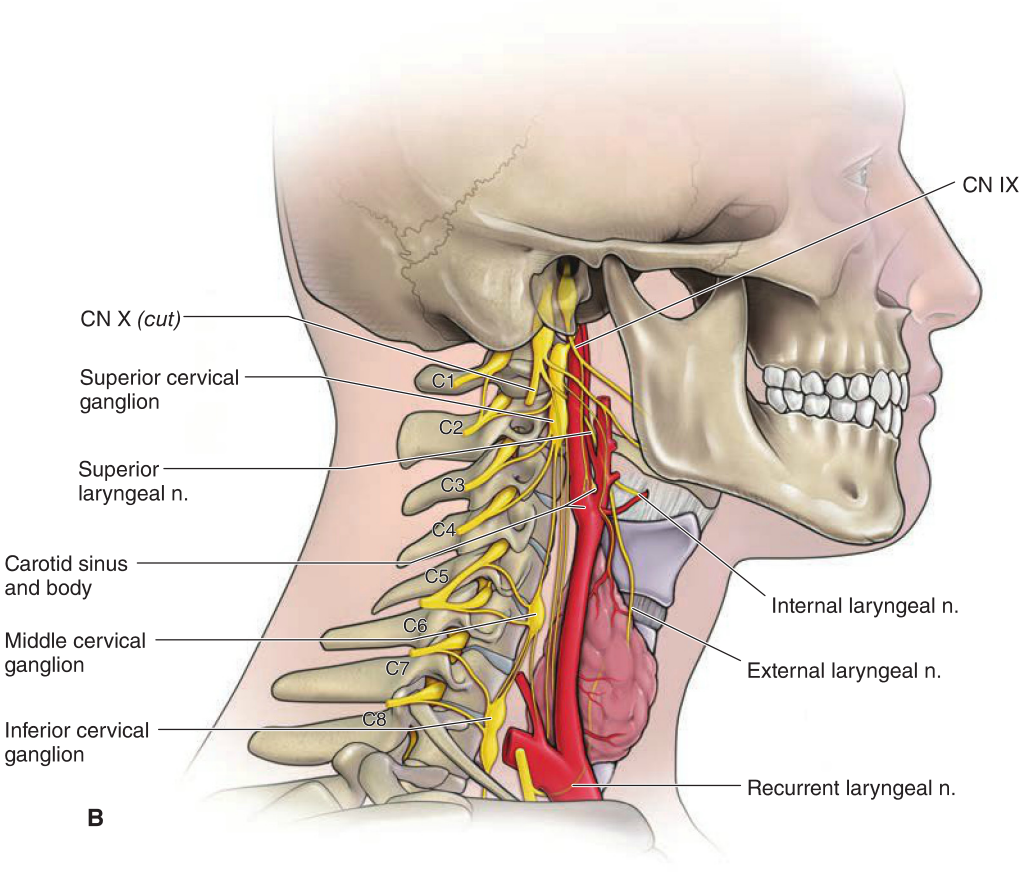

Figure 25-5: **A**. Cervical plexus. **B.** Cranial nerves and autonomics of the neck.

This page intentionally left blank

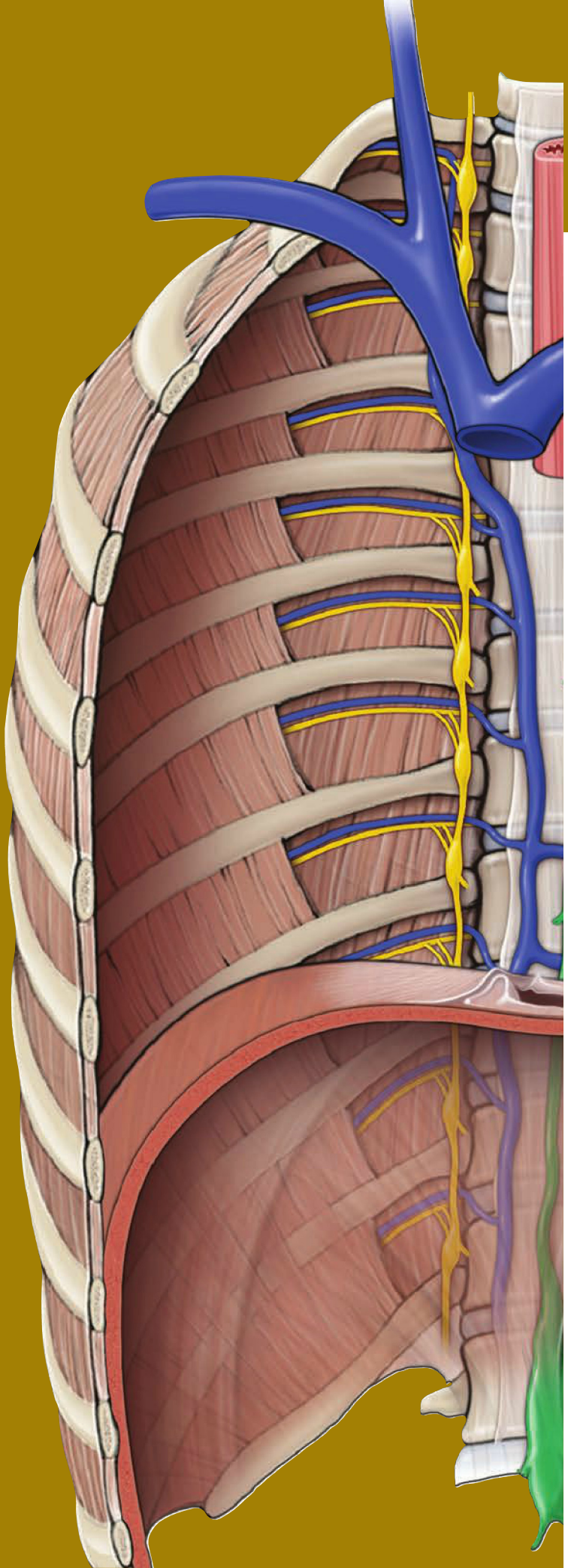

CHAPTER 26

VISCERA OF THE NECK

Visceral Layers of the Neck 278

VISCERAL LAYERS OF THE NECK

BIG PICTURE

The visceral region of the neck has three layers. From anterior to posterior, the layers are an endocrine layer (the thyroid and parathyroid glands), a respiratory layer (the trachea and larynx), and an alimentary layer (the pharynx and esophagus).

THYROID GLAND

The thyroid gland is an endocrine gland with two lobes connected by a central **isthmus**. The thyroid gland is located below the thyroid cartilage overlying the second through the fourth tracheal rings, all enclosed within the pretracheal fascia (Figure 26-1A–C).

- **Thyroid hormones (T3 or T4).** Regulate basal metabolic rate, increase body temperature and blood flow, and regulate growth rate.
- **Calcitonin.** Decreases blood calcium concentration.

Vessels of the thyroid gland are as follows:

- **Superior thyroid artery.** Arises from the external carotid artery and courses with the superior laryngeal nerve (CN X).
- **Inferior thyroid artery.** Arises from the thyrocervical trunk and is near the recurrent laryngeal nerve (CN X).
- **Middle and superior thyroid veins.** Generally, middle and superior thyroid veins course anterior to the common carotid artery and drain into the internal jugular vein.
- **Inferior thyroid veins.** Varied number of vessels that drain into the brachiocephalic veins.

Goiter. A goiter is a pathologic enlargement of the thyroid gland. Consequently, a goiter presents as a swelling in the anterior part of the neck, inferior to the thyroid cartilage. A goiter is usually caused by iodine deficiency. Iodine is necessary for the synthesis of thyroid hormones; when there is a deficiency of iodine, the gland is unable to produce thyroid hormones. When the levels of thyroid hormones decrease, the pituitary gland secretes more thyroid-stimulating hormone, which stimulates the thyroid gland to produce more faulty thyroid hormone, causing the gland to enlarge.

PARATHYROID GLANDS

The parathyroid glands are four small endocrine glands located on the posterior surface of the thyroid (usually two on each side) (Figure 26-1B).

- **Parathyroid hormone.** The major function of the parathyroid gland is the homeostatic maintenance of calcium and phosphate levels to ensure proper functioning of the muscular and nervous systems. Parathyroid hormone increases bone resorption of calcium, which increases blood calcium and phosphate concentration. Parathyroid hormone is an antagonist to calcitonin secreted by the thyroid.
- **Embryological origin.** Derived from the epithelium of the third and fourth branchial pouches.

TRACHEA AND ESOPHAGUS

At the C6 vertebral level the trachea extends inferiorly from the cricoid cartilage (Figure 26-1A–C).

- **Innervation.** Sympathetic nerves from the T1 to T4 spinal nerve levels cause airway smooth muscle relaxation and thus dilation of the airways, whereas parasympathetic innervation from the recurrent laryngeal nerves (CN X) causes airway smooth muscle constriction and thus narrowing of the airways.
- **Topography.** At the level of the jugular notch of the manubrium the trachea is halfway between the sternum and the vertebral column. The esophagus is posterior to the trachea.

Tracheostomy. For long-term access to the trachea, a tracheostomy is performed. A tracheostomy is a surgical incision in the trachea below the thyroid isthmus, providing an opening into the airway. During a tracheostomy, the inferior thyroid veins anterior to the trachea must be avoided.

LYMPHATICS

All lymphatic vessels throughout the body return their lymph to the blood stream by either the thoracic or the right lymphatic ducts. Both lymphatic ducts drain lymph into the subclavian veins.

- **Thoracic duct.** This duct is a major lymphatic vessel that begins in the abdomen and passes superiorly through the thorax entering the root of the neck, on the left side. Arching laterally, the duct passes deep to the carotid sheath and courses inferiorly to terminate in the junction between the left internal jugular and the subclavian veins (Figure 26-1A).
- **Right lymphatic duct.** Lymphatic vessels from the right side of the thorax, upper limb, neck, and head connect together to form the right thoracic duct, which drains into the junction between the right internal jugular and subclavian veins.

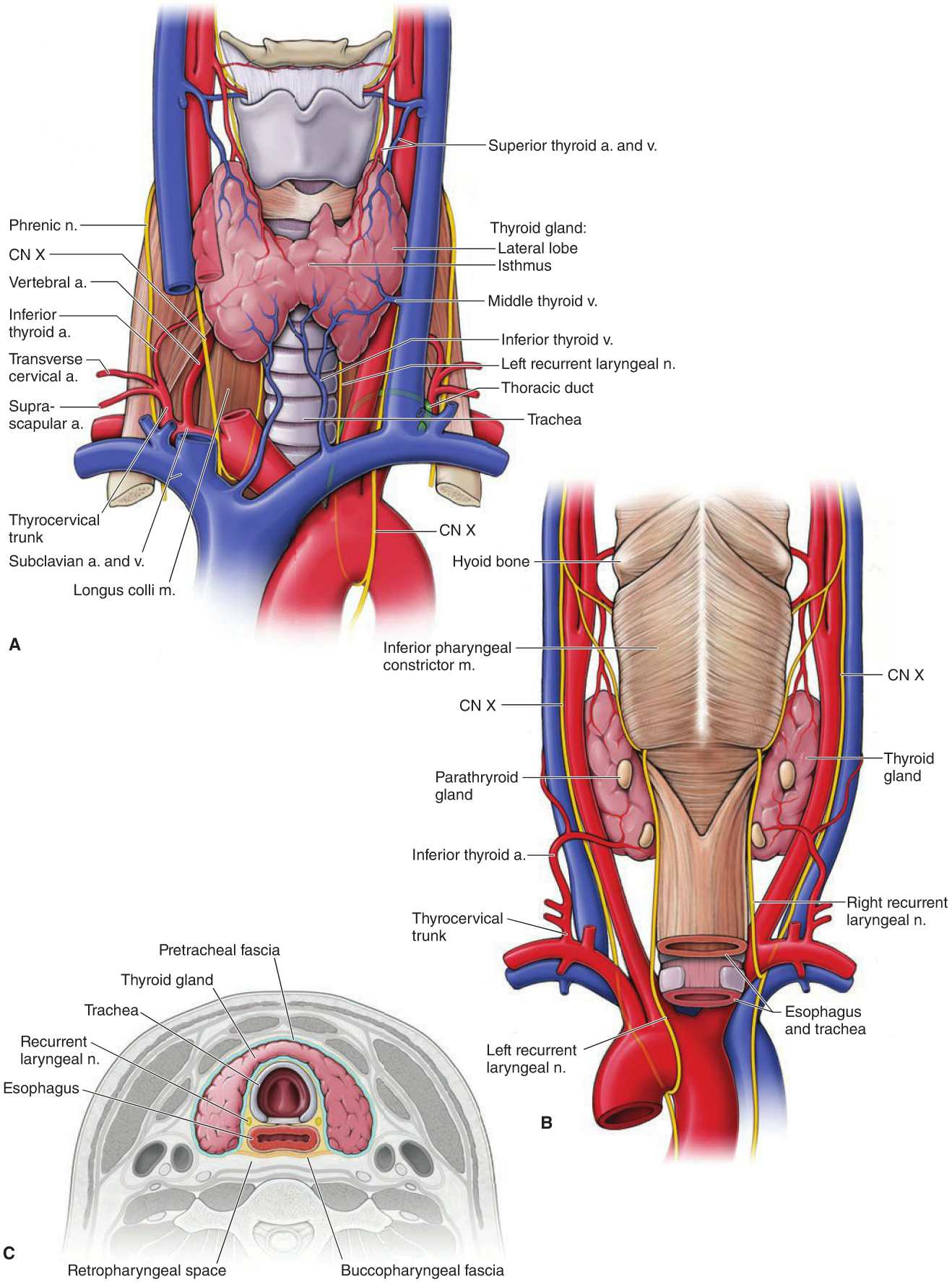

Figure 26-1: Anterior (**A**) and posterior (**B**) views of the visceral triangle of the neck. **C**. Cross-section through the thyroid gland.

This page intentionally left blank

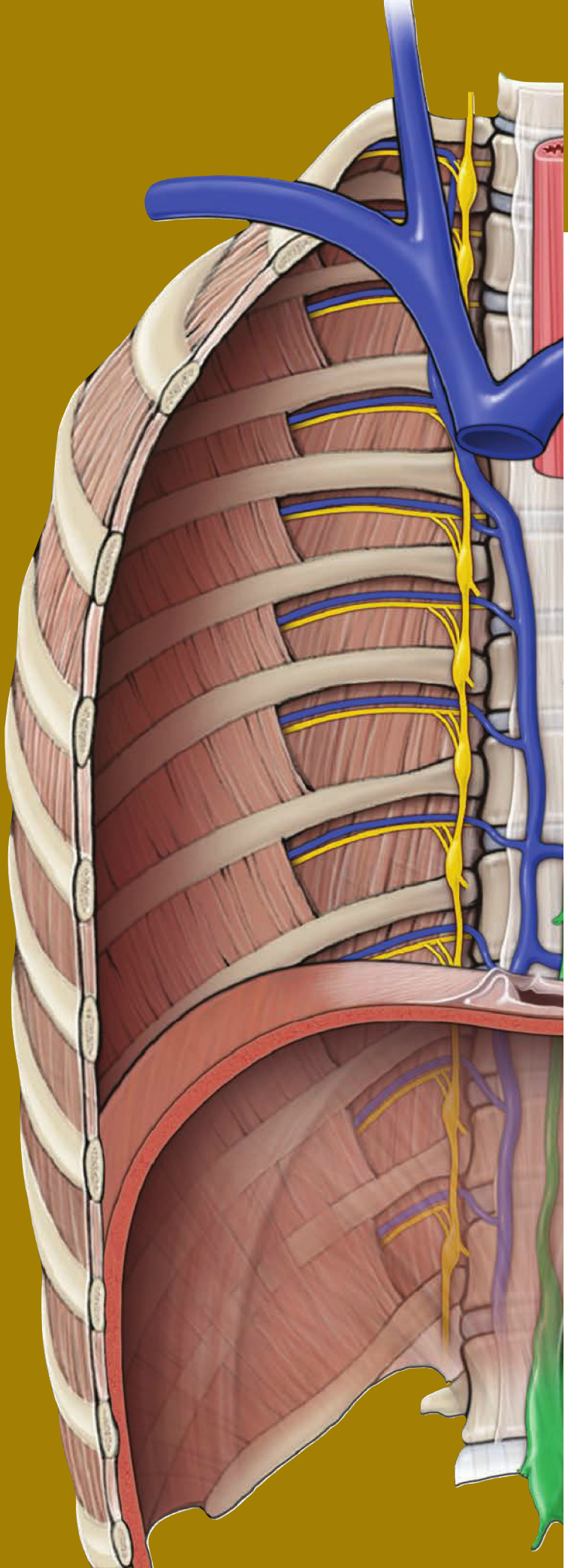

CHAPTER 27

PHARYNX

Overview of the Pharynx 282
Functions of the Pharynx 284
Neurovascular Supply of the Pharynx. 286

OVERVIEW OF THE PHARYNX

BIG PICTURE

The pharynx is a funnel-shaped, fibromuscular tube that extends from the base of the skull to the cricoid cartilage, where the pharynx continues as the esophagus. The pharynx serves as a common pathway for food and air.

SUBDIVISIONS OF THE PHARYNX

The pharynx is classically divided into three regions based on location: the nasopharynx, oropharynx, and laryngopharynx (Figure 27-1A–C).

NASOPHARYNX The nasopharynx is posterior to the nasal cavity and superior to the soft palate. During swallowing, the soft palate elevates and the pharyngeal wall contracts anteriorly to form a seal, preventing food from refluxing into the nasopharynx and nose. When we laugh, this sealing action can fail, and fluids that are being swallowed while we laugh can end up in the nasal cavity.

- **Choanae.** Arched openings that enable communication between the nasal cavity and nasopharynx.
- **Auditory tubes (**Pharyngotympanic/Eustachian tubes). Open into the lateral walls of the nasopharynx and communicate with the middle ear. The auditory tubes enable middle ear pressure to equalize with atmospheric pressure.
  - **Torus tubarius.** The cartilaginous opening of the auditory tube that opens into the nasopharynx. The salpingopharyngeal fold containing the salpingopharyngeal muscle arises from the lower part of the torus tubarius.
- **Pharyngeal tonsil (adenoids).** Lymphatic tissue in the posterosuperior nasopharynx; traps and destroys pathogens that enter from the air (Figure 27-1B).

Tonsillitis. When the pharyngeal tonsils (adenoids) are infected and swollen, they can completely block airflow through the nasal cavity so that breathing through the nose requires an uncomfortable amount of effort. As a result, inhalation occurs through an open mouth. Surgical removal of the adenoids (adenoidectomy) may be necessary if infections, earaches, or breathing problems become chronic.

OROPHARYNX The oropharynx is the region of the pharynx located between the soft palate and the epiglottis, and communicates with the oral cavity.

- **Palatoglossal arches.** Arches formed by the palatoglossal muscles; mark the boundary between the oral cavity anteriorly and the oropharynx posteriorly.
- **Palatine tonsils.** Situated within the palatoglossal arches and are considered mucosa-associated lymphoid tissues (MALT for short). They help protect the body from the entry of infectious material through mucosal sites. As a consequence, palatine tonsils may result in frequent infections.

LARYNGOPHARYNX The laryngopharynx extends between the epiglottis and the cricoid cartilage, with the larynx forming the anterior wall. The laryngopharynx serves as a common passageway for food and air (Figure 27-1B and C). The laryngopharynx communicates:

- Anteriorly with the larynx, where air is conducted in and out of the lungs during breathing.
- Posteriorly with the esophagus, where food and fluids to the stomach pass. During swallowing, food has the "right of way" and air passage stops temporarily.

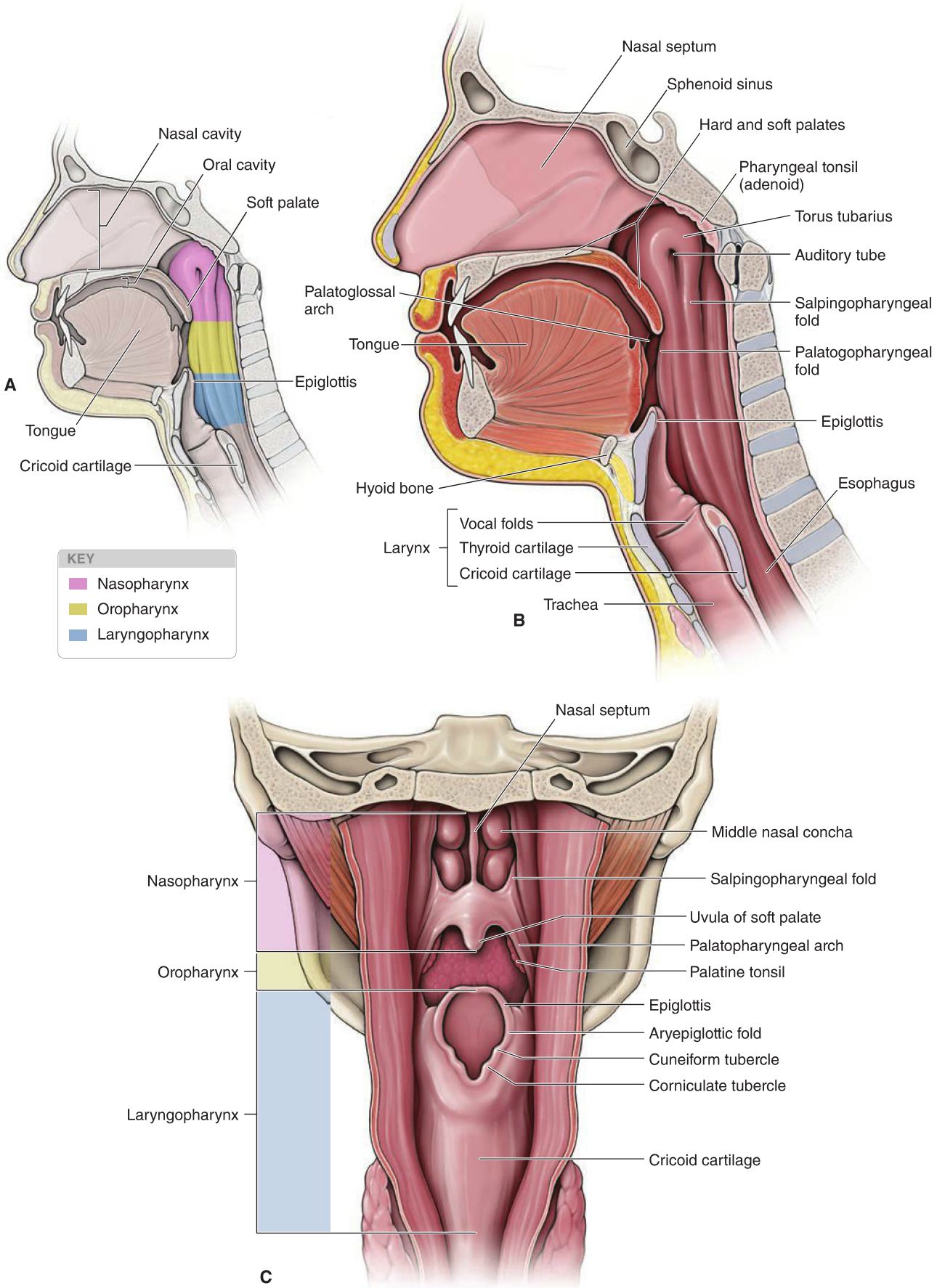

Figure 27-1: **A**. Regions of the pharynx. **B**. Sagittal section of the head. **C**. Posterior view of the pharynx (midsagittal incision through the pharyngeal constrictor muscles).

FUNCTIONS OF THE PHARYNX

BIG PICTURE

The pharynx is composed of skeletal muscle that is lined internally by a mucous membrane. Pharyngeal muscles aid in swallowing and speaking.

PHARYNGEAL CONSTRICTORS

The pharyngeal constrictor muscles form the lateral and posterior walls of the pharynx and are attached posteriorly to the **median pharyngeal raphe**. The median pharyngeal raphe extends downward from the pharyngeal tubercle, on the base of the occipital bone anterior to the foramen magnum, and blends inferiorly with the posterior wall of the laryngopharynx and esophagus. The **pharyngobasilar fascia** separates the mucosa and the muscle layer, and blends with the periosteum of the base of the skull.

The pharyngeal constrictors are arranged as the following three overlapping muscles (Figure 27-2A and B):

- **Superior pharyngeal constrictor.** Attaches to the medial pterygoid plate, the pterygomandibular raphe, and the lingula of the mandible.
  - The levator veli palatini muscle, the auditory (Eustachian) tube, and the ascending palatine artery course between the floor of the sphenoid bone and the superior pharyngeal constrictor.
- **Middle pharyngeal constrictor.** Attaches to the side of the body and the lesser horn of the hyoid bone.
  - The stylopharyngeus muscle, CN IX, and the stylohyoid ligament course between the superior and the middle pharyngeal constrictors.
- **Inferior pharyngeal constrictor.** Attaches to the lateral surface of the thyroid and cricoid cartilages. The lowest fibers of the inferior pharyngeal constrictor are thought to constitute a **cricopharyngeus muscle**, which must relax if food is to enter the esophagus.
  - The internal laryngeal nerve and the superior laryngeal artery and vein course between the middle and inferior pharyngeal constrictors.

The pharyngeal constrictor muscles narrow the pharynx when swallowing and are activated in a sequence, from top to bottom, to propel food toward the esophagus.

ACCESSORY PHARYNGEAL MUSCLES

Three small accessory pharyngeal muscles elevate the larynx and pharynx when swallowing is initiated. These muscles have separate origins and insert onto the posterior part of the pharynx (Figure 27-2A and B). The names of these muscles identify their origins and insertions.

- **Stylopharyngeus muscle.** Attaches to the styloid process (temporal bone) and into the pharyngeal wall between the superior and middle pharyngeal constrictors.
  - **Action.** Elevates the pharynx to permit passage of a bolus of food.
  - **Innervation.** Glossopharyngeal nerve (CN IX); the only muscle derived from the third pharyngeal arch.
- **Palatopharyngeus muscle.** Attaches to the soft and hard palates and the pharyngeal wall.
  - **Action.** Contraction pulls the pharynx upward and over the bolus of food during swallowing.
  - **Innervation.** Vagus nerve (CN X).
- **Salpingopharyngeus muscle.** Attaches to the auditory tube and the pharyngeal wall.
  - **Action.** Widens the opening of the pharyngotympanic tube during swallowing, which equalizes the pressure between the auditory canal and the nasopharynx.
  - **Innervation.** Vagus nerve (CN X).

SWALLOWING

The **stages of swallowing** (deglutition) are as follows (Figure 27-2C):

1. The tongue pushes the bolus of food back toward the oropharynx.
2. The palatoglossus and palatopharyngeus muscles contract to squeeze the bolus backward into the oropharynx. The tensor veli palatini and levator veli palatini muscles elevate and tense the soft palate to close the entrance into the nasopharynx.
3. The palatopharyngeus, stylopharyngeus, and salpingopharyngeus muscles elevate the walls of the pharynx in preparation to receive the food. The suprahyoid muscles elevate the hyoid bone and the larynx to close the opening into the larynx, thus preventing the food from entering the respiratory passageways.
4. The sequential contraction of the superior, middle, and inferior pharyngeal constrictor muscles moves the food through the oropharynx and the laryngopharynx into the esophagus, where the bolus of food is propelled via peristalsis.

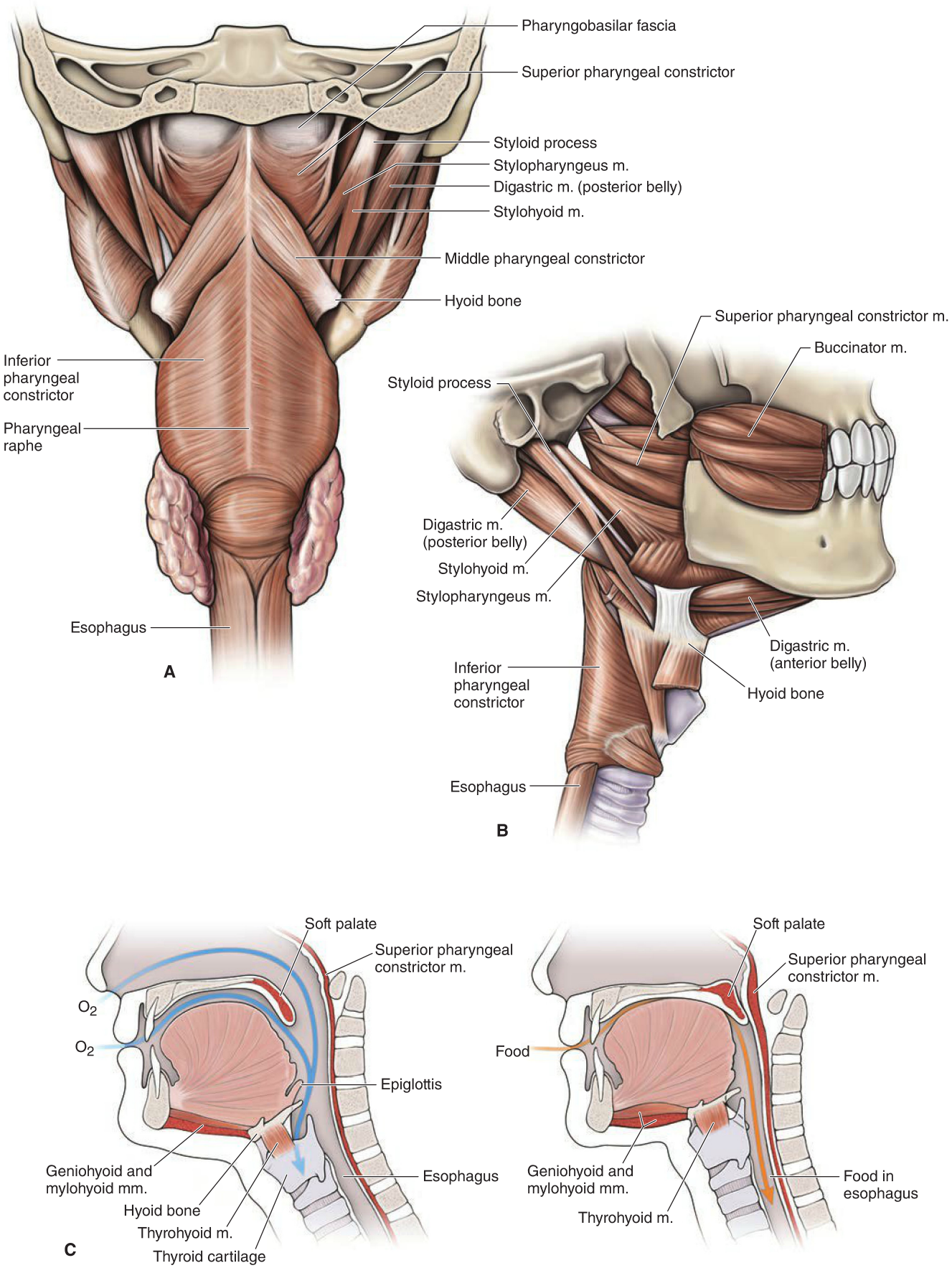

Figure 27-2: Posterior (**A**) and lateral (**B**) views of the muscles of the pharynx. **C**. Swallowing mechanism.

NEUROVASCULAR SUPPLY OF THE PHARYNX

BIG PICTURE

The mucosa of the pharynx receives its blood supply from branches of the external carotid artery and sensory innervation from CNN V-2, IX, and X. The motor supply to the pharynx is primarily from CN X, with the exception of the stylopharyngeus muscle, which is CN IX.

VASCULAR SUPPLY OF THE PHARYNX

The arterial supply of the pharynx is through the following arteries (Figure 27-3A):

- **Pharyngeal artery.** Arises from the maxillary artery, courses through the palatovaginal canal, to supply the nasopharynx.
  - Arises from the facial artery, ascends along the pharynx, and courses over the superior pharyngeal constrictor muscle; gives rise to the **tonsilar artery**, which penetrates through the superior pharyngeal constrictor muscle to supply the palatine tonsil.
- **Ascending pharyngeal artery.** Arises from the external carotid artery and courses with the ascending palatine artery.

The venous drainage of the pharynx includes tributaries of the internal and external jugular veins.

PHARYNGEAL PLEXUS OF NERVES

Pharyngeal nerves from CNN IX and X and a small contribution from CN V-2 form the pharyngeal plexus (Figure 27-3B). The plexus lies along the middle pharyngeal constrictor muscle and is responsible for sensory and motor innervation.

SENSORY INNERVATION The three regions of the pharynx each receive a unique cranial nerve supply.

- **Nasopharynx.** Sensory neurons travel from the mucosa of the nasopharynx, through the palatovaginal canal, and on through the pterygopalatine ganglion, to CN V-2, through the foramen rotundum into the pons.
- **Oropharynx.** Pharyngeal branches from glossopharyngeal nerve (CN IX) course into the pharyngeal plexus and back to the medulla.
- **Laryngopharynx.** Pharyngeal branches from vagus nerve (CN X) course into the pharyngeal plexus and back to the medulla.

MOTOR INNERVATION The pharyngeal muscles (superior constrictor, middle constrictor, inferior constrictor, salpingopharyngeus, and palatopharyngeus) are innervated by the vagus nerve (CN X) via the pharyngeal plexus. CN X originates in the brainstem, traverses the jugular foramen, and gives rise to pharyngeal motor branches to the pharyngeal muscles.

- **Stylopharyngeus muscle.** Innervated by the glossopharyngeal nerve (CN IX), which arises from the medulla, traverses the jugular foramen, and innervates the stylopharyngeus muscle via the pharyngeal plexus (only pharyngeal muscle not innervated by CN X).

▼ **Gag reflex.** The gag reflex tests both the sensory and motor components of CNN IX and X, respectively as well as the medulla. This reflex is evoked by touching the soft palate. Sensory neurons within CN IX relay this sensation to the spinal trigeminal nucleus in the medulla. Interneurons synapse with the nucleus ambiguus, which evokes a motor response through branchial motor neurons in the vagus nerve. The vagus nerve causes contraction of the pharyngeal muscles. Absence of the gag reflex can be symptomatic of CN IX, CN X, or medulla injury. However, a small percentage of the population does not respond to the gag reflex even though their CN IX, CN X, and medulla are normal. ▼

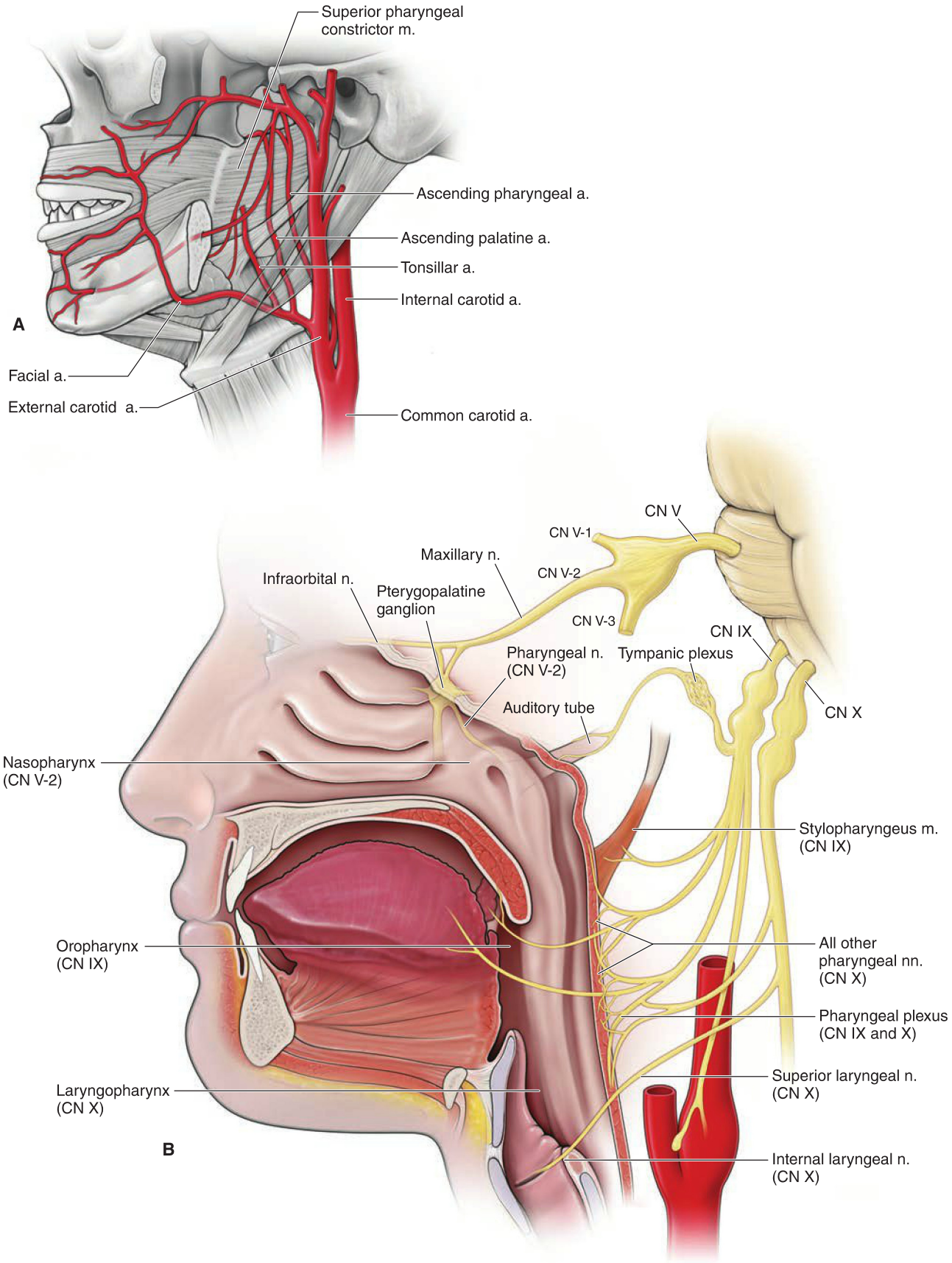

Figure 27-3: **A**. Vascular supply of the pharynx. **B**. Innervation of the pharynx.

This page intentionally left blank

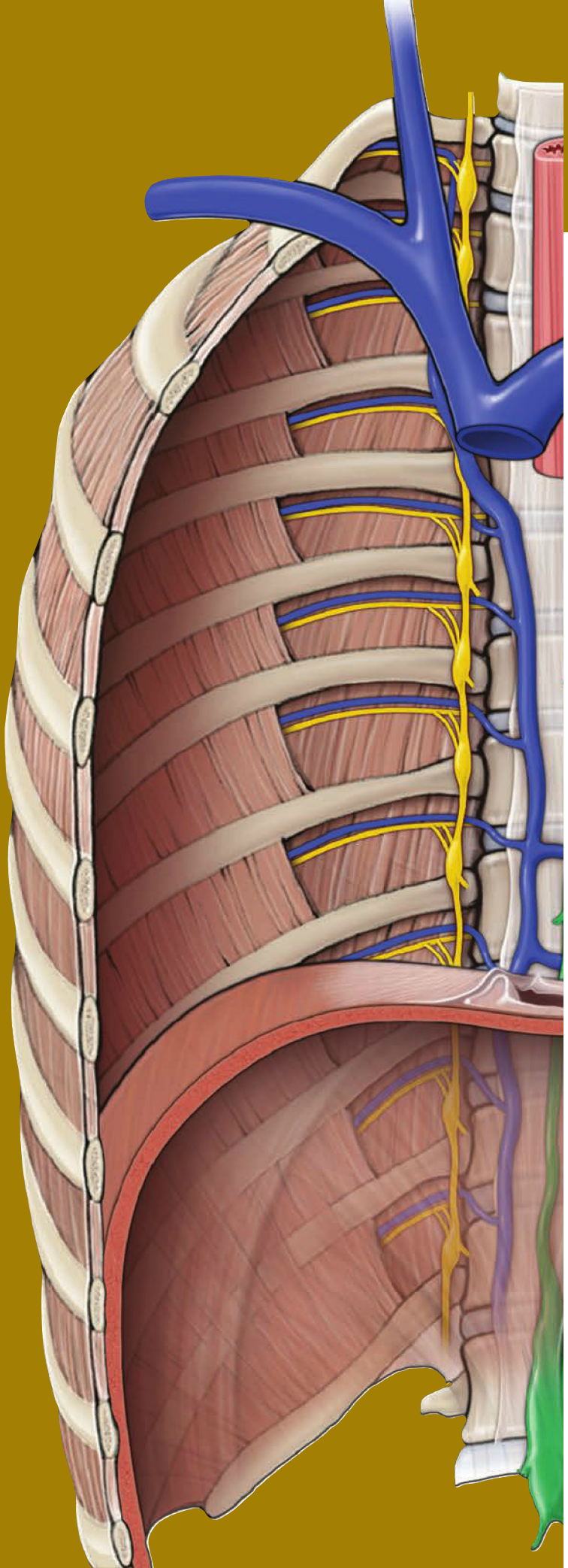

CHAPTER 28

LARYNX

Laryngeal Framework 290
Function of the Larynx 292
Vascular Supply and Innervation of the Larynx 294
Study Questions 296
Answers 298

LARYNGEAL FRAMEWORK

BIG PICTURE

The larynx, which is continuous with the laryngopharynx superiorly and trachea inferiorly, provides an open airway and acts as a switching mechanism to route air and food into the proper channels. The larynx, commonly known as the voice box, is supported by the hyoid bone, and provides the cartilaginous framework for muscle attachments and vocal folds, which vibrate to produce sound.

HYOID BONE

The hyoid bone consists of a body, two greater horns, and two lesser horns, and is the only bone that does not articulate with another bone. The hyoid bone is U-shaped and is suspended from the tips of the styloid processes of the temporal bones by the **stylohyoid ligaments** (Figure 28-1A and C). The hyoid bone is connected to the thyroid cartilage by the thyrohyoid membrane and supported by the suprahyoid and infrahyoid muscles and by the middle pharyngeal constrictor muscle. In addition, the hyoid bone supports the root of the tongue.

LARYNGEAL CARTILAGES

The framework of the larynx is an intricate arrangement of nine cartilages connected by membranes and ligaments (Figure 28-1A–C).

- **Thyroid cartilage.** Lies inferior to the hyoid bone and forms a midline elevation, called the **laryngeal prominence** ("Adam's apple"). The thyroid cartilage typically is larger in males than in females because the male sex hormones stimulate its growth during puberty.
  - **Superior horn.** Attaches to the tip of the greater horn of the hyoid bone.
  - **Inferior horn.** Articulates with the cricoid cartilage, forming the cricothyroid joint.
  - **Thyrohyoid membrane.** Stretches between the thyroid cartilage and the hyoid bone. The superior laryngeal vessels and the internal laryngeal nerve pierce the membrane en route to providing vascular supply and sensory information, respectively, to the mucosa superior to the vocal folds.
- **Cricoid cartilage.** Shaped like a signet ring (the only complete ring of cartilage in the airways). The lower border marks the inferior limits of the larynx and pharynx. Provides attachments for laryngeal muscles, cartilages, and ligaments involved in opening and closing of the airway to produce sound.
  - **Cricothyroid ligament.** Arises inferiorly from the cricoid cartilage and inserts superiorly in thyroid cartilage and vocal processes of the arytenoid cartilages.
- **Epiglottis.** A spoon-shaped structure consisting of elastic cartilage and is positioned posterior to the root of the tongue. The lower end of the epiglottis is attached to the deep surface of the thyroid cartilage.
  - **Function.** When only air is flowing into the larynx, the inlet to the larynx is open wide, with the free edge of the epiglottis projecting superiorly and anteriorly. During swallowing, the larynx is pulled superiorly and the epiglottis tips posteriorly to cover the laryngeal inlet. As a result, the epiglottis acts as a deflector to keep food out of the larynx (and trachea) during swallowing.
- **Arytenoid cartilages.** Shaped like a pyramid with their base articulating with the cricoid cartilage. Paired arytenoid cartilages each have the following:
  - **Vocal process.** Gives attachment to the vocal ligaments and vocalis muscle.
  - **Muscular process.** Gives attachment to the thyroarytenoid, lateral cricoarytenoid, and posterior cricoarytenoid muscles.
- **Cuneiform and corniculate cartilages.** These tiny paired cartilages lie on the apices of the arytenoid cartilages and are enclosed within the aryepiglottic folds.

▼ **Cricothyrotomy.** A cricothyrotomy is an incision made through the skin between the cricoid and thyroid cartilages, and then through the cricothyroid membrane to insert a small tube to establish a patent airway when the airway is blocked above the vocal folds (i.e., angioedema, serious facial trauma, or a foreign body). With the exception of the occasional pyramidal lobe of the thyroid gland or some small vessels, few structures are located in the tissue superficial to the cricothyroid ligament. A cricothyrotomy is a last resort in a life-threatening situation when an endotracheal tube is not feasible due to trauma or foreign body obstruction. ▼

VOCAL LIGAMENTS AND THEIR MOVEMENTS

From the vocal process of each arytenoid cartilage, a fibrous band extends anteriorly to attach to the deep surface of the thyroid cartilage (Figure 28-1C).

- **Vocal folds.** These two fibrous ligaments are composed largely of elastic fibers and form the core of the mucosal folds called the vocal folds, or true vocal cords. Consequently, the vocal folds vibrate, producing sound as air rushes up from the lungs through the opening between the vocal cords called the rima glottis.
- **Vestibular folds.** Superior to the true vocal folds are a similar pair of mucosal folds, called the vestibular (false) vocal folds, which play no part in the production of sound because the vestibular folds are not opposable.

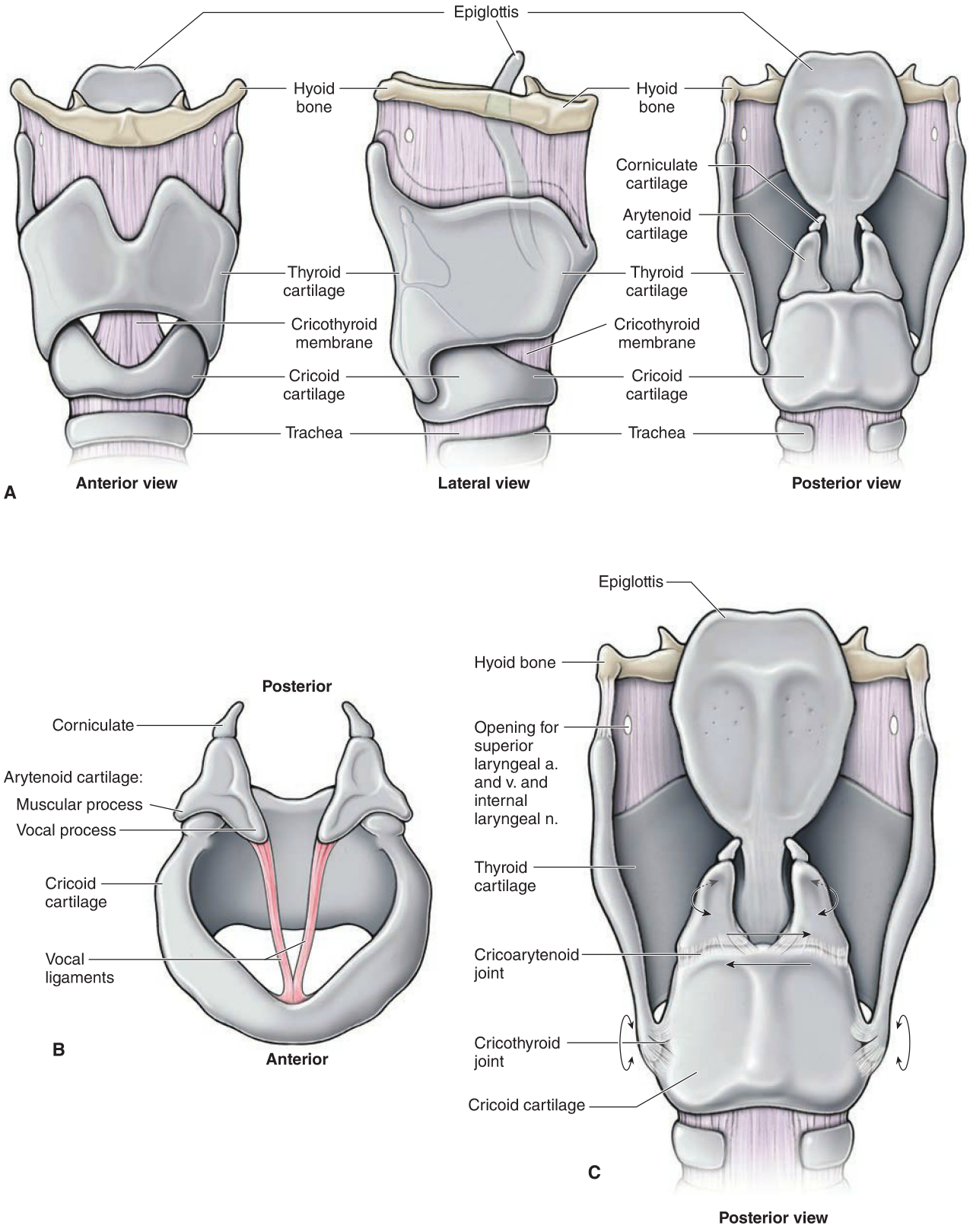

Figure 28-1: **A**. Views of the cartilaginous skeleton. **B**. Superior view, looking down into the vocal ligament anatomy. **C**. Posterior view of the movements of the laryngeal cartilage joints.

FUNCTION OF THE LARYNX

BIG PICTURE

Laryngeal muscles move the laryngeal skeleton and are innervated by the vagus nerve (CN X). In turn, this movement changes the width and the tension on the vocal folds so that air passing between the vocal folds causes them to vibrate, producing sound.

LARYNGEAL MUSCLES

The intrinsic laryngeal muscles move the laryngeal framework, altering the size and shape of the rima glottidis and the length and tension of the vocal folds (Figure 28-2). The actions of the laryngeal muscles are best understood when considered in the following functional groups: adductors and abductors and tensors and relaxers.

ADDUCTORS AND ABDUCTORS Rotation of the cricoarytenoid cartilages results in medial or lateral displacement of the vocal folds, thereby decreasing or increasing, respectively, the aperture of the rima glottis.

- **Adduction (closing) of the vocal folds.** The **lateral cricoarytenoid muscles** pull the muscular processes anteriorly, rotating the arytenoids so their vocal processes swing medially. When this action is combined with that of the **transverse arytenoid muscles**, which pull the arytenoid cartilages together, the gap between the vocal folds is decreased. Air pushed through the rima glottidis causes vibration of the vocal ligaments.
- **Abduction (opening) of the vocal folds.** The **posterior cricoarytenoid muscles** pull the muscular processes posteriorly, rotating the vocal processes laterally and thus widening the rima glottidis.

GLIDING MOVEMENT OF THE ARYTENOID CARTILAGES Horizontal gliding action of the arytenoid cartilages permits the bases of these cartilages to move side to side. Medial gliding and medial rotation of the arytenoid cartilages occur simultaneously, as do the two lateral movements.

- **Adduction of the vocal folds** also is aided by horizontal medial gliding of the arytenoid cartilages. This action is caused by bilateral contraction of the lateral cricoarytenoid, the transverse and oblique arytenoids, and the aryepiglottic muscles.
- **Abduction of the vocal folds** also is aided by horizontal lateral gliding of the arytenoid cartilages. This action is caused by bilateral contraction of the posterior cricoarytenoid muscles.

LENGTH AND TENSION OF THE VOCAL FOLDS The **cricothyroid joint** is a synovial articulation between the side of the cricoid cartilage and the inferior horn of the thyroid cartilage. This joint enables the thyroid cartilage to tilt back and forth upon the cricoid cartilage, altering the length and tension of the vocal folds.

- **Tensing of the vocal folds.** The principal tensors are the **cricothyroid muscles**, which tilt the thyroid cartilage anteriorly and inferiorly, increasing the distance between the thyroid cartilage and the arytenoid cartilage. This movement elongates and tightens the vocal ligaments, raising the pitch of the voice.
- **Relaxing the vocal folds.** The principal relaxers are the **thyroarytenoid muscles**, which pull the arytenoid cartilages anteriorly toward the thyroid angle (prominence), thereby relaxing the vocal ligaments.
  - **Vocalis muscles.** Produce minute adjustments of the vocal ligaments, selectively tensing and relaxing parts of the vocal folds during animated speech and singing.

VOICE PRODUCTION

To understand how we speak and sing, we first need to understand how sound is produced, and then we need to understand how that sound is articulated.

PHONATION Phonation, or the production of sound, involves the intermittent release of expired air coordinated with opening and closing the rima glottis. The length of the true vocal folds and the size of the rima glottis are altered by the action of the intrinsic laryngeal muscles, most of which move the arytenoid cartilages. As the length and tension of the vocal folds change, the pitch of the sound is altered. Generally, the more tense the vocal folds, the faster they vibrate and thus the higher the pitch. The rima glottis is wide when deep tones are produced and narrows to a slit when high-pitched sounds are produced. As a young boy's larynx enlarges during puberty, the vocal folds become both longer and thicker, causing them to vibrate more slowly and thus the voice becomes deeper.

Loudness of the voice depends on the force with which air rushes across the vocal folds. The greater the force of air across the vocal folds, the stronger the vibration, which results in louder sounds. The vocal folds do not move at all when we whisper, but they vibrate vigorously when we yell.

Although the vocal folds produce sounds, the quality of the voice depends on the coordinated activity of many other structures. For example, the pharynx acts as a resonating chamber to amplify and enhance the quality of the sound, as do the oral and nasal cavities and the paranasal sinuses.

ARTICULATION Articulation, or the production of intelligible sounds, involves the actions of the pharyngeal muscles (vagus nerve, CN X), the tongue (hypoglossal nerve, CN XII), the muscles of facial expression (facial nerve, CN VII), mandibular movements (mandibular branch of the trigeminal nerve, CN V-3), and the soft palate (CN X). Each of these structures modifies the crude sounds that are produced by the larynx and convert them into recognizable consonants and vowels.

▼ **Laryngitis.** Inflammation of the vocal folds, or laryngitis, results in hoarseness or inability to speak above a whisper. Overuse of the voice, very dry air, bacterial infections, or inhalation of irritating chemicals can cause laryngitis. Whatever the cause, irritation of the laryngeal tissues causes swelling and prevents the vocal folds from moving freely. ▼

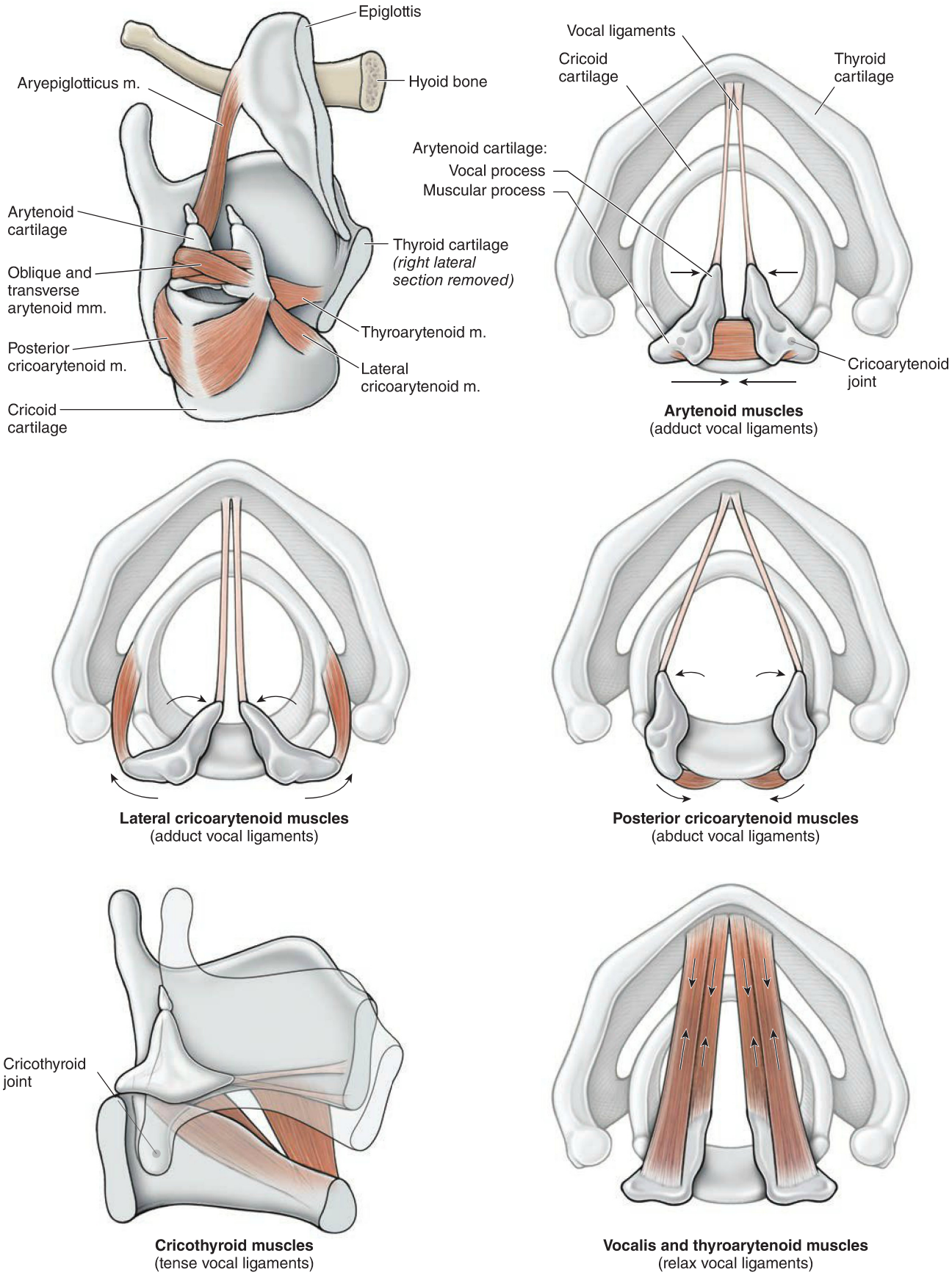

Figure 28-2: Muscles and actions of laryngeal muscles.

VASCULAR SUPPLY AND INNERVATION OF THE LARYNX

BIG PICTURE

Blood supply to the larynx is derived principally from the superior and inferior laryngeal arteries. The vagus nerve (CN X) provides both motor and sensory innervation.

LARYNGEAL VESSELS

The blood supply to the larynx is derived from the superior and inferior laryngeal arteries (Figure 28-3A and B). Rich anastomoses exist between the corresponding contralateral and ipsilateral arteries.

- **Superior thyroid artery.** Originates from the external carotid artery and while descending toward the thyroid gland gives rise to the superior laryngeal artery; penetrates the thyrohyoid membrane and supplies the interior of the larynx (tissues above the vocal folds and laryngeal muscles).
- **Inferior laryngeal artery.** Arises from the thyrocervical trunk and supplies the region below the vocal folds.

Venous return from the larynx occurs via the superior and inferior laryngeal veins, which are tributaries of the superior and inferior thyroid veins, respectively. The superior thyroid vein drains into the internal jugular vein, whereas the inferior thyroid vein drains into the brachiocephalic vein.

LARYNGEAL INNERVATION

Innervation of the larynx is from CN X via the superior and recurrent laryngeal nerves (Figure 28-3A and B).

SUPERIOR LARYNGEAL NERVE Arises from the inferior vagal ganglion and divides into a smaller external laryngeal branch and a larger internal laryngeal branch.

- **External laryngeal nerve.** Courses laterally to innervate the cricothyroid muscle.
- **Internal laryngeal nerve.** Courses with the superior thyroid artery and vein, pierces the thyrohyoid membrane, and provides general sensory innervation to the mucosa above the vocal folds.

Cough reflex. The cough reflex mediates coughing in response to irritation of the laryngeal mucosa above the vocal folds. The internal laryngeal nerve provides the sensory limb of the cough reflex above the vocal folds.

RECURRENT LARYNGEAL NERVE All intrinsic laryngeal muscles are supplied by the recurrent laryngeal nerve (CN X), except for the cricothyroid muscle, which is supplied by the external laryngeal nerve (CN X). The recurrent laryngeal nerve also provides visceral sensory innervation from the mucosa inferior to the vocal folds.

Hoarse voice. A lesion of the recurrent laryngeal nerve results in paralysis of laryngeal muscles. The voice is weak (aka hoarse) because the paralyzed vocal fold on the side of the lesion cannot meet the contralateral vocal fold. When bilateral paralysis of the vocal folds occurs, the voice is almost absent.

- **Hoarseness** is the most common symptom of disorders of the larynx, including inflammation or carcinoma of the larynx.
- **Injury to the superior laryngeal nerve** causes anesthesia of the laryngeal mucosa superior to the vocal folds. As a result, the protective mechanism designed to keep food out of the larynx (the sensory limb of the cough reflex) is inactive.

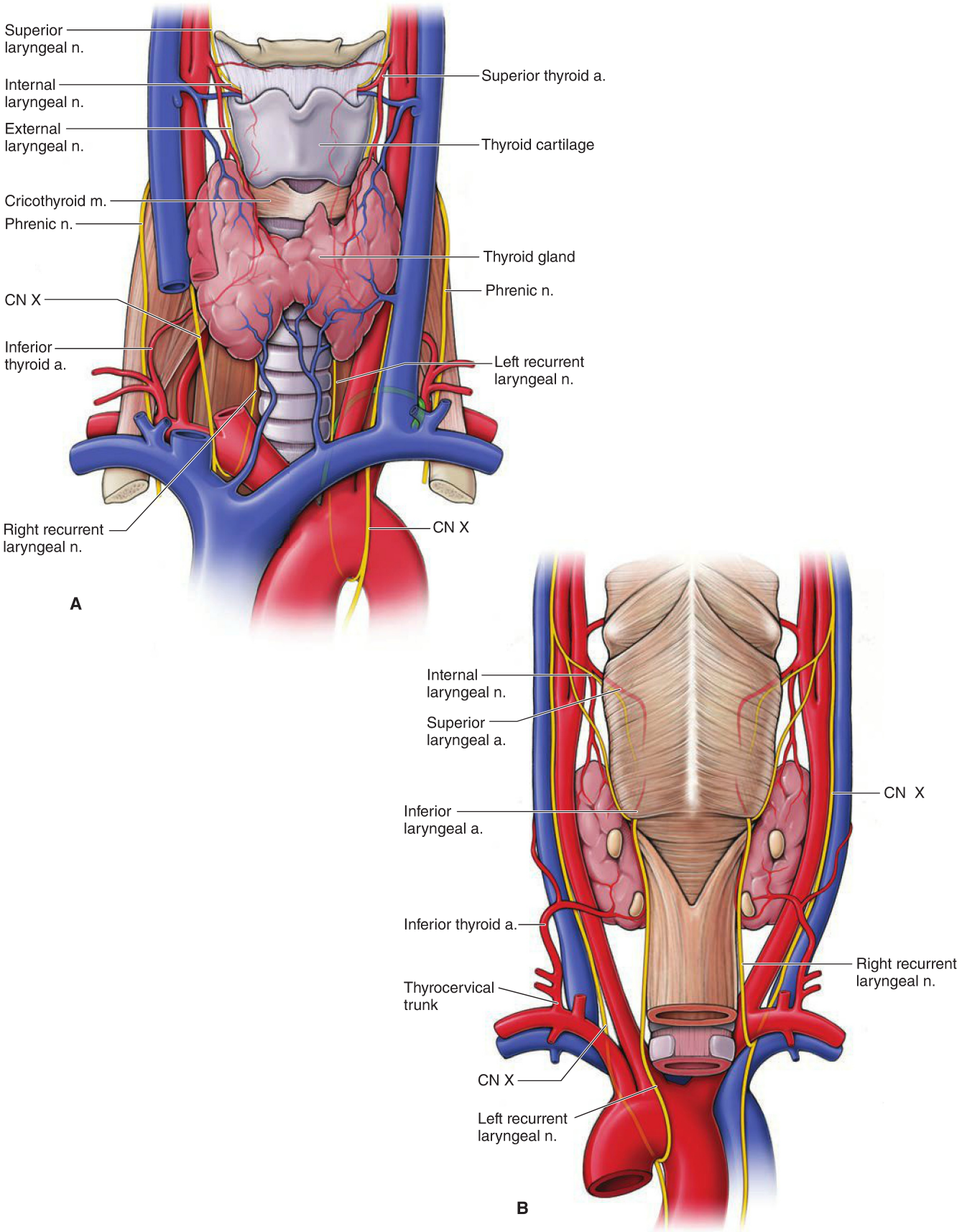

Figure 28-3: Anterior (**A**) and posterior (**B**) views of the vascular supply and innervation of the larynx.

STUDY QUESTIONS

Directions: Each of the numbered items or incomplete statements is followed by lettered options. Select the **one** lettered option that is **best** in each case.

1. A surgeon is performing an endarterectomy on a 64-year-old man who has stenosis of the carotid artery. In approaching the internal carotid artery, the surgeon severs a nerve embedded within the fascia of the carotid sheath. As a result of this complication, which muscle would most likely be paralyzed?

A. Digastric muscle (anterior belly)
B. Digastric muscle (posterior belly)
C. Masseter muscle
D. Mylohyoid muscle
E. Sternohyoid muscle
F. Stylohyoid muscle

2. A 62-year-old woman sees her physician with the complaint of severe pain on the left side of her face. Physical examination shows pallor of the left ear, preauricular region, and tongue. Angiography would most likely confirm complete occlusion of which artery?

A. External carotid
B. Internal carotid
C. Subclavian
D. Superior thyroid
E. Vertebral

3. A 46-year-old woman undergoes surgery to fuse (stabilize) the C4–C5 vertebrae due to a herniated disc that is compressing spinal nerves in the neck. The surgeon approaches the cervical vertebrae laterally between the sternocleidomastoid and trapezius muscles. After dissection through the skin and superficial fascia, which of the fascial layers of the neck, from superficial to deep, is the surgeon most likely to dissect through to reach the cervical vertebrae?

A. Carotid to deep investing
B. Investing to pretracheal
C. Investing to prevertebral
D. Prevertebral to carotid to pretracheal
E. Pretracheal to prevertebral

4. During a subclavian venipuncture procedure, the cannula is inserted into the patient's neck just superior to the clavicle. Which of the following is the relative position of the subclavian vein in the root of the neck?

A. Anterior to the anterior scalene muscle
B. Anterior to the longus capitis muscle
C. Medial to the trapezius muscle
D. Medial to the sternocleidomastoid muscle
E. Posterior to the anterior scalene muscle
F. Posterior to the subclavian artery

5. A 22-year-old student stands up after studying at her desk all morning. As soon as she stands, she becomes light headed and has to hold the back of her chair because she feels as though she may faint. Within a few seconds, she feels fine and walks to the water fountain. What anatomic structure was responsible for measuring her drop in blood pressure?

A. Carotid body
B. Carotid sinus
C. Cervical plexus
D. Choroid plexus
E. Ciliary ganglion
F. Submandibular ganglion

6. During a physical examination, the physician stands behind the patient to feel the thyroid gland. To palpate the left thyroid lobe, the patient is instructed to look to the left. The action of turning the head to the left is accomplished by contraction of which of the following muscles?

A. Left anterior scalene muscle
B. Left sternocleidomastoid muscle
C. Left trapezius muscle
D. Right anterior scalene muscle
E. Right sternocleidomastoid muscle
F. Right trapezius muscle

7. A surgeon dissects through subcutaneous fat in the neck and identifies lobulated, slightly paler glandular tissue that will be surgically removed. A vein coursing superficial to the gland and an artery coursing deep to the gland are isolated. The hypoglossal nerve is retracted to avoid risk of damage during the procedure. This surgery is most likely occurring in which of the following cervical triangles?

A. Carotid
B. Muscular
C. Posterior
D. Submandibular
E. Submental

8. While eating popcorn, a child inhaled a kernel into her laryngeal cavity. The popcorn kernel touched the top of her vocal folds, initiating her cough reflex. Which sensory nerve is responsible for relaying the message to the brain that a popcorn kernel has touched the top of the vocal folds?

A. External laryngeal nerve
B. Facial nerve
C. Glossopharyngeal nerve
D. Internal laryngeal nerve
E. Recurrent laryngeal nerve

9. For general surgical procedures, anesthetics and muscle relaxants are used routinely. However, anesthetics and muscle relaxants may decrease nerve stimulation to skeletal muscles, including the intrinsic muscles of the larynx, which results in closure of the vocal folds. Therefore, tracheal intubation is necessary. Which of the following intrinsic muscles of the larynx may be unable to maintain an open glottis because of the anesthetics?

A. Cricothyroid muscles
B. Lateral cricoarytenoid muscles
C. Posterior cricoarytenoid muscles
D. Thyroarytenoid muscles
E. Transverse arytenoid muscles

10. A 37-year-old woman complains of cough and hoarseness of several weeks' duration. Upon further examination, the physician notes that the patient has partial paralysis of her vocal cords. Radiographic studies confirm an aneurysm of the aortic arch. Which of the following would account for the relationship between symptoms of cough and hoarseness and this finding?

A. Direct contact of the aneurysm with the trachea in the superior mediastinum
B. Injury to that part of the sympathetic chain that provides sensory innervation to the larynx
C. Irritation of the left phrenic nerve as it crosses the arch of the aorta on its way to the diaphragm
D. Pressure of the aneurysm on the esophagus in the posterior mediastinum
E. Pressure on the left recurrent laryngeal nerve, which wraps around the aortic arch

11. A 55-year-old man who has been diagnosed with colon cancer is noted to have a probable metastatic mass in the neck at the thoracic duct. In which region is the metastasis most likely to be located?

A. Left subclavicular region
B. Left supraclavicular region
C. Right subclavicular region
D. Right supraclavicular region

12. The phrenic nerve in the cervical region courses along the anterior surface of which of the following muscles?

A. Anterior scalene muscle
B. Middle scalene muscle
C. Posterior scalene muscle
D. Sternocleidomastoid muscle
E. Trapezius muscle

13. The parietal peritoneum covering the inferior surface of the diaphragm transmits its sensory information via the phrenic nerve. In the case of peritonitis in the parietal peritoneum on the inferior surface of the diaphragm, pain may be referred through which of the following nerves?

A. Greater occipital
B. Lesser occipital
C. Superior division of the ansa cervicalis
D. Supraclavicular

ANSWERS

1—E: The ansa cervicalis of the cervical plexus is embedded within the fascia of the carotid sheath and, as such, infrahyoid muscles would be affected if a nerve is severed within this fascia. The only infrahyoid muscle in the list of choices is the sternohyoid muscle. The anterior belly of the digastric muscle and mylohyoid muscle is innervated by the mandibular nerve (CN V-3); the stylohyoid and posterior belly of the digastric muscles are innervated by the facial nerve (CN VII). The masseter is a muscle of mastication and is innervated by CN V-3.

2—A: The external carotid artery supplies the ipsilateral face, ear region, and tongue. The internal carotid artery does not supply any of the described areas in the question, but instead enters the base of the skull at the carotid canal to supply the brain. The superior thyroid artery is a branch of the external carotid artery, but it does not supply the face, ear, or tongue. The subclavian and vertebral arteries do not directly distribute to the affected areas.

3—C: Deep to the skin and superficial fascia, the next layer of tissues the surgeon will reach is the investing fascia between the trapezius and the sternocleidomastoid muscles and then the prevertebral fascia around the cervical muscles. The cervical vertebrae are located deep to the prevertebral fascia.

4—A: The subclavian artery and brachial plexus course between the anterior and middle scalene muscles. However, the subclavian vein courses anterior to the anterior scalene muscle.

5—B: The carotid sinus is a baroreceptor that measures blood pressure to the brain. The carotid body is a chemoreceptor that measures blood oxygen concentration. The choroid plexus has nothing to do with blood pressure; it produces cerebrospinal fluid in the ventricular system. The ciliary and the submandibular ganglia are parasympathetic ganglia in the orbit and oral cavity, respectively. The circle of Willis is the anastomosis between the paired internal carotid and vertebral arteries around the pituitary gland.

6—E: Unilateral contraction of the sternocleidomastoid muscle results in the head rotating to the contralateral side. Therefore, contraction of the right sternocleidomastoid muscle results in the head rotating to the left. Unilateral contraction of the trapezius muscle results in minor rotation, but it is not the primary muscle responsible for this movement. The anterior scalene muscle attaches between rib 1 and the cervical vertebrae and, therefore, will not directly move the skull.

7—D: The question outlines the course of the facial vessels in relation to the submandibular salivary gland (the vein is superficial and the artery is deep). The hypoglossal nerve (CN XII) courses within the submandibular triangle. Therefore, the relation of the facial vessels to the submandibular gland and identification of CN XII indicate the location of the surgery within the submandibular triangle.

8—D: The internal laryngeal nerve is the branch of the vagus nerve (CN X) that provides general sensory innervation to the laryngopharynx and mucosal lining superior to the vocal folds. As such, when a stimulus touches the superior element of the vocal folds, the sensory stimulation is conducted along the internal laryngeal nerve to the brainstem, initiating the cough reflex. The external laryngeal nerve innervates the cricothyroideus muscle. The facial nerve (CN VII) innervates muscles of facial expression. The glossopharyngeal nerve (CN IX) provides sensory innervation for the oropharynx and the posterior third of the tongue. The recurrent laryngeal nerve provides visceral sensory innervation for the mucosal lining inferior to the vocal folds.

9—C: The posterior cricoarytenoid is the only muscle in the list of choices, which, when stimulated to contract, will open the vocal folds and therefore open the glottis. The other muscles (i.e., cricothyroid, lateral cricoarytenoid, thyroarytenoid, and the transverse arytenoids) will either tense or close the vocal folds.

10—E: The left recurrent laryngeal nerve courses back up the neck between the trachea and esophagus and will provide motor innervation to all laryngeal muscles (except the cricothyroideus). Therefore, pressure from the aneurysm may inhibit conduction of motor impulses and, therefore, result in paralysis of the laryngeal muscles.

11—B: The thoracic duct collects lymph from all regions of the body (including the colon), except for the right side of the head, neck, and right upper limb. Therefore, if a mass is present, it could manifest in the root of the neck where the thoracic duct enters the junction of the left internal jugular and subclavian veins in the supraclavicular region.

12—A: The phrenic nerve courses along the anterior surface of the anterior scalene muscle en route to the thoracic cavity.

13—D: The phrenic nerve consists of contributions from spinal nerve levels C3 to C5. Therefore, when sensory information comes from the parietal peritoneum on the inferior diaphragmatic surface, it may refer through spinal nerves at the same levels. Therefore, the supraclavicular nerve shares levels with the C3 and C4 levels. The greater and lesser occipital nerves both originate at the C2 level, and the superior division of the ansa cervicalis originates from the C1 level.

SECTION 6

UPPER LIMB

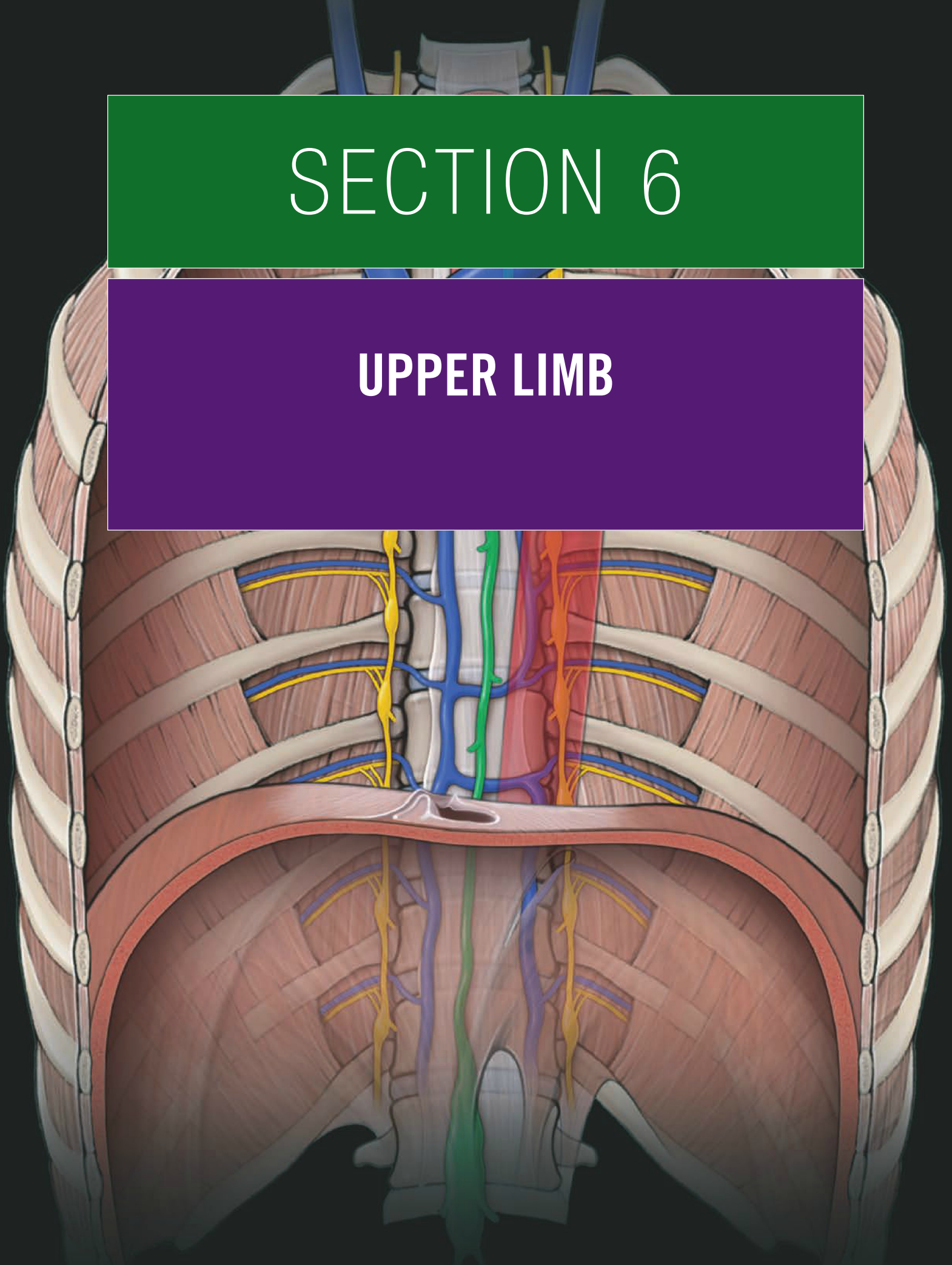

This page intentionally left blank

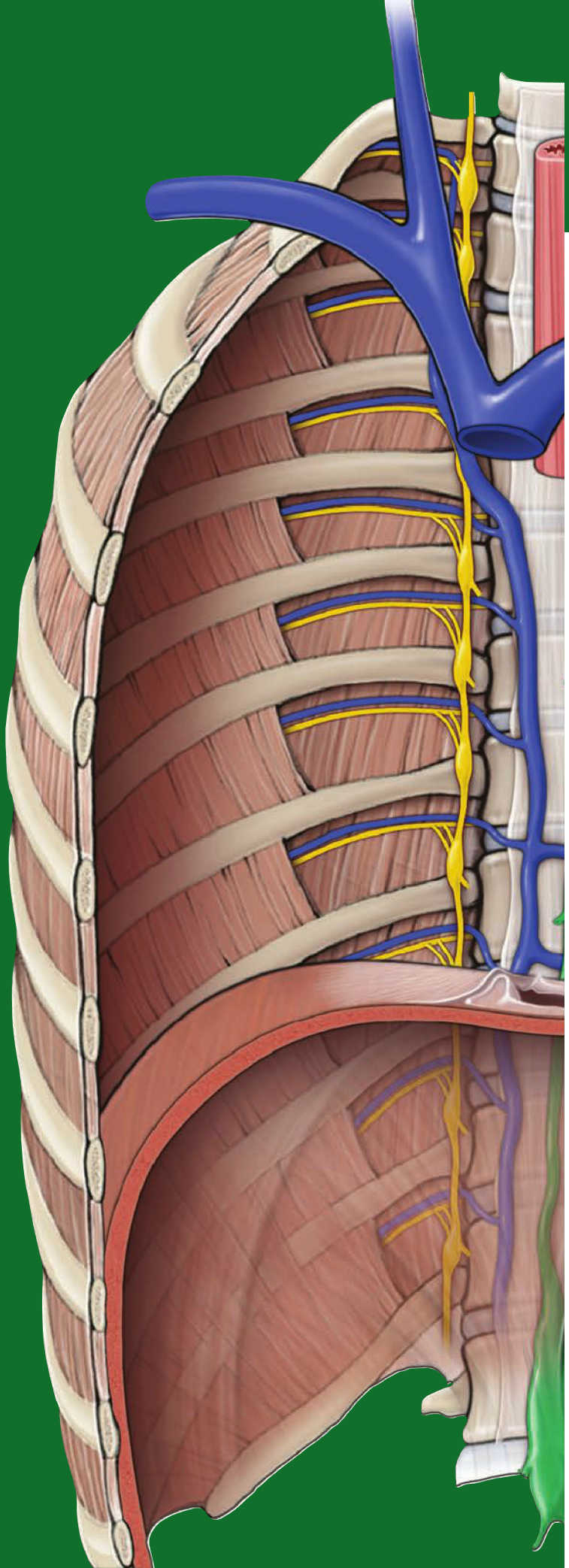

CHAPTER 29

OVERVIEW OF THE UPPER LIMB

Bones of the Shoulder and Arm 302
Bones of the Forearm and Hand. 304
Fascial Planes and Muscles 306
Innervation of the Upper Limb by the Brachial Plexus 308
Sensation of the Upper Limb 310
Vascularization of the Upper Limb 312

BONES OF THE SHOULDER AND ARM

BIG PICTURE

The bones of the skeleton provide a framework to which muscles, tendons, and ligaments attach. The bony structure of the shoulder and arm consists of the clavicle, scapula, and humerus (Figure 29-1A). Synovial joints and ligaments connect bone to bone.

CLAVICLE

The **clavicle**, or collarbone, is the only bony attachment between the upper limb and the axial skeleton (Figure 29-1B and C). It is superficial along its entire length and shaped like an "**S**." The clavicle provides an attachment for muscles that connect the clavicle to the trunk and the upper limb. The following landmarks are found on the clavicle:

- **Acromial end.** Articulates laterally with the acromion of the scapula and forms the **acromioclavicular joint**.
- **Sternal end.** Articulates medially with the manubrium and forms the **sternoclavicular joint**.
- **Conoid tubercle.** Located on the inferior surface of the lateral clavicle and serves as an attachment for the **coracoclavicular ligament**.

SCAPULA

The **scapula**, or **shoulder blade**, is a large, flat triangular bone with two angles (superior and inferior), three borders (superior, lateral, and medial), two surfaces (costal and posterior), and three processes (acromion, spine, and coracoid) (Figure 29-1D and E). The following landmarks are found on the scapula:

- **Subscapular fossa.** Located anteriorly and characterized by a shallow, concave fossa. Because the subscapular fossa glides upon the ribs, it is also known as the costal surface. Serves as an attachment for the subscapularis muscle.
- **Acromion.** A large projection of the anterolateral surface of the spine; the acromion arches over the glenohumeral joint and articulates with the clavicle.
- **Spine.** Very prominent and palpable; the spine subdivides the posterior surface of the scapula into a small supraspinous fossa and a larger infraspinous fossa. Serves as an attachment for the trapezius and deltoid muscles.
- **Supraspinous fossa.** Located on the posterior surface of the scapula and superior to the spine of the scapula. Serves as an attachment for the supraspinatus muscle.
- **Infraspinous fossa.** Located on the posterior surface of the scapula and inferior to the spine of the scapula. Serves as an attachment for the infraspinatus muscle.
- **Suprascapular notch.** A small notch medial to the root of the coracoid process where the suprascapular nerve courses. The superior transverse scapular ligament converts the suprascapular notch into a foramen.
- **Glenoid cavity (fossa).** A shallow cavity that articulates with the head of the humerus to form the **glenohumeral joint**.
- **Supraglenoid tubercle.** Located superior to the glenoid cavity and serves as the attachment for the long head of the biceps brachii muscle.
- **Infraglenoid tubercle.** Located inferior to the glenoid cavity and serves as the attachment for the long head of the triceps brachii muscle.
- **Coracoid process.** A prominent and palpable hook-like structure inferior to the clavicle. The coracoid process serves as an attachment for the pectoralis minor, coracobrachialis, and short head of the biceps brachii muscles.

HUMERUS

The humerus is the longest bone of the arm and is characterized by many distinct features that allow the upper extremity to move through a significant range of motion. The following landmarks are found on the humerus (Figure 29-1F and G):

- **Head.** A ball-shaped structure that articulates with the glenoid cavity.
- **Anatomical neck.** Formed by a narrow constriction immediately distal to the head of the humerus.
- **Surgical neck.** Lies distal to the anatomical neck and tubercles of the humerus. The axillary nerve and the posterior humeral circumflex artery course into the posterior compartment of the arm deep to the surgical neck.
- **Greater tubercle.** Lateral enlargement on the proximal posterolateral humerus; attachment site for supraspinatus, infraspinatus, and teres minor muscles.
- **Lesser tubercle.** Smaller enlargement on the proximal, anterior humerus; attachment site for the subscapularis muscle.
- **Intertubercular (bicipital) groove.** A deep sulcus between the greater and lesser tubercles, where the long head of the biceps brachii tendon courses en route to the supraglenoid tubercle.
- **Radial (spiral) groove.** A distinct groove on the posterior surface of the humerus, where the radial nerve and the deep brachial artery course.
- **Deltoid tuberosity.** A large V-shaped protrusion on the lateral surface of the humerus, midway along its length where the deltoid muscle attaches.
- **Lateral epicondyle.** Located on the distal lateral end of the humerus and provides an attachment surface for the posterior forearm muscles (extensors).
- **Medial epicondyle.** Located on the distal medial end of the humerus and provides an attachment surface for the anterior forearm muscles (flexors).
- **Trochlea.** Characterized by a pulley shape; it helps guide the hinge joint; articulates with the trochlear notch of the ulna.
- **Capitulum.** Characterized by its oval, convex shape for articulation with the radial head.
- **Coronoid fossa.** Located on the distal anterior surface of the humerus; associated with the coronoid process of the ulna.
- **Olecranon fossa.** Located on the distal posterior surface of the humerus; associated with the olecranon process of the ulna.

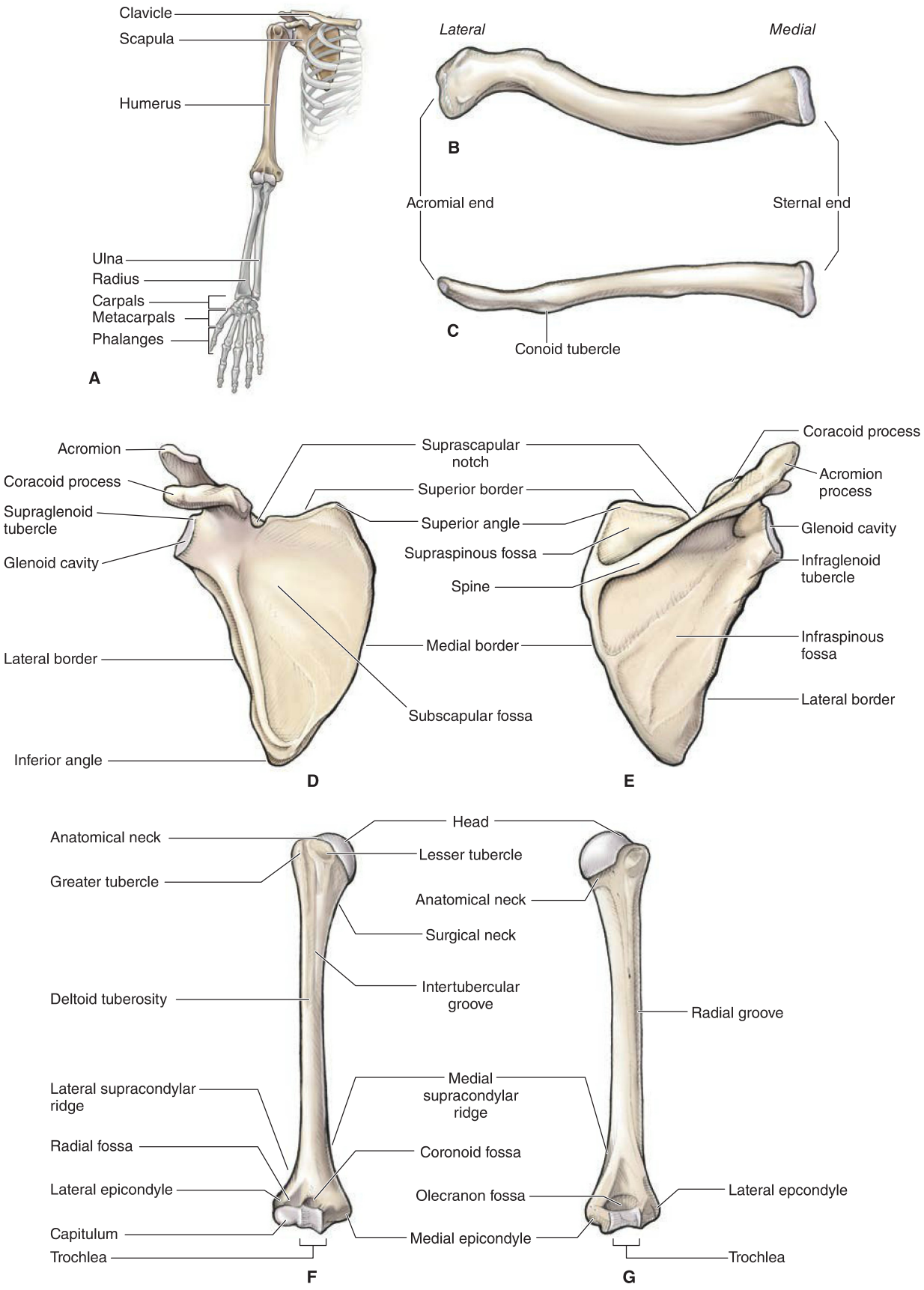

Figure 29-1: A. Osteology of the upper limb (right side). Superior (**B**) and anterior (**C**) views of the clavicle. Anterior (**D**) and posterior (**E**) views of the scapula. Anterior (**F**) and posterior (**G**) views of the humerus.

BONES OF THE FOREARM AND HAND

BIG PICTURE

The bony structure of the forearm and hand consists of the radius, ulna, 8 carpals, 5 metacarpals, and 14 phalanges (Figure 29-2A). The radius and ulna are bound together by a tough fibrous sheath known as the interosseous membrane.

RADIUS

In the anatomic position, the **radius** is the lateral bone of the forearm. It articulates with the capitulum of the humerus, ulna, and scaphoid. The radius is primarily a bone of movement in the forearm during rotation (supination and pronation) relative to the fixed ulna. The following landmarks are found on the radius (Figure 29-2B):

- **Head.** A disc-shaped structure that enables the synovial pivot joint in the forearm.
- **Radial tuberosity.** A swelling inferior to the radial neck on the medial surface where the biceps brachii muscle attaches.
- **Radial styloid process.** Prominent and palpable process on the distal and lateral end where the brachioradialis muscle attaches.

ULNA

In the anatomic position, the **ulna** is the medial bone of the forearm. It articulates with the trochlea of the humerus and with the radius. The ulna remains relatively fixed during forearm rotation of pronation and supination. The following landmarks are found on the ulna (Figure 29-2B):

- **Olecranon process.** A large posterior projection that contributes to the trochlear notch and articulates with the humerus.
- **Coronoid process.** A small anterior projection that contributes to the trochlear notch and articulates with the humerus.
- **Trochlear notch.** A large notch on the proximal end of the ulna that is formed by the olecranon and coronoid processes. It articulates with the trochlea on the humerus.
- **Ulnar head.** A distal rounded surface at the end of the ulna.
- **Ulnar styloid process.** A palpable distal projection from the dorsal medial ulna.

HAND

The hand is subdivided into the carpals (wrist), metacarpals, and phalanges (Figure 29-2C).

- **Carpals.** Formed by eight small carpal bones arranged as a proximal row and a distal row, with each row consisting of four bones.
  - **Proximal row**
    - **Pisiform.** A prominent pea-shaped sesamoid bone lying in the tendon of the flexor carpi ulnaris muscle.
    - **Triquetrum.** Three-sided bone.
    - **Lunate.** Characterized by its crescent shape.
    - **Scaphoid.** Most commonly fractured carpal bone located in the floor of the anatomical snuffbox.
  - **Distal row**
    - **Trapezium.** Articulates with the metacarpal bone of the thumb.
    - **Trapezoid.** Four-sided bone.
    - **Capitate.** The largest of the carpal bones.
    - **Hamate.** Characterized by a prominent hook (the **hook of the hamate**) on its palmar surface.
- **Metacarpals.** Each of the five metacarpal bones is related to one digit. The first metacarpal is related to the thumb (digit 1), and metacarpals 2 through 5 are related to the index, middle, ring, and little finger, respectively.
- **Phalanges.** The phalanges are the bones of the five digits (numbered 1–5, beginning at the thumb). Digits 2 through 5 consist of a proximal, middle, and a distal phalanx. Digit 1 (thumb) contains only a proximal and a distal phalanx.

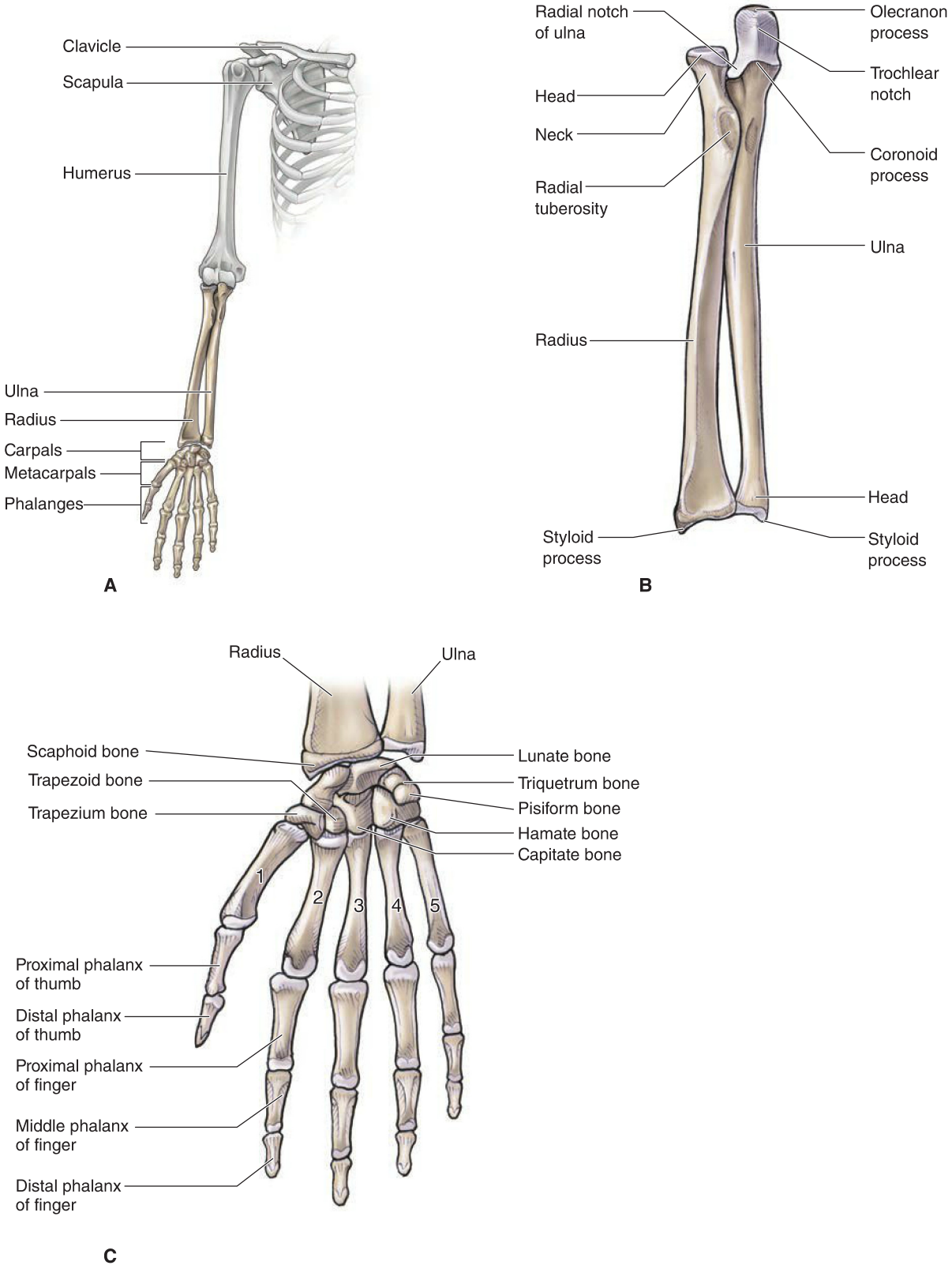

Figure 29-2: **A**. Osteology of the upper limb. **B**. Radius and ulna. **C**. Hand.

FASCIAL PLANES AND MUSCLES

BIG PICTURE

Two fascial layers, defined as the superficial and the deep fascia, lie between the skin and the bone of the upper limb. The deep fascia divides the upper limb into anterior and posterior compartments. Muscles are organized into these compartments and have common attachments, innervations, and actions.

FASCIA OF THE UPPER LIMB

The upper limb consists of superficial and deep fascia (Figure 29-3A).

- **Superficial fascia.** Referred to as the subcutaneous or hypodermis layer; located deep to the skin and primarily contains fat, superficial veins, lymphatics, and cutaneous nerves.
- **Deep fascia.** Lies deep to the superficial fascia; primarily contains muscles, nerves, vessels, and lymphatics. Gives rise to intermuscular septae, which extend to the bones, dividing the arm and forearm into anterior and posterior compartments. Each compartment contains muscles that perform similar movements and have a common innervation.

MUSCLES OF THE UPPER LIMB

The muscles of the upper limb can be organized into the following groups (Figure 29-3B):

- **Scapular muscles.** The muscles of the shoulder are primarily responsible for stability and movement of the scapulothoracic and glenohumeral joints. Muscular stability of the scapula is important because of the lack of bony stability. These muscles consist of the trapezius, deltoid, rhomboid major, rhomboid minor, serratus anterior, levator scapulae, pectoralis minor, and subclavius.
- **Rotator cuff muscles.** These muscles are considered a cuff because the inserting tendons blend with the **glenohumeral joint capsule** and provide stability and movement to the joint. These muscles consist of the supraspinatus, infraspinatus, teres minor, and subscapularis.
- **Intertubercular groove muscles.** The muscles of the intertubercular attach proximally to the trunk (vertebral column, scapula, rib cage) and distally to the intertubercular groove.
- **Arm muscles.** The deep fascia divides the arm into anterior and posterior compartments, with common actions and innervation.
  - **Muscles of the anterior compartment of the arm.** Muscles of the anterior compartment of the arm (coracobrachialis, biceps brachii, and brachialis muscles) share common actions (flexion of the glenohumeral joint and/or elbow) and innervation (musculocutaneous nerve).
  - **Muscles of the posterior compartment of the arm.** Consist of the triceps brachii muscle that extends from the glenohumeral joint to the elbow and receives motor innervation via the radial nerve.
- **Forearm muscles.** The deep fascia divides the forearm into anterior and posterior compartments with common attachments, actions, and innervation.
  - **Muscles of the anterior compartment of the forearm.** Many of these muscles share a common origin (medial epicondyle of the humerus), common actions (flexion of elbow, wrist, and digits), and common innervation (median and ulnar nerves).
  - **Muscles of the posterior compartment of the forearm.** Many of these muscles share a common origin (lateral epicondyle of the humerus), common actions (extension of the elbow, wrist, and digits), and common innervation (radial nerve).
- **Hand muscles.** The intrinsic muscles of the hand consist of those that act on the thumb (**thenar muscles**), the little finger (**hypothenar muscles**), and lumbricals, dorsal interossei, and palmar interossei muscles.

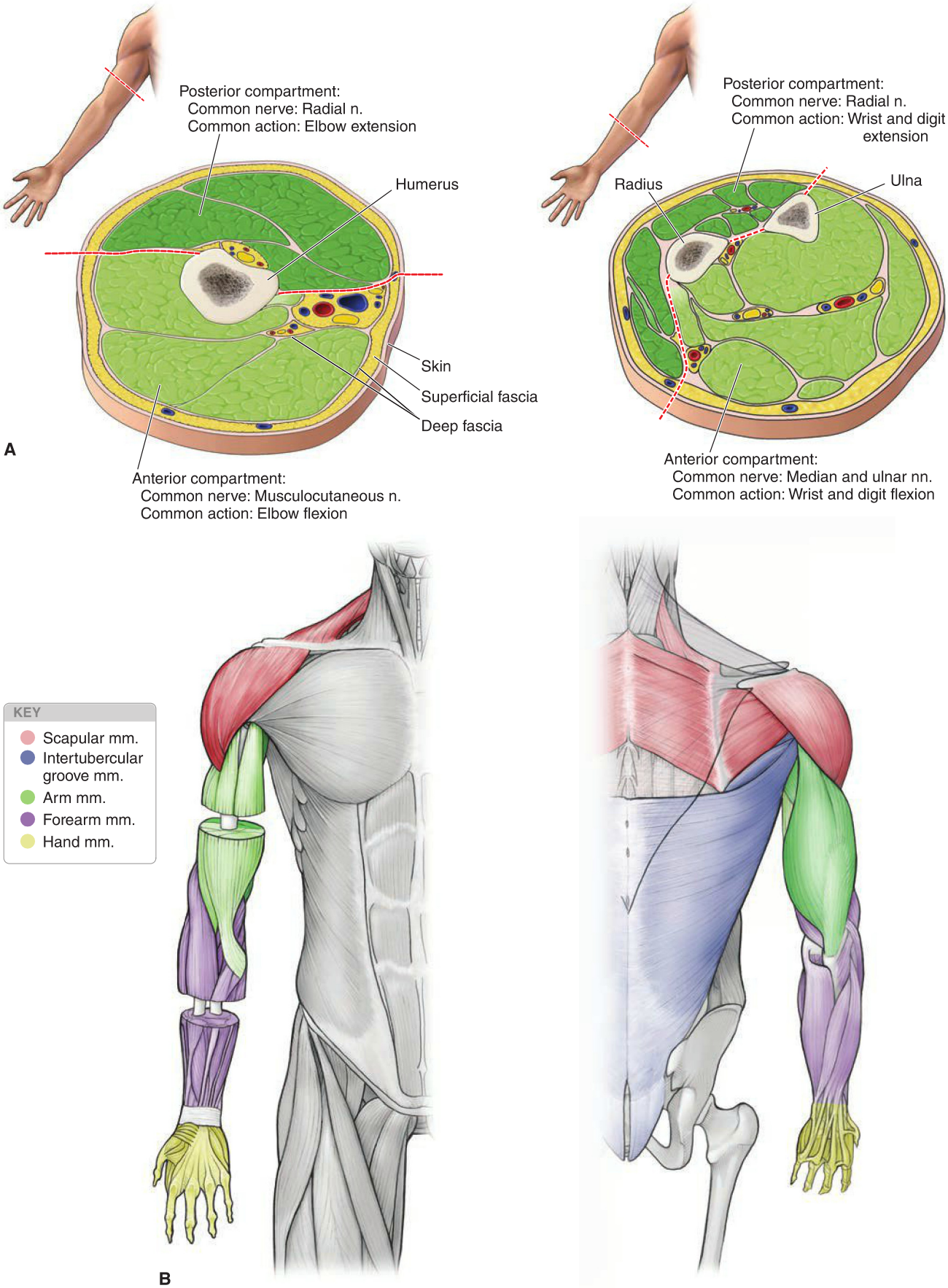

Figure 29-3: A. Cross-section of the arm and forearm showing the anterior compartments (flexors) and the posterior compartments (extensors); superior view. **B**. Upper limb divided into compartments.

INNERVATION OF THE UPPER LIMB BY THE BRACHIAL PLEXUS

BIG PICTURE

The upper limb is innervated by ventral rami originating from spinal nerve levels C5–T1. These rami form a network of nerves referred to as the **brachial plexus**, which extends from the neck into the axilla providing motor and sensory innervation to the upper limb (Figure 29-4). The brachial plexus consists of the following regions: roots, trunks, divisions, cords, and terminal branches.

ROOTS OF THE BRACHIAL PLEXUS

The five **roots** are the **C5–T1** ventral rami and they exit between the anterior and middle scalene muscles along with the subclavian artery. The following two nerves originate from the roots:

- **Dorsal scapular nerve (C5).** Innervates the rhomboid and levator scapulae muscles.
- **Long thoracic nerve (C5–C7).** Innervates the serratus anterior muscle.

TRUNKS OF THE BRACHIAL PLEXUS

The roots give rise to three trunks:

- **Superior trunk.** Formed from the union of the C5 and C6 roots and gives rise to the following:
  - **Nerve to subclavius (C5).** Innervates the subclavius muscle.
  - **Suprascapular nerve (C5–C6).** Innervates the supraspinatus and infraspinatus muscles.
- **Middle trunk.** A continuation of the C7 root.
- **Inferior trunk.** Formed from the union of C8 and T1 roots.

DIVISIONS OF THE BRACHIAL PLEXUS

The trunks give rise to three anterior and three posterior divisions, which are associated with the ventral and dorsal musculature, respectively. The axillary artery separates the anterior and posterior divisions of the brachial plexus deep to the clavicle.

- **Anterior divisions.** Give rise to nerves that innervate the anterior (flexor) compartments of the arm and forearm.
- **Posterior divisions.** Give rise to nerves that innervate the posterior (extensor) compartments of the arm and forearm.

CORDS OF THE BRACHIAL PLEXUS

The anterior and posterior divisions form three cords, named according to their anatomic position relative to the axillary artery.

- **Lateral cord.** Located lateral to the axillary artery; gives rise to the following:
  - **Lateral pectoral nerve (C5–C7).** Innervates the pectoralis major muscle.
- **Medial cord.** Located medial to the axillary artery; gives rise to the following:
  - **Medial pectoral nerve (C8–T1).** Innervates the pectoralis major and pectoralis minor muscles.
  - **Medial cutaneous nerve of the arm (C8–T1).** Provides cutaneous innervation to the medial surface of the arm.
  - **Medial cutaneous nerve of the forearm (C8–T1).** Provides cutaneous innervation to the medial surface of the forearm.
- **Posterior cord.** Located posterior to the axillary artery; gives rise to the following:
  - **Upper subscapular nerve (C5–C6).** Innervates the subscapularis muscle.
  - **Thoracodorsal** (middle subscapular) **nerve (C6–C8).** Innervates the latissimus dorsi muscle.
  - **Lower subscapular nerve (C5–C6).** Innervates the subscapularis and teres major muscles.

TERMINAL BRANCHES OF THE BRACHIAL PLEXUS

The brachial plexus terminates in the following branches (discussed briefly below and in greater detail in Chapters 30 to 33):

- **Musculocutaneous nerve (C5–C7).** Provides innervation to the following:
  - **Motor.** Anterior compartment arm muscles (biceps brachii, brachialis, and coracobrachialis).
  - **Sensory.** Cutaneous innervation to the lateral forearm.
- **Median nerve (C6–T1).** Provides innervation to the following:
  - **Motor.** Anterior compartment forearm muscles (pronator teres, flexor carpi radialis, palmaris longus, flexor digitorum superficialis, flexor pollicis longus, radial half of the flexor digitorum profundus, and pronator quadratus muscles) and hand muscles (thenar and lumbricals 1–2).
  - **Sensory.** Cutaneous innervation to the palmar surface of digits 1 through 3 and half of digit 4; the lateral palm is supplied by the palmar cutaneous branch of the median nerve.
- **Ulnar nerve (C8–T1).** Provides innervation to the following:
  - **Motor.** Flexor carpi ulnaris and the ulnar half of the flexor digitorum profundus muscle in the anterior compartment of the forearm and hand muscles (hypothenar muscles, lumbricals 3 and 4, adductor pollicis, palmar interossei, and dorsal interossei muscles).
  - **Sensory.** Cutaneous innervation of the medial half of the palm, digit 5, and medial region of digit 4.
- **Radial nerve (C5–T1).** Provides innervation to the following:
  - **Motor.** Posterior compartment arm (triceps muscle) and forearm (wrist, thumb, and forearm extensors).
  - **Sensory.** Cutaneous innervation to the posterior arm, posterior forearm, and lateral dorsum of the hand and the dorsum of digits 1 through 3 and half of digit 4.
- **Axillary nerve (C5–C6).** Provides innervation to the following:
  - **Motor.** Deltoid and the teres minor muscles.
  - **Sensory.** Cutaneous innervation to the lateral region of the shoulder.

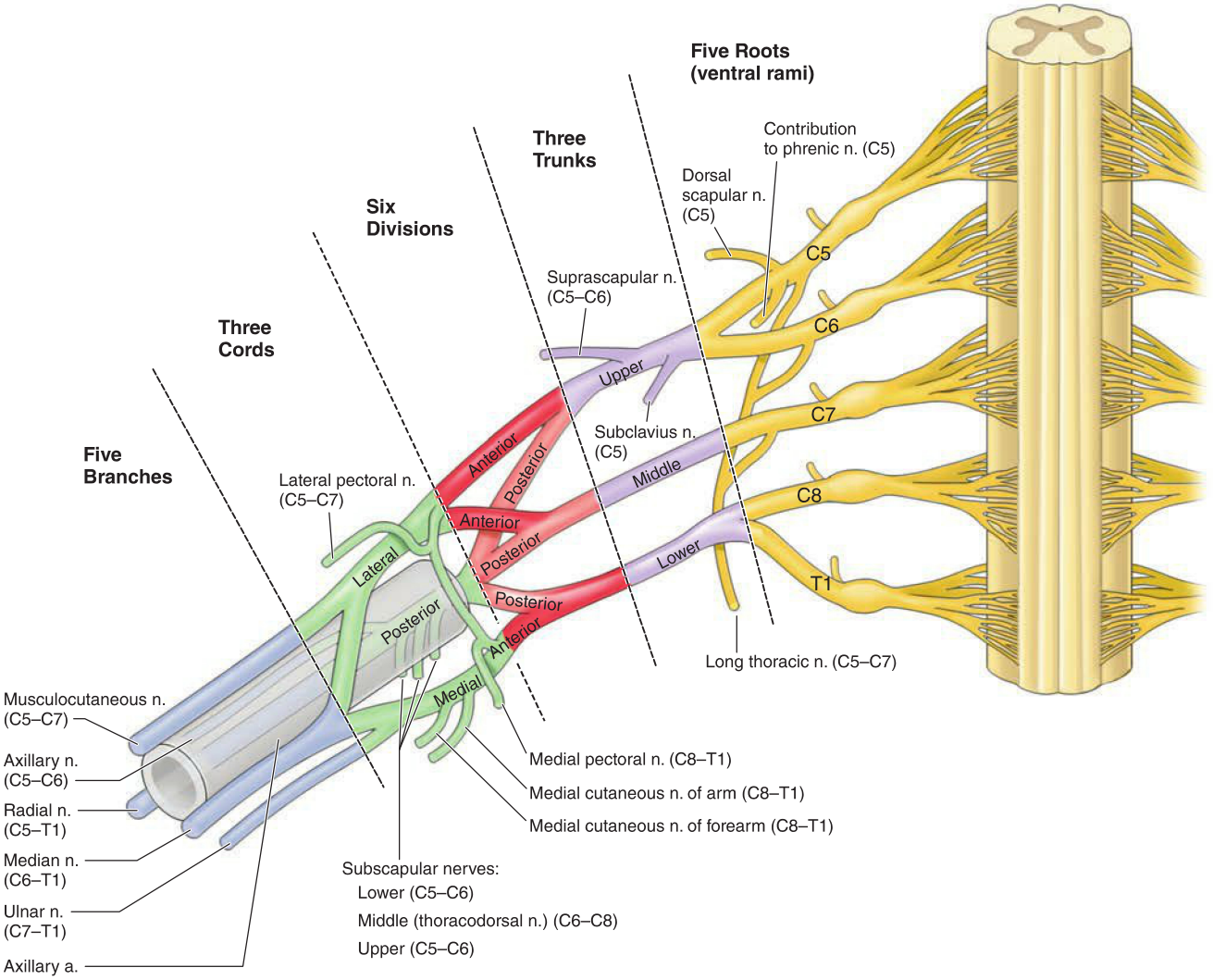

Figure 29-4: Schematic of the brachial plexus showing the branches, cords, divisions, trunks, and roots.

SENSATION OF THE UPPER LIMB

BIG PICTURE

The brachial plexus provides the pathways for sensory neurons from the skin of the upper limb to the spinal cord. Sensory innervation of the upper limb is characterized in two ways: dermatomes and cutaneous fields. A dermatome is a region of skin that is innervated by one spinal nerve level. In contrast, a cutaneous nerve provides sensory innervation from a region of skin and may consist of sensory neurons from more than one spinal nerve level.

DERMATOMES (UPPER LIMB)

A dermatome is a region of skin that is innervated by one spinal nerve level (Figure 29-5A). Therefore, all sensory neurons leaving that region of skin course to the same segmental spinal nerve level. The following are the primary places to touch in order to test specific dermatomes in the upper limb:

- **C5.** Lateral side of the elbow.
- **C6.** Dorsal surface of the proximal phalanx of the thumb.
- **C7.** Dorsal surface of the proximal phalanx of the middle finger.
- **C8.** Dorsal surface of the proximal phalanx of the little finger.
- **T1.** Medial side of the elbow.

CUTANEOUS NERVES (UPPER LIMB)

Cutaneous nerves are responsible for providing sensory innervation to a specific region of skin (often referred to as a "cutaneous field") (Figure 29-5B). The principal cutaneous nerves of the upper limb are as follows:

- **Superior lateral cutaneous nerve of the arm** (axillary nerve branch).
- **Medial cutaneous nerve of the arm** (medial cord branch).
- **Inferior lateral cutaneous nerve of the arm** (radial nerve branch).
- **Lateral cutaneous nerve of the forearm** (musculocutaneous nerve branch).
- **Medial cutaneous nerve of the forearm** (medial cord branch).
- **Posterior cutaneous nerve of the forearm** (radial nerve branch).
- **Superficial branch of the radial nerve.**
- **Dorsal, palmar and digital branches of the ulnar nerve.**
- **Palmar and digital branches of the median nerve.**

Cutaneous nerves are considered "sensory-only" but it should be remembered that they also distribute sympathetic nerves to cutaneous organs like sweat glands.

Localizing nerve injuries. Understanding the similarities and differences of cutaneous and dermatomal innervation may provide helpful information when localizing the location of nerve injuries. In other words, lesions to cutaneous nerves will most likely present differently than lesions to spinal roots. For example, if the lateral cutaneous nerve of the forearm is damaged, a loss of sensation will occur along the lateral side of the forearm, whereas sensation to the side of the hand will remain intact. Therefore, this could result in loss of sensation to a cutaneous field (lateral forearm) and yet retain partial sensation to the rest of the C6 dermatome (lateral hand). In contrast, injury to the C6 nerve root results in sensory loss along the C6 dermatome (lateral forearm and hand). However, the region of the C7 dermatome supplied by the musculocutaneous nerve would remain unaffected.

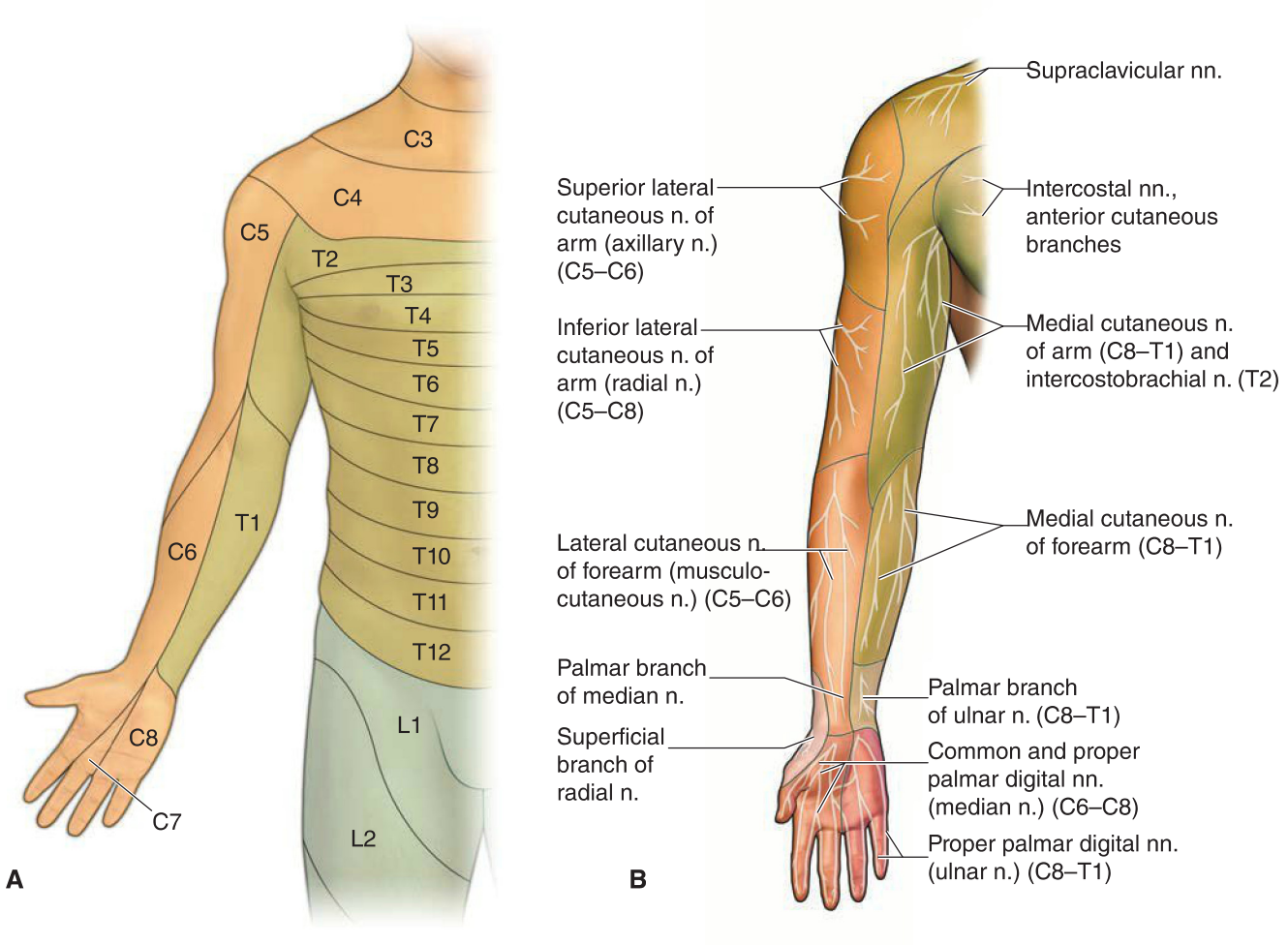

Figure 29-5: Sensory innervation of the upper limb: dermatomes (**A**) and cutaneous fields (**B**).

VASCULARIZATION OF THE UPPER LIMB

BIG PICTURE

The subclavian artery and its subsequent branches supply the upper limb. The right subclavian artery arises from the brachiocephalic artery, and the left subclavian artery from the aortic arch. Blood is returned to the heart via a superficial and a deep venous system. Given that the deep venous system follows the arteries, most deep veins have the same name as their accompanying arteries.

ARTERIES

The **subclavian artery** becomes the **axillary artery** as it crosses over the lateral border of the first rib (Figure 29-6A). The axillary artery continues distally and becomes the **brachial artery** at the inferior border of the teres major muscle. The brachial artery continues distally, passing over the elbow, and bifurcates into the **ulnar** and **radial arteries**. These arteries continue into the hand, where they form the **superficial** and **deep palmar arches**. Throughout the upper limb, smaller vessels branch from the larger vessels to supply structures such as muscle, bone, and joints.

VEINS OF THE UPPER LIMB

Generally, the veins of the upper limb drain into veins of the back, neck, axilla, and arm, and eventually reach the superior vena cava. The upper limb contains a deep and a superficial venous system.

- **Superficial veins.** Veins that course within the subcutaneous layer of skin and are not paired with an artery; originate in the hand and primarily consist of the following (Figure 29-6B):
  - **Basilic vein.** Travels along the medial border of the upper limb and unites with the brachial vein to become the axillary vein.
  - **Cephalic vein.** Travels along the lateral border of the upper limb and empties into the axillary vein.
  - **Median cubital vein.** Anastomotic connection of the basilic and cephalic veins in anterior region of the elbow.
- **Deep veins.** Veins located deep within the upper limb and course along with their associated artery of the same name; usually consist of two or more veins that wrap around the accompanying artery (**vena comitantes**) (Figure 29-6C). The deep veins of the upper limb are as follows (Figure 29-6D):
  - **Radial vein.** Typically paired, they accompany the radial artery; located laterally in the forearm.
  - **Ulnar vein.** Typically paired, they accompany the ulnar artery; located medially in the forearm.
  - **Brachial vein.** Typically paired, they accompany the brachial artery; located medially in the arm.
  - **Axillary vein.** Formed by the union of the brachial and basilic veins at the lower border of the teres major muscle; its terminal part receives the cephalic vein.
  - **Subclavian vein.** At the lateral border of the first rib the axillary vein becomes the subclavian vein; courses across the anterior scalene muscle to unite with the internal jugular vein forming the brachiocephalic vein.

LYMPHATICS OF THE UPPER LIMB

Lymphatic vessels and nodes in the shoulder and axillary region drain excess interstitial fluid as well as have an immunologic function.

- **Right upper limb.** Lymphatics from the right upper limb drain into the right subclavian vein via the **right lymphatic duct**.
- **Left upper limb.** Lymphatics from the left upper limb drain into the left subclavian vein via the **thoracic duct**.

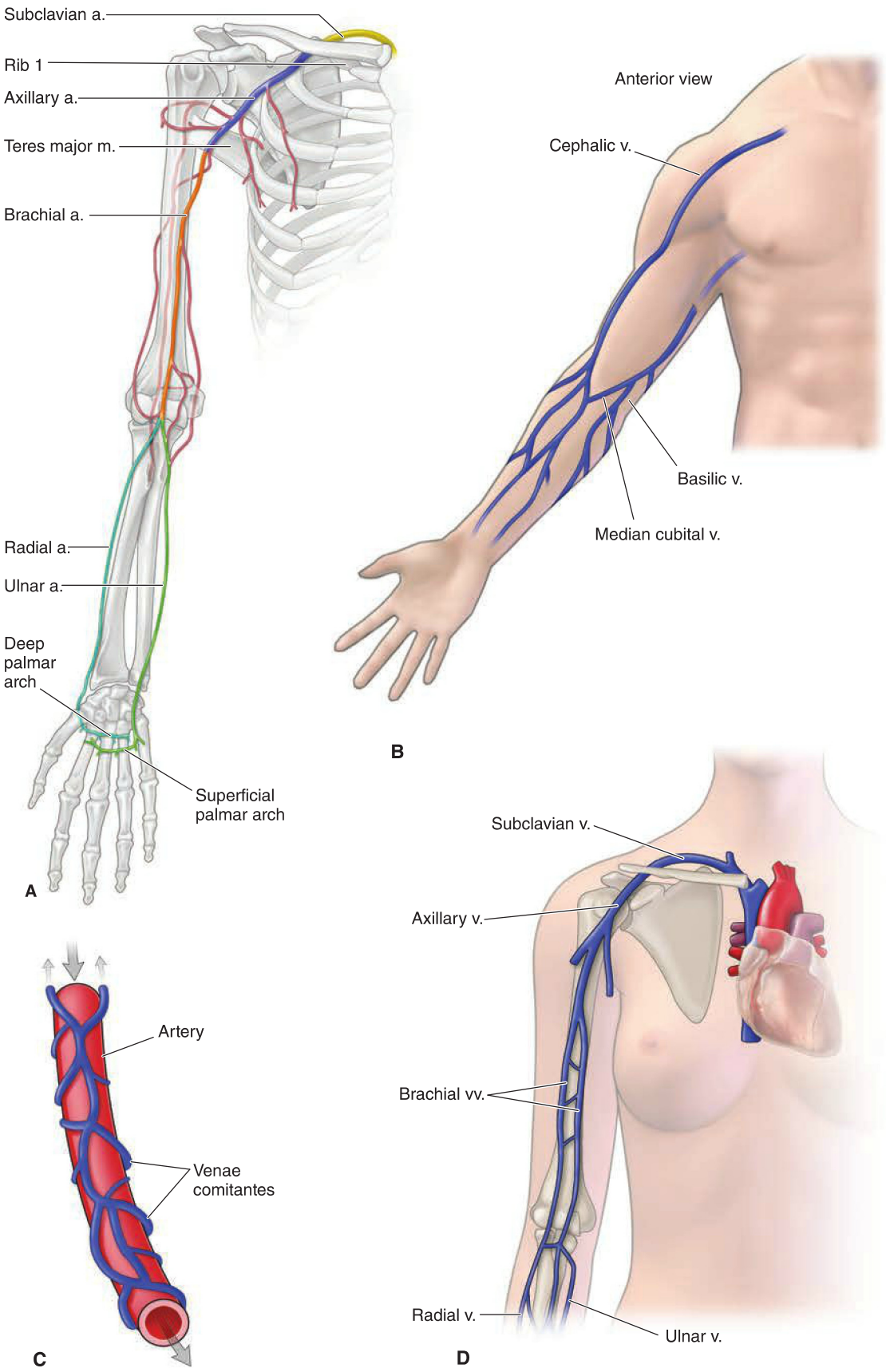

Figure 29-6: **A**. Arterial supply of the upper limb. **B**. Superficial and **C**. Schematic of the vena comitantes around an artery. **D**. Deep veins of the upper limb.

This page intentionally left blank

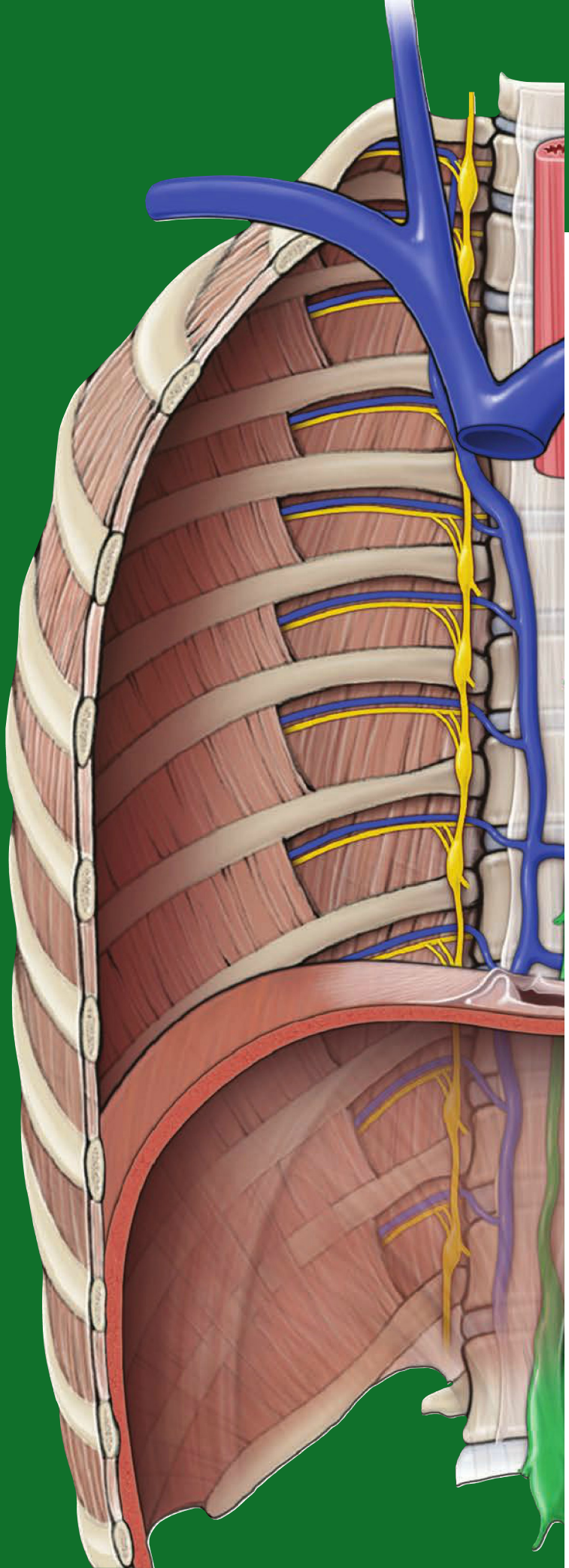

CHAPTER 30

SHOULDER AND AXILLA

Shoulder Complex 316
Muscles of the Shoulder Complex 318
Brachial Plexus of the Shoulder 322
Vascularization of the Shoulder and Axilla 324
Glenohumeral Joint 326

SHOULDER COMPLEX

BIG PICTURE

The combined joints connecting the scapula (scapulothoracic joint), clavicle (sternoclavicular and acromioclavicular joints), and humerus (glenohumeral joint) form the shoulder complex and anchor the upper limb to the trunk. The only bony stability of the upper limb to the trunk is through the connection between the clavicle and the sternum. The remaining stability of the shoulder complex depends on muscles, and as a result, the shoulder complex has a wide range of motion.

SCAPULAR SUPPORT

To best understand the actions of the scapula, it is important to understand the scapulothoracic, acromioclavicular, and sternoclavicular joints (Figure 30-1A).

- **Scapulothoracic joint.** Formed by the articulation of the scapula with the thoracic wall through the scapular muscles, including the trapezius and the serratus anterior muscles. The scapulothoracic joint is not considered a true anatomic joint; as such, it is frequently referred to as a "pseudo joint" because it does not contain the typical joint characteristics (e.g., synovial fluid and cartilage).
- **Acromioclavicular joint.** A synovial joint formed by the articulations of the acromion (scapula) and clavicle.
- **Sternoclavicular joint.** A synovial joint formed by the articulations between the clavicle and sternum.

The scapulothoracic, sternoclavicular, and acromioclavicular joints are interdependent. For example, if motion occurs at one joint (e.g., the scapula elevates), the movement will directly affect the other two joints. Therefore, the motions produced frequently involve more than a single joint. Although the scapular movements include the scapulothoracic, acromioclavicular, and sternoclavicular joints, we will refer only to the scapula in the following text.

MOVEMENTS OF THE SCAPULA

The following terms describe the movements of the scapula (Figure 30-1B):

- **Protraction (abduction).** Anterolateral movement of the scapula on the thoracic wall.
- **Retraction (adduction).** Posteromedial movement of the scapula on the thoracic wall.
- **Elevation.** Raising the scapula in a superior direction.
- **Depression.** Lowering the scapula in an inferior direction.
- **Upward rotation.** Named according to the upward rotation and direction that the glenoid fossa faces.
- **Downward rotation.** Named according to the downward rotation and direction that the glenoid fossa faces.

ACTIONS OF THE GLENOHUMERAL JOINT

The glenohumeral joint is a synovial, ball-and-socket joint. The "ball" is the head of the humerus, and the "socket" is the glenoid fossa of the scapula. The glenohumeral joint is considered to be the most mobile joint in the body and produces the following actions (Figure 30-1C and D):

- **Flexion.** Anterior movement in the sagittal plane.
- **Extension.** Posterior movement in the sagittal plane.
- **Abduction.** Movement away from the body in the frontal plane.
- **Adduction.** Movement toward the body in the frontal plane.
- **Internal (medial) rotation.** Humerus rotates toward the body in the transverse plane.
- **External (lateral) rotation.** Humerus rotates away from the body in the transverse plane.
- **Circumduction.** A combination of glenohumeral joint motions that produce a circular motion.

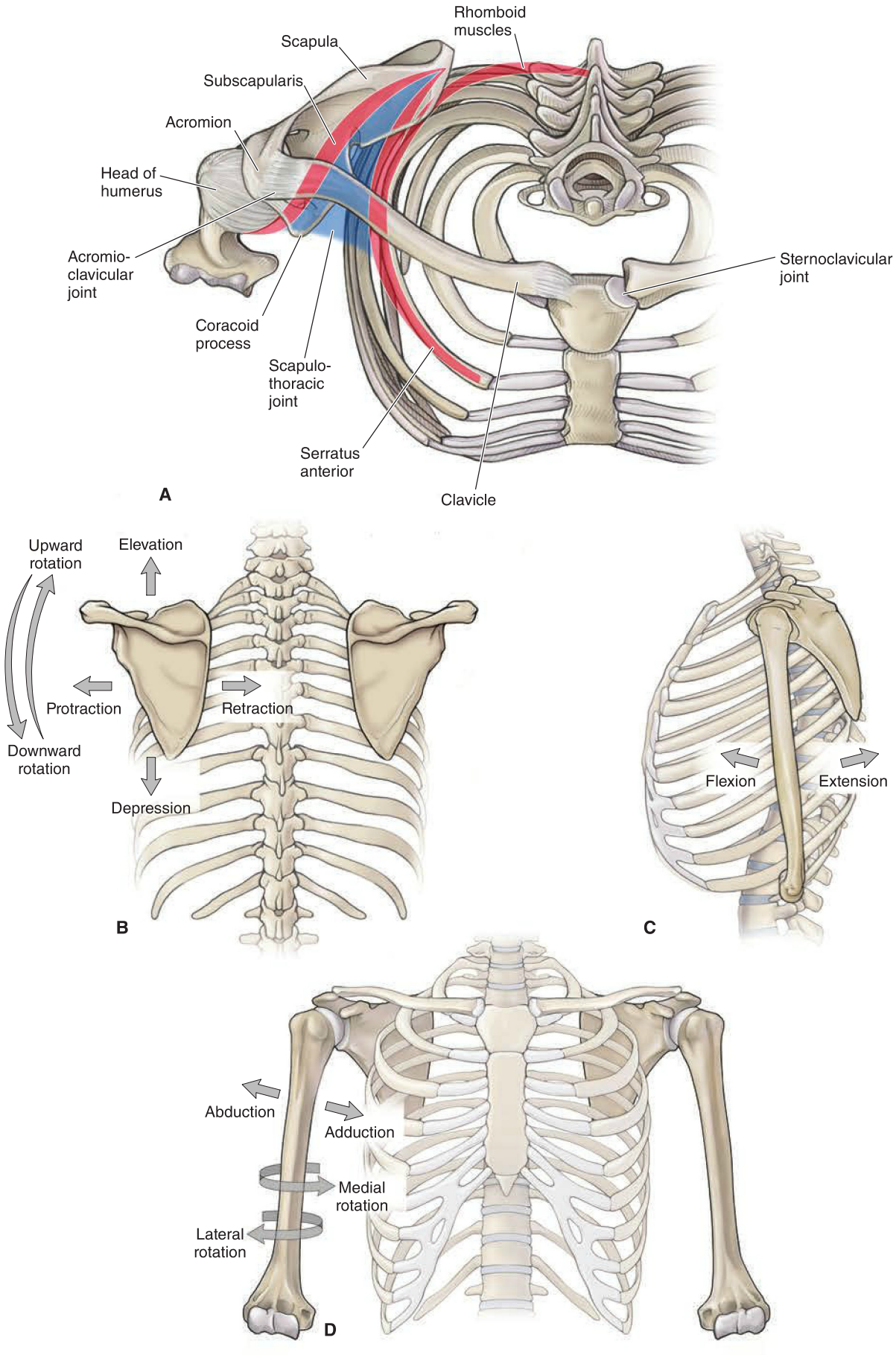

Figure 30-1: **A**. Superior view of the scapulothoracic joint. **B**. Scapular actions. **C, D**. Glenohumeral joint actions.

MUSCLES OF THE SHOULDER COMPLEX

BIG PICTURE

The musculature of the scapulothoracic joint is responsible primarily for the stability of the scapula to provide a stable base for the muscles acting on the glenohumeral joint. In other words, the upper limb must have proximal stability to have distal mobility. In addition, the scapulothoracic joint works in conjunction with the glenohumeral joint to produce movements of the shoulder. For example, the available range of motion for shoulder abduction is 180 degrees. This motion is produced by approximately 120 degrees from abduction at the glenohumeral joint and by approximately 60 degrees of upward rotation from the scapulothoracic joint.

MUSCLES OF THE SCAPULA

The following are muscles of the scapula (Figure 30-2A–C and Table 30-1):

- **Trapezius muscle.** A triangular shaped muscle in the upper back.
  - **Attachments.** Occipital bone, nuchal ligament, spinous processes of C7–T12; spine of the scapula, acromion, and lateral clavicle.
  - **Movements.** The trapezius has the following muscle fiber orientations:
    - **Superior fibers.** Course obliquely from the occipital bone and upper nuchal ligament to the scapula, producing scapular elevation and upward rotation.
    - **Middle fibers.** Course horizontally from the lower nuchal ligament and thoracic vertebrae to the scapula, producing scapular retraction.
    - **Inferior fibers.** Course superiorly from the lower thoracic vertebrae to the scapula, producing scapular depression and upward rotation.
    - The multiple fiber orientations of the trapezius muscle stabilize the scapula to the posterior thoracic wall during upper limb movement.
  - **Innervation.** Spinal accessory nerve (CN XI); receives proprioception innervation from C3-C4 ventral rami.
- **Levator scapulae muscle.** Located deep to the trapezius muscle and superior to the rhomboid muscles.
  - **Attachments.** Transverse processes of C1–C4; superior angle of the scapula.
  - **Actions.** Elevation and downward rotation of the scapula.
  - **Innervation.** Dorsal scapular nerve (C5) may receive contributions from C3 and C4.
- **Rhomboid major and minor muscles.** The rhomboid minor is superior to the rhomboid major, with both positioned deep to the trapezius muscle.
  - **Attachments.** Spinous processes of C7–T1 (minor) and T2–T5 (major); medial margin of the scapula.
  - **Actions.** Scapular retraction.
  - **Innervation.** Dorsal scapular nerve (C5).
- **Pectoralis minor muscle.** Located on the anterior thoracic wall deep to the pectoralis major muscle.
  - **Attachments.** Ribs 3–5; coracoid process of the scapula.
  - **Actions.** Protracts, depresses, and stabilizes the scapula against the thoracic wall.
  - **Innervation.** Medial pectoral nerve (C8–T1).
- **Serratus anterior muscle.**
  - **Attachments.** Ribs 1–8 along the mid-axillary line; medial margin of the scapula.
  - **Actions.** Protraction and upward rotation stabilizes the medial border of the scapula against the thoracic wall.
  - **Innervation.** Long thoracic nerve (C5–C7).
- **Subclavius muscle.**
  - **Attachments.** First rib and clavicle.
  - **Actions.** Depresses the clavicle and stabilizes the sternoclavicular joint.
  - **Innervation.** Nerve to the subclavius muscle (C5–C6).

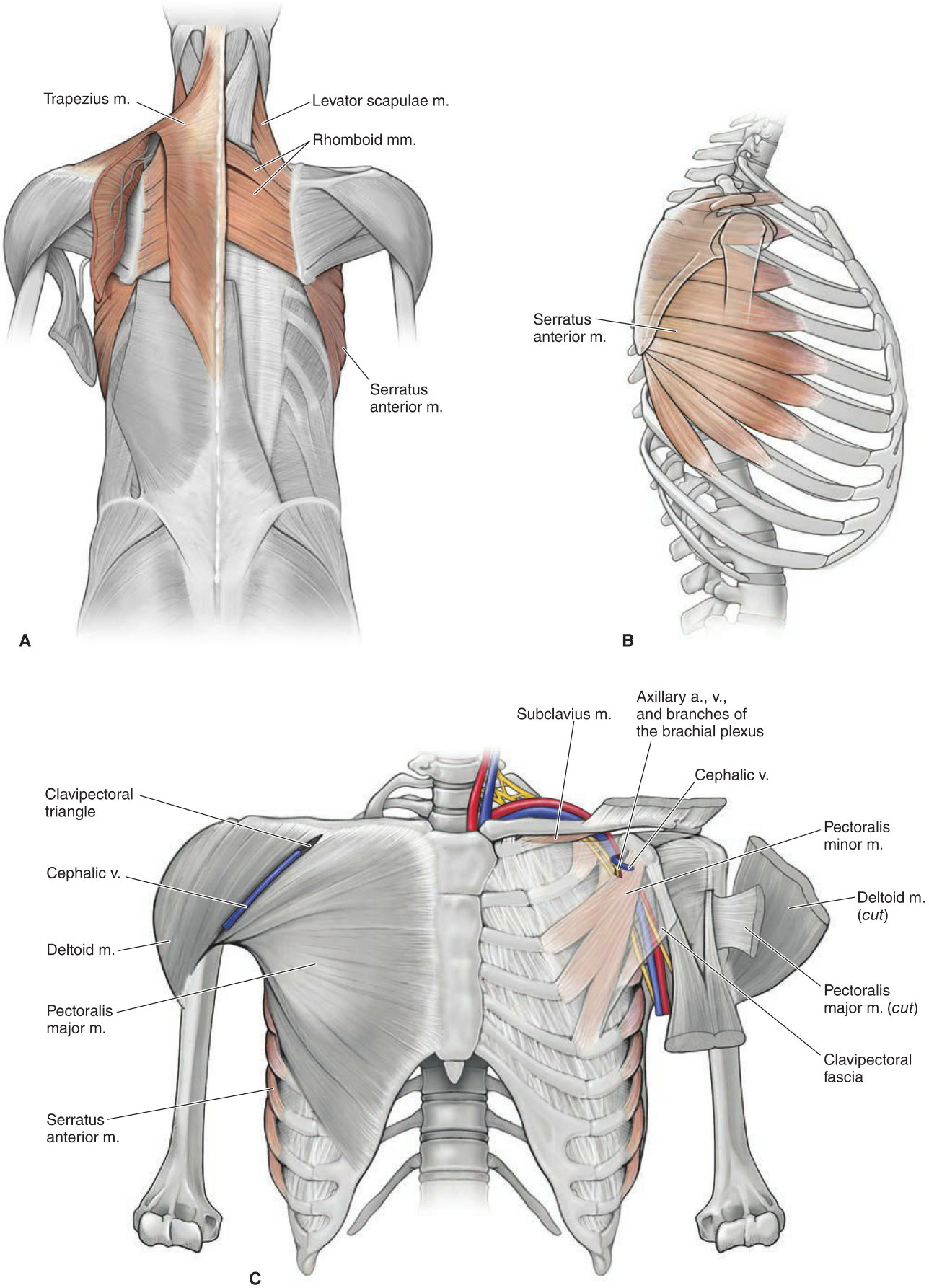

Figure 30-2: **A**. Back muscles in step dissection. **B**. Lateral view of the thorax. **C**. Anterior view of thoracic muscles.

MUSCLES OF THE GLENOHUMERAL JOINT

The following muscles and muscle groups comprise the muscles of the glenohumeral joint (Figure 30-3A–C and Table 30-2).

- **Rotator cuff muscles.** Consist of four muscles (supraspinatus, infraspinatus, teres minor, and subscapularis) that form a musculotendinous cuff around the glenohumeral joint. The cuff provides muscular support primarily to the anterior, posterior, and superior aspects of the joint (the first letter of each muscle forms an acronym known as **SITS**).
  - **Supraspinatus muscle.**
    - **Attachments.** Supraspinous fossa; courses under the acromion to attach to the greater tubercle of the humerus.
    - **Actions.** Abduction of the humerus; most active during initial 15 degrees of abduction.
    - **Innervation.** Suprascapular nerve (C5–C6).
  - **Infraspinatus muscle.**
    - **Attachments.** Infraspinous fossa; courses posterior to the glenohumeral joint and attaches to the greater tubercle of the humerus.
    - **Actions.** External rotation of the humerus.
    - **Innervation.** Suprascapular nerve (C5–C6).
  - **Teres minor muscle.**
    - **Attachments.** Lateral border of the scapula; greater tubercle of the humerus.
    - **Actions.** External rotation of the humerus.
    - **Innervation.** Axillary nerve (C5–C6).
  - **Subscapularis muscle.**
    - **Attachments.** Subscapular fossa; lesser tubercle of the humerus.
    - **Actions.** Medial rotation of the humerus.
    - **Innervation.** Upper and lower subscapular nerves (C5–C6).

Rotator cuff injury. A tear of the rotator cuff usually involves a tear of one or more of the rotator cuff muscles or their associated tendons. The most frequently injured muscle or tendon is the supraspinatus muscle. Most injuries occur as the result of overuse (usually repetitive overhead activities). However, traumatic injuries also occur as the result of a shoulder dislocation, lifting injury, or a fall.

- **Deltoid muscle.** A triangular shaped muscle on the lateral region of the shoulder.
  - **Attachments.** Spine of the scapula, acromion, clavicle; deltoid tuberosity of the humerus.
  - **Actions.** Flexion, abduction, and extension of the humerus.
  - **Innervation.** Axillary nerve (C5–C6).
- **Intertubercular groove muscles.** This group of muscles is named because of their common insertion into the intertubercular sulcus of the humerus.
  - **Pectoralis major muscle.** A large muscle on the anterior thoracic wall consisting of a clavicular head and a sternocostal head.
    - **Attachments.** One head arises from the clavicle and the other the sternum and costal margins; inserts into the lateral lip of the intertubercular groove over the long head of the biceps brachii tendon.
    - **Actions.** Flexion, adduction, and medial rotation of the humerus.
    - **Innervation.** Clavicular head (lateral pectoral nerve; C5–C7); sternocostal head (medial pectoral nerve; C8–T1).
  - **Latissimus dorsi muscle.** A broad, flat muscle of the lower region of the back.
    - **Attachments.** Spinous processes of T7 sacrum via the **thoracolumbar fascia**; intertubercular groove of the humerus.
    - **Actions.** Adduction, extension, and medial rotation of the humerus.
    - **Innervation.** Thoracodorsal nerve (C6–C8).
  - **Teres major muscle.**
    - **Attachments.** Inferior angle of the scapula and intertubercular groove.
    - **Actions.** Adduction, extension, and medial rotation of the humerus.
    - **Innervation.** Lower subscapular nerve (C5–C6).

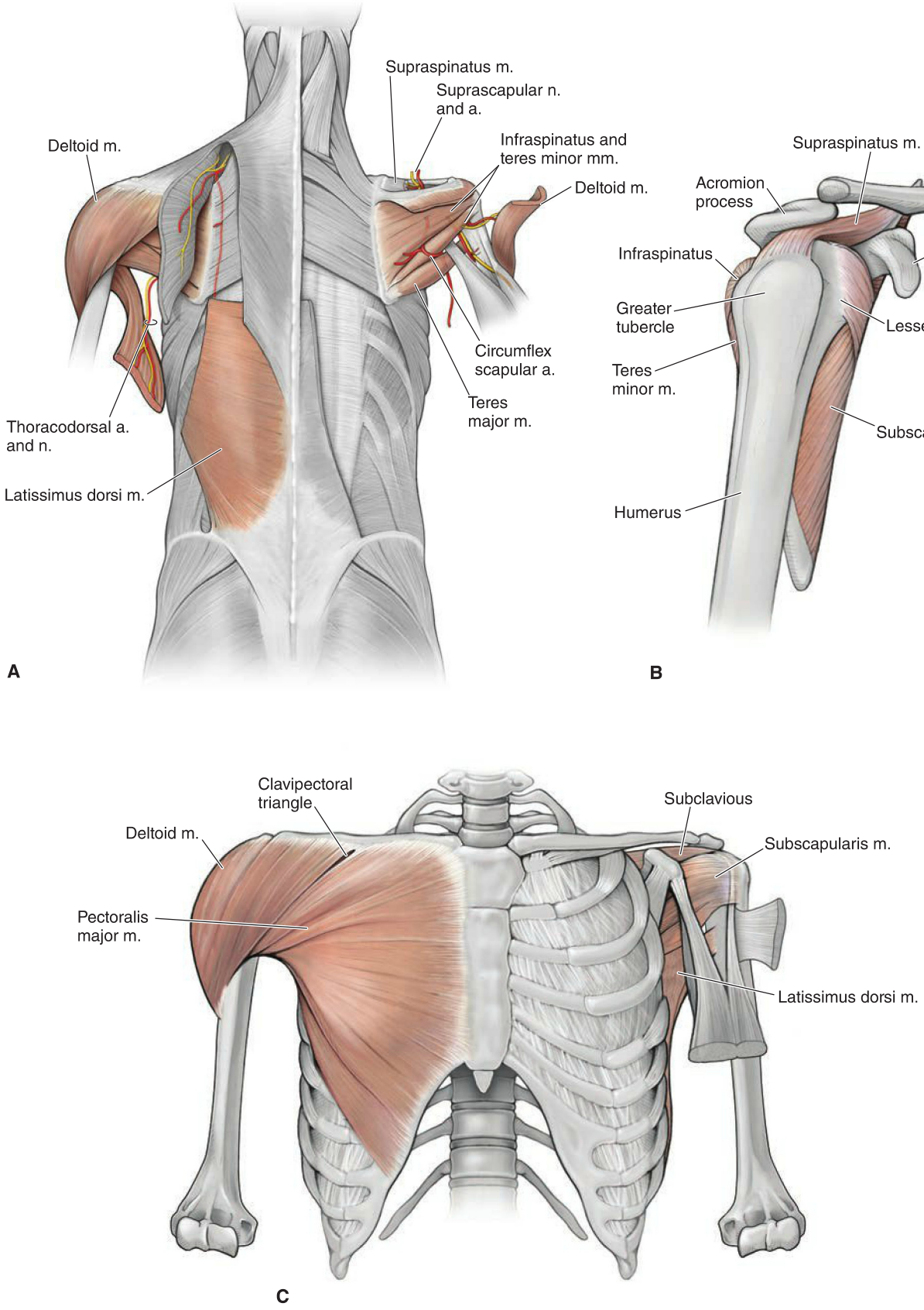

Figure 30-3: A. Muscles of the glenohumeral joint (posterior view). **B**. Lateral view of the rotator cuff muscles supporting the glenohumeral joint. **C**. Muscles of the glenohumeral joint (anterior view).

BRACHIAL PLEXUS OF THE SHOULDER

BIG PICTURE

The brachial plexus (C5–T1) innervates the upper limb via roots, trunks, divisions, cords, and terminal branches. The roots, trunks, and cords primarily innervate shoulder anatomy with contribution from the axillary nerve.

ROOTS

The roots of the brachial plexus are a continuation of the ventral rami of C5–T1 and are located between the anterior and middle scalene muscles with the subclavian artery (Figure 30-4A).

- The dorsal and ventral roots arise directly from the spinal cord. The dorsal root contains the dorsal root ganglion (DRG) and relays sensory information. The ventral root relays motor information. The roots come together and form the spinal nerve and then divide into the ventral and dorsal rami. When discussing the brachial plexus, the term "root" refers to the ventral ramus and not the ventral or dorsal root that come directly from the cord.

Each individual root of the brachial plexus (C5–T1) supplies the sensory and motor contributions for its associated dermatome and myotome. For example, the C7 root transports sensory neurons from the C7 dermatome and motor neurons to the C7 myotome.

The following nerves arise from the roots:

- **Dorsal scapular nerve (C5).** Branches off the C5 root, pierces the middle scalene muscle, and descends deep to and innervates the levator scapulae and rhomboid major and minor muscles; courses with the deep branch of the transverse cervical artery.
- **Long thoracic nerve (C5–C7).** Branches off the C5–C7 roots, descends vertically deep to the roots of the brachial plexus and axillary artery, and innervates the serratus anterior muscle; parallels the lateral thoracic artery. The long thoracic nerve is one of the few nerves found superficially instead of deep to its associated muscle.

▽ **Winged scapula.** Injury to the long thoracic nerve results in paralysis of the serratus anterior muscle. This presents when a patient is instructed to push his/her arms against the wall and the medial border of the scapula sticks straight out of the back (winged scapula). ▼

TRUNKS

The superior trunk is formed by the union of the C5 and C6 roots and thus the pathway for all motor and sensory neurons from these two segmental levels (Figure 30-4A). In other words, the superior trunk transports:

- Sensory neurons from the C5 and C6 dermatomes to the spinal cord.
- Motor neurons to muscles associated with the C5 myotome (shoulder abduction) and C6 myotome (elbow flexion).

The superior trunk gives rise to the following nerves:

- **Suprascapular nerve (C5, C6).** Traverses the suprascapular foramen by coursing inferior to the transverse scapular ligament (suprascapular artery and vein pass *superior* to the transverse scapular ligament), entering the supraspinous fossa. The nerve supplies the supraspinatus muscle and then curves around the great scapular (spinoglenoid) notch to supply the infraspinatus muscle.
- **Nerve to the subclavius (C5, C6).** Innervates the subclavius muscle.

▽ **Erb's palsy.** Stretching of the superior trunk will likely injure the C5 and C6 spinal roots and result in an Erb's palsy injury (i.e., neck and shoulder are stretched apart). As such, all nerves receiving contributions from C5 and C6 roots would be involved (suprascapular, musculocutaneous, axillary, upper and lower subscapular, long thoracic, and dorsal scapular nerves). Notable motor loss would likely be observed in the rotator cuff (supraspinatus, infraspinatus, teres minor, and subscapularis), deltoid, biceps brachii, and brachialis muscles. As a result, the affected upper limb would be adducted flat against the trunk wall (lack of glenohumeral abduction by deltoid and supraspinatus muscles), internally rotated (lack of external rotation from teres minor and infraspinatus muscles), and the elbow extended (lack of elbow flexion from the biceps brachii and brachialis muscles). Sensory deficits would also be noted along the lateral shoulder, arm, forearm, and hand (C5 and C6 dermatomal distribution). ▼

DIVISIONS

The divisions of the brachial plexus (anterior and posterior) consist of the following:

- **Three anterior divisions.** Give rise to lateral and medial cords, which innervates the anterior compartments of the upper limb (flexor muscles).
- **Three posterior divisions.** Give rise to the posterior cord, which innervates the posterior compartments of the upper limb (extensor muscles) (Figure 30-4A and B).

CORDS

The cords of the brachial plexus (medial, lateral, and posterior) course deep to the pectoralis minor muscle, are named for their relation to the axillary artery, and give rise to the terminal branches of the plexus. The cords are as follows (Figure 30-4A–C):

- **Medial cord.** Courses medially along the axillary artery; gives rise to the following:
  - **Medial pectoral nerve (C8, T1).** Pierces the clavipectoral fascia and innervates the pectoralis minor muscle, then pierces the pectoralis minor and innervates the sternocostal head of the pectoralis major muscle; often receives a contribution from the lateral pectoral nerve.
  - **Medial cutaneous nerve of the arm (C8–T1).** Provides cutaneous innervation to the medial side of the arm.
  - **Medial cutaneous nerve of the forearm (C8–T1).** Provides cutaneous innervation to the medial side of the forearm.

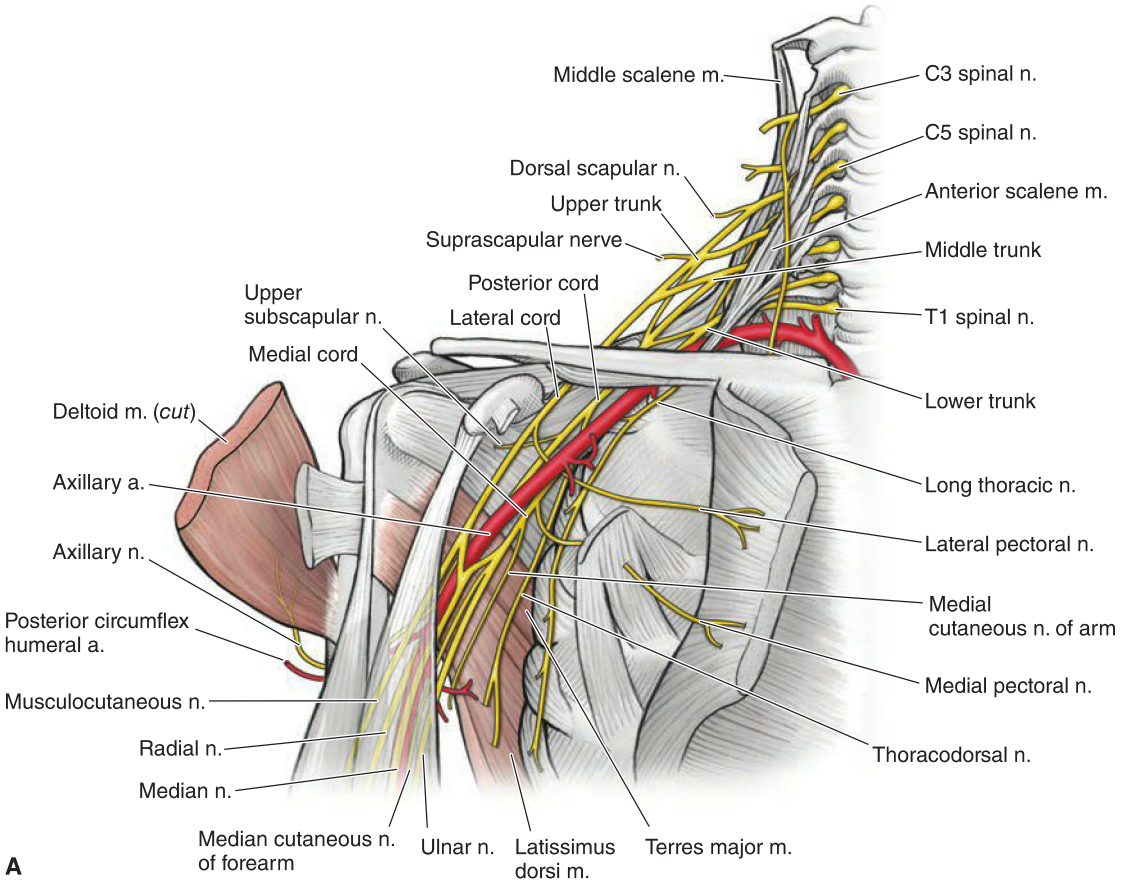

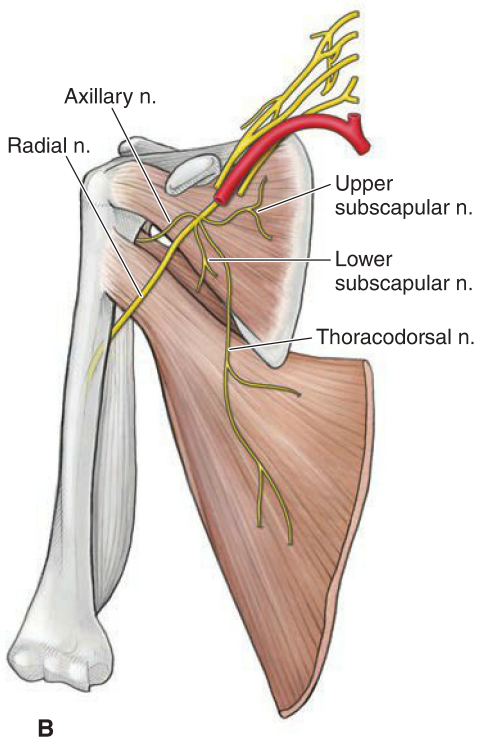

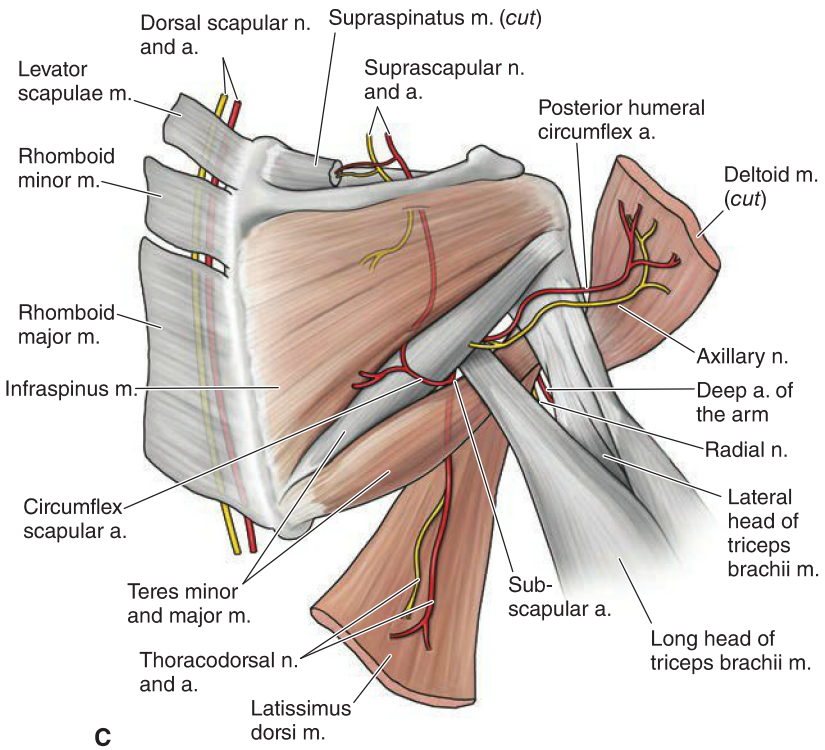

Figure 30-4: **A**. Brachial plexus and topography of the axillary artery. **B**. Posterior division of the brachial plexus. **C**. Posterior view of the shoulder.

- **Lateral cord.** Courses laterally along the axillary artery; gives rise to the following:
  - **Lateral pectoral nerve (C5–C7).** Pierces the clavipectoral fascia and innervates the clavicular head of the pectoralis major muscle; often receives a contribution from the medial pectoral nerve.
- **Posterior cord.** Courses deep to the axillary artery; gives rise to the following:
  - **Upper subscapular nerve (C5, C6).** Innervates the subscapularis muscle (superior region).
  - **Thoracodorsal (middle subscapular) nerve (C6–C8).** Accompanies the subscapular artery along the posterior region of the axilla and innervates the latissimus dorsi muscle.
  - **Lower subscapular nerve (C5, C6).** Innervates the subscapularis muscle (inferior region) and the teres major muscle.

TERMINAL BRANCHES

The primary terminal branch to supply the shoulder and axilla region is the axillary nerve (Figure 30-4A–C).

- **Axillary nerve (C5, C6).** Arises from the posterior cord, traverses the quadrangular space to enter the posterior region of the shoulder; provides the following innervation:
  - **Motor.** Teres minor and deltoid muscles.
  - **Sensory.** Skin over the lateral region of the shoulder (superior lateral cutaneous nerve of arm (C5-6)).

VASCULARIZATION OF THE SHOULDER AND AXILLA

BIG PICTURE

Blood supply to the upper limbs is provided by the subclavian arteries. The subclavian artery becomes the axillary artery at the lateral border of the first rib. The axillary artery continues distally and becomes the brachial artery at the inferior border of the teres major muscle. The brachial artery continues distally, passing over the elbow, and becomes the ulnar and radial arteries.

SUBCLAVIAN ARTERY

The left subclavian artery arises directly from the aortic arch and the right subclavian artery from the brachiocephalic trunk. The subclavian artery courses between the anterior and middle scalene muscles and then deep to the clavicle (the subclavian vein travels anteriorly to the anterior scalene). The subclavian artery has the following branches (Figure 30-5A–C):

- **Thyrocervical trunk.** Arises medially to the anterior scalene and gives rise to the following:
  - **Transverse cervical artery.** Courses over the anterior scalene muscle and branches into superficial and deep transverse cervical arteries.
    - **Superficial transverse cervical artery.** Travels deep to the trapezius muscle.
    - **Deep transverse cervical artery (dorsal scapular artery).** Travels along the medial border of the scapula deep to the rhomboid muscles; forms anastomoses with the circumflex scapular and suprascapular arteries.
  - **Dorsal scapular artery.** Occasionally, the dorsal scapular artery will branch directly off the subclavian artery. When this occurs, the deep transverse cervical artery may be absent.
  - **Suprascapular artery.** Courses superior to the transverse scapular ligament to supply the supraspinatus muscle and through the greater scapular notch to supply the infraspinatus muscle; forms collateral circuits with the circumflex scapular and dorsal scapular arteries.

AXILLARY ARTERY

The axillary artery is subdivided into three parts by its relationship to the pectoralis minor muscle (Figure 30-5A–C):

- **First part (one branch).** Superior to the pectoralis minor muscle; gives rise to one branch:
  - **Superior (supreme) thoracic artery.** Supplies the first and second intercostal spaces.
- **Second part (two branches).** Deep to the pectoralis minor muscle; gives rise to two branches:
  - **Thoracoacromial artery (trunk).** Wraps around the proximal border of the pectoralis minor muscle and gives rise to pectoral, acromial, clavicular, and deltoid branches.
  - **Lateral thoracic artery.** Courses with the long thoracic nerve along the lateral surface of the serratus anterior muscle where it supplies this muscle and surrounding tissues.
- **Third part (three branches).** Inferior to the pectoralis minor muscle; gives rise to three branches:
  - **Subscapular artery.** Courses along the anterior surface of the subscapularis muscle and gives rise to two branches:
    - **Circumflex scapular artery.** Traverses the triangular space to the posterior side of the scapula (forms an anastomosis with the suprascapular and dorsal scapular arteries).
    - **Thoracodorsal artery.** Courses with the thoracodorsal nerve supplying the latissimus dorsi muscle.
  - **Anterior humeral circumflex artery.** Wraps anteriorly around the surgical neck of the humerus and forms an anastomosis with the posterior humeral circumflex artery.
  - **Posterior humeral circumflex artery.** Traverses the quadrangular space with the axillary nerve, wraps posteriorly around the surgical neck of the humerus, and forms anastomoses with the anterior humeral circumflex artery.

▼ **Collateral arterial supply of the shoulder.** If the subclavian artery is surgically clamped or a segment is removed, blood can bypass the blockage and continue to supply the upper limb. The reason this occurs is due to the rich shoulder anastomosis between the dorsal scapular, supraclavicular, and posterior humeral circumflex arteries (Figure 30-5C). ▼

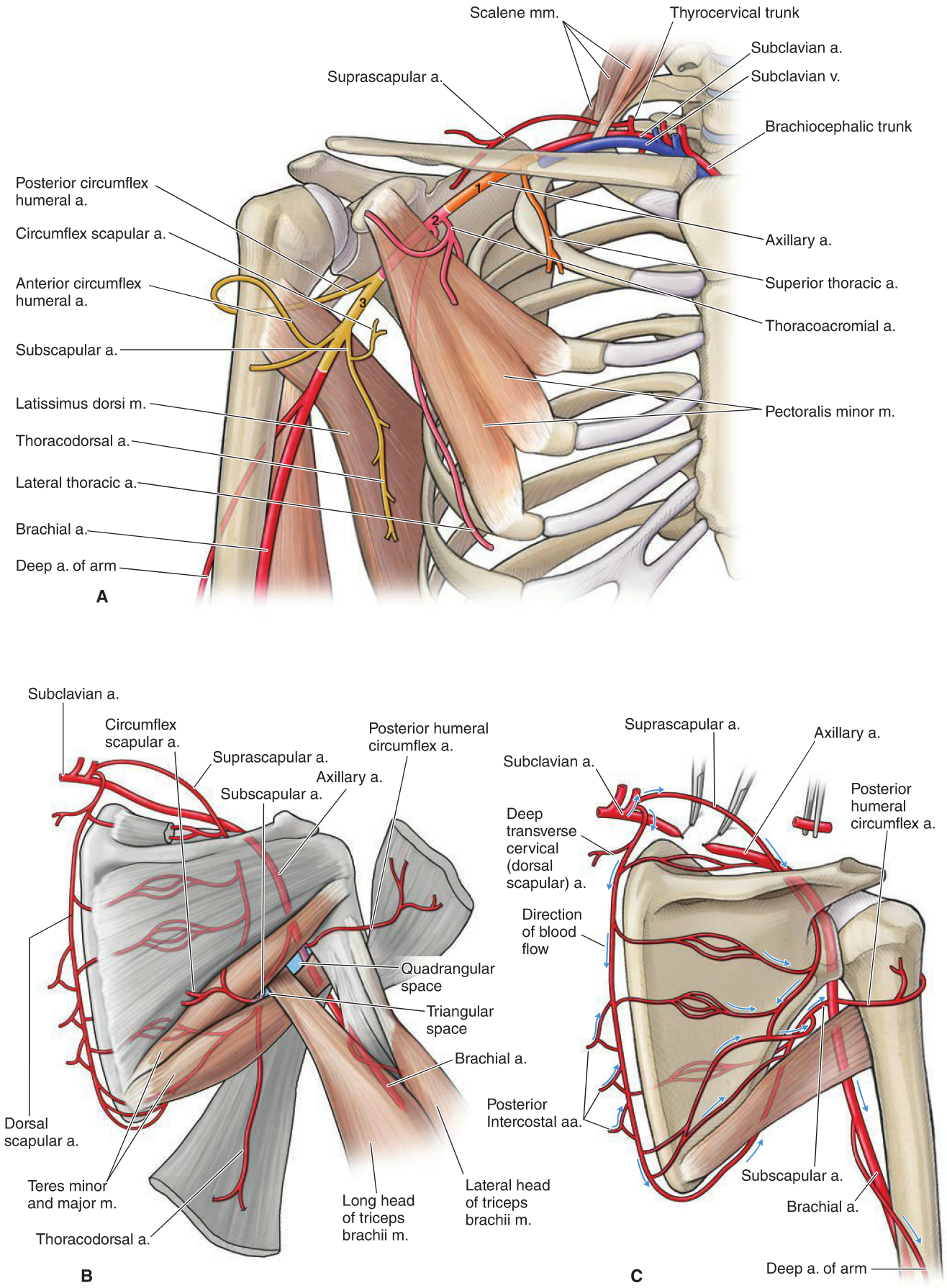

Figure 30-5: **A**. Branches of the subclavian and axillary arteries. **B**. Posterior view of the shoulder arteries. **C**. Anastomoses of the shoulder arteries.

ANATOMIC SPACES

The following anatomic spaces are helpful in locating the neurovascular structures in the posterior scapular region (Figure 30-5B):

- **Quadrangular space.** A four-sided space formed by the humerus and the teres major, teres minor, and long head of the triceps brachii muscles.
  - **Contents.** Axillary nerve and posterior humeral circumflex artery.
- **Triangular space.** Formed by the teres major, teres minor, and long head of the triceps brachii muscle.
  - **Contents.** Circumflex scapular artery.

VEINS OF THE SHOULDER AND AXILLA

The veins of the shoulder region consist of a deep and a superficial venous system.

- **Deep venous system.** Veins located deep within the shoulder and course along with their associated artery of the same name. Typically 2 or more veins are associated with each artery (venae comitantes). The deep veins are as follows:
  - **Brachial vein.** Radial and ulnar veins unite to become the brachial vein, which forms venae comitantes around the brachial artery; conveys blood from the forearm and hand to the axillary vein.
  - **Axillary vein.** Formed by the union of the brachial and basilic veins; the cephalic vein joins the terminate region of the axillary vein.
    - The axillary vein becomes the subclavian vein at the lateral border of the first rib.
- **Superficial venous system.** Veins that course within the subcutaneous layer of skin and are not paired with an artery; the superficial veins are as follows:
  - **Basilic vein.** Courses along the medial side of the forearm and perforates the deep fascia of the arm proximal to the medial epicondyle. Near the inferior border of the teres major muscle the basilic vein joins the brachial veins and forms the axillary vein.
  - **Cephalic vein.** Courses superficially and laterally along the arm and into the deltopectoral triangle before diving to join the axillary vein.
    - After the axillary vein crosses the lateral border of the first rib, it becomes the subclavian vein.

GLENOHUMERAL JOINT

BIG PICTURE

The glenohumeral joint is a ball-and-socket synovial joint that produces a considerable range of motion including flexion and extension, abduction and adduction, and internal and external rotation. Due to this great mobility ligaments and muscles are needed for added structural support. To minimize friction, bursae (synovial sacs) are positioned around the shoulder joint.

STRUCTURE OF THE GLENOHUMERAL JOINT

The articulating surface of the **glenoid cavity** is approximately one-third the size of the articulating surface of the **humeral head** (Figure 30-6A). This disproportionate articulation results in increased range of motion. However, it also results in a joint that is not as stable as other ball-and-socket joints (e.g., hip). To compensate for this lack of stability, a cartilaginous cuff called the **glenoid labrum** enhances and deepens the articulating surface of the glenoid fossa. The capsule of the **glenohumeral joint** is loose, which enables a large degree of motion.

LIGAMENTOUS SUPPORT TO THE GLENOHUMERAL JOINT

The following ligaments provide support to the glenohumeral joint (Figure 30-6B):

- **Joint capsule (glenohumeral ligaments).** Regions of the glenohumeral joint capsule have thickened regions to add increased support to the superior, anterior, and inferior joint and are named superior, middle, and inferior glenohumeral ligaments respectively. The inferior region of the joint capsule possesses an **axillary fold** to allow increased range of motion during abduction.
- **Coracoacromial ligament.** Supports the superior aspect of the glenohumeral joint to prevent superior dislocation by forming an arch over the superior aspect of the humeral head.

BURSAE

Bursae help decrease the friction between two moving structures such as tendon and bone (Figure 30-6C). In the shoulder complex, and especially the glenohumeral joint, the bursae are important because of the complexity of the muscular stability and the high degree of mobility. The **two most important bursae in the shoulder complex** are as follows:

- **Subacromial bursa.** Separates the supraspinatus tendon and the head of the humerus from the acromion.
- **Subdeltoid bursa.** Separates the deltoid muscle from the joint capsule. The subdeltoid bursa is continuous with the subacromial bursa.

MUSCULAR SUPPORT

Any muscle that crosses the glenohumeral joint and produces a compressive force between the head of the humerus and the glenoid cavity will produce joint stability (Figure 30-6D). Muscular stability is best exemplified by the **rotator cuff muscles**, which provide support to all sides, except the inferior aspect of the glenohumeral joint.

- **Supraspinatus muscle.** Provides superior support.
- **Infraspinatus muscle.** Provides posterior support.
- **Teres minor muscle.** Provides posterior support.
- **Subscapularis muscle.** Provides anterior support.

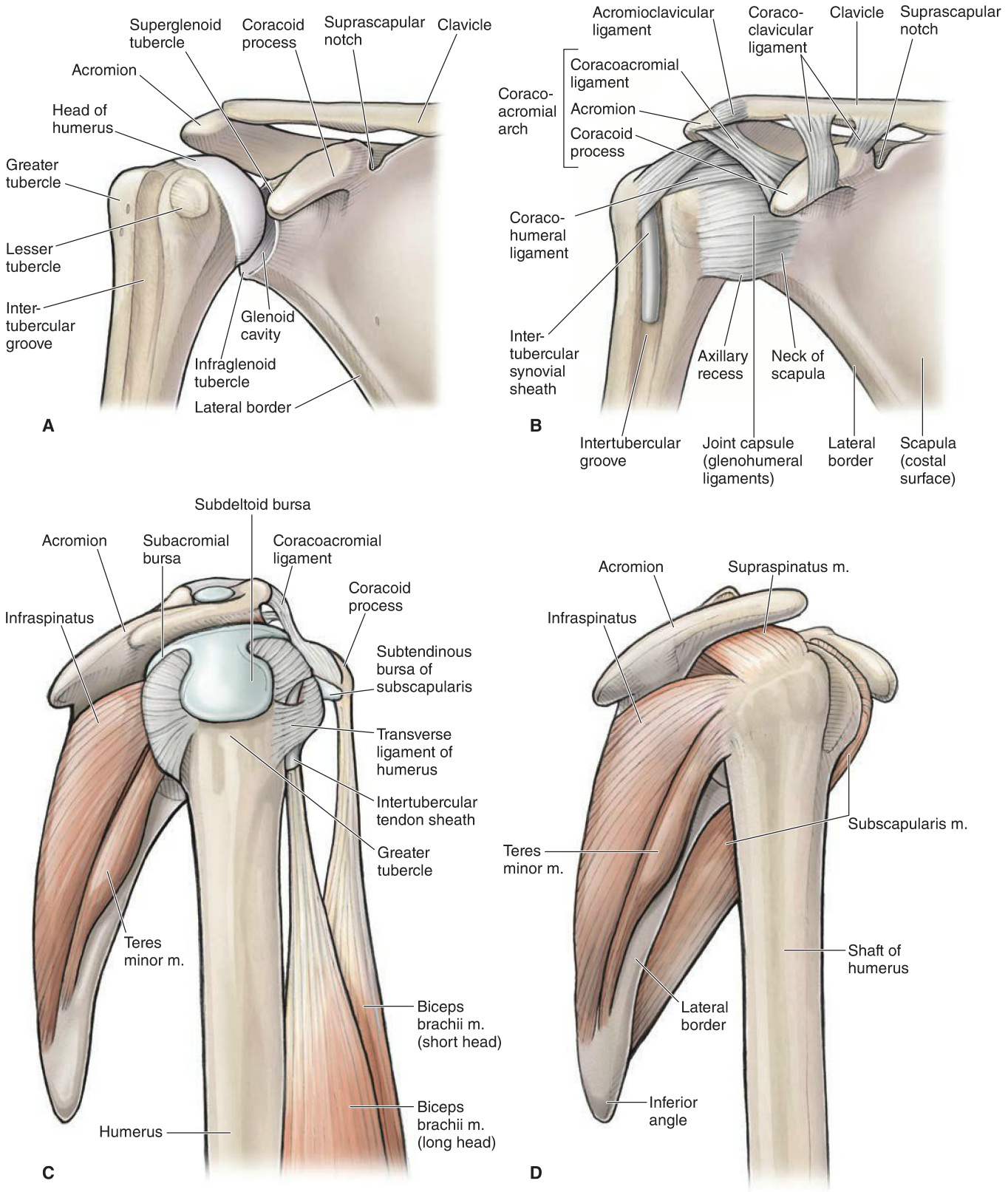

Figure 30-6: **A**. Glenohumeral joint. **B**. Joint capsule of the glenohumeral joint. **C**. Rotator cuff with associated bursae. **D**. Rotator cuff from a lateral view.

In addition to the support of the rotator cuff musculature, the long head of the biceps brachii and deltoid muscles assist in the support of the glenohumeral joint:

- **Long head of the biceps brachii muscle.** Provides superior and anterior support.
- **Deltoid muscle.** Provides superior support.

A combination of ligamentous and dynamic muscle support of multiple joints is critical for the stability of the shoulder complex because of the laxity of the capsule and the large degree of mobility.

▼ A **Superior Labrum Anterior and Posterior (SLAP) tear** is an injury that usually results from an activity such as throwing an object (e.g., pitching a baseball). The result is a tear of the labrum from the glenoid. A SLAP tear is thought to be due to the long head of the biceps tendon pulling on the superior labrum when the humerus decelerates during a throwing motion, resulting in a tear. ▼

▼ **Shoulder separation** is not an injury to the glenohumeral joint itself, but rather it is an injury to the acromioclavicular joint. The injury is usually caused by falling directly on the shoulder, resulting in damage or tearing of the ligaments that support the acromioclavicular joint. The clavicle may be out of alignment with the acromion of the scapula, resulting in a bump (i.e., the clavicle becomes more superior to the acromion forming a step-off deformity). The severity of this injury is determined by the amount of ligamentous damage; usually if there is more ligamentous damage, the deformity is more noticeable. ▼

TABLE 30-1. Muscles of the Scapula

Muscle	Proximal Attachment	Distal Attachment	Action	Innervation
Trapezius	Occipital bone, nuchal ligament, C7–T12 vertebrae	Spine, acromion, and lateral clavicle	Elevation, retraction, upward rotation, and depression of scapula	Spinal accessory n. and ventral rami of C3 and C4 (proprioception)
Levator scapulae	Transverse processes of C1–C4	Superior angle of scapula	Elevation and downward rotation of scapula	Dorsal scapular n. (C5) and ventral rami of C3–C4
Rhomboid minor	C7–T1 vertebrae	Medial margin of scapula	Retraction of scapula	Dorsal scapular n. (C5)
Rhomboid major	T2–T5 vertebrae			
Serratus anterior	Ribs 1–8		Protraction and upward rotation of the scapula	Long thoracic n. (C5–C7)
Pectoralis minor	Ribs 3–5	Coracoid process of scapula	Protraction, depression, and stabilization of scapula	Medial pectoral n. (C8–T1)
Subclavius	Rib 1	Clavicle	Depression and stabilization of clavicle	Nerve to the subclavius (C5–C6)

TABLE 30-2. Muscles of the Glenohumeral Joint

Muscle	Proximal Attachment	Distal Attachment	Action		Innervation
Deltoid	Spine, acromion, and lateral clavicle	Deltoid tuberosity of humerus	Flexion, extension, and abduction of the humerus		Axillary n. (C5–C6)
Rotator cuff muscles					
Supraspinatus	Supraspinous fossa	Greater tubercle of humerus	Abduction of humerus	Stabilization of shoulder joint	Suprascapular n. (C5–C6)
Infraspinatus	Infraspinous fossa		Lateral rotation of humerus		Suprascapular n. (C5–C6)
Teres minor	Lateral margin of scapula				Axillary n. (C5–C6)
Subscapularis	Subscapular fossa	Lesser tubercle of humerus	Medial rotation of humerus		Upper and lower subscapular nn. (C5–C6)
Intertubercular groove muscles					
Teres major	Inferior angle of scapula	Intertubercular groove of humerus	Adduction, extension, and medial rotation of humerus		Lower subscapular (C5–C6)
Pectoralis major	Clavicle, sternum, and costal cartilage		Adduction, medial rotation, and flexion of humerus		Medial and lateral pectoral nn. (C5–T1)
Latissimus dorsi	T7–T12, sacrum, and thoracolumbar fascia		Adduction, extension, and medial rotation of humerus		Thoracodorsal n. (C6–C8)

This page intentionally left blank

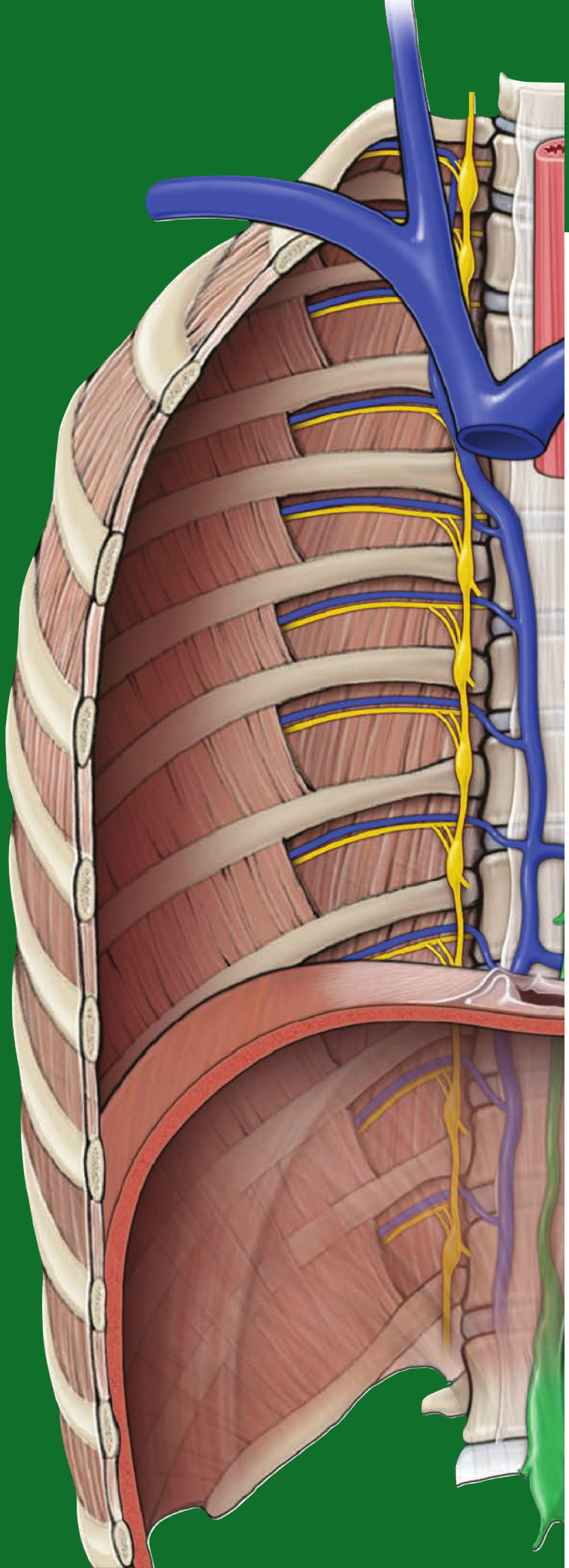

CHAPTER 31

ARM

Arm 332

Muscles of the Arm 332

Terminal Branches of the Brachial Plexus in the Arm 334

Vascularization of the Arm 334

Joints Connecting the Arm and Forearm 336

ARM

BIG PICTURE

The arm, or brachial region, contains the humerus and is located between the shoulder and elbow. The humerus articulates with the forearm (antebrachium) at the elbow complex, which consists of three bones: humerus, ulna, and radius. The articulations of these bones result in three separate joints that share a common synovial cavity, enabling the forearm to flex, extend, pronate, and supinate on the humerus.

ACTIONS OF THE ELBOW COMPLEX

The elbow complex consists of the joints and actions (Figure 31-1A–C):

- **Humeroulnar joint.** Articulation between the humerus (trochlea) and ulna (trochlear notch).
- **Humeroradial joint.** Articulation between the humerus (capitulum) and radius (head).
  - **Flexion.** Bending of the elbow (i.e., biceps brachii and brachialis muscles; musculocutaneous nerve).
  - **Extension.** Straightening of the elbow (i.e., triceps brachii muscle; radial nerve).
- **Proximal radioulnar joint.** Articulation between the radius (head) and ulna (radial notch).
  - **Pronation.** Pivoting the elbow (forearm) into the prone position (palms down) (i.e., pronator teres muscle; median nerve).
  - **Supination.** Pivoting the elbow (forearm) into the supine position (palms up) (biceps brachii muscle; musculocutaneous nerve).

MUSCLES OF THE ARM

BIG PICTURE

The muscles of the arm are divided by their fascial compartments (anterior and posterior), and primarily act on the elbow. Identifying the joints that the muscles cross provides useful insight into the actions of these muscles (Table 31-1).

MUSCLES OF THE ANTERIOR COMPARTMENT OF THE ARM

The muscles in the anterior compartment of the arm have the following in common:

- **Common action.** Flexion of the elbow (due to their anterior orientation to the humeroulnar hinge joint).
- **Common innervation.** Musculocutaneous nerve (C5–C7).

The following muscles are within the anterior compartment of the arm (Figure 31-1D):

- **Biceps brachii muscle.** A two-headed muscle (long and short heads) located superficially in the arm.
  - **Attachments.** Scapula (long head = supraglenoid tubercle; short head = coracoid process) and radius (radial tuberosity).
  - **Actions.** The biceps brachii crosses anterior to, and therefore flexes, both the glenohumeral and elbow joints. Due to its distal attachment to the radius the biceps brachii will also supinate the radioulnar joint.
  - **Innervation.** Musculocutaneous nerve (C5–C7).
- **Brachialis muscle.** Located deep to the biceps brachii muscle.
  - **Attachments.** Humeral mid-shaft and ulna (coranoid process).
  - **Actions.** Elbow joint flexion; attaches on the ulna and therefore primarily acts on the humeroulnar hinge joint.
  - **Innervation.** Musculocutaneous nerve (C5–C6); the radial nerve (C7) innervates a small, lateral portion of the muscle.
- **Coracobrachialis muscle.** Located adjacent to the short head of the biceps brachii muscle.
  - **Attachments.** Coracoid process (scapula) and humerus (mid-shaft).
  - **Actions.** Glenohumeral joint flexion.
  - **Innervation.** Musculocutaneous nerve (C5–C7).

▼ **Biceps tendinopathy.** A painful condition where the long head of the biceps is irritated by repetitive and excessive overhead motions. This may result in inflammation of the tendon and the peripheral structures. The pain is most often described as occurring where the tendon of the long head of the biceps brachii courses within the intertubercular groove. The condition is exacerbated by the actions of the biceps (e.g., shoulder flexion, elbow flexion, and supination) and is frequently confused with pathologies of the rotator cuff. ▼

MUSCLES OF THE POSTERIOR COMPARTMENT OF THE ARM

The muscles in the posterior compartment of the arm have the following in common:

- **Common action.** Extension of the elbow (due to their posterior orientation to the humeroulnar hinge joint).
- **Common innervation.** Radial nerve (C5–T1).

The following muscle is within the posterior compartment of the arm (Figure 31-1E):

- **Triceps brachii muscle.** A three-headed muscle (long, lateral, and medial heads) located superficially in the posterior compartment of the arm.
  - **Attachments.** Scapula (long head = infraglenoid tubercle; medial and lateral heads attach to the posterior humerus) and ulna (olecranon process).
  - **Actions.** Elbow extension; the long head also extends the glenohumeral joint.
  - **Innervation.** Radial nerve (C5–C7); however, the primary spinal level responsible for extension is C7.

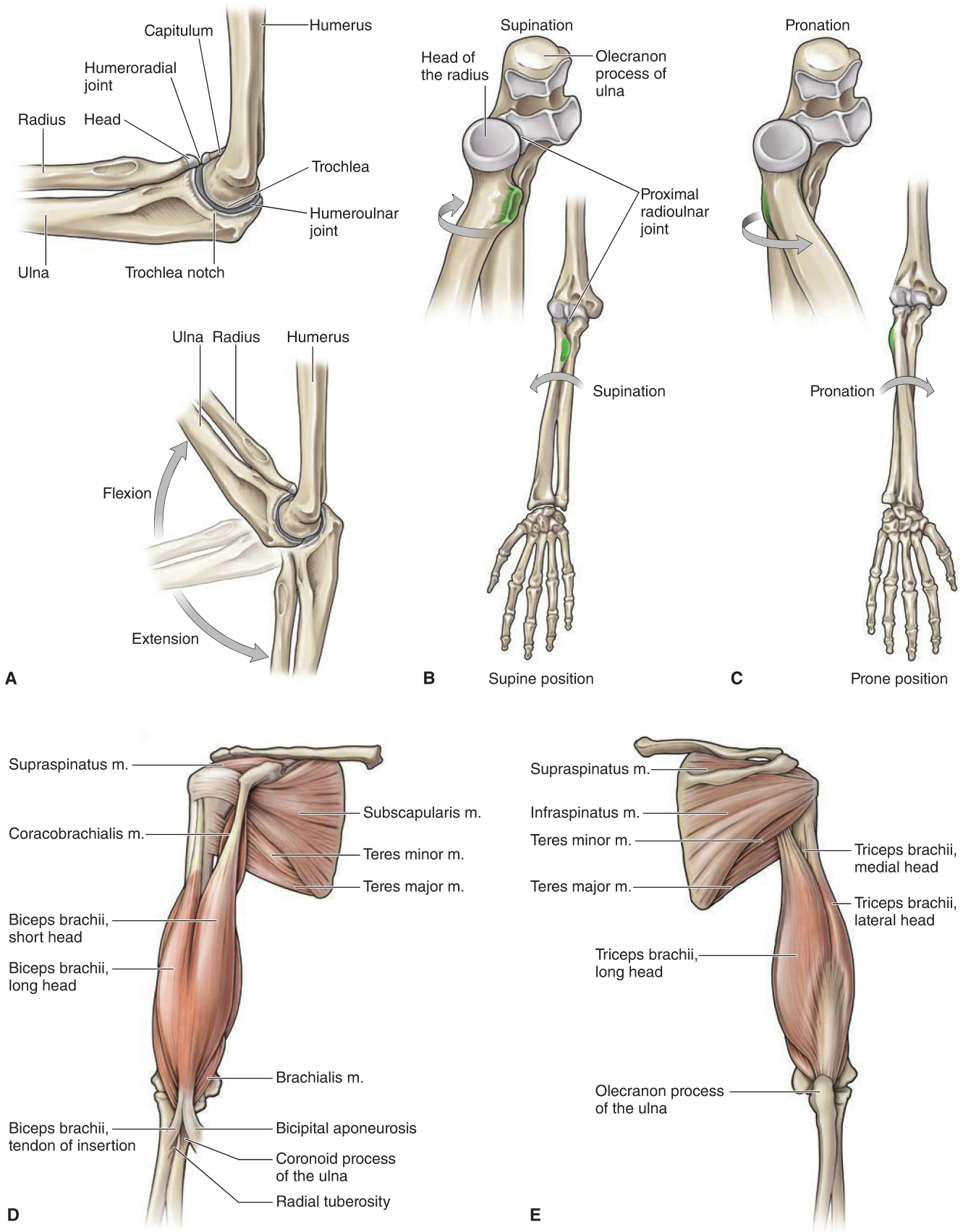

Figure 31-1: A. Lateral view of the elbow demonstrating bony landmarks and articulations. Radioulnar joint during supination (**B**) and pronation (**C**). Anterior (**D**) and posterior (**E**) views of the brachial muscles.

TERMINAL BRANCHES OF THE BRACHIAL PLEXUS IN THE ARM

BIG PICTURE

The musculocutaneous nerve innervates the muscles in the anterior compartment of the arm. The radial nerve innervates muscles in the posterior compartment of the arm. Cutaneous innervation of the arm is supplied by the radial nerve and medial cutaneous nerve of the arm.

MUSCULOCUTANEOUS NERVE

The musculocutaneous nerve has the following properties (Figure 31-2A):

- **Topography.** Arises from the lateral cord, pierces the coracobrachialis muscle, and descends through the arm between the biceps brachii and brachialis muscles and terminates as the lateral cutaneous nerve of the forearm.
- **Motor.** Muscles of the anterior compartment of the arm (biceps brachii, brachialis, and coracobrachialis).
- **Sensory.** Lateral surface of the forearm.

RADIAL NERVE

The radial nerve has the following properties (Figure 31-2B):

- **Topography.** Arises from the posterior cord and descends posterior to the humerus along the spiral groove with the deep artery of the arm; the radial nerve pierces the intermuscular septum and courses anteriorly to the lateral epicondyle between the brachialis and the brachioradialis; descends in the posterior compartment of the forearm.
- **Motor.** Muscles of the posterior compartment of the arm (triceps brachii muscle).
- **Sensory.** Cutaneous innervation via the posterior cutaneous nerve of the arm, inferior lateral cutaneous nerve of the arm, and the posterior cutaneous nerve of the forearm.

▽ **Radial neuropathy** (aka "**Saturday night palsy**"). Radial neuropathy is often caused by compression of the radial nerve as it spirals around the posterior region of the humerus (i.e., compression of nerve by the edge of a desk or chair). Although the injury occurs at the posterior humerus, symptoms are often identified in the forearm. Symptoms include decreased finger and wrist extension (wrist drop) and loss of sensation to the posterior portion of the hand. In contrast, radial neuropathy occurring in the axillary region due to the improper use of crutches will result in weakness in the triceps muscles because the injury is more proximal. ▼

MEDIAL CUTANEOUS NERVE OF THE ARM

The medial cutaneous nerve of the arm branches from the medial cord and supplies the anteromedial skin of arm.

VASCULARIZATION OF THE ARM

BIG PICTURE

The axillary artery supplies the arm and becomes the brachial artery after crossing the inferior border of the teres major muscle.

BRACHIAL ARTERY

The brachial artery courses through the medial side of the arm and terminates anteriorly at the elbow when it bifurcates into the radial and ulnar arteries. The brachial artery gives rise to the following branches (Figure 31-2C–D):

- **Deep artery of arm (profunda brachii artery, deep brachial artery).** Descends with the radial nerve posteriorly along the spiral groove of humerus; gives rise to the following branches, which form anastomoses with the posterior circumflex humeral artery:
  - **Radial collateral artery.** Courses anteriorly to the lateral epicondyle of the humerus; forms an anastomosis with the radial recurrent artery.
  - **Middle collateral artery.** Courses along the posterior humerus; forms an anastomosis with the recurrent interosseous artery.
- **Superior ulnar collateral artery.** Courses posteriorly to the medial epicondyle of the humerus; forms an anastomosis with the posterior ulnar recurrent artery.
- **Inferior ulnar collateral artery.** Bifurcates around the medial epicondyle of the humerus; forms an anastomosis with the anterior recurrent ulnar artery and the middle collateral artery.

▽ **Mid-humeral fracture.** A mid-humeral fracture is often caused by a fall and depending on the severity of the injury may injure the radial nerve due to its proximal nature along the spiral groove. The radial nerve may be involved because of the displaced humerus resulting in transient or permanent damage to the radial nerve. ▼

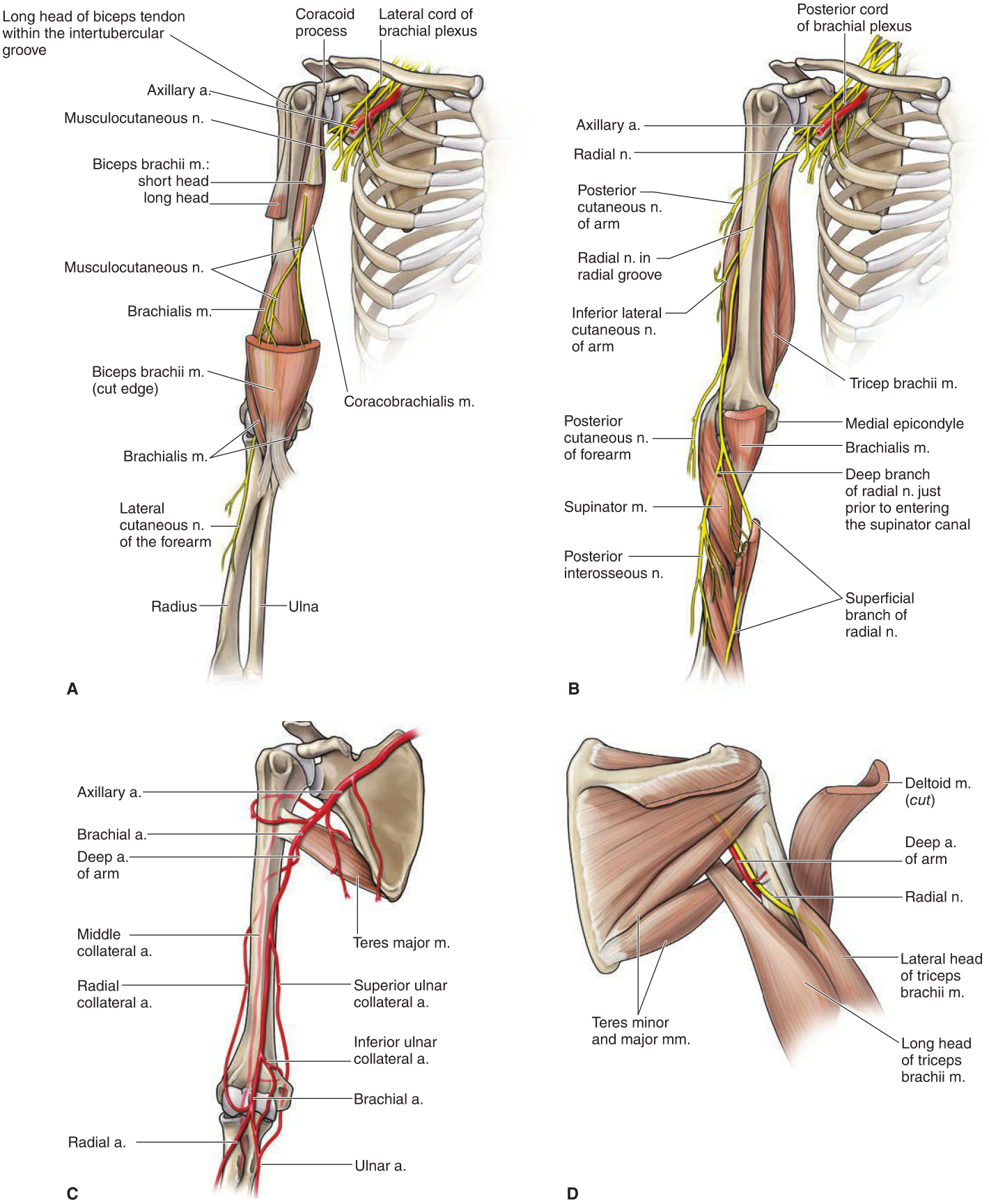

Figure 31-2: **A**. Musculocutaneous nerve innervation of muscles in the anterior compartment of the arm. **B**. Radial nerve innervation of the muscles in the posterior compartment of the arm and forearm. **C**. Arterial supply to the brachium. **D**. Triangular interval demonstrating the course of the deep artery of the arm and the radial nerve.

JOINTS CONNECTING THE ARM AND FOREARM

BIG PICTURE

The elbow consists of articulations between the humerus, radius, and ulna, and provides flexion, extension, supination, and pronation of the forearm.

ELBOW COMPLEX

The elbow is composed of the following joints (Figure 31-3A):

- **Humeroulnar joint.** Synovial hinge joint producing flexion and extension; articulations include the trochlea of the humerus and the trochlear notch of the ulna.
- **Humeroradial joint.** Synovial joint that works in conjunction with the humeroulnar joint to produce flexion and extension; articulations include the capitulum of the humerus and the head of the radius.
- **Proximal radioulnar joint.** Synovial pivot joint that is mechanically linked with the distal radioulnar joint and produces supination and pronation; articulations include the head of the radius and the radial notch of the ulna.
  - The proximal radioulnar joint is interdependent with the distal radioulnar joint and will be discussed in greater detail in Chapter 32.

LIGAMENTOUS AND CAPSULAR SUPPORT OF THE ELBOW

The following ligaments and the capsule provide support to the elbow joint (Figure 31-3B–D):

- **Capsule.** The humeroulnar, humeroradial, and proximal radioulnar joints are enclosed in a single capsule. The capsule is loose, which accommodates the high degree of motion; however, the capsule is reinforced with ligaments.
- **Ligaments.** Most hinge joints in the body, including the humeroulnar joint, contain medial and lateral collateral ligaments to enhance medial and lateral stability.
  - **Ulnar collateral (medial collateral).** Fibers run from the medial epicondyle of the humerus to the proximal ulna.
    - Provides medial stability of the elbow complex; resists valgus forces; prevents gapping of the joint medially.
  - **Radial collateral (lateral collateral).** Fibers run from the lateral epicondyle to the annular ligament and the olecranon process of the ulna.
    - Provides lateral stability of the elbow complex; resists varus forces; prevents gapping of the joint laterally.
  - **Annular ligament.** A circular ligament attached to the anterior and posterior surfaces of the radial notch of the ulna and forms a ring that encompasses the radial head.
    - The inner surface of the ligament is covered with cartilage and provides stability for the humeroulnar joint while allowing supination and pronation.

Nursemaid's elbow. Ligaments and muscles support the elbow complex. However, a sufficient longitudinal force on the radius may result in the head of the radius being pulled through the annular ligament resulting in a distraction injury (or more commonly as "nursemaid's elbow"). This injury occurs most frequently in small children and usually when a parent unexpectedly lifts a child by the arm.

OLECRANON BURSA

The most important bursa associated with the elbow complex is the olecranon bursa, which is located between the capsule of the elbow complex and the triceps tendon. The olecranon bursa diminishes friction between the two surfaces as they cross over each other.

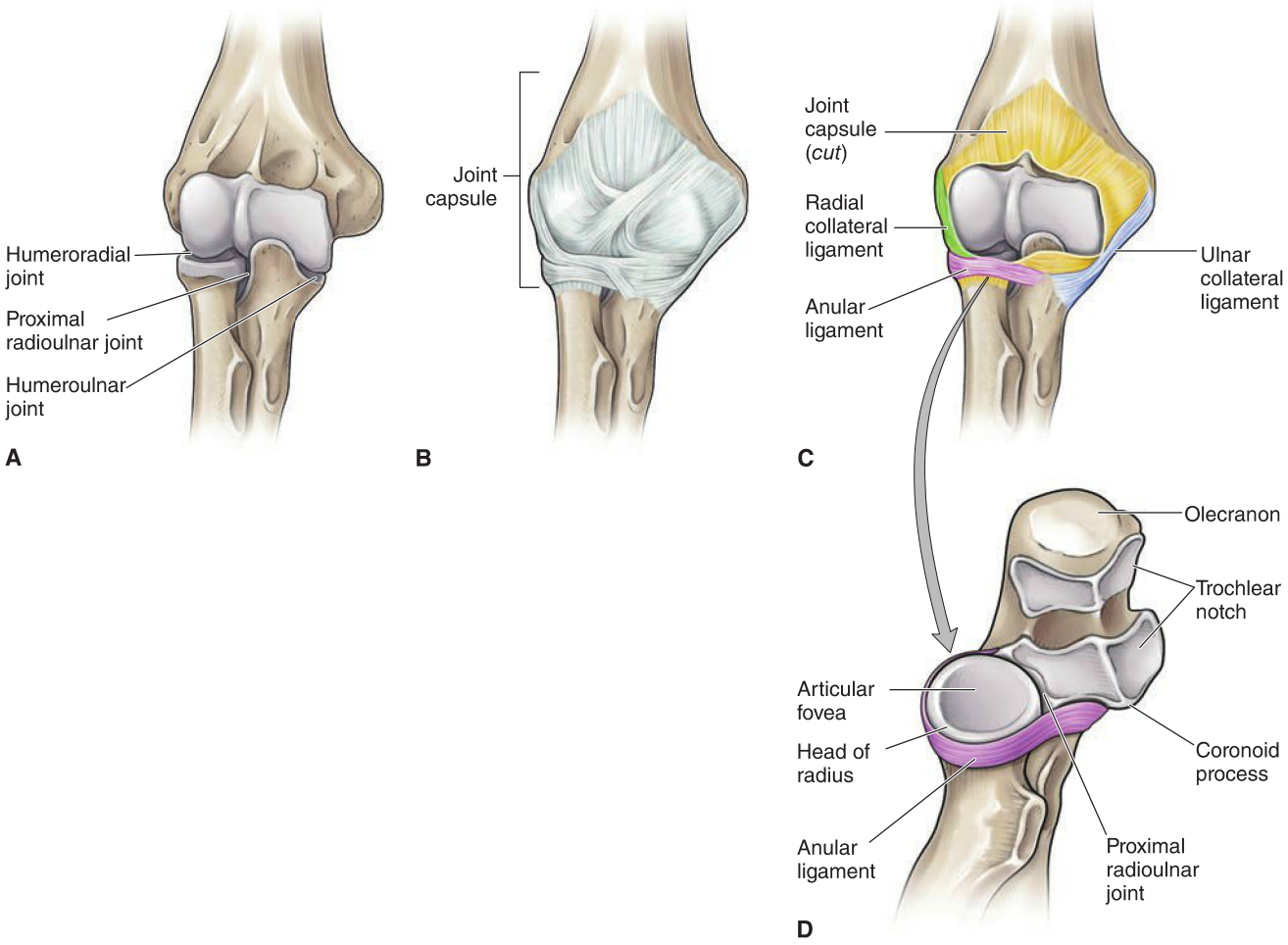

Figure 31-3: **A**. Joints of the elbow. **B**. Joint capsule of the elbow. **C**. Joint capsule cut and open revealing the articulations. **D**. Superior view of the proximal radioulnar joint demonstrating the annular ligament.

TABLE 31-1. Muscles of the Arm

Muscle	Proximal Attachment	Distal Attachment	Action	Innervation
Anterior compartment of the arm				
Biceps brachii	Long head: supraglenoid tubercle Short head: coracoid process	Radial tuberosity	Flexion of shoulder; flexion and supination of elbow	Musculocutaneous n. (C5–C6)
Brachialis	Distal anterior surface of humerus	Coronoid process and tuberosity of ulna	Flexion of the elbow	Musculocutaneous n. (C5–C6)
Coracobrachialis	Coracoid process of scapula	Medial, midshaft surface of humerus	Flexion of shoulder	Musculocutaneous n. (C5–C7)
Posterior compartment of the arm				
Triceps brachii	Long head: infraglenoid tubercle Lateral head: posterior humerus Medial head: posterior humerus	Olecranon process of ulna	Extension of shoulder and elbow	Radial n. (C6–C8)

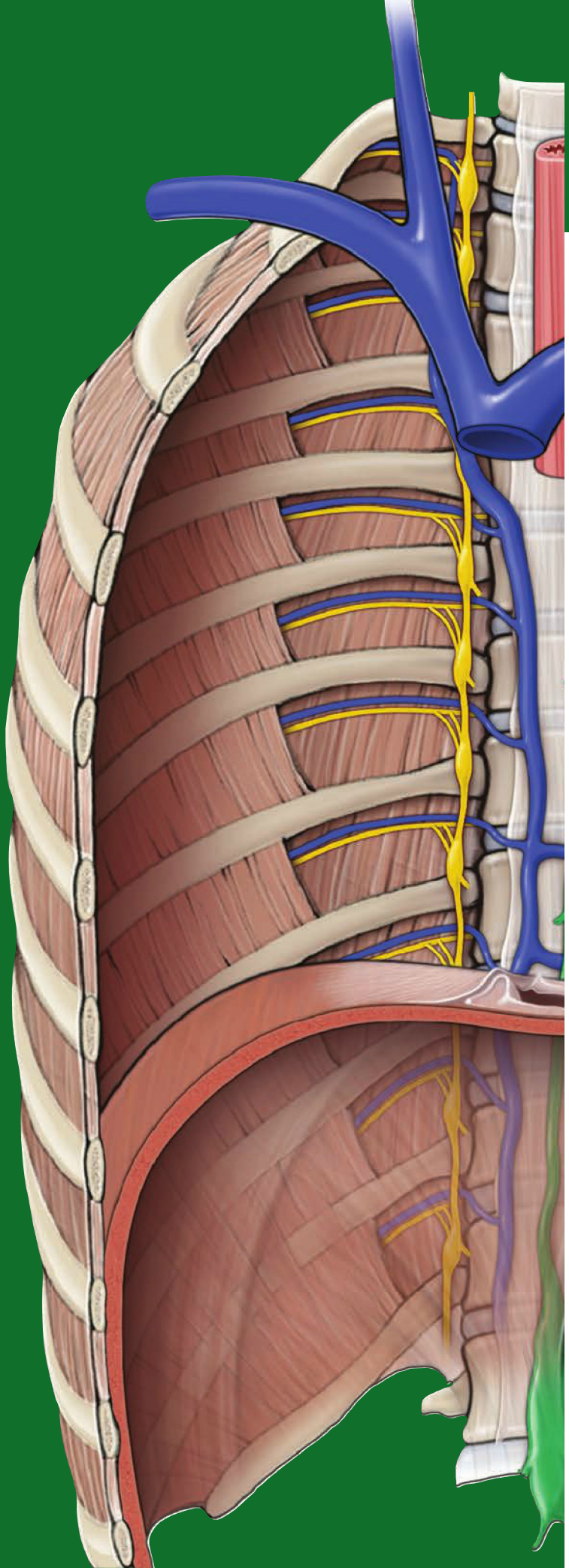

CHAPTER 32

FOREARM

Muscles of the Forearm 340

Terminal Branches of the Brachial Plexus in the Forearm 344

Vascularization of the Forearm 346

Joints Connecting the Forearm and Hand 348

MUSCLES OF THE FOREARM

BIG PICTURE

The forearm (antebrachium) consists of the radius and ulna. Proximally, the forearm articulates with the humerus through the elbow complex (humeroulnar and humeroradial joints). Distally, the forearm articulates with the carpal bones through the wrist complex, enabling a wide array of actions. Forearm muscles are organized into two fascial compartments, similar to those of the arm muscles. The anterior compartment contains flexor muscles (innervated by the median and ulnar nerves). The posterior compartment contains extensor muscles (innervated by the radial nerve).

ACTIONS OF THE WRIST

The wrist complex allows for motion in two planes (Figure 32-1A):

- **Flexion.** Wrist bends anteriorly.
- **Extension.** Wrist bends posteriorly.
- **Radial deviation (abduction).** Wrist abducts toward the radius.
- **Ulnar deviation (adduction).** Wrist adducts toward the ulna.

FOREARM MUSCLES OF THE ANTERIOR COMPARTMENT

The muscles in the anterior compartment of the forearm have the following in common:

- **Common attachment.** Medial epicondyle of the humerus.
- **Common innervation.** Median nerve with some contribution from the ulnar nerve.
- **Common action.** Flexion.

The **muscles in the anterior compartment** of the forearm are divided into three groups: superficial, intermediate, and deep.

- **Superficial group** (Figure 32-1B).
  - **Pronator teres muscle (PT).** Possesses two heads and crosses anteriorly to the elbow complex.
    - **Attachments.** Two heads (medial epicondyle and medial supracondylar ridge of the humerus as well as the coronoid process of the ulna); inserts laterally on the midshaft of the radius.
    - **Actions.** Pronates forearm.
    - **Innervation.** Median nerve (C6–C7); the median nerve enters the forearm by coursing between the two heads.
  - **Flexor carpi radialis muscle (FCR).**
    - **Attachments.** Medial epicondyle (humerus); base of second and third metacarpals.
    - **Actions.** Wrist flexion and radial deviation.
    - **Innervation.** Median nerve (C6–C7).
  - **Palmaris longus muscle (PL).** This muscle may be absent on one or both sides in some individuals.
    - **Attachments.** Medial epicondyle (humerus); palmar aponeurosis.
    - **Actions.** Weak wrist flexion; resists shearing forces of the palmar aponeurosis.
    - **Innervation.** Median nerve (C7–C8).
  - **Flexor carpi ulnaris muscle (FCU).** Possesses two heads.
    - **Attachments.** Two heads (medial epicondyle and olecranon process); pisiform bone and base of the fifth metacarpal.
    - **Actions.** Wrist flexion and ulnar deviation.
    - **Innervation.** Ulnar nerve (C7–T1); the ulnar nerve enters the forearm by coursing deep to the medial epicondyle and traverses the two heads of the flexor carpi ulnaris muscle.
- **Intermediate group** (Figure 32-1C).
  - **Flexor digitorum superficialis muscle (FDS).** Arises from two heads and gives rise to four tendons, which traverse the carpal tunnel to insert on digits 2 to 5.
    - **Attachments.** Two heads (medial epicondyle and radius); gives rise to four tendons, which traverse the carpal tunnel and insert onto the middle phalanges of digits 2 to 5.
    - **Actions.** Wrist, metacarpophalangeal (MCP) joints, and proximal interphalangeal (PIP) joint flexion.
    - **Innervation.** Median nerve (C8–T1); the median nerve enters the forearm by coursing between the two heads.
- **Deep group** (Figure 32-1D).
  - **Flexor pollicis longus muscle (FPL).** Located deep to the FDS.
    - **Attachments.** Radius and interosseous membrane; tendon traverses the carpal tunnel to insert on the distal phalanx of digit 1 (thumb).
    - **Actions.** Thumb flexion (flexion of MCP and IP joints of digit 1).
    - **Innervation.** Anterior interosseous nerve branch from median nerve (C7–C8).
  - **Flexor digitorum profundus muscle (FDP).** Positioned deep to the FDS.
    - **Attachments.** Medial surface of ulna and interosseous membrane; gives rise to four tendons, which traverse the carpal tunnel and insert anteriorly onto the distal phalanges of digits 2 to 5.
    - **Actions.** Wrist, MCP, PIP, and distal interphalangeal (DIP) joint flexion.
    - **Innervation.** The FDP is a unique muscle in that it is dually innervated:
      - **Radial belly** (acts on digits 2–3). Anterior interosseous nerve (branch from median nerve) (C8–T1).
      - **Ulnar belly** (acts on digits 4–5). Ulnar nerve (C8–T1).
  - **Pronator quadratus muscle (PQ).** Positioned deep in the anterior region of the wrist.
    - **Attachments.** Courses horizontally from the ulna to the radius (distal anterior surfaces).
    - **Actions.** Pronates forearm.
    - **Innervation.** Anterior interosseous nerve (branch from median nerve) (C7–C8).

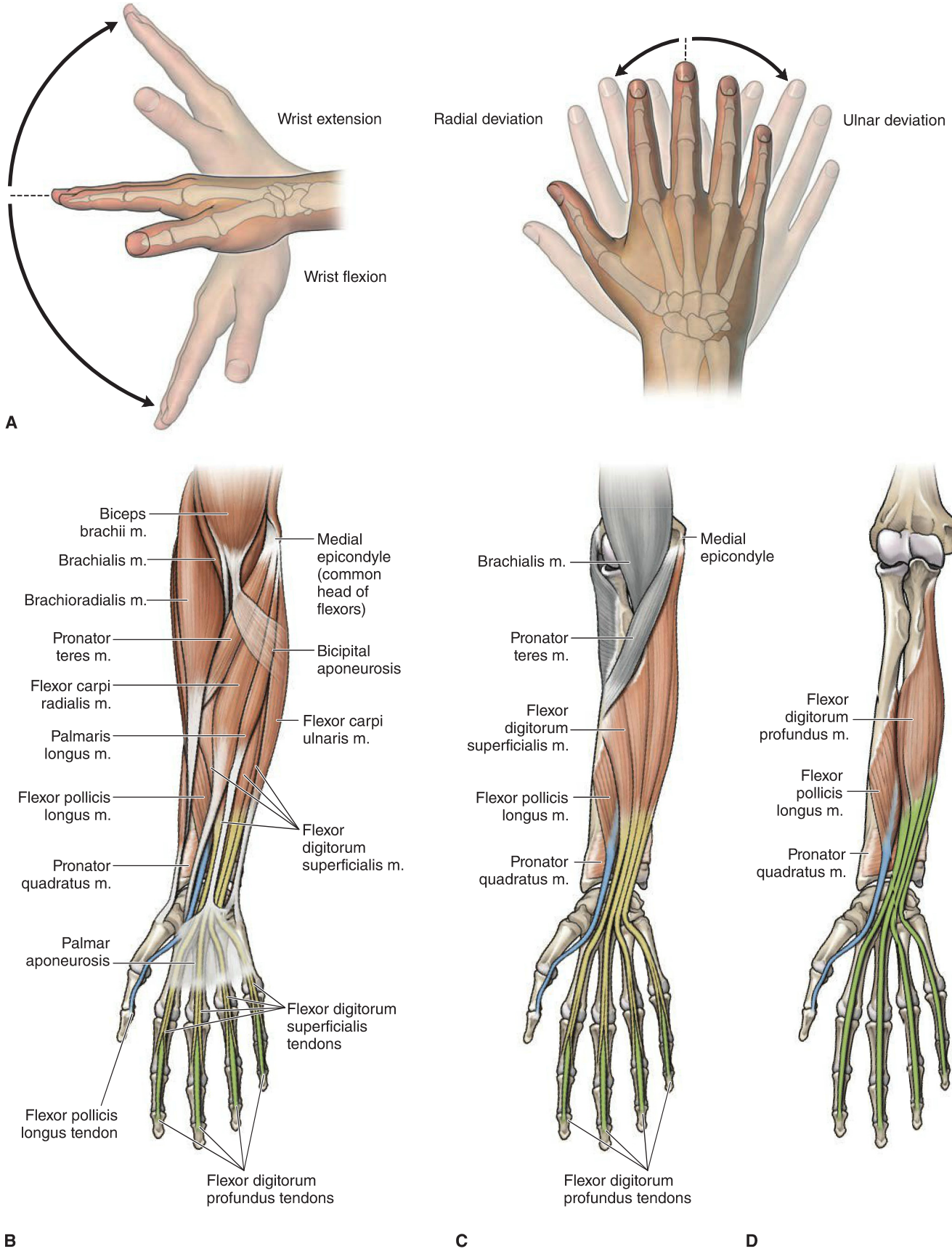

Figure 32-1: A. Actions of the wrist joint. Superficial (**B**), intermediate (**C**), and deep (**D**) muscles of the anterior forearm.

FOREARM MUSCLES OF THE POSTERIOR COMPARTMENT

The muscles in the posterior compartment of the forearm have the following in common (Table 32-1):

- **Common attachment.** Lateral epicondyle of the humerus.
- **Common innervation.** Radial nerve.
- **Common action.** Extension.

The **muscles in the posterior compartment** are divided into superficial and deep groups.

- **Superficial group** (Figure 32-2A and B).
  - **Brachioradialis muscle.**
    - **Attachments.** Lateral supracondylar ridge and styloid process of the radius.
    - **Actions.** Assists in elbow flexion (primarily in mid-pronated position).
    - **Innervation.** Radial nerve before divisions into superficial and deep branches (C5–C6).
  - **Extensor carpi radialis longus muscle (ECRL).**
    - **Attachments.** Lateral supracondylar ridge and base of metacarpal 2 (dorsal surface).
    - **Actions.** Wrist extension and radial deviation.
    - **Innervation.** Radial nerve before divisions into superficial and deep branches (C6–C7).
  - **Extensor carpi radialis brevis muscle (ECRB).**
    - **Attachments.** Lateral epicondyle and dorsal surface of the base of metacarpal 3.
    - **Actions.** Wrist extension and radial deviation.
    - **Innervation.** Deep branch of the radial nerve prior to traveling to the supinator muscle (C7–C8).
  - **Extensor digitorum communis muscle (EDC).**
    - **Attachments.** Lateral epicondyle and dorsal digital expansions of digits 2 to 5. Intertendinous connecting the tendons may be present on the dorsum of the hand (location and number of connections may be variable). Lumbricals, dorsal interossei, and palmar interossei muscles share a common attachment to the dorsal digital expansion.
    - **Actions.** Prime actions are wrist and MCP extension (ironically the EDC produces weak IP extension).
    - **Innervation.** Posterior interosseous nerve branch (radial nerve) (C7–C8).
  - **Extensor digiti minimi muscle (EDM).**
    - **Attachments.** Lateral epicondyle and dorsal digital expansion of digit 5.
    - **Actions.** Extension of digit 5.
    - **Innervation.** Posterior interosseous nerve branch (radial nerve) (C7–C8).
  - **Extensor carpi ulnaris muscle (ECU).**
    - **Attachments.** Lateral epicondyle and base of metacarpal 5.
    - **Actions.** Wrist extension and ulnar deviation.
    - **Innervation.** Posterior interosseous nerve branch (radial nerve) (C7–C8).
  - **Anconeus muscle.**
    - **Attachments.** Lateral epicondyle and olecranon process (ulna).
    - **Actions.** Contributes to elbow extension.
    - **Innervation.** Radial nerve (C6–C8).
- **Deep group** (Figure 32-2C).
  - **Supinator muscle**. Has two heads.
    - **Attachments.** Two heads (lateral epicondyle and supinator crest of ulna); inserts on lateral radius.
    - **Actions.** Supination of forearm.
    - **Innervation.** Posterior interosseous nerve (radial nerve) (C6–C7); radial nerve courses between the two heads of the supinator to enter the posterior compartment of the forearm.
  - **Abductor pollicis longus muscle (APL).**
    - **Attachments.** Ulna, radius, and interosseous membrane; base of metacarpal 1.
    - **Actions.** Abducts the carpometacarpal joint of digit 1.
    - **Innervation.** Posterior interosseous nerve (radial n.) (C7–C8).
  - **Extensor pollicis longus muscle (EPL).**
    - **Attachments.** Ulna and interosseous membrane; distal phalanx of 1 (thumb).
    - **Actions.** Extends all joints associated with digit 1.
    - **Innervation.** Posterior interosseous nerve (radial n.) (C7–C8).
  - **Extensor pollicis brevis muscle (EPB).**
    - **Attachments.** Radius and interosseous membrane; proximal phalanx of digit 1.
    - **Actions.** Extends carpometacarpal and MCP joints digit 1.
    - **Innervation.** Posterior interosseous nerve (radial n.) (C7–C8).
  - **Extensor indicis muscle (EI).**
    - **Attachments.** Ulna and interosseous membrane; dorsal digital expansion digit 2.
    - **Actions.** Assists in extending digit 2 independent of the other digits.
    - **Innervation.** Posterior interosseous nerve (radial n.) (C7–C8).

Lateral epicondylitis ("tennis elbow"). A condition caused by the overuse of muscles that attach to the lateral epicondyle. This injury is seen in almost 50% of tennis players (hence, the name "tennis elbow"); however, it can affect anyone who participates in repetitive activity. A person with lateral epicondylitis will typically experience pain over the lateral epicondyle. The etiology of the pain is microtears of the proximal attachment of the extensor muscles. A similar-condition medial epicondylitis ("golfer's elbow") occurs at the medial epicondyle.

Anatomical snuffbox. A triangular depression on the posterolateral wrist formed by the abductor pollicis longus, extensor pollicis brevis, and extensor pollicis longus tendons. The scaphoid bone forms the floor of the snuffbox, the radial artery courses across the scaphoid bone, and the superficial radial nerve and cephalic vein course over the roof within the hypodermis.

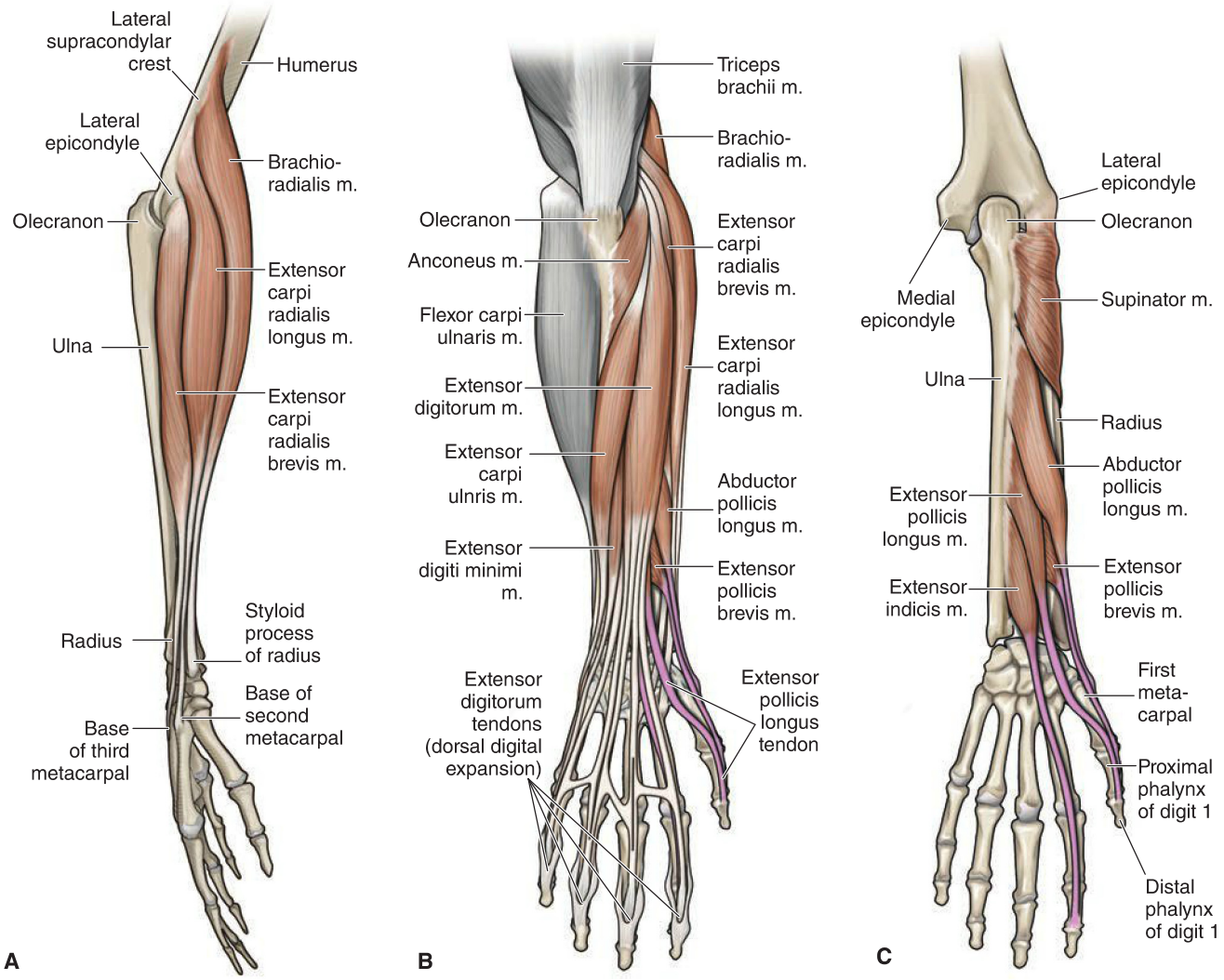

Figure 32-2: A. Lateral view of the forearm. Superficial (**B**) and deep (**C**) muscles of the posterior forearm.

TERMINAL BRANCHES OF THE BRACHIAL PLEXUS IN THE FOREARM

BIG PICTURE

The median, ulnar, and radial nerves innervate the anterior and posterior compartments of the forearm. The median nerve innervates all muscles in the anterior compartment of the forearm except one and a half muscles (FCU and half of the FDP are innervated by the ulnar nerve). The posterior compartment of the forearm is innervated entirely by the radial nerve.

MEDIAN NERVE

The median nerve arises from the medial and lateral cords of the brachial plexus and travels with the brachial artery along the medial side of the arm (Figure 32-3A). In the elbow, the median nerve courses through the cubital fossa, deep to the bicipital aponeurosis and between the two heads of the pronator teres, to enter the anterior compartment of the forearm.

- **Main branch of median nerve.** Courses between the flexor digitorum superficialis and the profundus muscles; traverses the **carpal tunnel** to enter the hand.
  - Innervates the superficial and intermediate muscles of the anterior forearm (except the ulnar half of the flexor digitorum profundus and flexor carpi ulnaris).
- **Anterior interosseous nerve.** Arises from the median nerve upon exiting the pronator teres muscle.
  - Innervates the flexor pollicis longus, pronator quadratus, and radial half of the flexor digitorum profundus muscles.
- **Palmar branch.** Prior to traversing the carpal tunnel the median nerve gives rise to a palmar branch.
  - Provides cutaneous innervation to the lateral side of the palm (not digits).

Pronator syndrome. A syndrome caused by the entrapment of the median nerve between the two heads of the pronator teres muscle. Depending on the severity of the injury, sensory changes in the distribution of the median nerve are more commonly experienced. In rare circumstances motor deficits in the distribution of the median nerve are experienced.

Anterior interosseous syndrome. Injury of the anterior interosseous nerve, due to tendinous bands, fractures, or compression, result in weakness of associated muscles (Figure 32-3B). In other words, the flexor pollicis longus muscle (flexes the thumb) and radial belly of the flexor digitorum profundus (flexes digit 1 and 2) are affected. To test this injury the patient is instructed to make the "ok" sign. If the FPL and FDP are unable to function, the patient would be unable to make a circle with their thumb and index finger and would instead make a triangle. There is no sensory loss involved with this syndrome.

ULNAR NERVE

The ulnar nerve courses posteriorly to the medial epicondyle of the humerus in the osseous groove, into the anterior compartment of the forearm between the two heads of the flexor carpi ulnaris muscle (Figure 32-3B).

- **Main branch of the ulnar nerve.** Innervates the flexor carpi ulnaris and the ulnar half of the flexor digitorum profundus. The ulnar nerve continues into the hand superficial to the carpal tunnel and courses through **Guyon's canal** by the pisiform bone to enter the hand.
- **Cutaneous branches.** Proximal to the wrist, the ulnar nerve gives rise to two cutaneous branches, a **dorsal branch and a palmar branch**, which provide cutaneous innervation to the dorsal medial side of the hand and the medial side of the palm, respectively.

Cubital tunnel syndrome. Caused by compression or injury of the ulnar nerve as it passes under the medial epicondyle. Symptoms are usually tingling and numbness in the cutaneous distribution of the ulnar nerve. In severe cases, muscle weakness may be apparent, with atrophy of the hypothenar eminence.

RADIAL NERVE

The radial nerve enters the forearm, anterior to the lateral epicondyle, and travels distally between the brachialis and the brachioradialis muscles, where it bifurcates into deep (posterior interosseous nerve) and superficial (superficial radial nerve) branches (Figure 32-3C):

- **Posterior interosseous nerve.** Enters the posterior forearm between the two heads of the supinator muscle.
  - Innervates the muscles in the posterior compartment of the forearm (except the brachioradialis and extensor carpi radialis longus, which are innervated by the radial nerve prior to its bifurcation).
- **Superficial radial nerve.** Courses along the brachioradialis muscle and then over the anatomical snuffbox.
  - Provides cutaneous innervation to the dorsum of the hand.
- **Posterior cutaneous nerve of the forearm**. Arises from the radial nerve in the arm; supplies skin in the posterior forearm.

MEDIAL CUTANEOUS NERVE OF THE FOREARM

The medial cutaneous nerve of the forearm (C8–T1) branches from the medial cord and supplies the medial skin of the forearm.

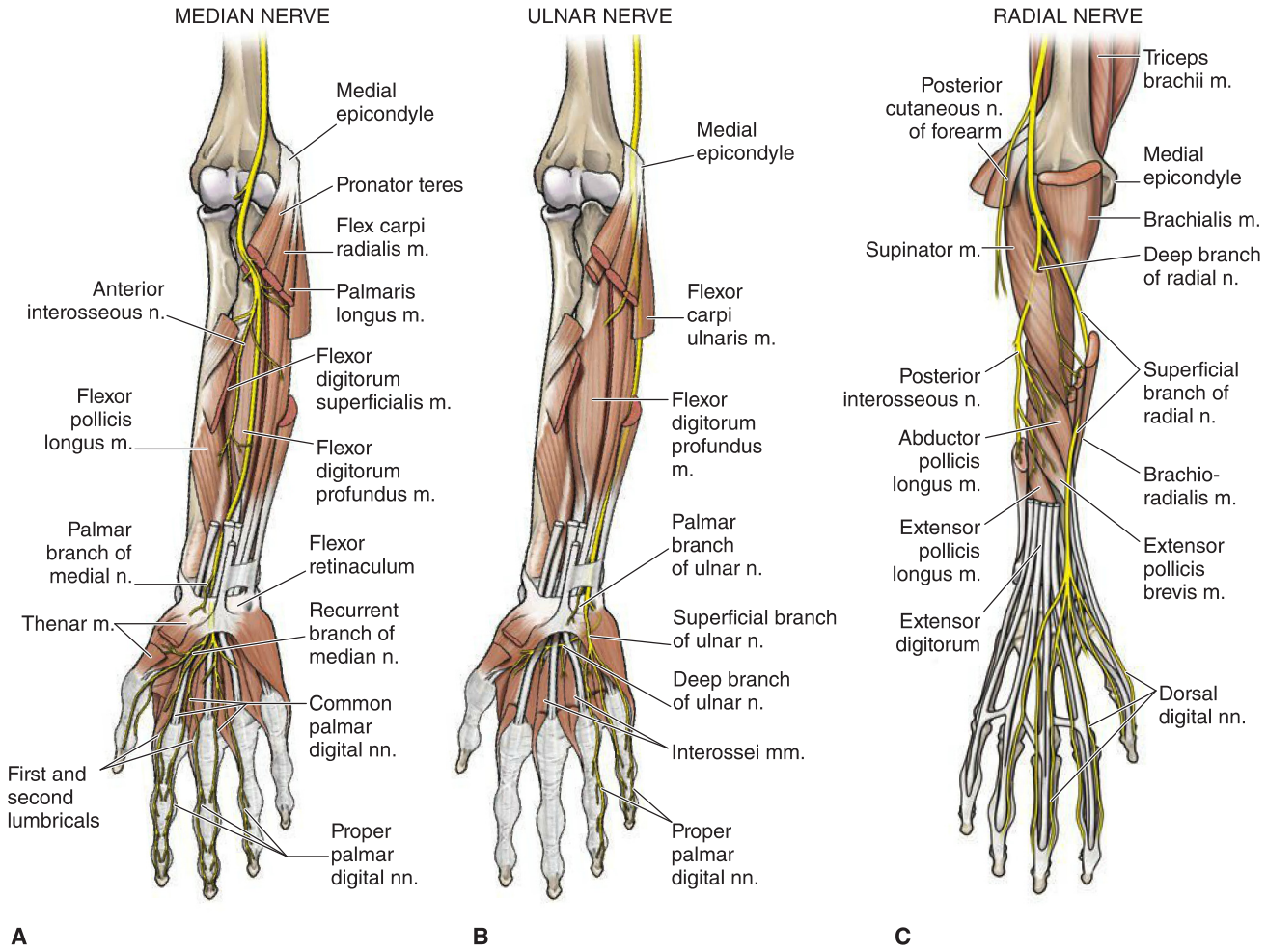

Figure 32-3: **A**. Median nerve (right forearm in supine position). **B**. Ulnar nerve (right forearm in supine position). **C**. Radial nerve (right forearm in prone position).

VASCULARIZATION OF THE FOREARM

BIG PICTURE

The brachial artery gives rise to the radial and ulnar arteries, which supply the anterior and posterior compartments of the forearm and extend distally into the hand.

ULNAR ARTERY

The ulnar artery travels through the cubital fossa, descends between the flexor carpi ulnaris and the flexor digitorum profundus muscles, and terminates in the hand as the deep and superficial ulnar palmar arches. Gives rise to the following branches (Figure 32-4A and B):

- **Superior ulnar recurrent artery.** Courses in a superior direction anterior to the medial epicondyle and forms an anastomosis with the inferior ulnar collateral artery.
- **Inferior ulnar recurrent artery.** Courses in a superior direction posterior to the medial epicondyle and forms an anastomosis with the superior ulnar collateral artery.
- **Common interosseous artery.** Courses toward the interosseous membrane and bifurcates into the anterior and posterior interosseous branches.
  - **Anterior interosseous artery.** Travels along the anterior surface of the interosseous membrane, pierces the membrane, and supplies the deep extensor muscles.
  - **Posterior interosseous artery.** Travels along the posterior surface of the interosseous membrane and supplies the superficial extensors. Forms anastomoses with the recurrent interosseous artery vascular network of the elbow.
    - **Recurrent interosseous artery.** Travels in a superior direction, posterior to the elbow complex, and forms an anastomosis with the middle collateral artery.

RADIAL ARTERY

The radial artery travels through the cubital fossa along the lateral side of the forearm, deep to the brachioradialis along the flexor pollicis longus muscle. The pulse of the radial artery is often felt on the lateral, palmar surface of the wrist. The radial artery terminates in the hand as the deep and superficial radial palmar arches. The radial artery gives rise to the radial recurrent artery (Figure 32-4A and B).

- **Radial recurrent artery.** Courses anteriorly to the lateral epicondyle of the humerus to anastomose with the radial collateral artery.

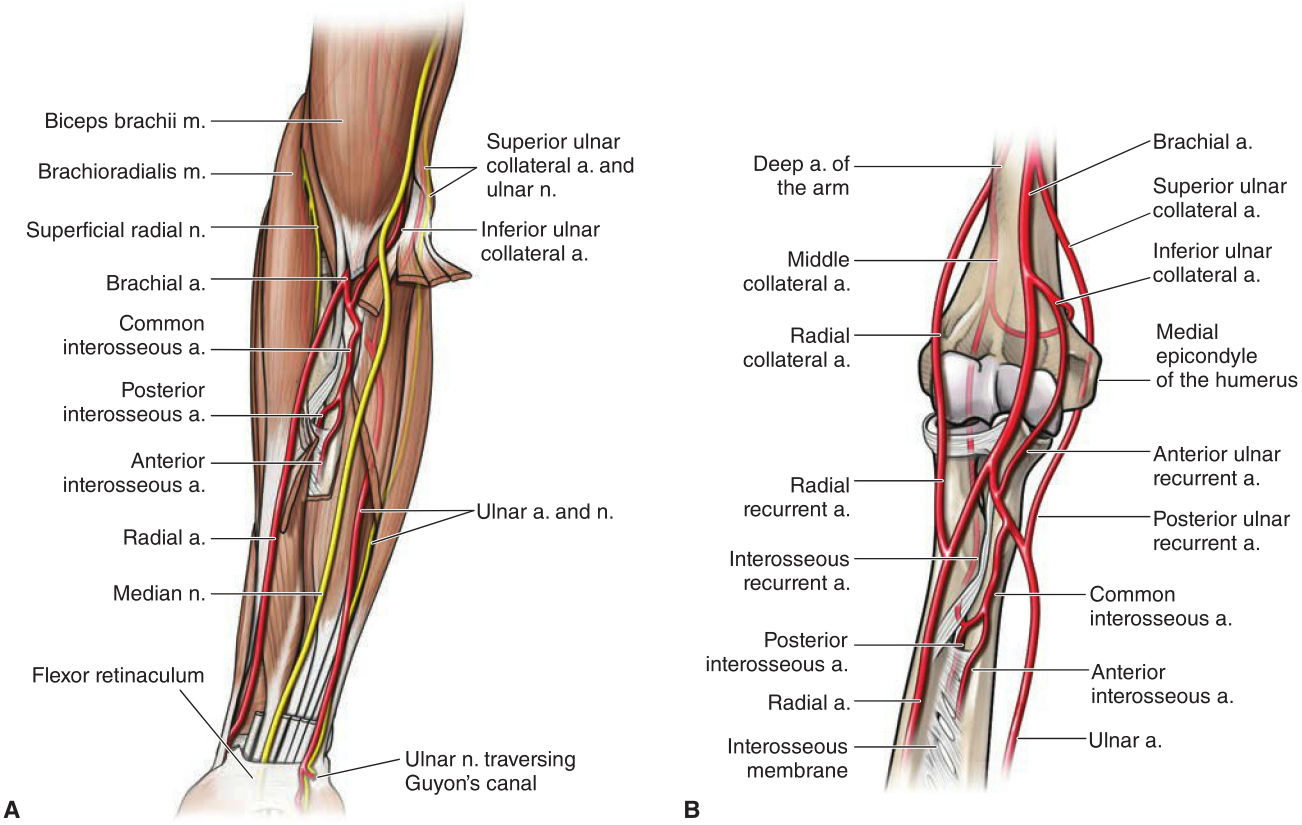

Figure 32-4: **A**. Arteries and nerves of the anterior forearm. **B**. Arteries of the elbow and forearm.

JOINTS CONNECTING THE FOREARM AND HAND

BIG PICTURE

The proximal and distal radioulnar joints form synovial pivot joints that provide pronation and supination of the forearm. The wrist complex is very flexible because of the synovial joint between the radius and the proximal row of carpal bones (radiocarpal joint) and the proximal and the distal row of carpal bones (midcarpal joint).

DISTAL RADIOULNAR JOINT

A synovial pivot joint (proximal and distal radioulnar joint) exists between the radius and ulna, which produces supination and pronation. They are mechanically linked; one joint is unable to move without the other (Figure 32-5A and B).

- **Distal radioulnar joint.** Articulation between the ulnar notch of the radius, the articular disc, and the head of the ulna.
- **Triangular fibrocartilage complex (TFCC).** A fibrocartilaginous structure located within the medial side of the wrist joint distal to the ulna; cushions and supports the carpal bones.
- **Dorsal and palmar radioulnar ligaments.** The distal radioulnar joint is supported by two ligaments that originate from the dorsal and palmar aspects of the ulnar notch of the radius and extend to the base of the styloid process of the ulna. These ligaments form the margins for the triangular fibrocartilage complex.
- **Interosseous membrane.** The interosseous membrane is a wide sheet of connective tissue that connects the radius and ulna and functions to support both the proximal and distal radioulnar joints. The arrangement of the fibers allows for the transmission of forces from the hand and radius to the ulna.

WRIST COMPLEX

The wrist complex consists of the radiocarpal and midcarpal joints that result in wrist flexion and extension and in radial and ulnar deviation (Figure 32-5A and B).

- **Radiocarpal joint.** Articulation between the radius and the radioulnar disc (triangular fibrocartilage complex) with the proximal row of carpal bones (scaphoid, lunate, and triquetrum).
- **Midcarpal joint.** Articulation between the proximal row of carpal bones (scaphoid, lunate, and triquetrum) with the distal row of carpal bones (trapezium, trapezoid, capitate, and hamate).

The radiocarpal and midcarpal joints share similar ligamentous and capsular support because most of the structures that support the radiocarpal joint also cross the midcarpal joint. These joints consist of a fairly loose, but strong capsule reinforced with the following ligaments:

- **Palmar radiocarpal ligament.** Reinforces the anterior capsule and attaches proximally to the distal radius and distally to the scaphoid, lunate, triquetrum, and capitate.
- **Palmar ulnocarpal ligament.** Attaches proximally to the ulnar styloid process and the triangular fibrocartilage complex and distally to the lunate and triquetrum.
- **Dorsal radiocarpal ligament.** Reinforces the posterior capsule and attaches proximally to the distal radius and distally to the scaphoid, lunate, and triquetrum.
- **Ulnar collateral ligament.** Attaches from the ulnar styloid process to the triquetrum and pisiform.
- **Radial collateral ligament.** Attaches from the radial styloid process to the scaphoid and trapezium.
- **Intercarpal ligaments.** Interconnect carpal bones within and between rows.

▼ **Colles' fracture.** A Colles' fracture is a distal radial fracture that is usually caused by FOOSH injury (Falling On an Out-Stretched Hand). This fracture may result in a visual deformity proximal to the wrist complex. The fracture most often occurs about 1 to 2 inches proximal to the radiocarpal joint. ▼

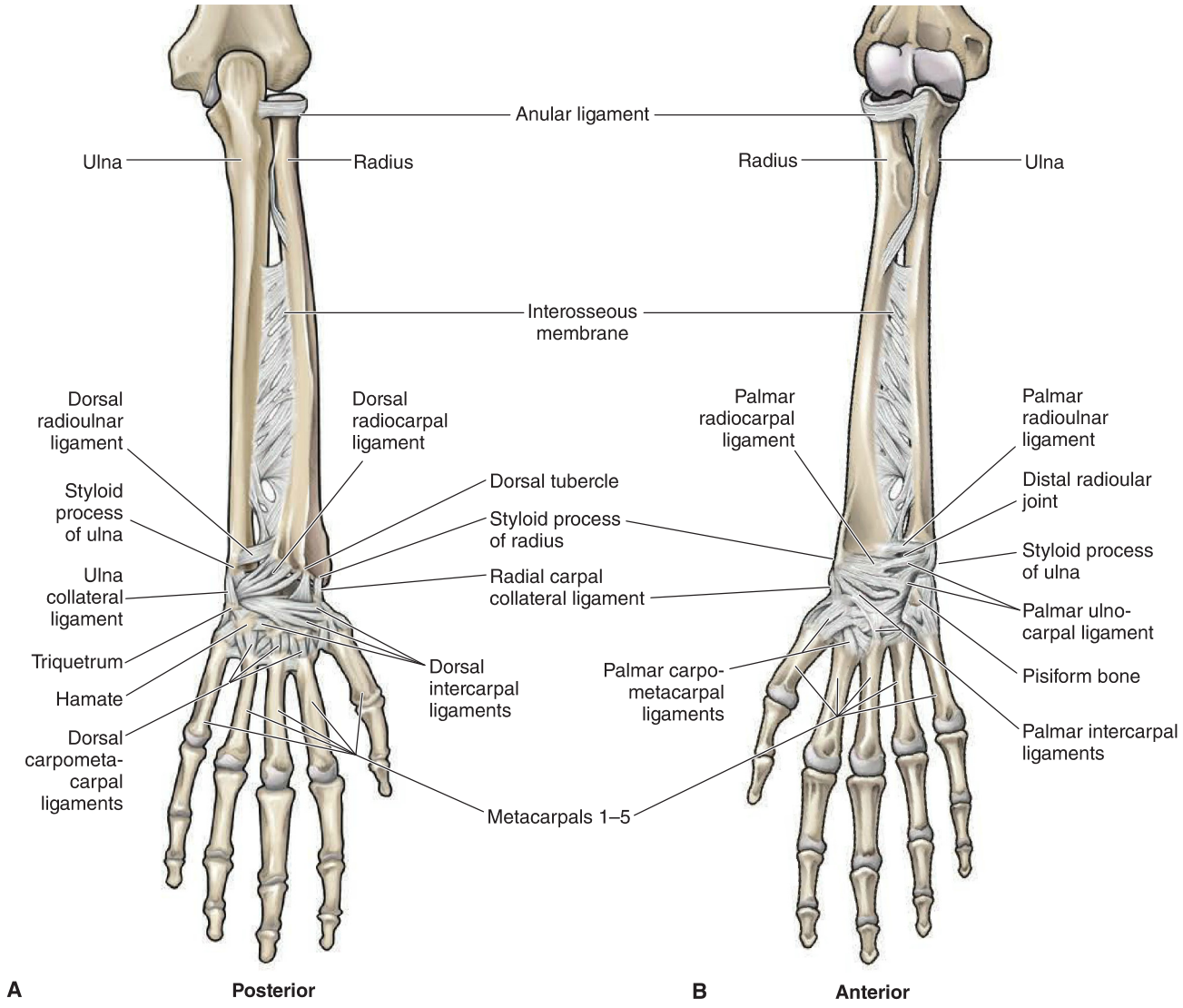

Figure 32-5: Posterior (**A**) and anterior (**B**) views of the wrist joint.

TABLE 32-1. Muscles of the Forearm

Muscle	Proximal Attachment	Distal Attachment	Action	Innervation
Anterior forearm				
Pronator teres	Humeral head: medial epicondyle and supracondylar ridge of humerus Ulnar head: coronoid process of ulna	Midshaft of radius	Pronation and flexion of elbow	Median n. (C6–C7)
Flexor carpi radialis	Medial epicondyle of humerus	Metacarpals 2 and 3	Flexion and radial deviation of wrist; weak elbow flexion	
Palmaris longus		Palmar aponeurosis	Flexion of wrist, weak elbow flexion, and tightened palmar aponeurosis	Median n. (C7–C8)
Flexor carpi ulnaris	Humeral head: medial epicondyle Ulnar head: olecranon and posterior border of ulna	Pisiform, hamate, and metacarpal 5	Weak elbow flexion, wrist flexion, ulnar deviation	Ulnar n. (C7–T1)
Flexor digitorum superficialis	Medial epicondyle, coronoid process of the ulna, and anterior border of the radius	Lateral surfaces of the middle phalanx of digits 2–5	Flexion of wrist, and the metacarpophalangeal and proximal interphalangeal joints	Median n. (C8–T1)
Flexor digitorum profundus	Medial surfaces of proximal ulna and interosseous membrane	Distal phalanges of digits 2–5	Flexion of joints from wrist to distal interphalangeal joints	Medial part: ulnar n. (C8–T1) Lateral part: anterior interosseous n. from median n. (C8–T1)
Flexor pollicis longus	Radius and interosseous membrane	Distal phalanx of digit 1	Flexion of the thumb	Anterior interosseous n. from median n. (C7–C8)
Pronator quadrates	Distal anterior ulna	Distal anterior radius	Pronation of elbow	

TABLE 32-1. Muscles of the Forearm (*continued*)

Muscle	Proximal Attachment	Distal Attachment	Action	Innervation
Posterior forearm				
Anconeus	Lateral epicondyle of humerus	Olecranon process of the ulna	Extension of elbow	Radial n. (C6–C8)
Brachioradialis	Lateral supracondylar ridge of humerus	Styloid process of the radius	Flexion of elbow	Radial n. (C5–C6)
Extensor carpi radialis longus		Metacarpal 2	Extension and radial deviation of wrist	Radial n. (C6–C7)
Extensor carpi radialis brevis	Lateral epicondyle of humerus	Metacarpals 2 and 3		Posterior interosseous n. (C7–C8), the continuation of deep branch of radial n.
Extensor digitorum		Dorsal digital expansion of digits 2–5	Extension of wrist and digits	
Extensor digiti minimi		Dorsal digital expansion of digit 5	Extension of digit 5	
Extensor carpi ulnaris	Lateral epicondyle of humerus and posterior ulna	Metacarpal 5	Extension and ulnar deviation of wrist	
Supinator	Lateral epicondyle and supinator crest of ulna	Lateral surface of radius	Supination of forearm	Posterior interosseous n. (C6–C7)
Abductor pollicis longus	Ulna, radius, and interosseous membrane	Metacarpal 1	Abduction of thumb	Posterior interosseous n. (C7–C8)
Brevis	Radius and interosseous membrane	Proximal phalanx of digit 1	Extension of thumb at metacarpophalangeal and carpometacarpal joints	
Extensor pollicis longus	Ulna and interosseous membrane	Distal phalanx of digit 1	Extension of thumb	
Extensor indicis		Dorsal digital expansion of digit 2	Extension of digit 2	

This page intentionally left blank

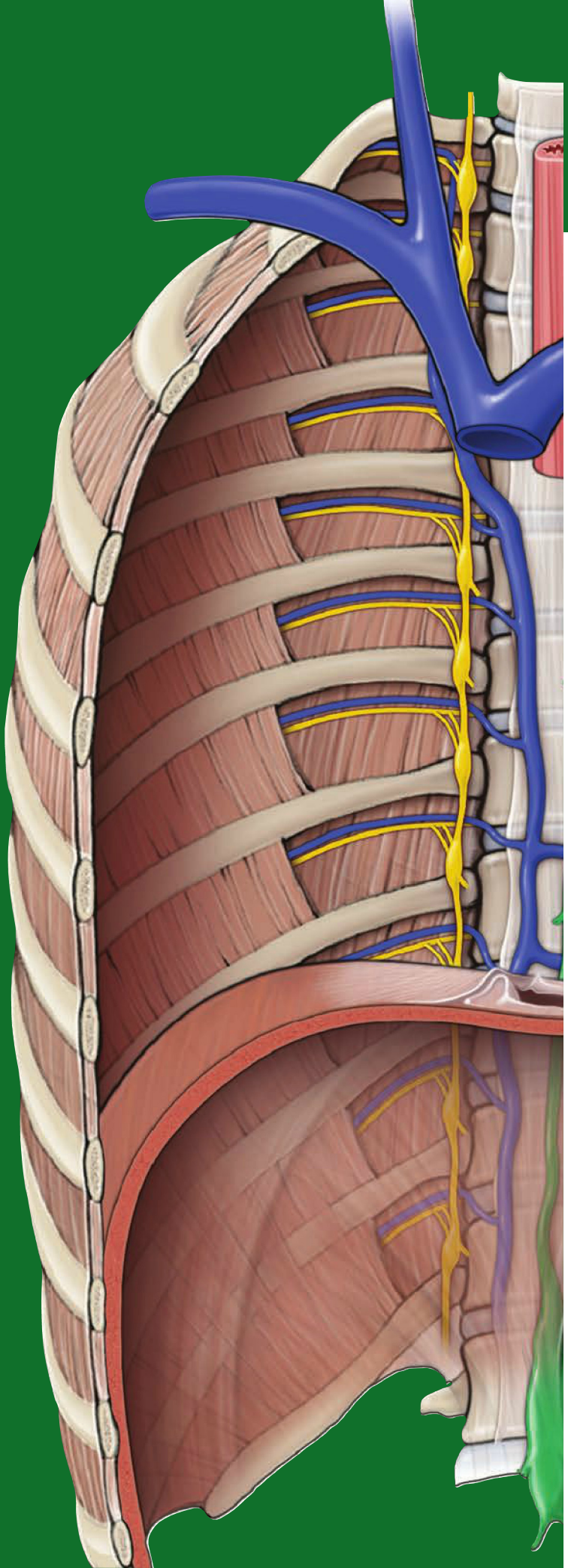

CHAPTER 33

HAND

Organization of the Fascia of the Hand 354
Actions of the Fingers and Thumb 356
Muscles of the Hand 358
Terminal Branches of the Brachial Plexus in the Hand 360
Vascularization of the Hand 362
Joints of the Hand 364
Study Questions 367
Answers 370

ORGANIZATION OF THE FASCIA OF THE HAND

BIG PICTURE

The fascia of the hand is continuous with the fascia of the forearm (antebrachium). In the hand, the fascia varies in thickness and divides the hand into five separate compartments that correspond with the five digits and have similar blood supply, innervation, and actions.

FASCIAL LAYERS OF THE PALMAR SIDE OF THE HAND (FIGURE 33-1A)

- **Palmar aponeurosis.** A triangular shaped portion of the deep fascia (located over the palm of the hand) that is continuous with the palmaris longus tendon.
  - Forms four longitudinal digital bands that radiate distally and become continuous with the fibrous digital sheaths.
- **Fibrous digital sheaths.** Tunnels composed of dense collagenous connective tissue that encloses the flexor tendons of digits 2 to 5 and the tendon of the flexor pollicis longus muscle (digit 1) and their associated synovial sheaths.
- **Flexor retinaculum (transverse carpal ligament).** A band of dense collagenous connective tissue that forms a roof over the concavity of the carpal bones thus forming the **carpal tunnel**; anchors to the pisiform and the hook of the hamate (medially) and the scaphoid and trapezium (laterally). The carpal tunnel has the following contents:
  - Four flexor digitorum superficialis tendons (and associated synovial sheaths).
  - Four flexor digitorum profundus tendons (and associated synovial sheaths).
  - One flexor pollicis longus tendon (and associated synovial sheath).
  - One median nerve.

FASCIAL COMPARTMENTS OF THE PALMAR SIDE OF THE HAND

The fascial layers divide the palmar side of the hand into the following compartments (Figure 33-1A):

- **Thenar compartment.** Contains three muscles that act on digit 1 (thumb).
- **Hypothenar compartment.** Contains three muscles that act on digit 5.
- **Central compartment.** Located between the thenar and hypothenar compartments and contains the flexor tendons and the lumbrical muscles.
- **Adductor compartment.** Contains the adductor pollicis muscle.
- **Interosseous compartment.** Located between the metacarpals and contains the dorsal and palmar interossei muscles.

FASCIAL LAYERS OF THE DORSAL SIDE OF THE HAND

- **Extensor retinaculum.** Continuous with the fascia of the forearm; retains the tendons that are near the bone while allowing proximal and distal gliding of the tendons (Figure 33-1B).
- **Dorsal digital expansions.** An aponeurosis covering the dorsum of the digits and attaches distal to the distal phalanx.
  - Proximally and centrally, the extensor digitorum, extensor digiti minimi, extensor indicis, and extensor pollicis brevis muscles attach to the dorsal digital expansion.
  - The small intrinsic muscles that attach laterally (lumbricals and interossei) are responsible for delicate finger movements that would not be possible with the forearm muscles alone.

FASCIAL COMPARTMENTS OF THE DORSAL SIDE OF THE WRIST

The extensor retinaculum of the hand divides the dorsum of the wrist into the following six compartments:

- **Compartment 1.** Contains the abductor pollicis longus and extensor pollicis brevis muscles.
- **Compartment 2.** Contains the extensor carpi radialis longus and brevis muscles.
- **Compartment 3.** Contains the extensor pollicis longus muscles.
- **Compartment 4.** Contains the extensor digitorum and extensor indicis muscles.
- **Compartment 5.** Contains the extensor digiti minimi muscles.
- **Compartment 6.** Contains the extensor carpi ulnaris muscles.

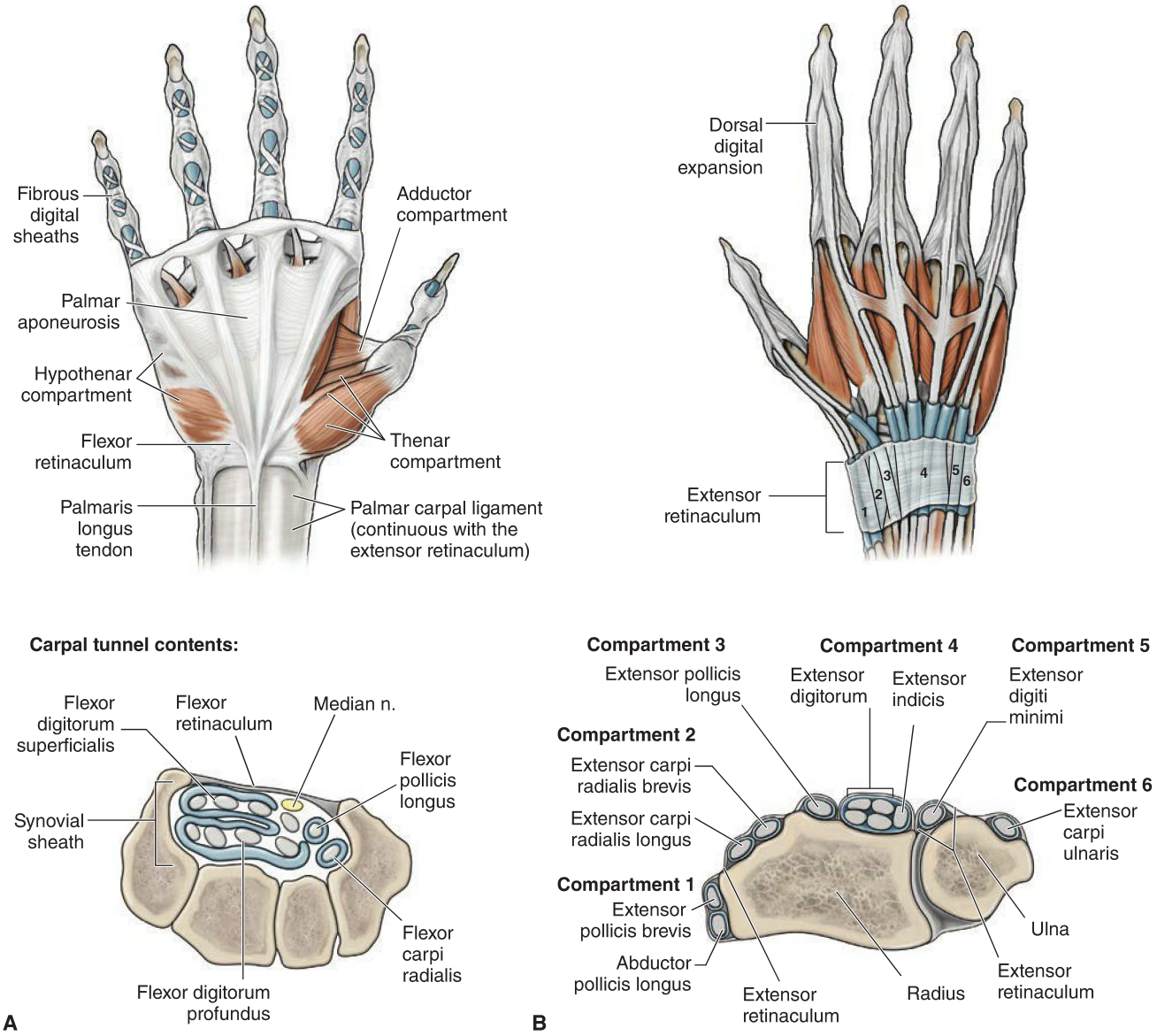

Figure 33-1: **A**. Fascia of the palm of the hand and carpal tunnel. **B**. Fascia of the posterior hand and extensor compartments.

ACTIONS OF THE FINGERS AND THUMB

BIG PICTURE

The hand consists of carpal, metacarpal, and phalangeal bones and carpometacarpal, metacarpophalangeal, and interphalangeal joints.

BONES OF THE HAND

The bones of the hand are as follows (Figure 33-1E):

- **Eight carpal bones.** Form the bones of the wrist arranged in the following manner:
  - **Proximal row of bones.** From lateral to medial.
    - **Scaphoid.** Boat-shaped bone that articulates with the radius; forms the floor of the anatomical snuffbox.
    - **Lunate.** Crescent-shaped bone that articulates with the radius.
    - **Triquetrum.** Three-sided bone.
    - **Pisiform.** Pea-shaped; formed in the tendon of the FCU.
  - **Distal row of bones.** From lateral to medial.
    - **Trapezium.** Forms the carpometacarpal joint in the thumb.
    - **Trapezoid.** Four-sided bone.
    - **Capitate.** Has a head.
    - **Hamate.** Has a hook.
  - **Carpal arch.** Carpal bones form an arch and are not positioned in a flat plane.
- **Five metacarpals.** Form the bones of the palm of the hand; each of the five metacarpal bones are related to one digit. For example, metacarpal 1 to the thumb and metacarpal 5 to the pinkie.
- **Fourteen phalanges.** Form the bones of the digits.
  - **Digit 1 (thumb).** Possesses two digits (proximal and distal).
  - **Digits 2–5.** Possess three digits (proximal, middle, and distal).

ACTIONS OF THE FINGERS

The finger joints (digits 2–5) and associated movements are as follows (Figure 33-1C):

- **Carpometacarpal (CMC) joints.** Sliding joints that allow for gliding and rotation (except at the thumb where it is a saddle joint).
- **Metacarpophalangeal (MCP) joints.** Condylar joints that allow for flexion, extension, abduction, and adduction.
  - **Flexion and extension.** Moving the metacarpal toward the palm (flexion) and away from the palm (extension).
  - **Abduction and adduction.** Described in relation to digit 3; abduction is spreading fingers away from digit 3; adduction is moving fingers toward digit 3.
- **Interphalangeal (IP) joints.** Hinge joints that allow for flexion and extension; there is a proximal interphalangeal (PIP) joint and a distal interphalangeal (DIP) joint.

ACTIONS OF THE THUMB

The thumb joints and associated movements are as follows (Figure 33-1D):

- **Carpometacarpal (CMC) joint.** Saddle joint that allows for opposition and reposition.
- **Metacarpophalangeal (MCP) joint.** Hinge joint that allows for flexion and extension.
- **Interphalangeal (IP) joint.** Hinge joint that allows for flexion and extension (there is only one interphalangeal joint for digit 1 (the thumb)).

The thumb is rotated 90 degrees to digits 2 to 5. Therefore, abduction and adduction occur in the sagittal plane, and flexion and extension occur in the coronal plane.

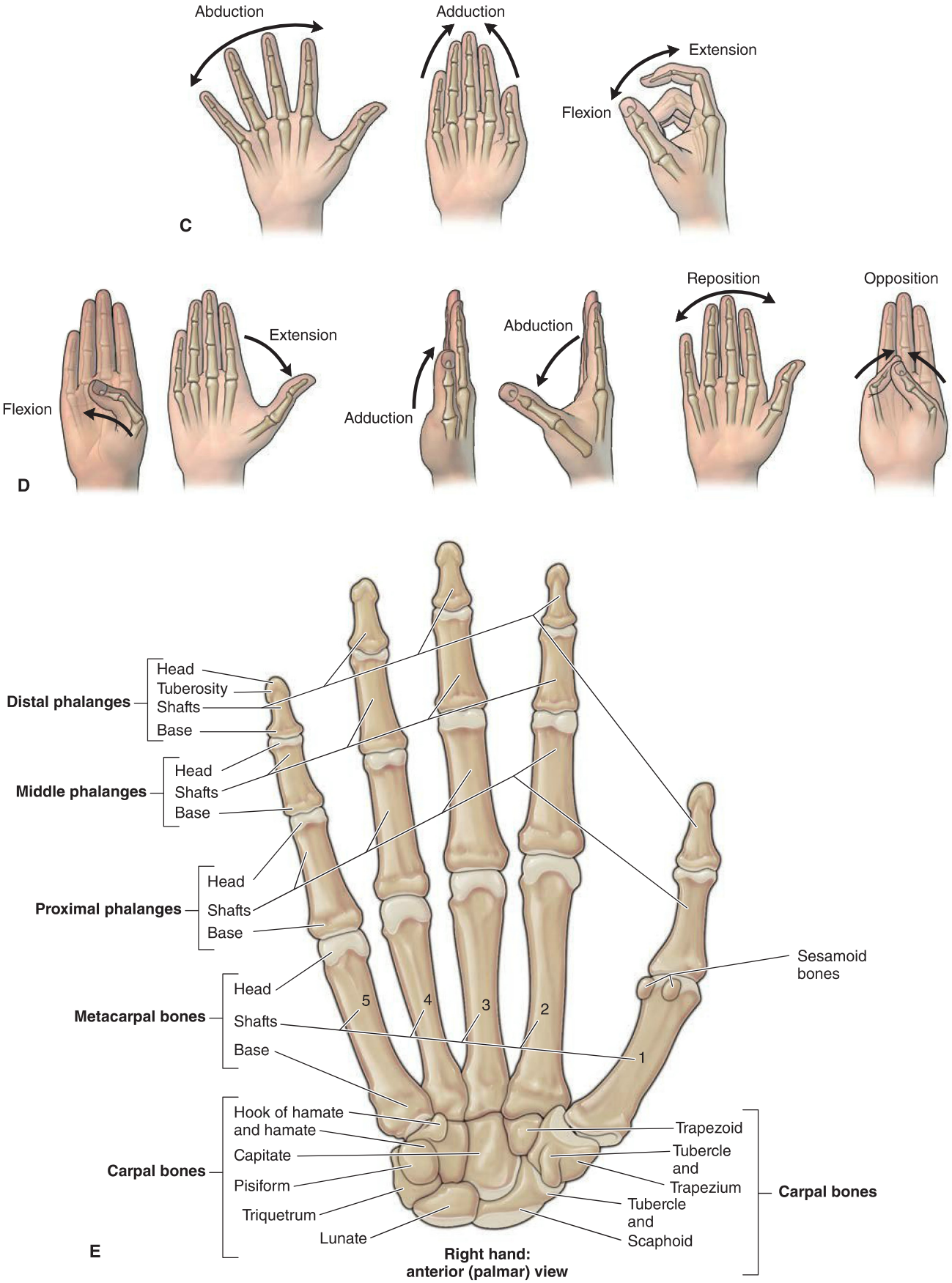

Figure 33-1: (*continued*) **C.** Actions of digits 2–4. **D.** Actions of digit 1 (thumb). **E.** Bones of the hand (anterior view).

MUSCLES OF THE HAND

BIG PICTURE

Muscles that act on the hand joints are either extrinsic (originating in the forearm and specialize in powerful gripping) or intrinsic (originating within the hand and specialize in precision movement) (Table 33-1). The thenar, hypothenar, lumbrical, adductor pollicis, dorsal interossei, and palmar interossei muscles are the intrinsic hand muscles and they are primarily innervated by the ulnar and median nerves (C8–T1).

THENAR MUSCLES

Thenar muscles insert and act on the thumb, contribute to the prominent thenar eminence, and consist of the **abductor pollicis brevis, flexor pollicis brevis,** and **opponens pollicis muscles** (Figure 33-2A).

- **Collective actions.** Opposition and fine motor movements of digit 1.
- **Innervation.** Recurrent branch of the median nerve (C8–T1).

HYPOTHENAR MUSCLES

Hypothenar muscles insert and act on digit 5, contribute to the prominent hypothenar eminence, and consist of the **abductor digiti minimi, flexor digiti minimi,** and **opponens digiti minimi muscles** (Figure 33-2A).

- **Collective actions.** Opposition and fine motor movements of digit 5.
- **Innervation.** Ulnar nerve (C8–T1).

LUMBRICAL MUSCLES

The lumbricals are four worm-like muscles each associated with the digits 2 to 5. The lumbrical muscles are unique in that they connect flexor tendons (FDP) with the extensor tendons (extensor expansion hood) (Figure 33-2A and B).

- **Attachments.** FDP tendons in the hand to the lateral sides of the dorsal digital expansions of digits 2 to 5.
- **Actions.** As a result of the insertion on the dorsal digital expansion, the lumbricals flex the MCP joints and extend the PIP and DIP joints for digits 2 to 5.
- **Innervation.**
  - Lumbricals 1 and 2. Lateral two lumbricals that act on digits 2 and 3 (digital branches of the median nerve (C8–T1).
  - Lumbricals 3 and 4. Medial two lumbricals that act on digitrs 4 and 5 (deep branches of the ulnar nerve (C8–T1)).

ADDUCTOR POLLICIS MUSCLE

Consists of a transverse and oblique head, both innervated by the deep branch of the ulnar nerve (C8–T1) (Figure 33-2A). As its name implies, this muscle adducts the thumb.

INTEROSSEOUS MUSCLES

All the interossei muscles share a common innervation from the deep branch of the ulnar nerve (C8–T1).

- **Dorsal interossei muscle** (Figure 33-2C). Four bipennate muscles located between the metacarpal bones on the posterior aspect of the hand.
  - **Attachments.** Sides of the metacarpals and dorsal digital expansion.
  - **Actions.** Abducts the fingers at the MCP joint. However, because the dorsal interossei muscle attaches to the dorsal digital expansion, it can also produce flexion of the MCP joint and extension at the IP joints. *A helpful acronym to remember the dorsal interossei muscle is "**DAB**," where "D" represents dorsal and "AB" represents abduction.*
  - **Innervation.** Deep branch of the ulnar nerve (C8–T1).
- **Palmar interossei muscle** (Figure 33-2D). Three unipennate muscles located between the metacarpal bones on the palmar side of the hand.
  - **Attachments.** Sides of the metacarpals and base of the proximal phalanx and the dorsal digital expansions.
  - **Adducts the MCP joints for the fingers.** However, because the muscle attaches to the dorsal digital expansion, it can also produce flexion of the metacarpophalangeal joint and extension at the proximal and distal interphalangeal joints. *A helpful acronym to remember the palmar interossei muscle is "**PAD**," where "P" represents palmar and "AD" represents adduct.*
  - **Innervation.** Deep branch of the ulnar nerve (C8–T1).

Flexor tendon injuries. Injury to the flexor tendons is commonly caused by a cut that causes one or both of the flexor tendons that attach to the digits to have impaired flexion. If the flexor digitorum profundus tendon is cut, the distal interphalangeal joint will be unable to flex, whereas the proximal interphalangeal joint will flex due to the intact flexor digitorum superficialis. This injury may be seen in an athlete whose finger is caught in the jersey of an opponent, causing tearing or avulsion of the flexor digitorum profundus from the distal phalanx. The injury is often referred to as "**jersey finger**."

Extensor tendon injuries in the region of the dorsal digital expansion into the distal phalanx may occur due to their superficial location. The injury usually occurs when an extended distal interphalangeal joint is forcefully flexed, causing tearing or even rupture. The result is the inability to extend the distal interphalangeal joint. The injury is often referred to as "**mallet finger**."

Injury to the dorsal digital expansion at the central slip is due to tearing or avulsing of the central slip of the dorsal digital expansion from the middle phalanx. The injury is usually due to forceful flexion of an extended proximal interphalangeal joint, and the result is the inability to extend the proximal interphalangeal joint. If untreated, a **boutonnière deformity** may occur. A boutonnière deformity is flexion of the proximal interphalangeal joint, with hyperextension of the distal interphalangeal and metacarpophalangeal joints.

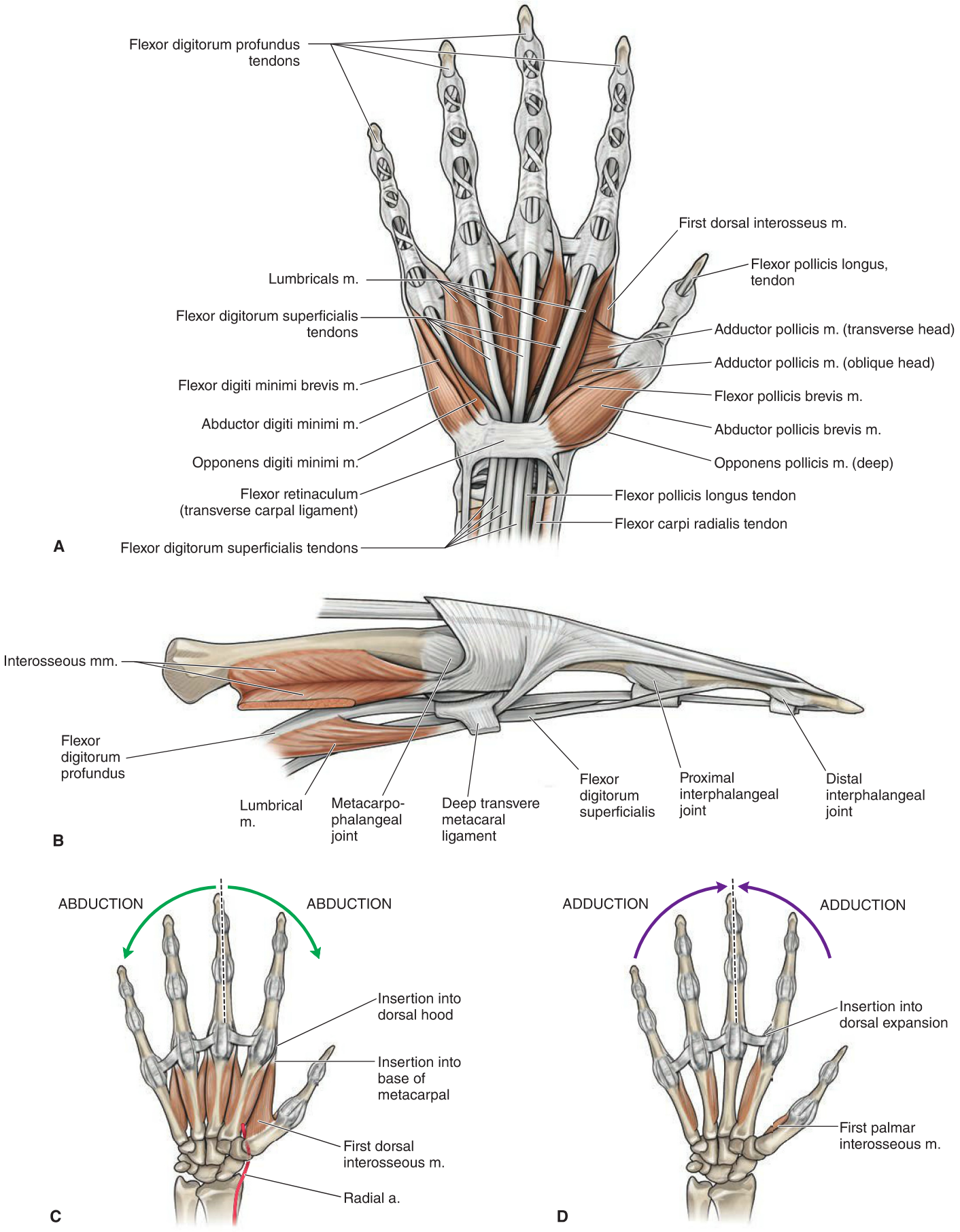

Figure 33-2: **A**. Muscles of the palm of the hand. **B**. Lumbrical muscles. **C**. Doral interossei muscles. **D**. Palmar interossei muscles.

TERMINAL BRANCHES OF THE BRACHIAL PLEXUS IN THE HAND

BIG PICTURE

The median nerve innervates lumbricals 1 and 2 and the thenar muscles (excluding the deep head of the flexor pollicis brevis). The ulnar nerve provides the remaining motor innervation to the hand. The superficial radial nerve, median nerve, and ulnar nerve provide sensory innervation to the hand.

ULNAR NERVE

In the forearm, the ulnar nerve gives rise to a dorsal branch and a palmar branch (Figure 33-3A).

- **Dorsal branch of ulnar nerve.** Provides cutaneous innervation to the medial side of the dorsum of the hand, digit 5, and the ulnar half of digit 4.
- **Palmar branch of ulnar nerve.** Provides cutaneous innervation to the medial palmar surface of the hand.

The ulnar nerve enters the hand superficial to the carpal tunnel, laterally to the pisiform with the ulnar artery, and then bifurcates into a deep and a superficial branch.

- **Deep branch of ulnar nerve.** Crosses the palm in a fibro-osseous tunnel (Guyon's tunnel) and supplies the hypothenar compartment, adductor pollicis, dorsal interossei, palmar interossei, and two medial lumbricals. Also innervates the deep head of the flexor pollicus brevis muscle.
- **Superficial branch of ulnar nerve.** Supplies the palmaris brevis and then bifurcates into the common and the proper palmar digital branches to travel along digit 5 and the medial side of digit 4 to supply the surrounding skin.

MEDIAN NERVE

Proximal to the carpal tunnel, the median nerve gives rise to a palmar branch (Figure 33-3B).

- **Palmar branch of the median nerve.** Provides cutaneous innervation to the lateral palmar surface of the hand.

After passing through the carpal tunnel, the median nerve branches into the following branches:

- **Recurrent branch of the median nerve.** Innervates the thenar muscles of the hand.
- **Palmar digital nerves.** Travel along the first three digits and the lateral side of the fourth, supplying the lateral two lumbricals, the palmar skin of the first three digits, and the radial side of the fourth digit.

RADIAL NERVE

The **superficial branch of the radial nerve** enters the hand by coursing superficially over the anatomical snuffbox, and supplies the skin on the dorsal side of the first three digits (Figure 33-3C).

- The radial nerve has no motor innervation to intrinsic muscles of the hand and only innervates the extrinsic muscles that send tendons from muscles that originate in the posterior forearm to the thumb and digits.

Carpal tunnel syndrome. A condition caused by swelling of the flexor digitorum superficialis, profundus, and flexor pollicis longus tendon synovial sheaths, resulting in pressure on the median nerve. Repetitive motions of the fingers and wrist, hormonal changes, and vibration can be causes of tendon swelling. The result is tingling and numbness in the cutaneous distribution of the median nerve (lateral side). In more severe cases, atrophy of the thenar eminence may be present. The palmar cutaneous branch provides cutaneous innervation to the lateral palm and should be spared in a patient who has carpal tunnel syndrome.

Ulnar nerve injuries. When the ulnar nerve is injured in the hand there is a loss of the interossei and lumbricals 3 and 4, and clawing of digits 4 and 5 may become apparent due to an imbalance of the extrinsic and intrinsic muscles. Because the extrinsic extensors of the hand are not opposed by the intrinsic flexors of the hand, the metacarpophalangeal joint hyperextends and is unable to extend the proximal and distal interphalangeal joints. The proximal and distal interphalangeal joints continue to flex because the extrinsic flexors are not opposed by the intrinsic extensors of the distal and proximal interphalangeal joints. The result is extension of the metacarpophalangeal joint and flexion of the proximal and distal interphalangeal joints.

Klumpke's palsy. Stretching of the inferior trunk may damage the C8–T1 spinal roots resulting in Klumpke's palsy. Notable loss or limited function of forearm flexors and intrinsic hand muscles would most likely be observed. Symptoms would most likely include weakness in wrist flexion, and in finger flexion, abduction, and adduction. As all intrinsic muscles of the hand are affected a "claw hand" may result.

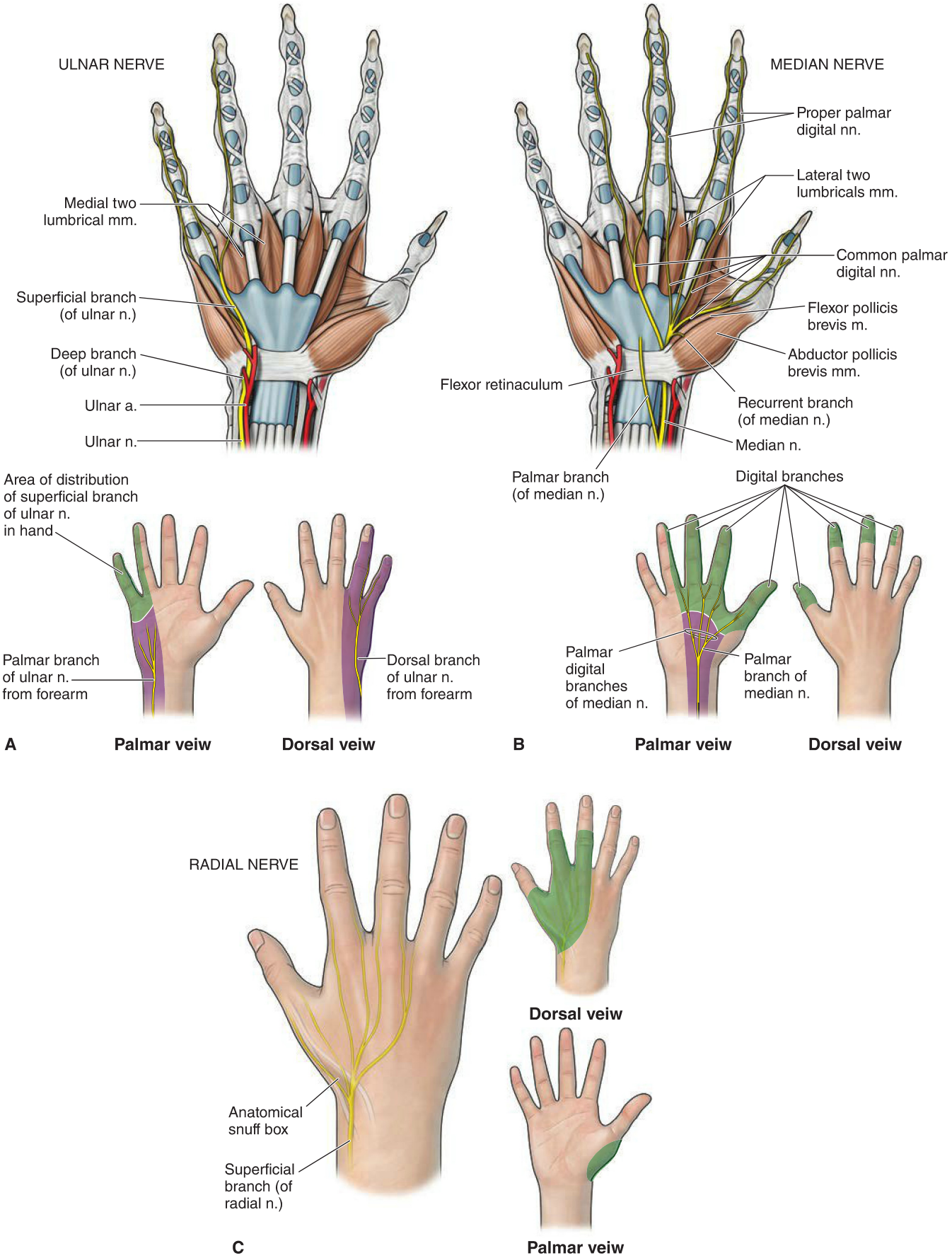

Figure 33-3: **A**. Ulnar nerve. **B**. Median nerve. **C**. Radial nerve.

VASCULARIZATION OF THE HAND

BIG PICTURE

The blood supply to the hand is provided by the radial and ulnar arteries, which give rise to a superficial and a deep palmar arch and to smaller tributaries as they travel distally to the tips of the fingers. The blood is returned to the axillary and subclavian veins via a deep and superficial venous system.

ULNAR ARTERY

The ulnar artery, with the ulnar nerve, enters the hand lateral to the pisiform, where it gives rise to the deep palmar branch and becomes the principal contributor to the superficial palmar arch (Figure 33-4A).

- **Deep palmar branch.** Curves medially around the hook of the hamate to the deep layer of the palm, where it anastomoses with the deep palmar arch of the radial artery. It also gives rise to the **palmar metacarpal arteries**, which in turn anastomose with the **common palmar digital arteries** and bifurcate into the **proper palmar digital arteries**.
- **Superficial palmar arch.** Anastomoses with the palmar branch of the radial artery just deep to the palmar aponeurosis, where it gives rise to the common palmar digital arteries. These arteries then bifurcate to become the proper palmar digital arteries that supply the digits.

RADIAL ARTERY

The radial artery courses through the anatomical snuff box, contributes to the dorsal carpal arch, and then travels deep into the hand, becoming the principal contributor to the deep palmar arch (Figure 33-4B).

- **Deep palmar arch.** Travels deep to the adductor pollicis and anastomoses with the deep palmar branch of the ulnar artery, giving rise to the palmar metacarpal arteries.
- **Dorsal carpal arterial arch.** Courses along the dorsal side of the wrist, giving rise to the dorsal metacarpal and dorsal digital arteries.

VEINS OF THE HAND

The hand contains a **deep** and a **superficial venous system**. The deep veins are named according to the arteries they follow (Figure 33-4C). The superficial venous system drains into the **dorsal venous arch**. From the dorsal venous arch, the radial side of the hand drains to the cephalic vein and the ulnar side of the hand drains to the basilic vein.

▼ **Raynaud's syndrome.** A condition caused by a vascular spasm that most commonly involves the fingers but occasionally the toes as well. The spasms can be caused by cold or stress and result in numbness, burning pain, color changes, and tingling of one or more fingers. ▼

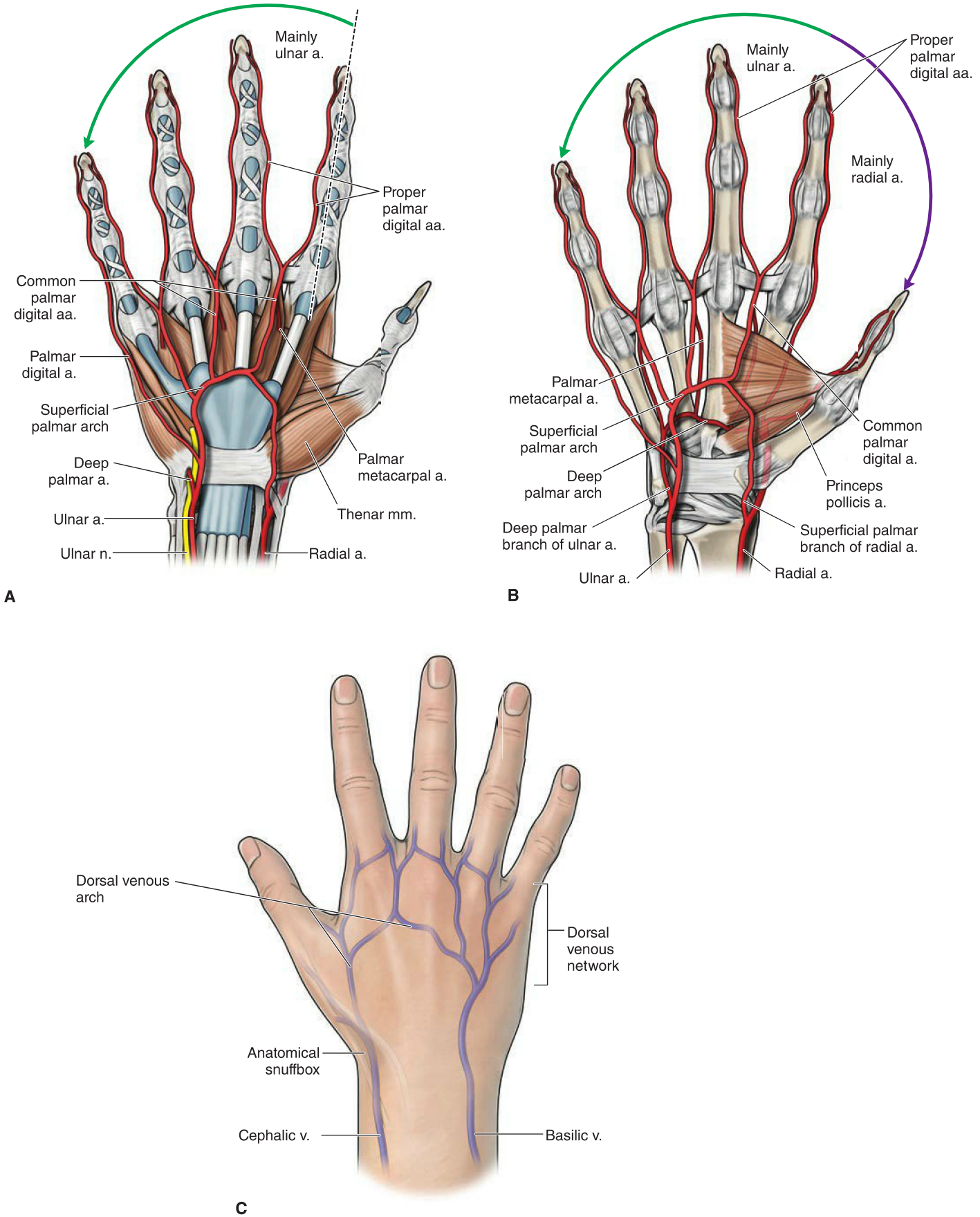

Figure 33-4: **A**. Superficial palmar arch. **B**. Deep palmar arch. **C**. Veins of the hand.

JOINTS OF THE HAND

BIG PICTURE

The hand is composed of carpometacarpal, metacarpophalangeal, and interphalangeal joints.

JOINTS OF DIGITS 2 TO 4

- **Carpometacarpal joints.** Articulate between the distal row of carpal bones and the metacarpals of digits 2 to 4. The carpometacarpal joints are classified most often as plane synovial joints (gliding) (Figure 33-5C).
- **Metacarpophalangeal (MCP) joints.** Articulate between the metacarpal head and the base of the proximal phalanx. The metacarpophalangeal joints are classified as a synovial condyloid joint that produces flexion and extension and abduction and adduction.
- **Interphalangeal (IP) joints.** Synovial hinge joints between phalanges that produce flexion and extension movements. There are two sets of IP joints (except in the thumb, which has only one):
  - **Proximal interphalangeal (PIP) joint.** Located between proximal and middle phalanges.
  - **Distal interphalangeal (DIP) joint.** Located between middle and distal phalanges.

JOINTS OF DIGIT 1 (THUMB)

- **Carpometacarpal joints.** A saddle joint that produces flexion and extension and abduction and adduction. The carpometacarpal joints also produce some rotation when combined with other motions of the thumb (Figure 33-5C).
- **Metacarpophalangeal (MCP) joints.** Articulate between the head of the first metacarpal and the base of the first proximal phalanx. The metacarpophalangeal joints are classified as synovial condyloid joints that produce flexion and extension.
- **Interphalangeal (IP) joint.** Articulates between the head of the proximal phalanx and the base of the distal phalanx. The interphalangeal joints are classified as synovial hinge joints that produce flexion and extension.

LIGAMENTOUS AND CAPSULAR SUPPORT

- **Carpometacarpal joints.** Supported by articular capsules and dorsal, palmar, and interosseous ligaments (Figure 33-5C).
- **Metacarpophalangeal.** Supported by a capsule as well as a palmar and two collateral ligaments, a volar plate, and the deep transverse metacarpal ligament.
  - **Palmar ligaments.** Located between the collateral ligaments on the palmar side and support the palmar side of the joint.
  - **Collateral ligaments.** Attached proximally to the sides of the metacarpal and run distally in an anterior direction to attach to the phalanges. These ligaments are important for stability of the medial and lateral joint capsules.
  - **Volar plate.** Structure that increases joint congruence. It is composed of fibrocartilage and is connected to the proximal phalanx and the joint capsule.
  - **Deep transverse metacarpal ligaments.** Connect the metacarpal heads of digits 2 to 4 as well as connect laterally to the volar plate.
- **Interphalangeal joints.** A joint capsule, a volar plate, and two collateral ligaments support both the proximal and distal interphalangeal joints.
  - **Volar plate.** Supports and reinforces the joint capsule of the interphalangeal joints.
  - **Collateral ligaments.** Located on the medial and lateral sides of the capsule and provide medial and lateral support throughout the proximal and distal interphalangeal movement.

MUSCULAR SUPPORT

- **Interphalangeal joints** (Figure 33-5A and B).
  - **Palmar side.** The flexor digitorum superficialis and the flexor digitorum profundus muscles will cross anteriorly at the proximal interphalangeal joint, whereas only the flexor digitorum profundus will cross anteriorly at the distal interphalangeal joint.
  - **Dorsal side.** At the proximal and distal interphalangeal joint, the extensor digitorum, extensor digiti minimi, extensor pollicis longus, extensor pollicis brevis, lumbricals, and interossei muscles will support the dorsal aspect of the joint primarily through their attachment to the dorsal digital expansion.
- **Metacarpophalangeal joints.**
  - **Palmar side.** Support to the metacarpophalangeal joints is provided by the flexor digitorum superficialis, flexor digitorum profundus, lumbricals, interossei, flexor digiti minimi brevis, flexor pollicis longus, and flexor pollicis brevis muscles.
  - **Dorsal side.** Support is provided by the extensor digitorum, extensor indicis, extensor digiti minimi, extensor pollicis longus, and extensor pollicis brevis muscles.

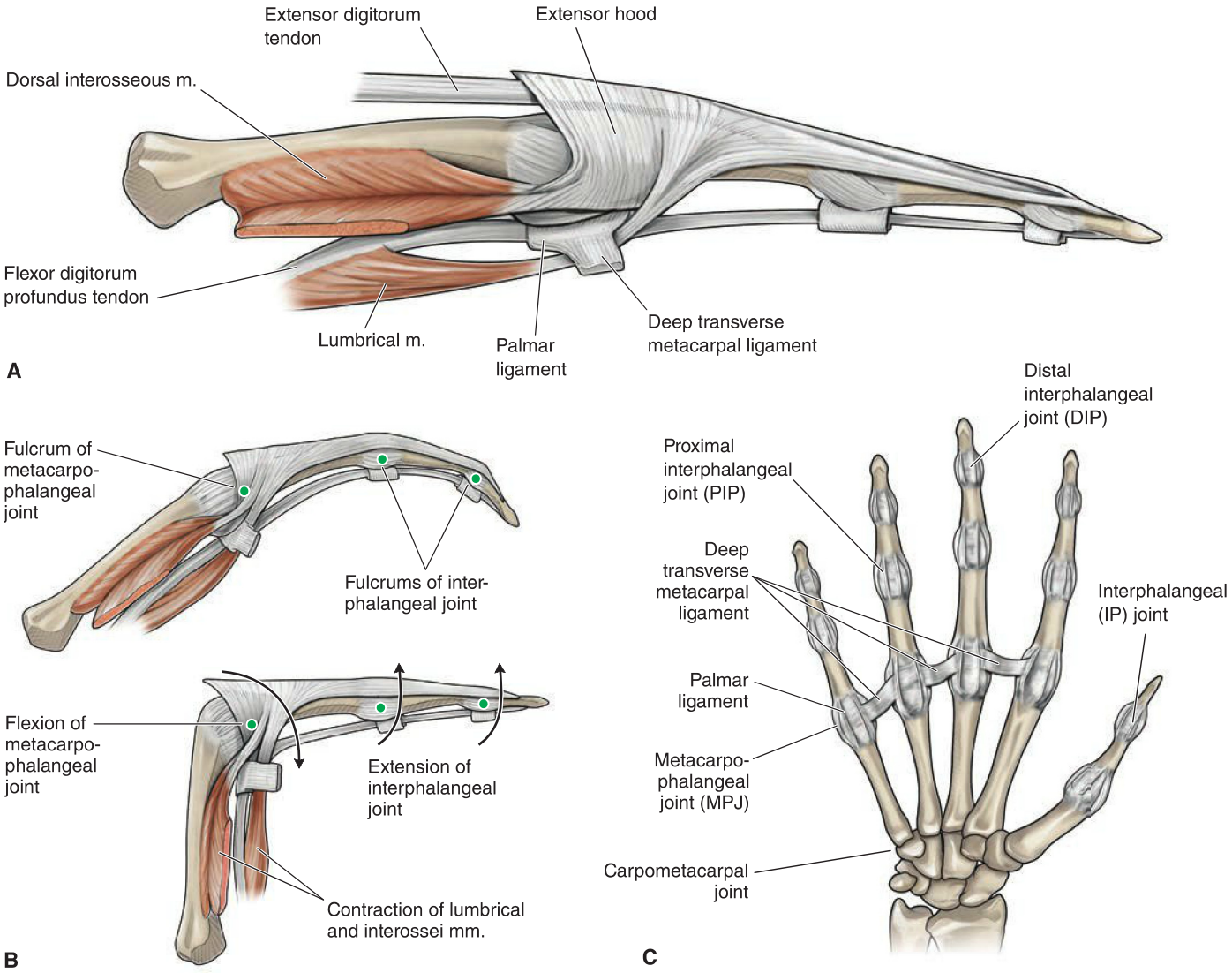

Figure 33-5: **A**. Extensor expansion. **B**. Movements of the lumbrical and interossei muscles. **C**. Ligaments and joints of the hand.

TABLE 33-1. Muscles of the Hand

Muscle	Proximal Attachment	Distal Attachment	Action	Innervation
Palmaris brevis	Palmar aponeurosis and flexor retinaculum	Dermis on the ulnar side of hand	Tenses the skin over the hypothenar muscles	Ulnar n., superficial branch (C8–T1)
Thenar muscles				
Abductor pollicis brevis	Flexor retinaculum, scaphoid, and trapezium	Proximal phalanx of digit 1	Abduction of thumb	Median n., recurrent branch (C8–T1)
Flexor pollicis brevis	Deep head: trapezium and flexor retinaculum Superficial head: trapezoid and capitate		Flexion of digit 1 (metacarpophalangeal joint)	
Opponens pollicis	Trapezium and flexor retinaculum	Metacarpal 1	Medial rotation of thumb and flexion of metacarpal of digit 1	
Adductor compartment				
Adductor pollicis	Oblique head: metacarpals 2 and 3 and capitates Transverse head: metacarpal 3	Proximal phalanx of digit 1	Adduction of thumb	Ulnar n., deep branch (C8–T1)
Hypothenar muscles				
Abductor digit minimi	Pisiform bone, pisohamate ligament, and tendon of flexor carpi ulnaris	Proximal phalanx of digit 5	Abduction of digit 5	Ulnar n., deep branch (C8–T1)
Flexor digiti minimi brevis	Hook of hamate and flexor retinaculum		Flexion of metacarpophalangeal joint of digit 5	
Opponens digiti minimi		Metacarpal 5	Lateral rotation of metacarpal 5	
Central compartment				
Lumbricals 1 and 2	Lateral two tendons of flexor digitorum profundus	Lateral sides of dorsal digital expansions for digits 2–5	Flexes metacarpophalangeal joints and extends interphalangeal joints	Median n. (C8–T1)
Lumbricals 3 and 4	Medial two tendons of flexor digitorum profundus			Ulnar n., deep branch (C8–T1)
Dorsal interossei 1–4	Adjacent sides of metacarpals	Dorsal digital expansions and base of proximal phalanges of digits 2–4	Abducts digits (DAB) and flexes metacarpophalangeal joints and extends interphalangeal joints	Ulnar n., deep branch (C8–T1)
Palmar interossei 1–3	Metacarpals 2, 4, and 5	Dorsal digital expansions and base of proximal phalanges of digits 2, 4, and 5	Adducts digits (PAD) and flexes metacarpophalangeal joints and extends interphalangeal joints	

STUDY QUESTIONS

Directions: Each of the numbered items or incomplete statements is followed by lettered options. Select the **one** lettered option that is **best** in each case.

1. Which of the following structures is the only boney connection between the axial and appendicular skeleton?

A. Clavicle
B. Humerus
C. Radius
D. Scapula
E. Ulna

2. A 38-year-old construction worker sees his health care provider because of shoulder pain. Physical examination reveals a dislocated glenohumeral joint. Radiographic imaging reveals a tear in the muscles that stabilize the glenohumeral joint. Identify the muscle most likely injured in this patient.

A. Biceps brachii muscle
B. Infraspinatus muscle
C. Pectoralis minor muscle
D. Serratus anterior muscle
E. Triceps brachii muscle

3. A 41-year-old executive sees her physician because of chronic spasm of the scalene muscles due to stress and depression. The physician determines that she has thoracic outlet syndrome. The scalene muscle spasms most likely affect which region of the brachial plexus?

A. Branches
B. Cords
C. Divisions
D. Roots
E. Trunks

4. A 46-year-old woman sees her health care provider with a complaint of pain over the anterolateral forearm. Clinical examination reveals no muscle weakness in the patient's upper limb, but notes problems with the right lateral cutaneous nerve of the forearm. Which of the following is the most likely activity resulting in this patient's injury?

A. Avulsion of the medial epicondyle of the humerus
B. Fracture in the midhumeral region
C. Hypertrophy of the coracobrachialis muscle
D. Tendon inflammation on the lateral epicondyle of the humerus
E. Venipuncture of the right cephalic vein in the antebrachial fossa

5. The radial and ulnar arteries most likely arise from the bifurcation of which artery?

A. Axillary
B. Brachial
C. Cephalic
D. Subclavian

6. The upper subscapular, lower subscapular, and thoracodorsal nerves branch from which cord of the brachial plexus?

A. Anterior cord
B. Lateral cord
C. Medial cord
D. Posterior cord

7. Which of the following is the limb muscle in which its motor neuron origin resides in a cranial nerve (CN)?

A. Levator scapulae
B. Pectoralis minor
C. Rhomboid major
D. Serratus anterior
E. Trapezius

8. You watch a friend as he is doing pushups and notice the medial border of his right scapula protruding from his thorax more than it protrudes on his left side. Which muscle is weakened on your friend's right side that is causing this protrusion?

A. Pectoralis major muscle
B. Serratus anterior muscle
C. Trapezius muscle
D. Triceps brachii muscle

9. A paralabral cyst arising from a detached inferior glenoid labrum tear compresses neurovascular structures coursing through the quadrangular space. If this condition were to become chronic, which of the following findings would most likely be revealed on an MRI?

A. Atrophy in the deltoid muscle
B. Atrophy in the biceps brachii muscle
C. Atrophy of the pectoralis major muscle
D. Impingement of the ulnar nerve
E. Impingement of the radial nerve
F. Impingement of the medial nerve

10. The suprascapular and dorsal scapular arteries form a collateral circuit on the posterior side of the scapula with which of the following branches of the axillary artery?

A. Anterior circumflex humeral artery
B. Circumflex scapular artery
C. Posterior circumflex humeral artery
D. Thoracodorsal artery

11. Which of the following muscles can flex, extend, and abduct the glenohumeral joint?

A. Biceps brachii muscle
B. Deltoid muscle
C. Latissimus dorsi muscle
D. Pectoralis major muscle
E. Triceps brachii muscle

12. A 41-year-old construction worker visits his health care provider because of an infected cutaneous laceration in his hand. Bacteria entering the lymph via the lesion will next pass through which lymph nodes?

A. Apical nodes
B. Central nodes
C. Humeral nodes
D. Pectoral nodes

13. The boundaries of the three parts of the axillary artery are determined by its relationship to which muscle?

A. Pectoralis major muscle
B. Pectoralis minor muscle
C. Teres major muscle
D. Teres minor muscle

14. Which of the following muscles flexes the glenohumeral and elbow joints and supinates the radioulnar joints?

A. Coracobrachialis muscle
B. Biceps brachii muscle
C. Brachialis muscle
D. Triceps brachii muscle

15. A 17-year-old patient sees his health care provider with a complaint of weakness with elbow flexion and numbness on the lateral side of the forearm. Which of the flowing nerves is most likely damaged?

A. Axillary nerve
B. Median nerve
C. Musculocutaneous nerve
D. Radial nerve
E. Ulnar nerve

16. Which of the following nerves courses between the brachialis and brachioradialis muscles?

A. Axillary nerve
B. Median nerve
C. Musculocutaneous nerve
D. Radial nerve
E. Ulnar nerve

17. The superior ulnar collateral artery forms a collateral circuit with which of the following arteries?

A. Anterior interosseous artery
B. Anterior ulnar recurrent artery
C. Middle collateral artery
D. Posterior ulnar recurrent artery
E. Radial collateral artery

18. A patient is diagnosed with a peripheral nerve injury that weakens his ability to extend his elbow, wrist, and fingers. Which area of this patient's upper limb will most likely experience cutaneous deficit as a result of this injury?

A. Anterior forearm
B. Lateral forearm
C. Medial forearm
D. Posterior forearm

19. A 49-year-old woman is diagnosed with carpal tunnel syndrome. Which tendon of the following muscles would most likely be associated with carpal tunnel syndrome?

A. Flexor carpi radialis muscle
B. Flexor carpi ulnaris muscle
C. Flexor pollicis longus muscle
D. Palmaris longus muscle
E. Pronator teres muscle
F. Pronator quadratus muscle

20. Which of the following muscles flexes the wrist and the metacarpophalangeal and the proximal and distal interphalangeal joints of digits 2 to 5?

A. Flexor carpi radialis muscle
B. Flexor carpi ulnaris muscle
C. Flexor digitorum profundus muscle
D. Flexor digitorum superficialis muscle

21. Which of the following muscles flexes the metacarpophalangeal joints, but extends the interphalangeal joints of digits 2 to 5?

A. Flexor digitorum profundus muscle
B. Lumbrical muscle
C. Flexor digitorum superficialis muscle
D. Palmaris brevis muscle

22. Which of the following arteries supplies blood to the deep extensor muscles of the forearm?

A. Anterior interosseous artery
B. Posterior interosseous artery
C. Radial collateral artery
D. Radial recurrent artery

23. The radiocarpal joint includes the distal end of the radius, the triangular fibrocartilage complex, the scaphoid bone, the triquetrum bone, and which of the following carpal bones?

A. Capitate
B. Hamate
C. Lunate
D. Trapezium

24. Which of the following fascial layers forms the roof of the carpal tunnel?

A. Fibrous digital sheaths
B. Flexor retinaculum
C. Palmar aponeurosis
D. Transverse palmar ligament

25. Inflammation in Guyon's canal will most likely result in weakness in which of the following movements?

A. Adduction of digits 2 to 5
B. Adduction of the thumb
C. Flexion of the wrist
D. Extension of the wrist

26. Compression of the median nerve in the carpal tunnel leads to weakness in the thenar muscles and the first and second lumbricals as well as cutaneous deficits in which of the following regions?

A. Lateral dorsal surface of the hand
B. Medial dorsal surface of the hand
C. Palmar surface of digit 5
D. Palmer surface of digits 2 and 3

27. Which of the following arteries courses through the anatomical snuffbox?

A. Deep palmar arch
B. Radial artery
C. Superficial palmar arch
D. Ulnar artery

ANSWERS

1—A: The clavicle connects the manubrium of the sternum to the acromion of the scapula. All other support is through muscles and ligaments.

2—B: The rotator cuff muscle group stabilizes the glenohumeral joint. The tendons of these muscles reinforce the ligaments of the glenohumeral joint capsule. The tendons of the long head of the biceps and triceps brachii muscles attach to the supraglenoid and infraglenoid tubercles, but do not significantly contribute to stability of the glenohumeral joint.

3—D: The roots of the brachial plexus pass between the anterior and middle scalene muscles. Spasm of these muscles can cause entrapment of the roots of the plexus.

4—E: The musculocutaneous nerve innervates the anterior compartment of the arm. The cephalic vein courses in the antebrachial fossa adjacent to the lateral cutaneous nerve of the forearm. Therefore, a venipuncture of the cephalic vein may injure the adjacent cutaneous branch of the musculocutaneous nerve. Avulsion of the medial epicondyle would affect forearm flexors, and a midhumeral fracture would affect the radial nerve. Hypertrophy of the coracobrachialis muscle would affect the entire musculocutaneous nerve and result in the cutaneous presentation, but would also negatively affect motor activity. Lateral epicondyle inflammation would affect forearm extensors.

5—B: The brachial artery bifurcates just distal to the elbow to form the radial and ulnar arteries.

6—D: The upper subscapular, lower subscapular, and thoracodorsal nerves branch off of the posterior cord in the axilla, just anterior to the subscapularis muscle.

7—E: The trapezius muscle is the only upper limb muscle innervated by the spinal accessory nerve (CN XI).

8—B: The serratus anterior muscle stabilizes the medial border of the scapula against the thorax. When in a pushup position, the medial border of the scapula is pushed away from the thorax, making the weakness more apparent.

9—A: The axillary nerve courses through the quadrangular space with the posterior humeral circumflex artery. Therefore, compression of the axillary nerve would weaken the deltoid muscle and thus weaken shoulder abduction.

10—B: The circumflex scapular artery courses through the triangular space to form a collateral circuit with the suprascapular and dorsal scapular arteries.

11—B: The deltoid muscle inserts in the deltoid tuberosity of the humerus. However, its origins include the lateral third of the clavicle (flexion), acromion (abduction), and scapular spine (extension).

12—C: Lymph traveling from the arm will first course through the humeral nodes before continuing toward the central and apical nodes of the axilla.

13—B: The boundaries of the three parts of the axillary artery are determined by its relationship to the pectoralis minor muscle.

14—B: The biceps brachii muscle flexes the glenohumeral and elbow joints because of its anterior position. Its attachment to the radial tuberosity also allows it to supinate the radioulnar joints.

15—C: When the musculocutaneous nerve is damaged, the biceps brachii and brachialis muscles are weakened or paralyzed. The skin innervated by the lateral cutaneous nerve of the forearm would feel tingly or numb.

16—D: The radial nerve courses between the brachialis and brachioradialis muscles on the lateral side of the brachium after piercing the intermuscular septum.

17—D: The superior ulnar collateral artery anastomoses with the posterior ulnar recurrent artery from the ulnar artery that is posterior to the medial epicondyle.

18—D: Damage to the radial nerve would cause the weakness in the triceps brachii muscle and extension of the elbow. This damage would cause deficits in the cutaneous field of the radial nerve in the posterior forearm.

19—C: The tendon of the flexor pollicis longus muscle courses through the carpal tunnel with the tendons of the flexor digitorum superficialis and the flexor digitorum profundus muscles and the median nerve.

20—C: The flexor digitorum profundus muscle flexes the wrist and the metacarpophalangeal and the proximal and distal interphalangeal joints of digits 2 to 5.

21—B: The lumbrical muscles cross anterior to the metacarpophalangeal joints, then insert on the extensor expansion. It is this orientation that allows the muscles to flex the metacarpophalangeal joints and extend the interphalangeal joints.

22—B: The posterior interosseous artery branches from the common interosseous artery, courses along the anterior surface of the interosseous membrane, and pierces the membrane to supply the deep extensor muscles.

23—C: The radiocarpal joint is formed by the distal end of the radius, the triangular fibrocartilage complex, and the proximal row of the carpal bones. The lunate bone is included in the proximal carpals.

24—B: The flexor retinaculum anchors to the hamate, pisiform, trapezium, and scaphoid bones to enclose the tendons of the flexor digitorum superficialis, the flexor digitorum profundus, and the flexor pollicis longus muscles and the median nerve.

25—A: The ulnar nerve courses through Guyon's canal. Compression of the nerve will cause weakness in the muscles it innervates, including the palmer interosseous muscles, which are responsible for adduction of digits 2 to 5.

26—D: The digital branches of the median nerve send cutaneous branches to the skin of digits 2 and 3 and half of 4 primarily on the palmar side of the hand after the median nerve passes through the carpal tunnel. The palmar branch of the median nerve that innervates the lateral skin of the palm branches proximal to the carpal tunnel and would not be involved.

27—B: The radial artery courses through the anatomical snuffbox. The radial pulse can be felt at this site.

This page intentionally left blank

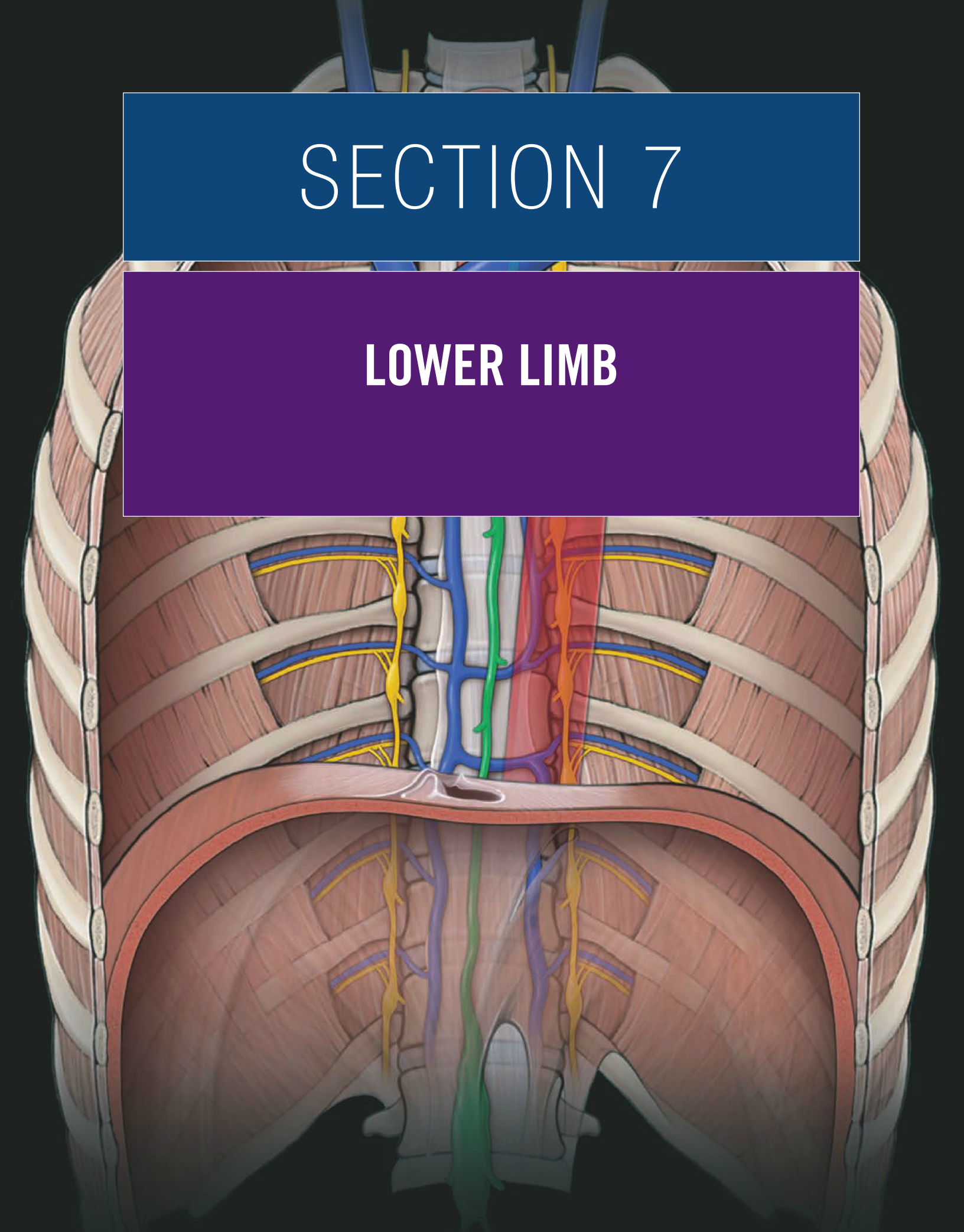

SECTION 7

LOWER LIMB

This page intentionally left blank

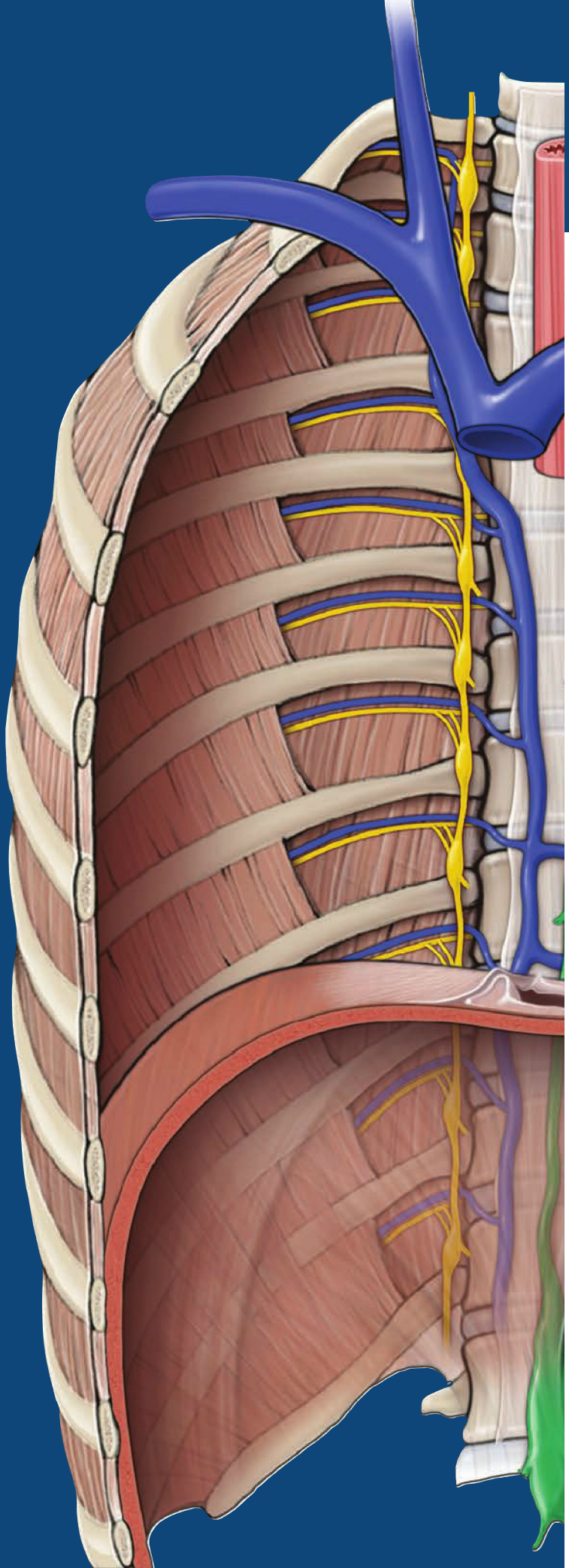

CHAPTER 34

OVERVIEW OF THE LOWER LIMB

Bones of the Pelvic Region and Thigh 376
Bones of the Leg and Foot 378
Fascial Planes and Muscles 380
Innervation of the Lower Limb 382
Sensation of the Lower Limb 384
Vascularization of the Lower Limb 386

BONES OF THE PELVIC REGION AND THIGH

BIG PICTURE

The bones of the skeleton provide a framework that serves as an attachment for soft tissues (e.g., muscles). The bony structure of the gluteal region and thigh, from proximal to distal, consists of the pelvis, femur, patella, tibia, and fibula (Figure 34-1A). Synovial joints and fibrous ligaments serve to connect bones together.

PELVIC AND THIGH BONES

THE PELVIS The pelvis consists of right and left pelvic bones and has the following properties (Figure 34-1A and B):

- **Articulations.** The pelvic bones articulate posteriorly with the sacrum via the **sacroiliac joints**, and anteriorly with each other at the **pubic symphysis**.
- **Constituents.** Each pelvic bone consists of three bones: **ilium, ischium**, and **pubis**.
- **Acetabulum.** A large cup-shaped structure at the junction where the ilium, ischium, and pubis fuse. The acetabulum protrudes laterally for articulation with the head of the femur bone.
- **Obturator foramen.** An opening formed by the ilium, ischium, and pubis.

ILIUM The ilium is the most superior and the largest bone of the three components of the pelvis.

- **Iliac fossa.** Attachment site for the iliacus muscle.
- **Iliac crest.** A prominent, palpable crest between the ASIS and PSIS where numerous body wall and limb muscles attach; possesses a large amount of red bone marrow and thus an ideal harvest site to collect stem cells in bone marrow transplant surgery. Additionally, the iliac crest marks the L4 vertebral level.
- **Anterior superior iliac spine (ASIS).** Attachment site of the inguinal ligament, sartorius muscle, and tensor fascia latae muscle.
- **Anterior inferior iliac spine (AIIS).** Attachment site for the rectus femoris muscle.
- **Posterior superior iliac spine (PSIS).** Attachment site for sacroiliac ligaments and the multifidus muscle; forms the dimples in the skin immediately superior and lateral to the gluteal cleft.
- **Posterior inferior iliac spine (PIIS).** Attachment site for ligaments.

ISCHIUM The ischium is the posterior and inferior component of the pelvic bone.

- **Ischial tuberosity.** A large tuberosity on the posteroinferior aspect of the ischium where the hamstring and adductor magnus muscles and sacrotuberous ligament attach. Covered by the gluteus maximus when standing but uncovers them when sitting; when sitting the weight is placed upon the ischial tuberosities.
- **Ischial ramus.** Projects anteriorly to join with the inferior ramus of the pubis; serves as attachment site for muscles.
- **Ischial spine.** A prominent spine that separates the lesser sciatic notch from the greater sciatic notch; serves as a site for muscle attachment and landmark for giving a pudendal nerve block.

PUBIS The pubis is the anterior and inferior part of the pelvic bone. The pubis has a body and two arms called rami.

- **Pubic tubercle.** A rounded crest on the superior surface of the pubis; attachment site for the inguinal ligament.
- **Superior pubic ramus.** Projects posterolaterally and joins with the ilium and ischium; forms part of the obturator foramen.
- **Inferior pubic ramus.** Projects laterally and inferiorly to join with the ramus of the ischium; serves as attachment site for muscles.

FEMUR

The femur forms the principal bone of the thigh and consists of the following landmarks (Figure 34-1A and C):

- **Head.** A spherically shaped knob on the proximal end of the femur that articulates with the acetabulum of the pelvic bone. The head is characterized by a nonarticular **fovea** on its medial surface, which serves as an attachment for the **foveolar ligament** (ligament of the head of the femur).
- **Neck.** A cylindrical part of the bone that connects the head to the shaft of the femur. The neck has a unique superomedial projection from the shaft at an angle of about 125 degrees and a slight forward projection.
- **Greater trochanter.** Attachment site for gluteus medius, gluteus minimis, piriformis, superior gemellus, inferior gemellus, obturator internus, and obturator externus muscles.
- **Lesser trochanter.** Attachment site for the iliopsoas muscle.
- **Linea aspera.** A distinct vertical ridge on the posterior femoral shaft; attachment site for vastus medialis, vastus lateralis, adductor muscles (brevis, longus, magnus), and short head of the biceps femoris muscles.
- **Pectineal line.** Attachment site for the pectineus muscle.
- **Medial and lateral condyles.** Both condyles lie at the distal aspect of the femur and articulate with the tibia to form the knee joint.
  - **Adductor tubercle.** Lies superior to the medial condyle; attachment site for the vertical fibers of the adductor magnus muscle.
- **Medial and lateral epicondyles.** Rounded eminences on the medial and lateral surfaces of either condyle; attachment site for the collateral ligaments of the knee joint.

PATELLA

The patella (knee cap) is the largest sesamoid bone in the body. It is formed in the tendon of the quadriceps femoris muscle and covers and protects the anterior region of the knee joint (Figure 34-1A). Its primary function is to increase the leverage of the quadriceps femoris muscles during knee extension. Babies are born with a patella of soft cartilage that starts to ossify between the ages of 3 and 6 years.

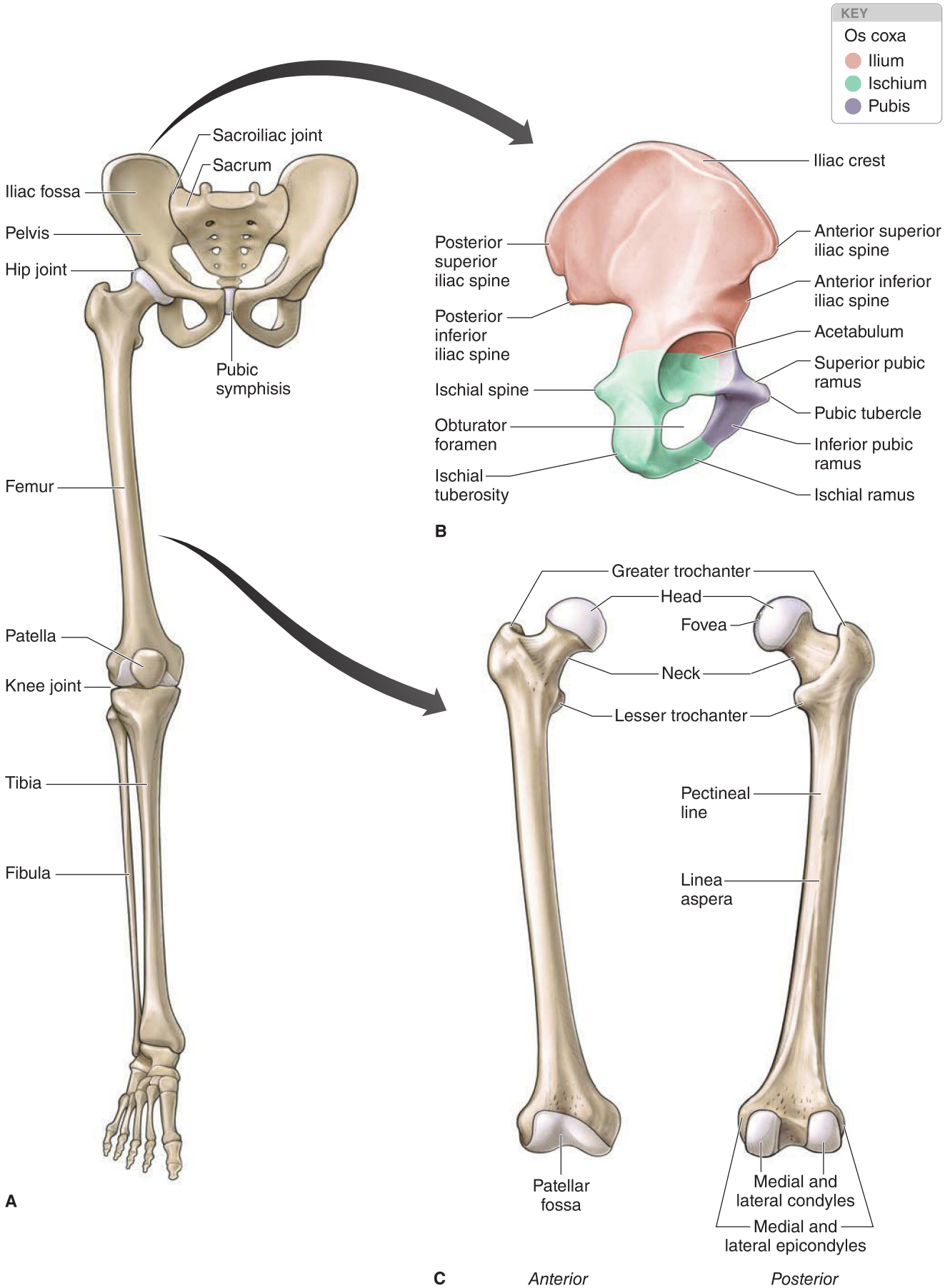

Figure 34-1: **A**. Skeleton of the lower limb. **B**. Osteology of the os coxa (pelvic bone). **C**. Femur.

BONES OF THE LEG AND FOOT

BIG PICTURE

The bony structure of the leg and foot, from proximal to distal, consists of the tibia, fibula, 7 tarsals, 5 metatarsals, and 14 phalanges (Figure 34-2A). The tibia and fibula are bound together by a tough, fibrous sheath known as the interosseous membrane.

TIBIA

The tibia is the medial and larger of the two bones of the leg and is the only bone that articulates with the femur at the knee joint (Figure 34-2A and B). The following landmarks are found on the tibia:

- **Medial and lateral condyles.** Lie on the proximal aspect of the tibia and articulate with the condyles of the femur.
- **Intercondylar eminence.** Lies between the articular surfaces of the medial and lateral condyles; attachment site for the anterior and posterior cruciate ligaments.
- **Tibial tuberosity.** Palpable on the proximal and anterior part of the tibia; attachment for the patellar ligament/ligament.
- **Anterior border.** A sharp and palpable ridge on the anterior surface of the tibia that descends from the tibial tuberosity, down the tibial shaft.
- **Interosseous border.** A vertical ridge that serves as attachment site for the interosseous membrane between the tibia and the fibula.
- **Medial malleolus.** Prominence on the medial side of the ankle; along with the lateral malleolus forms a mortis joint with the talus.

FIBULA

The fibula is lateral to the tibia and has limited involvement in weight-bearing activity. The fibular shaft is much narrower than the shaft of the tibia and is mainly surrounded by muscles (Figure 34-2A and B). The following landmarks are found on the fibula:

- **Head.** The most proximal aspect of the fibula.
- **Neck.** Separates the head from the fibular shaft; location of the common fibular nerve.
- **Interosseous border.** Attachment site for the interosseous membrane between the fibula and tibia.
- **Lateral malleolus.** Prominence on the lateral side of the ankle; along with the medial malleolus forms a mortis joint with the talus.

FOOT

The foot is subdivided into three sections: tarsus (ankle), metatarsus, and digits. There are five digits in the foot, beginning medially with the great toe and four lateral digits (Figure 34-2A and C). The three groups of bones that comprise the foot are the tarsals, metatarsals, and phalanges.

- **Tarsal bones.** The seven tarsal bones of the foot.
  - **Talus.** The most superior bone of the foot; sits on top of the calcaneus bone; articulates with the medial and lateral malleoli to form the mortis ankle joint.
  - **Calcaneus.** The largest of the tarsal bones and forms the heel posteriorly; attachment site for the calcaneal (Achilles) tendon and sustentaculum tali (attachment site for the spring ligament).
  - **Navicular bone.** Articulates with the talus bone posteriorly and with the cuneiform bones anteriorly; not a commonly broken bone in the foot.
  - **Medial, intermediate, and lateral cuneiform bones.** Articulate with the navicular bone and the three medial metatarsal bones.
  - **Cuboid bone.** Articulates with the calcaneus bone and with the two most lateral metatarsal bones.
- **Metatarsal bones.** There are five metatarsal bones in the foot, numbered one through five, from medial to lateral. The first metatarsal is associated with the great toe and is the shortest and the thickest bone; the second metatarsal is the longest bone. Each metatarsal has a head at the distal end, a base at the proximal end, and a shaft between the head and the base.
- **Phalanges.** The phalanges are the very short bones of the digits. Each digit, except the great toe, has three phalanges (the great toe has only two phalanges). The phalanges are named by location as proximal, middle, and distal for the lateral four digits, and only proximal and distal for the great toe. Each phalange has a base (proximal), a shaft, and a head (distal).

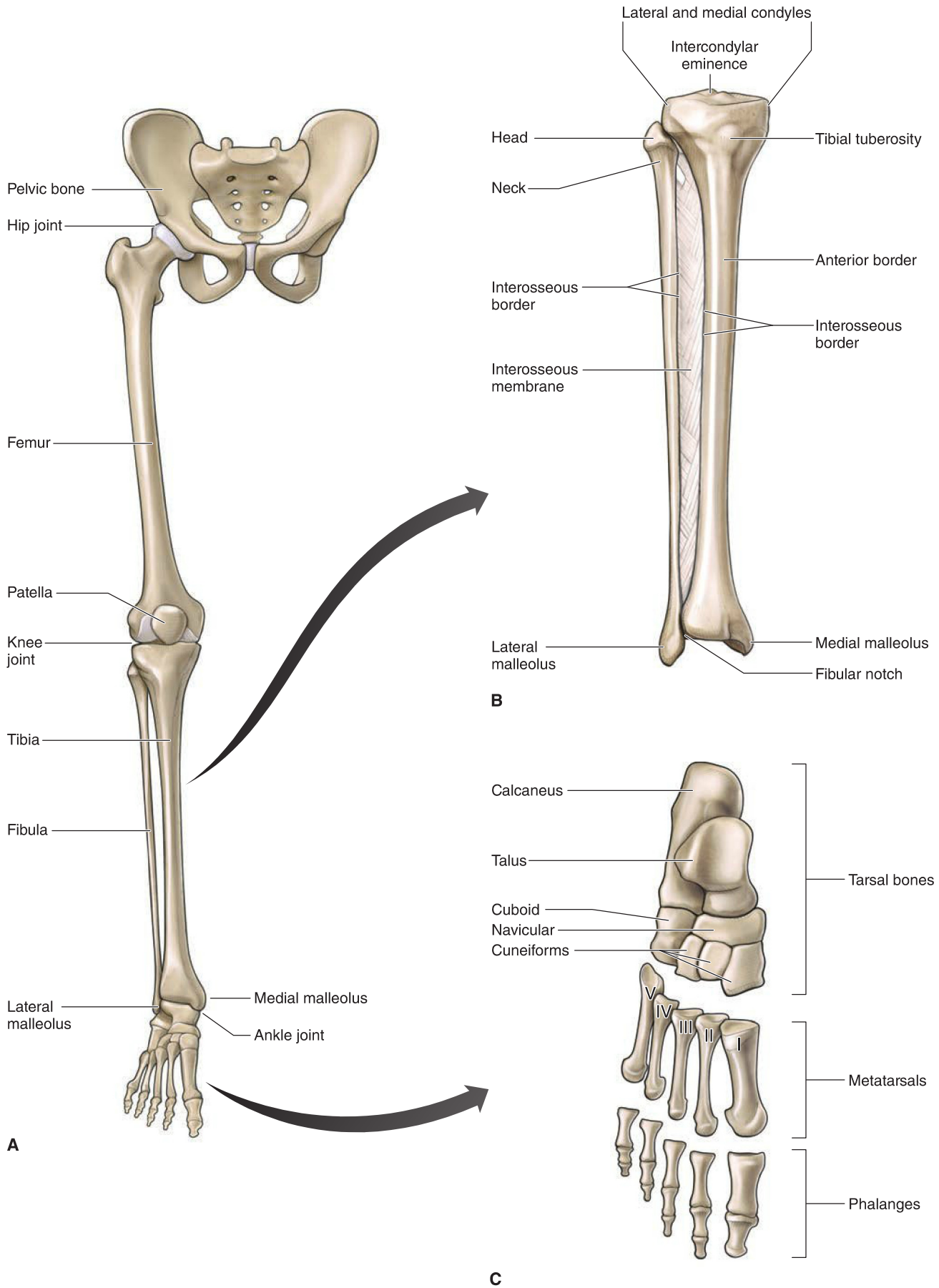

Figure 34-2: **A**. Skeleton of the lower limb. **B**. Tibia and fibula. **C**. Osteology of the foot.

FASCIAL PLANES AND MUSCLES

BIG PICTURE

The superficial fascia of the lower limb contains the superficial cutaneous nerves and veins. The deep fascia divides the lower limb into anterior, medial, and posterior compartments of the thigh (fascia lata) and anterior, lateral, and posterior compartments of the leg (crural fascia). Muscles within these compartments possess common attachments, innervation, and actions.

FASCIA OF THE LOWER LIMB

The lower limb consists of superficial and deep fascia (Figure 34-3A and B).

- **Superficial fascia.** Referred to as the subcutaneous or hypodermis, primarily contains fat and superficial veins (i.e., greater and small saphenous veins), lymphatics, and cutaneous nerves.
- **Deep fascia.** Develops intermuscular septae that extend to the bones, dividing the thigh and leg into three compartments. Each compartment contains muscles that perform similar movements and have a common innervation.

MUSCLES OF THE LOWER LIMB

The muscles of the lower limb are organized into the following groups:

- **Gluteal muscles.** The muscles of the gluteal region primarily act on the hip joint, producing extension, medial rotation, lateral rotation, and abduction. In addition to producing motion, the muscles of the gluteal region are important for stability of the trunk and hip joint and for locomotion. These muscles consist of the gluteus maximus, gluteus medius, gluteus minimus, piriformis, superior gemellus, inferior gemellus, obturator internus, quadratus femoris, and tensor fascia lata muscles.
- **Thigh muscles.** The deep fascia divides the thigh into anterior, medial, and posterior compartments with common attachments, actions, and innervation (Figure 34-3A).
  - **Muscles of the anterior compartment of the thigh.** Consist primarily of the sartorius and quadriceps femoris muscle group (rectus femoris, vastus lateralis, vastus medialis, and vastus intermedius muscles). Many of these muscles attach to the tibial tuberosity, extend the knee, and are innervated by the femoral nerve.
  - **Muscles of the medial compartment of the thigh.** Consist of the pectineus, adductor longus, adductor magnus, adductor brevis, gracilis, and obturator externus muscles. Many of these muscles attach to the linea aspera, adduct the hip, and are innervated by the obturator nerve.
  - **Muscles of the posterior compartment of the thigh.** Consist of the hamstring group of muscles, which consists of the semitendinosus, semimembranosus, and biceps femoris muscles. Many of the muscles attach to the ischial tuberosity, extend the hip and flex the knee, and are innervated by the tibial nerve.
- **Leg muscles.** The deep fascia divides the leg into anterior, lateral, and posterior compartments with common attachments, actions, and innervation (Figure 34-3B).
  - **Muscles of the anterior compartment of the leg.** Consist of the tibialis anterior, extensor hallucis longus, and fibularis tertius muscles. Most of these muscles dorsiflex the ankle and extend the digits, and are innervated by the deep fibular nerve.
  - **Muscles of the posterior compartment of the leg.** Consist of the gastrocnemius, plantaris, soleus, popliteus, flexor hallucis longus, flexor digitorum longus, and tibialis posterior muscles. Most of these muscles plantar flex the ankle and flexion of the digits and are innervated by the tibial nerve.
  - **Muscles of the lateral compartment of the leg.** Consist of the fibularis (peroneus) longus and fibularis (peroneus) brevis muscles. These muscles attach to the fibular, plantar flex and evert the ankle and are innervated by the superficial peroneal (fibular) nerve.
- **Foot muscles.** There are four layers of intrinsic muscles of the foot.
  - **Layer 1.** The abductor digiti minimi, flexor digitorum brevis, and abductor hallucis muscles.
  - **Layer 2.** The lumbricals and the quadratus plantae muscles.
  - **Layer 3.** The flexor digiti minimi, flexor hallucis brevis, and adductor hallucis muscles.
  - **Layer 4.** The plantar and dorsal interossei muscles.

The extensor digitorum brevis and extensor hallucis brevis muscles are the only two intrinsic muscles on the dorsum of the foot.

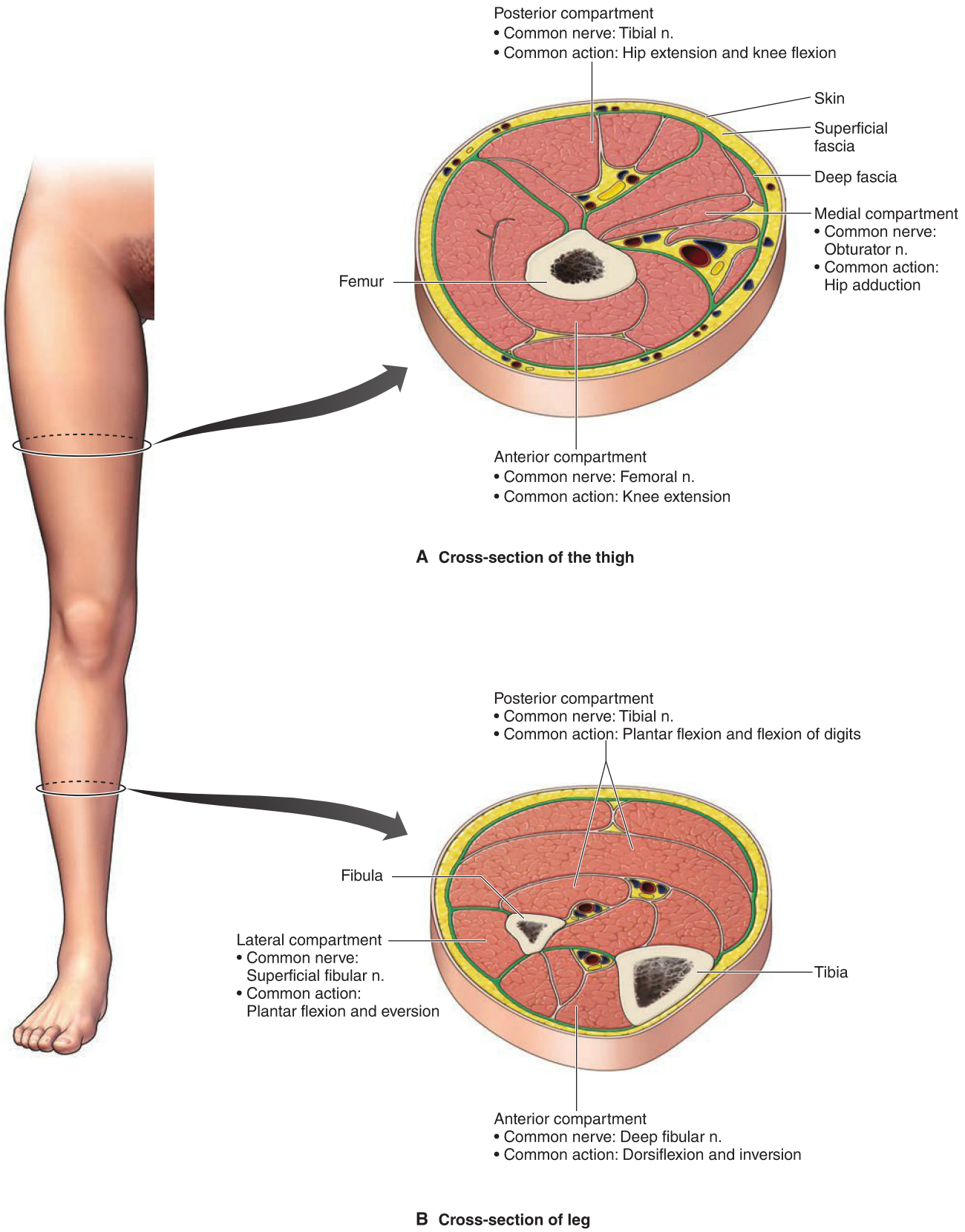

Figure 34-3: Cross-section of the thigh (**A**) and leg (**B**) for a superior view.

INNERVATION OF THE LOWER LIMB

BIG PICTURE

The lower limb receives sensory and motor innervation from L1–S4 ventral rami via the lumbar plexus (L1–L4) and sacral plexuses (L4–S4) (Figure 34-4).

LUMBAR PLEXUS

The lumbar plexus originates from ventral rami of L1–L4. It provides motor and sensory contributions to the anterior and medial compartments of the leg as well as to the abdominal wall and pelvic areas via the following branches:

- **Lateral cutaneous nerve of the thigh (L2–L3).** Provides sensory innervation to the skin over the lateral region of the thigh; also referred to as the lateral femoral cutaneous nerve or "Lat-Fem-Q" for short.
- **Femoral nerve (L2–L4).** Provides innervation to the following:
  - **Motor.** Anterior compartment muscles of the thigh: Sartorius muscle, Qaudriceps femoris muscle group (rectus femoris, vastus lateralis, vastus intermedius, vastus medialis), and pectineus muscle. Also innervates the iliacus muscle.
  - **Sensory.** Cutaneous to the anterior thigh (anterior cutaneous nerve of the thigh) and medial leg (saphenous nerve).
- **Obturator nerve (L2–L4).** Provides innervation to the following:
  - **Motor.** Medial compartment muscles of the thigh: obturator externus, adductor brevis, adductor longus, adductor magnus and gracilis muscles.
  - **Sensory.** Medial thigh via the cutaneous branch of obturator nerve.

SACRAL PLEXUS

The sacral plexus (L4–S4) innervates the posterior compartment of the thigh, and the entire leg, and foot by way of the following nerves:

- **Posterior cutaneous nerve of thigh (posterior femoral cutaneous nerve) (S1–S3).** Provides sensory innervation to the posterior region of the thigh.
- **Nerve to the piriformis muscle (S1–S2).** Provides motor innervation to the piriformis muscle.
- **Nerve to the superior gemellus and obturator internus muscles (L5–S2).** Provides motor innervation to the superior gemellus muscle and obturator internus muscles.
- **Nerve to the inferior gemellus and quadratus femoris muscles (L4–S1).** Provides motor innervation to the inferior gemellus and quadratus femoris muscles.
- **Tibial nerve (L4–S3).** Provides innervation to the following:
  - **Motor.** Posterior compartment muscles of the thigh (long head of biceps femoris [not short head], semitendinosus, semimembranosus and hamstring division of the adductor magnus muscles), posterior compartment muscles of the leg (gastrocnemius, soleus, plantaris, tibialis posterior, flexor hallucis longus, flexor digitorum longus and popliteus muscles), and plantar muscles of the foot.
  - **Sensory.** Posterolateral region of the leg and plantar surface of the foot.
- **Perforating cutaneous nerve (S2–S3).** Provides sensory innervation to the skin over the inferior aspect of the gluteus maximus muscle (inferior gluteal fold).
- **Superior gluteal nerve (L4–S1).** Provides motor innervation to the gluteus medius, gluteus minimus, and tensor fascia latae muscles.
- **Inferior gluteal nerve (L5–S2).** Provides motor innervation to the gluteus maximus muscle.
- **Common fibular (peroneal) nerve (L4–S2).** Provides motor innervation to the short head of the biceps femoris muscle and sensory innervation to the posterolateral leg. Gives rise to the following branches:
- **Superficial fibular nerve.** Provides innervation to the following:
  - **Motor.** Lateral compartment muscles of the leg (peroneus longus and peroneus brevis muscles).
  - **Sensory.** Anterior leg and dorsum of foot.
- **Deep fibular nerve.** Provides innervation to the following:
  - **Motor.** Anterior compartment muscles of the leg (tibialis anterior, extensor hallucis longus, extensor digitorum longus and peroneus tertius muscles).
  - **Sensory.** Skin between the first and second toe on dorsum of foot.

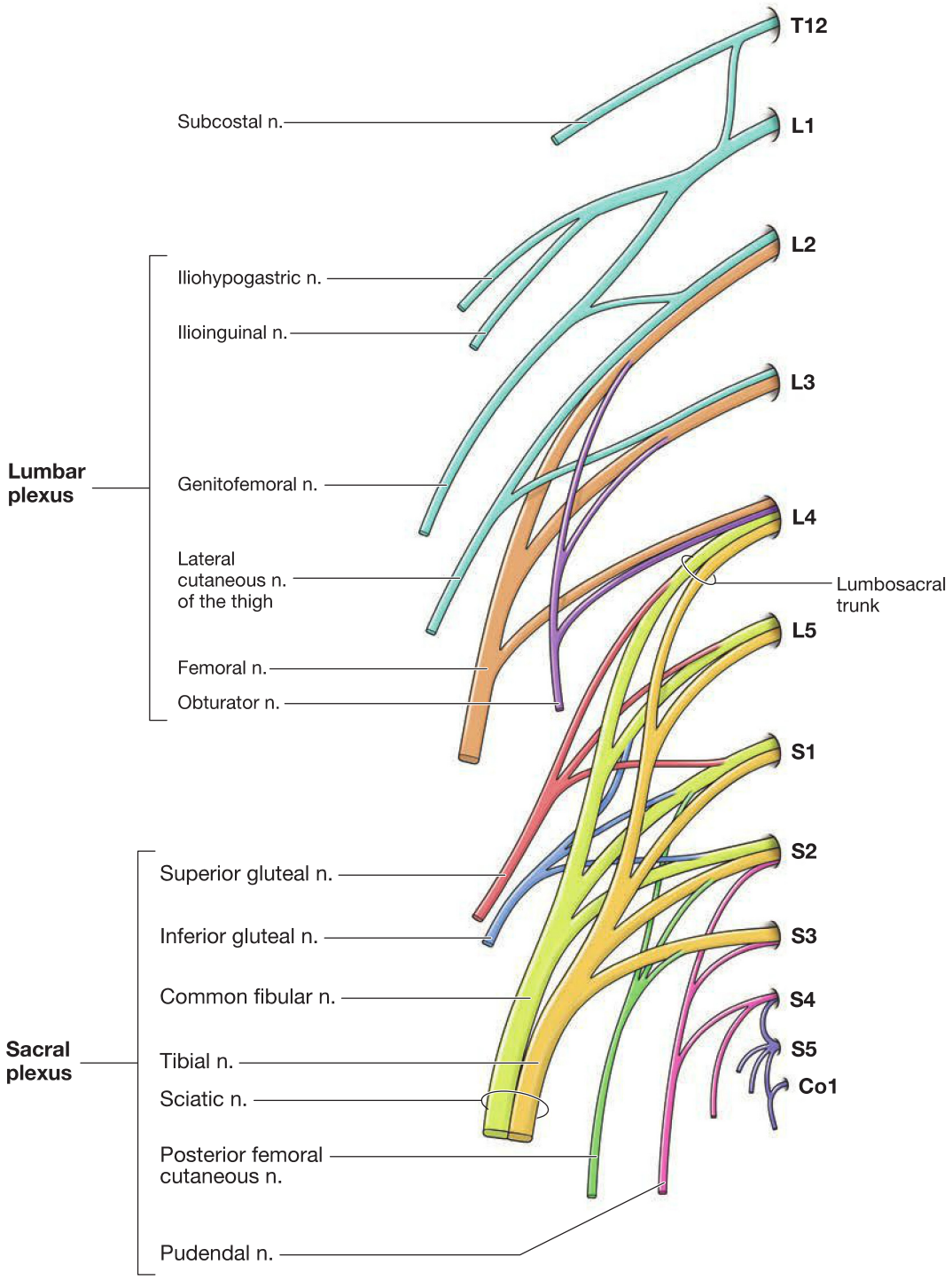

Figure 34-4: Lumbosacral plexus.

SENSATION OF THE LOWER LIMB

BIG PICTURE

The lumbar and sacral plexuses provide the pathways for sensory neurons from the skin of the lower limb to the spinal cord. Sensory innervation of the lower limb is characterized in two ways: dermatomes and cutaneous fields. A dermatome is a region of skin that is innervated by one spinal nerve level. In contrast, a cutaneous nerve provides sensory innervation from a region of skin and may consist of sensory neurons from more than one spinal nerve level.

DERMATOMES (LOWER LIMB)

A dermatome is a region of skin that is innervated by one spinal nerve level (Figure 34-5A). Therefore, all sensory neurons leaving that region of skin course to the same segmental spinal nerve level. The following are the primary places to touch in order to test specific dermatomes in the upper limb:

- **L1.** Skin overlying the inguinal region.
- **L3.** Medial femoral condyle above the knee.
- **L4.** Over the medial malleolus.
- **L5.** Dorsum of the foot over the third metatarsal phalangeal joint.
- **S1.** Lateral aspect of the calcaneus (heel).
- **S2.** Midpoint of the popliteal fossa.

CUTANEOUS NERVES (LOWER LIMB)

Cutaneous nerves are responsible for providing sensory innervation to a specific region of skin (often referred to as a "cutaneous field") (Figure 34-5B). The principal cutaneous nerves of the upper limb are as follows:

- **Lateral cutaneous nerve of the thigh** (lumbar plexus branch).
- **Anterior cutaneous nerve of the thigh** (femoral nerve branch).
- **Cutaneous branch of the obturator nerve** (obturator nerve branch).
- **Posterior cutaneous nerve of the thigh** (sacral plexus branch).
- **Saphenous nerve** (femoral nerve branch).
- **Cutaneous branch of the superficial fibular nerve.**
- **Lateral sural nerve** (common fibular nerve branch).
- **Medial sural nerve** (tibial nerve branch).
- **Cutaneous branch of the deep fibular nerve.**
- **Medial and lateral plantar nerves** (tibial nerve branches).

Cutaneous nerves are considered "sensory-only" but it should be remembered that they also distribute sympathetic nerves to cutaneous organs like sweat glands.

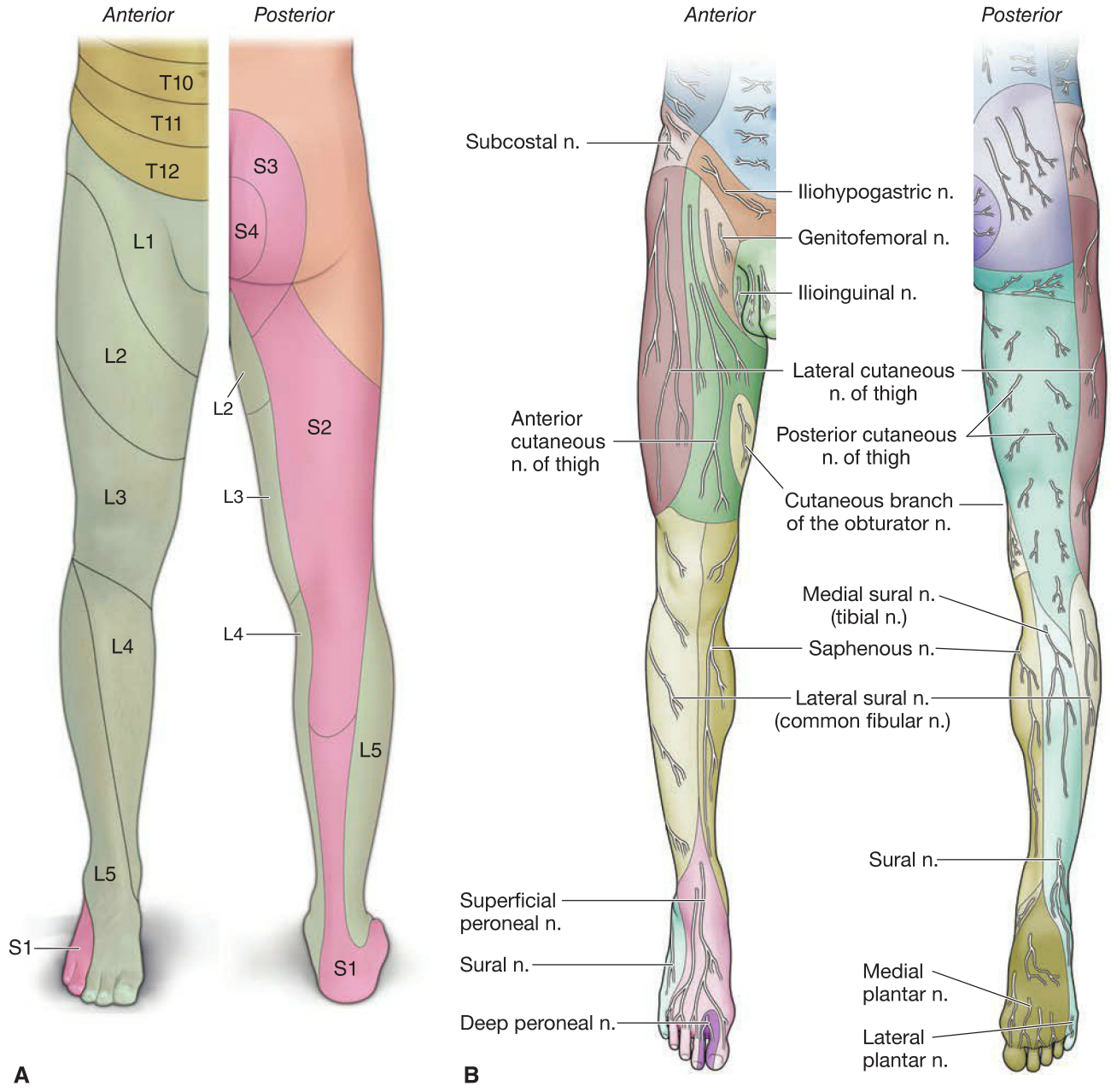

Figure 34-5: Dermatomal (**A**) and cutaneous (**B**) innervation of the lower limb.

VASCULARIZATION OF THE LOWER LIMB

BIG PICTURE

The common iliac artery provides blood supply to both lower limbs. Each iliac artery bifurcates into an external and an internal iliac artery. The internal iliac artery primarily supplies blood to the pelvic and gluteal regions, whereas the external iliac supplies blood to the remainder of the lower limbs. Blood is returned to the heart via a superficial and a deep venous system.

ARTERIES OF THE LOWER LIMB

The common iliac artery bifurcates into the internal and external iliac arteries (Figure 34-6A).

- **Internal iliac artery.** Gives rise to the obturator artery and to the superior and inferior gluteal arteries.
- **External iliac artery.** Becomes the femoral artery as it passes the inguinal ligament and enters the thigh. The femoral artery gives rise to the deep artery of the thigh and continues distally to become the popliteal artery behind the knee joint. The popliteal artery bifurcates into the anterior and posterior tibial arteries, which travel distally into the leg. These arteries continue into the dorsal and plantar surfaces of the foot. Smaller vessels throughout the lower limb branch from the larger vessels to supply muscle, bone, and joints.

VEINS OF THE LOWER LIMB

Generally, the superficial and deep venous system of the lower limb drains into the internal and external iliac veins before reaching the inferior vena cava. The deep veins follow the arteries and usually consist of two or more veins that wrap around the accompanying artery (vena comitantes). The superficial veins originate in the foot and primarily consist of the great and small saphenous veins.

- **Great saphenous vein.** Originates along the great toe (digit 1) from the **dorsal venous arch**. The great saphenous vein courses anterior to the medial malleolus and travels along the medial side of the lower limb, medial to the medial epicondyle of the femur. It traverses an opening, called the **saphenous opening**, in the fascia lata and drains into the **femoral vein** (Figure 34-6B).
- **Small saphenous vein.** Travels along the lateral foot and ascends the posterior region of the leg to drain into the popliteal vein.

▽ **Coronary arterial bypass graft (CABG).** A type of surgery performed when blood must be rerouted or bypassed around a clogged coronary artery. The surgeon removes a segment of a healthy vessel from another part of the body to serve as the bypass. The great saphenous vein of the thigh is a source of a graft in which one end of the vein is grafted above the blocked area (often to the aortic arch) and the other end is grafted below the blocked area. Thus, the great saphenous vein "detours" blood, "bypassing" the blocked part of the coronary artery, and supplies the myocardium distal to the blocked artery. ▼

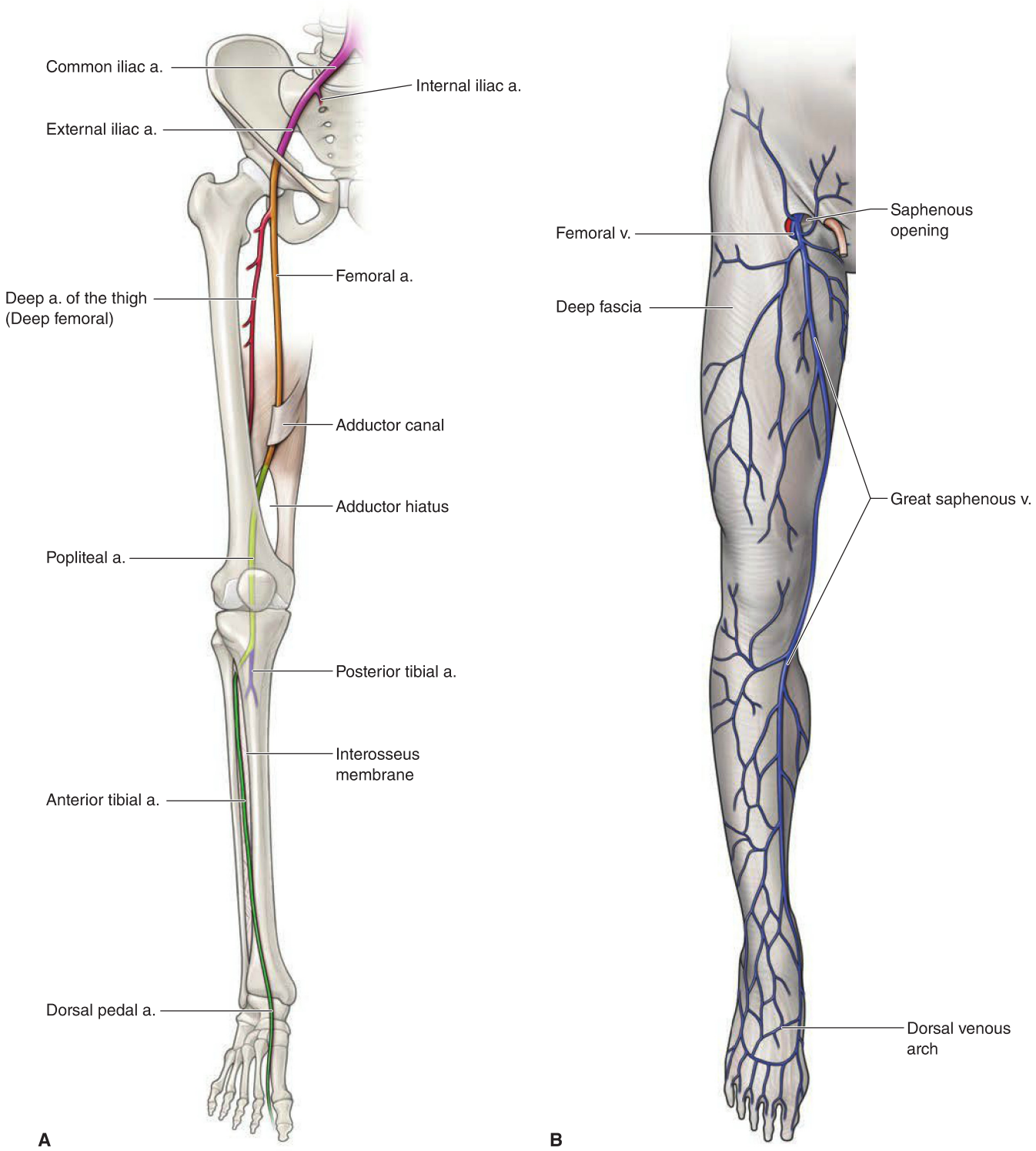

Figure 34-6: **A**. Arterial supply of the lower limb. **B**. Superficial veins of the lower limb.

This page intentionally left blank

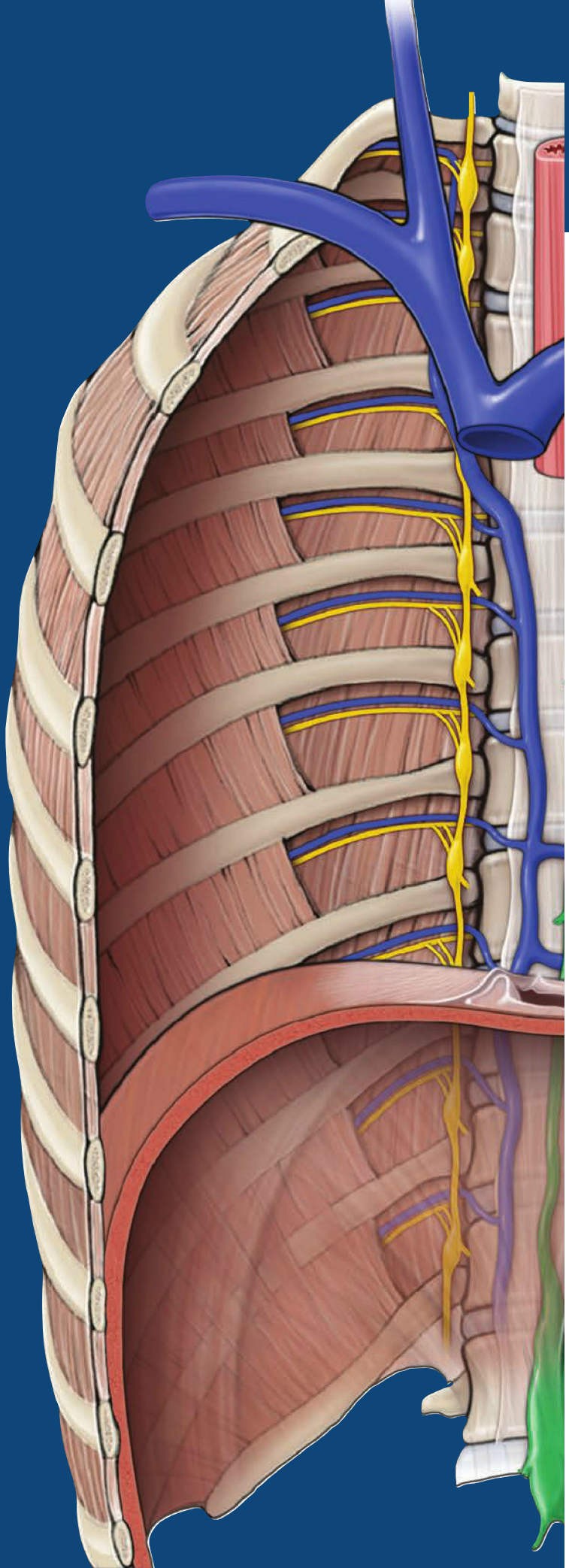

CHAPTER 35

GLUTEAL REGION AND HIP

Gluteal Region 390
Muscles of the Gluteal Region 390
Sacral Plexus 392
Vascularization of the Gluteal Region 394
Joints of the Gluteal Region 394

GLUTEAL REGION

BIG PICTURE

The bony component of the gluteal (buttocks) region consists of two pelvic bones (os coxae) joined anteriorly by the symphysis pubis and posteriorly by the sacrum. Each os coxa is composed of three fused bones: ilium, ischium, and pubis. The bones of the gluteal region contain foramina (notches), which serve as conduits for nerves and blood vessels that travel between the pelvis, gluteal region, perineum, and lower limb. Muscles of the gluteal region primarily act on the hip joint.

ACTIONS OF THE HIP JOINT

The hip joint is a synovial, ball-and-socket joint. The "ball" is the head of the femur, and the "socket" is the acetabulum of the pelvic bone. The motions of the hip joint are as follows (Figure 35-1A):

- **Flexion.** Movement anterior in the sagittal plane.
- **Extension.** Movement posterior in the sagittal plane.
- **Abduction.** Movement away from the midline in the frontal plane.
- **Adduction.** Movement toward the midline in the frontal plane.
- **Internal (medial) rotation.** Movement toward the midline in the transverse or axial plane.
- **External (lateral) rotation.** Movement away from the midline in the transverse or axial plane.
- **Circumduction.** A combination of hip joint motions that produces a circular motion.

MUSCLES OF THE GLUTEAL REGION

BIG PICTURE

The muscles of the gluteal region primarily act on the hip joint, producing extension, medial rotation, lateral rotation, and abduction (Table 35-1). In addition to producing motion, the muscles of the gluteal region are important for stability of the hip joint as well as for locomotion.

GLUTEAL MUSCLES (FIGURE 35-1B)

- **Gluteus maximus muscle.** The largest and most superficial gluteal muscle.
  - **Attachments.** Proximal attachments are the ilium, sacrum, coccyx, and sacrotuberous ligament. Distal attachments are the iliotibial tract and gluteal tuberosity of the femur.
  - **Actions.** Powerful extensor of the flexed femur (i.e., climbing stairs), maintains posture and is a lateral stabilizer of the hip joint.
  - **Innervation.** Inferior gluteal nerve (L5–S2).
- **Gluteus medius and minimus muscles.** The intermediate and deepest gluteal muscles.
  - **Attachments.** Ilium and greater trochanter of the femur.
  - **Actions.** Abduction and medial rotation of the hip joint. An additional action aids in stabilizing the pelvis. When standing, our weight is balanced over our two feet. However, when the right foot is lifted off the ground (i.e., taking a step while walking) the pelvis should dip on the right side. However, this does not occur because contraction of the gluteus medius and minimus on the left side pull downward on the left side of the pelvis and thus prevent the pelvis from dipping on the right.
  - **Innervation.** Superior gluteal nerve (L4–S1).
- **Tensor fascia lata muscle.** A laterally located fusiform-shaped muscle within the fascia lata.
  - **Attachments.** Proximal attachment is the lateral aspect of the iliac crest. Distal attachments are the iliotibial tract of fascia and the lateral condyle of the tibia.
  - **Actions.** Hip abduction; aids in maintaining knee extension and stabilization.
  - **Innervation.** Superior gluteal nerve (L4–S1).

DEEP HIP ROTATOR MUSCLES

The deep hip rotator muscles all have several common characteristics—they are deep to the gluteal muscles, they arise from the pelvis, they share common attachments around the greater trochanter of the femur, and they externally (laterally) rotate the femur at the hip joint. The deep hip rotator muscles are as follows (Figure 35-1C):

- **Piriformis muscle.** Attaches to the anterior surface of the sacrum and greater trochanter and is innervated by the nerve to the piriformis muscle (S1–S2).
- **Superior gemellus muscle.** Attaches to the ischial spine and greater trochanter; innervated by the nerve to the obturator internus and superior gemellus muscles (L5–S2).
- **Obturator internus muscle.** Attaches to the deep surface of the obturator membrane and surrounding bone and greater trochanter; innervated by nerve to the obturator internus and superior gemellus muscles (L5–S2).
- **Inferior gemellus muscle.** Attaches to the ischial tuberosity and greater trochanter; innervated by the nerve to the inferior gemellus and quadratus femoris muscles (L4–S1).
- **Quadratus femoris muscle.** Attaches to the lateral aspect of the ischium and the intertrochanteric crest; innervated by the nerve to the inferior gemellus and quadratus femoris muscles (L4–S1).

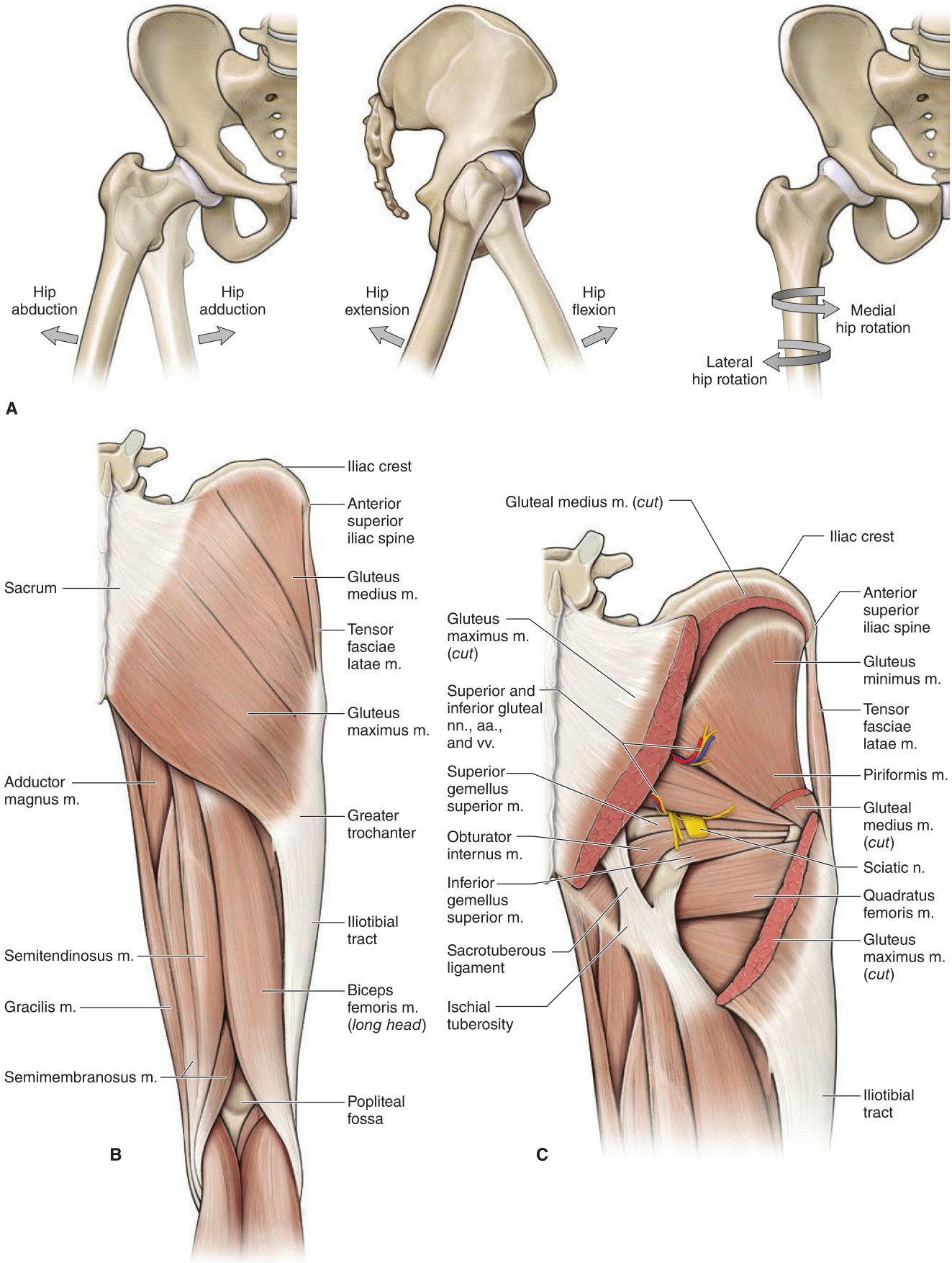

Figure 35-1: A. Actions of the hip joint. The right gluteal region illustrating the posterior view of the superficial gluteal muscles (**B**) and the deep gluteal muscles (**C**).

SACRAL PLEXUS

BIG PICTURE

The lower limb is innervated by the ventral rami from nerve roots L1–S4, which form two separate networks of nerves and are referred to as the lumbar plexus (L1–L4) and the sacral plexus (L4–S4). The lumbar plexus communicates with the sacral plexus via the lumbosacral trunk (L4, L5), which descends into the pelvic cavity to contribute to the sacral plexus. Most of the sacral plexus is divided into anterior and posterior divisions. The anterior division provides the primary motor innervation to the posterior compartment of the thigh and leg. The posterior division provides the primary motor innervation to the anterior and lateral compartments of the leg.

ANTERIOR DIVISION OF THE SACRAL PLEXUS

The anterior division of the sacral plexus consists of ventral rami from L4 to S4, which form a network and give rise to the following five nerves (Figure 35-2A and B):

- **Pudendal nerve (S2–S4).** Exits the pelvis via the greater sciatic foramen, enters the gluteal region, and courses to the perineum through the lesser sciatic foramen. The pudendal nerve provides motor innervation to the muscles of the pelvic floor and sensory innervation to the skin of the perineum.
- **Posterior femoral cutaneous nerve (S1–S3).** Exits the pelvis via the greater sciatic foramen, inferior to the piriformis muscle. The posterior femoral cutaneous nerve receives half of its innervation levels (S1 and S2) from the posterior division of the sacral plexus and the other half (S2 and S3) from the anterior division. The nerve remains deep to the gluteal maximus muscle and emerges at the inferior border, providing sensory innervation to the posterior region of the thigh. Also called the Posterior cutaneous nerve of the thigh.
- **Nerve to the superior gemellus and obturator internus muscles (L5–S2).** Exits the pelvis via the greater sciatic foramen, inferior to the piriformis muscle, and innervates the superior gemellus and obturator internus muscles.
- **Nerve to the inferior gemellus and quadratus femoris muscles (L4–S1).** Exits the pelvis via the greater sciatic foramen, inferior to the piriformis, and innervates the inferior gemellus and quadratus femoris muscles.
- **Tibial nerve (L4–S3).** The tibial nerve (a division of the sciatic nerve) exits the pelvis via the greater sciatic foramen to enter the gluteal region inferior to the piriformis muscle. The nerve descends along the posterior aspect of the thigh, providing motor innervation to the hamstring muscles (excluding the short head of the biceps femoris muscle) and a hamstring head of the adductor magnus muscle in the medial compartment of the thigh. The tibial nerve descends through the popliteal fossa and enters the posterior compartment of the leg, deep to the gastrocnemius and soleus muscles. It provides motor innervation to the posterior compartment of the leg as well as to the plantar muscles of the foot. Sensory branches provide cutaneous innervation to the posterolateral region of the leg and the lateral region of the foot.

POSTERIOR DIVISION OF THE SACRAL PLEXUS

The posterior division of the sacral plexus consists of ventral rami from L4 to S3, which form a network and give rise to the following six nerves (Figure 35-2A and B):

- **Perforating cutaneous nerve (S2–S3).** Pierces the sacrotuberous ligament and travels to the inferior edge of the gluteus maximus muscle, providing sensory innervation to the skin over the inferior aspect of the gluteus maximus (inferior gluteal fold).
- **Nerve to piriformis muscle (S1–S2).** Travels directly from the plexus to the piriformis muscle, providing motor innervation without leaving the pelvic cavity.
- **Superior gluteal nerve (L4–S1).** Exits the pelvis via the greater sciatic foramen and travels superior to the piriformis muscle and innervates the gluteus medius, gluteus minimus, and tensor fascia latae muscles.
- **Inferior gluteal nerve (L5–S2).** Exits the pelvis via the greater sciatic foramen and travels inferior to the piriformis to innervate the gluteus maximus muscle.
- **Common fibular (peroneal) nerve (L4–S2).** Exits the pelvis via the greater sciatic foramen inferior to the piriformis muscle. The nerve descends along the posterior aspect of the thigh, providing motor innervation to the short head of the biceps femoris muscle and sensory innervation to the superior lateral leg (lateral sural nerve). The common fibular nerve descends into the popliteal fossa and curves laterally around the neck of the fibula and bifurcates into the following nerves:
  - **Superficial fibular nerve.** Provides motor innervation to the lateral compartment of the leg (peroneus longus and brevis muscles) and sensory innervation to the anterolateral region of the leg and dorsum of the foot.
  - **Deep fibular nerve.** Provides motor innervation to the anterior compartment of the leg (tibialis anterior, extensor hallicus longus, extensor digitorum longus muscles) and sensory innervation to a small area between digits 1 and 2.

▽ The gluteal region is a common site for **intermuscular injections**. Specifically, the superior lateral portion of the gluteal region is the preferred site to avoid injuring structures such as the sciatic nerve. ▼

▽ **Trendelenburg sign.** During a physical exam a standing patient is asked to lift one leg off the ground. The pelvis should remain level due to the contraction of the gluteus medius and minimus muscles on the stance limb. The Trendelenburg sign is said to be positive if, when standing on one leg, the pelvis drops on the opposite side. The muscle weakness is present on the side of the stance limb. To compensate the patient may tilt his/her trunk towards the affected side, which raises the pelvis and compensates for this weakness. A Trendelenburg sign may be observed where there is muscular dysfunction (weakness of the gluteus medius or minimus) or when the superior gluteal nerve is injured. ▼

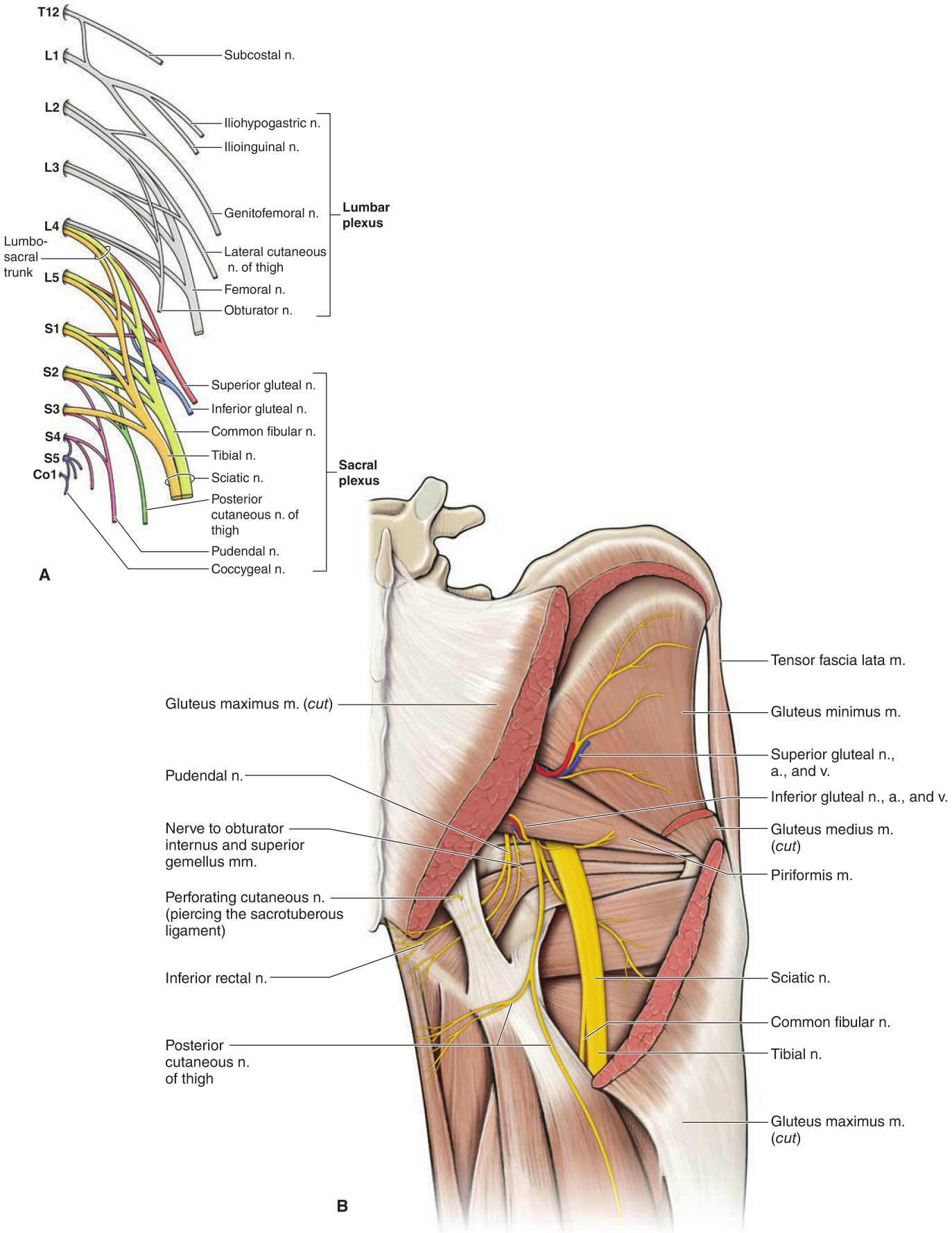

Figure 35-2: **A**. Schematic of the lumbosacral plexus. **B**. Neurovascular structures of the gluteal region.

VASCULARIZATION OF THE GLUTEAL REGION

BIG PICTURE

The common iliac artery bifurcates into the internal and external iliac arteries. The internal iliac artery is the major blood supply to the pelvis and gluteal region.

ARTERIES OF THE GLUTEAL REGION

- **Internal iliac artery.** The superior and inferior gluteal arteries branch from the internal iliac artery and travel with the superior and inferior gluteal nerves.
  - **Superior gluteal artery.** Travels between the lumbosacral trunk and S1 ventral ramus to exit the pelvis through the greater sciatic foramen. The superior gluteal artery supplies the muscles and skin in the gluteal region, including the tensor fascia latae muscle.
  - **Inferior gluteal artery.** The terminal branch of the internal iliac artery; travels between the S2 and S3 ventral rami and supplies the muscles of the gluteal region and forms anastomoses with blood vessels surrounding the hip joint.

JOINTS OF THE GLUTEAL REGION

BIG PICTURE

The hip joint is a synovial, ball-and-socket joint that allows for a great deal of freedom, including flexion and extension, abduction and adduction, medial and lateral rotation, and circumduction of the femur. The role of the hip joint is to provide support for the weight of the head, arms, and trunk during static postures (standing) and dynamic movements (walking and running). In addition to the hip joint, the gluteal region also contains the sacroiliac joint and the pubic symphysis, which connect the pelvic bones together as well as connecting the pelvic bones to the spine (i.e., the sacrum).

STRUCTURE OF THE HIP JOINT

The articulating surface of the **pelvic bone (os coxa)** is a concave socket that is composed of three fused bones, the ilium, ischium, and pubis, called the **acetabulum** (Figure 35-3A). The acetabulum is horseshoe-shaped fossa. The acetabulum articulates with the **head of the femur**. In addition, the hip joint has a wedge-shaped fibrocartilaginous ring around the periphery of the acetabulum (**acetabular labrum**), which increases stability by deepening the socket and increasing the concavity of the articulating surface. The wedge shape of the acetabular labrum also assists in maintaining contact of the acetabulum with the femoral head. The **medial circumflex femoral artery** provides the principal blood supply to the hip.

LIGAMENTOUS SUPPORT OF THE HIP JOINT

The following structures provide ligamentous support to the hip joint (Figure 35-3B):

- **Joint capsule.** Is strong and extends like a sleeve from the acetabulum to the base of the neck of the femur. The joint capsule possesses circular fibers, which form a ring around the neck of the femur, called the **zona orbicularis**. The capsule contains three capsular ligaments: two anterior ligaments and one posterior ligament. The ligaments of the hip primarily become taut with extension of the hip and permit little, if any, distraction between the articulating surfaces.
  - **Anterior ligaments**
    - **Iliofemoral ligament (Y ligament, or ligament of Bigelow).** A fan-shaped ligament that resembles an inverted "Y." The iliofemoral ligament extends from the anterior iliac spine and bifurcates to attach to the intertrochanteric line of the femur.
    - **Pubofemoral ligament.** Attaches from the anterior aspect of the pubic ramus and extends posteriorly to attach to the anterior surface of the intertrochanteric fossa.
  - **Posterior ligament**
    - **Ischiofemoral ligament.** Attaches from the superior acetabular rim and labrum to the inner surface of the greater trochanter.
- **Ligament of the head of the femur (ligamentum teres).** Attaches to the head of the femur (fovea). The ligament courses deep to the transverse acetabular ligament to attach to the acetabular notch. The ligament of the head of the femur does not appear to play a major role in stability of the hip joint, but rather serves as a conduit for the secondary arterial supply to the head of the femur from the **obturator artery**.
- **Transverse acetabular ligament.** Completes the circle of the acetabular labrum by spanning the acetabular notch and forming a foramen for the passage of the ligament of the head of the femur.

BURSAE

Bursae are synovial sacs filled with synovial fluid. They are found at areas in the tissue at which friction would otherwise develop. Bursae serve as small cushions because they decrease the friction between two moving structures, such as tendon and bone. The two most important bursae in the gluteal region are as follows:

- **Subtendinous iliac bursa.** Separates the iliacus and psoas major muscles from the anterior joint capsule.
- **Trochanteric bursa.** Separates the gluteus maximus muscle from the greater trochanter.

SACROILIAC JOINT

The sacroiliac joint is a plane synovial joint that connects the sacrum with the bilateral pelvic bones. This joint transmits forces from the vertebral column to the pelvic bones and lower limbs. The combination of strong ligaments and the irregular shape of the articulating surfaces increases the stability of the sacroiliac joint. In some individuals this joint may be fused, and in others it will allow minimal movement.

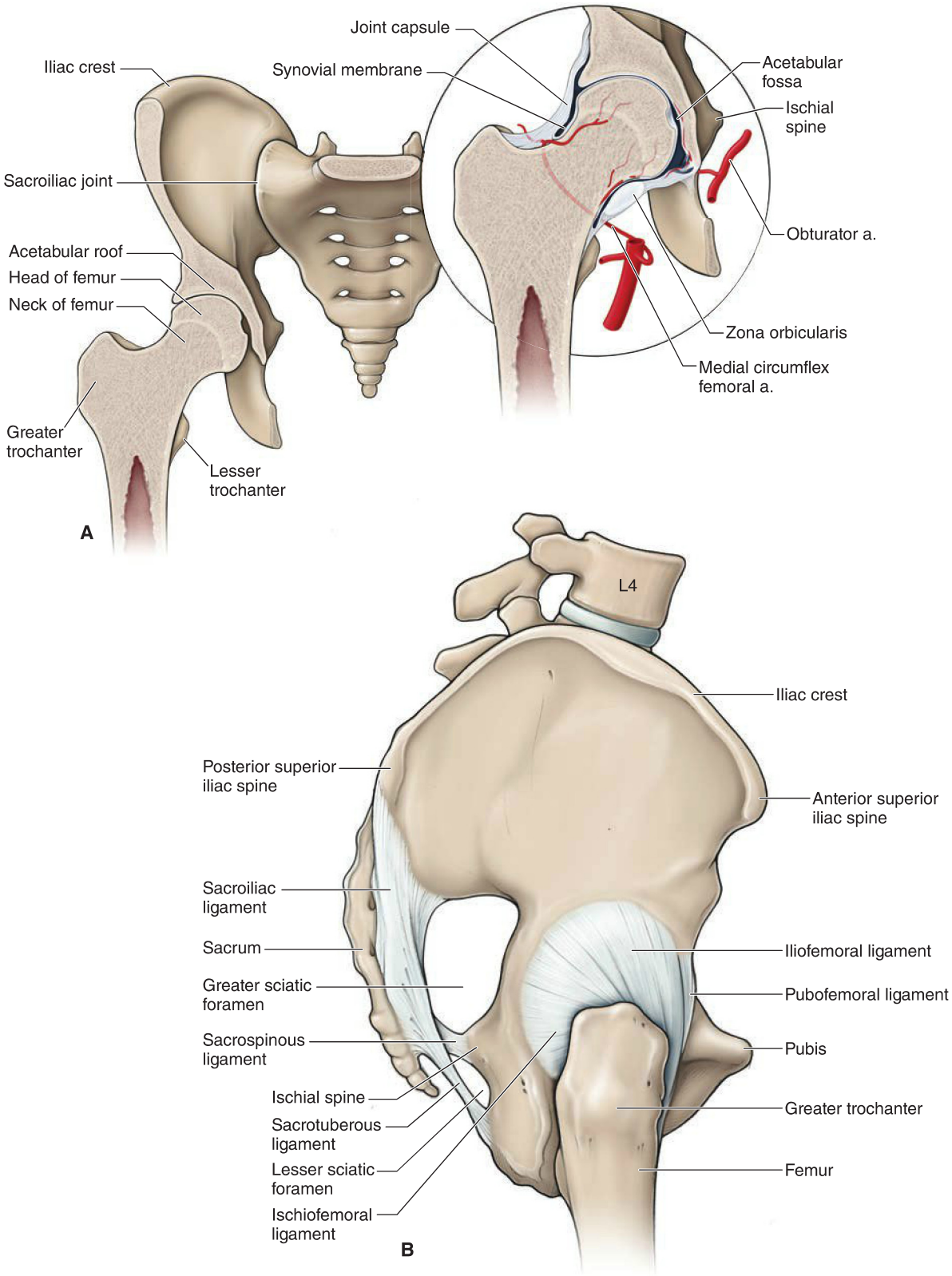

Figure 35-3: **A**. Structure of the hip joint. **B**. The right hip illustrating the lateral view of the ligaments of the hip joint.

TABLE 35-1. Muscles of the Gluteal Region

Muscle	Proximal Attachment	Distal Attachment	Action	Innervation
Gluteal region				
Tensor fascia lata	Lateral aspect of crest of ilium between anterior superior iliac spine and tubercle of crest	Iliotibial tract of fascia lata	Stabilizes knee in extension	Superior gluteal n. (L4–S1)
Gluteus maximus	Ilium behind posterior gluteal line, sacrum, coccyx, and sacrotuberous ligament	Iliotibial tract and gluteal tuberosity of femur	Powerful extensor of flexed femur at hip joint; lateral stabilizer of hip and knee joints	Inferior gluteal n. (L5–S2)
Gluteus medius	Ilium between anterior and posterior gluteal lines	Greater trochanter	Abducts femur at hip joint; holds pelvis secure over stance leg and prevents pelvic drop on opposite swing side during walking; hip internal rotation	Superior gluteal n. (L4–S1)
Gluteus minimus	Ilium between anterior and inferior gluteal lines			
Piriformis	Anterior surface of sacrum	Greater trochanter	Laterally rotates the hip joint	Nerve to piriformis m. (S1–S2)
Superior gemellus	Ischial spine			Nerve to obturator internus and superior gemellus mm. (L5–S2)
Obturator internus	Deep surface of obturator membrane and surrounding bone			
Inferior gemellus	Ischial tuberosity			
Quadratus femoris	Lateral aspect of ischium just anterior to ischial tuberosity	Intertrochanteric crest		Nerve to inferior gemellus and quadratus femoris mm. (L4–S1 for parallel construction)

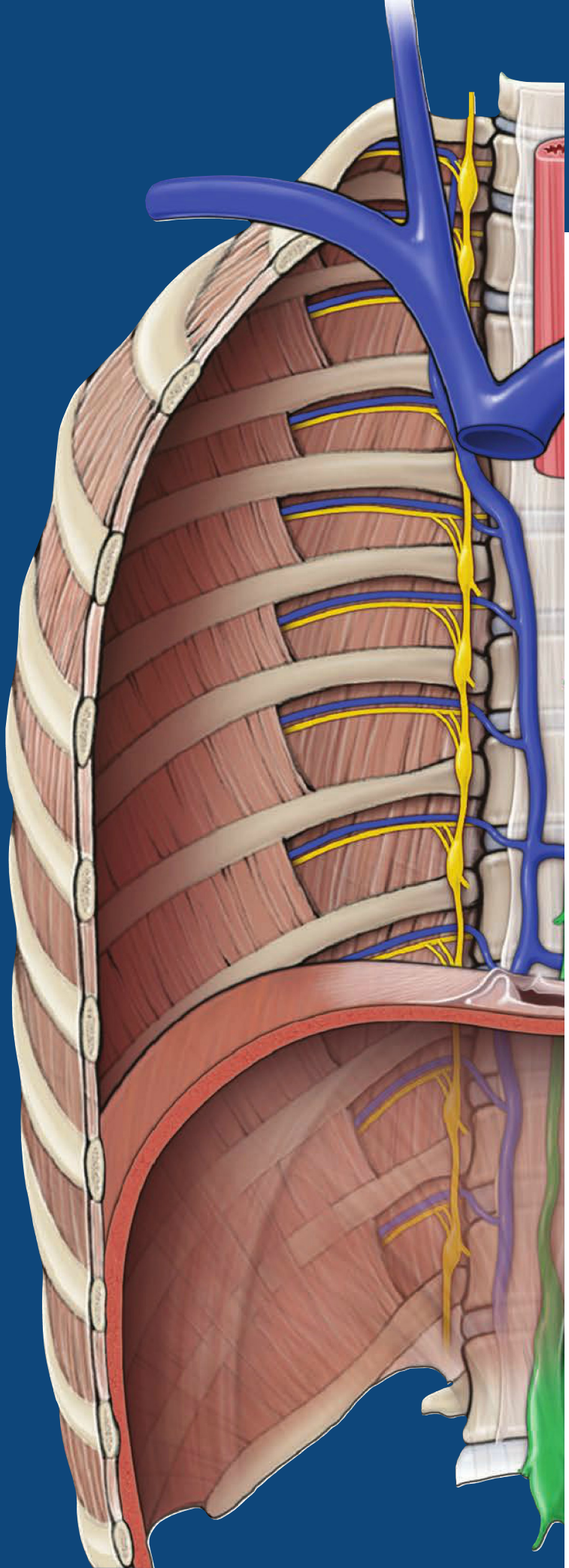

CHAPTER 36

THIGH

Thigh 398
Muscles of the Thigh 398
Femoral Triangle 402
Lumbar Plexus 402
Vascularization of the Thigh 404
Knee Complex 406

THIGH

BIG PICTURE

The femur is the longest and strongest bone in the body and primary bone of the thigh. The femur articulates with the acetabulum (hip joint) and tibia and patella (knee joint). The knee joint enables flexion, extension, and minimal rotation and supports the weight of the body during static positions and dynamic movement during gait.

ACTIONS OF THE KNEE COMPLEX

The articulations between the femur, tibia, and patella form the knee joint and enable the following actions (Figure 36-1A):

- **Flexion.** Bending the knee joint.
- **Extension.** Straightening the knee joint.
- **Internal and external rotation.** Small rotational movements in the vertical axis.

MUSCLES OF THE THIGH

BIG PICTURE

The muscles of the thigh are divided by their fascial compartments (anterior, medial, and posterior) and act on the joint(s) the individual muscles cross (Figure 36-1B and Table 36-1).

MUSCLES OF THE ANTERIOR COMPARTMENT OF THE THIGH

The muscles in the anterior compartment of the thigh are primarily flexors of the hip and extensors of the knee because of their anterior orientation (Figure 36-1C). The femoral nerve (L2–L4) innervates these muscles; however, each muscle does not necessarily receive each spinal nerve level between L2 and L4.

- **Iliopsoas muscle.** Arises from two muscles: psoas major and iliacus muscles.
  - **Attachments.** Psoas major (L1–L5 vertebrae) and iliacus (iliac fossa); after forming a common tendon at the level of the inguinal ligament the iliopsoas inserts in the lesser trochanter.
  - **Actions.** Flex and laterally rotate the hip joint.
  - **Innervation.** Dually innervated (psoas major muscle ventral rami of L2) and iliacus (femoral nerve; ventral rami of L1–L3).
- **Sartorius muscle.** The longest muscle in the body.
  - **Attachments.** Anterior superior iliac spine and pes anserinus ("goose's foot") along the medial border of the tibial tuberosity. Pes anserinus is a term used to describe the conjoined tendons of the sartorius, gracilis, and semitendinosus muscles; their common insertion is medial to the tibial tuberosity.
  - **Actions.** Flex, abduct, and externally rotate the hip joint; flex the knee joint.
  - **Innervation.** Femoral nerve (L2–L3).
- **Quadriceps femoris muscle group.** A group of four muscles in the anterior compartment of the thigh and is a strong extensor muscle of the knee. There are four separate muscles in this group, each with distinct origins. However, all four parts of the quadriceps femoris muscle attach to the patella, via the quadriceps tendon, and then insert onto the tibial tuberosity. The femoral nerve (L2–L4) innervates the quadriceps femoris muscle group. The four separate muscles are as follows:
  - **Rectus femoris muscle.** Attaches on the anterior inferior iliac spine and to the quadriceps femoris tendon; flexes the hip joint and extends the knee joint.
  - **Vastus lateralis muscle.** Attaches to the linea aspera and quadriceps femoris tendon; extends the knee joint.
  - **Vastus medialis muscle.** Attaches to the linea and quadriceps femoris tendon; extends the knee joint.
  - **Vastus intermedius muscle.** Attaches to the upper two-thirds of the femoral shaft and quadriceps femoris tendon; extends the knee joint.

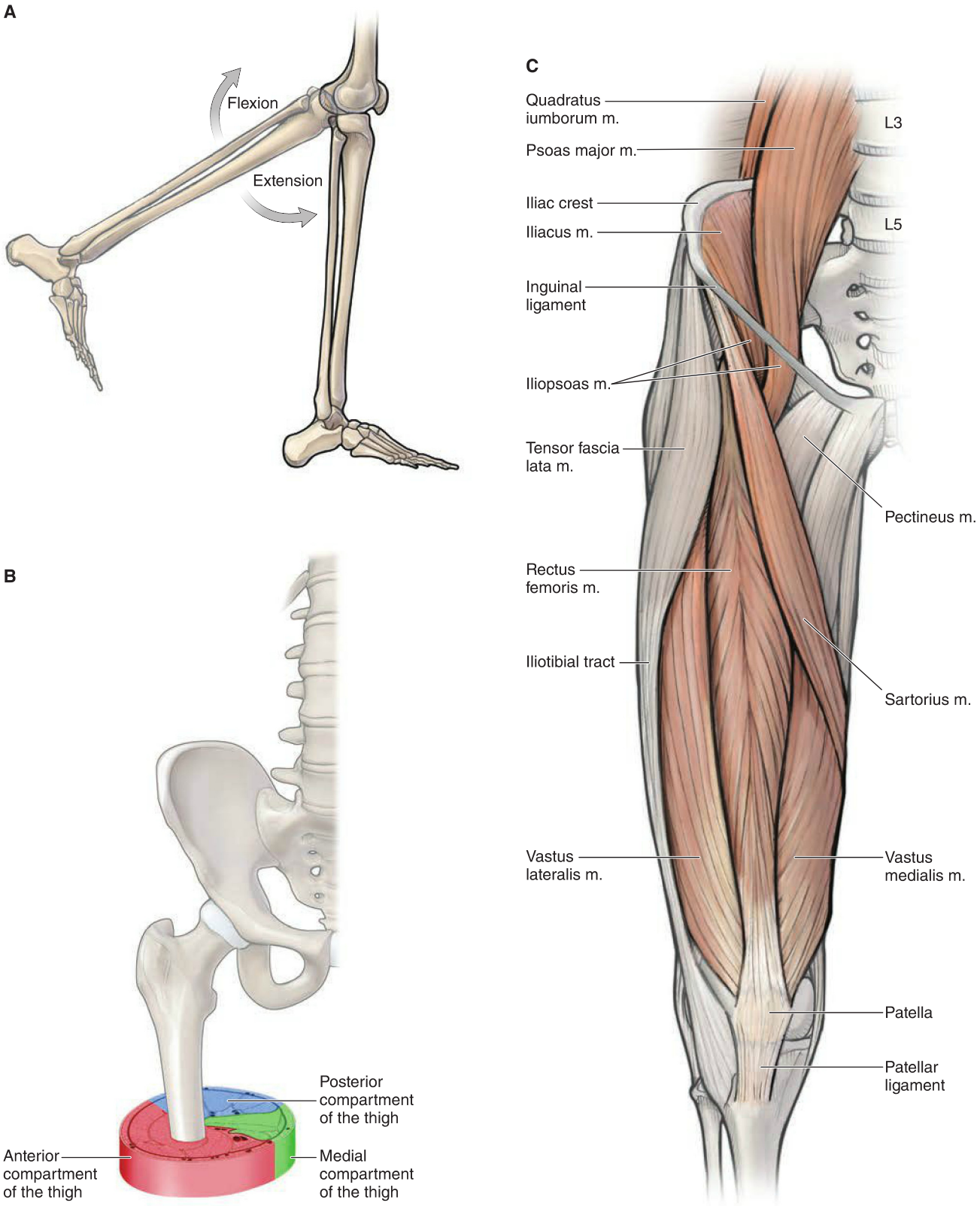

Figure 36-1: **A**. Actions of the knee joint. **B**. Compartments of the thigh. **C**. Muscles of the anterior compartment of the thigh.

MUSCLES OF THE MEDIAL COMPARTMENT OF THE THIGH

The muscles in the medial compartment of the thigh are primarily adductors of the hip because of their medial orientation. The obturator nerve (L2–L4) innervates most of the muscles in the medial compartment of the thigh (Figure 36-2A and B).

- **Pectineus muscle.** Attaches to the pectineal lines of the pubis and femur; adducts and flexes the hip joint. The femoral nerve (L2–L3) innervates this muscle, with occasional branches from the obturator nerve.
- **Adductor longus muscle.** Attaches to the pubis and linea aspera; adducts and internally rotates the hip joint.
- **Adductor magnus muscle.** Consists of a pubofemoral and ischiocondylar division. Between these two divisions is the adductor canal, which is traversed by the popliteal artery and vein.
  - **Pubofemoral (adductor) division.** Attaches to the inferior pubic ramus and linea aspera; adducts and internally rotates the hip joint; innervated by the obturator nerve (L2–L4).
  - **Ischiocondylar (hamstring) division**. Attaches to the ischiopubic ramus, ischial tuberosity, and adductor tubercle and adducts the hip joint; innervated by the tibial nerve (L4).
- **Adductor brevis muscle.** Attaches to the inferior pubic ramus and the linea aspera; adducts and internally rotates the hip joint and is innervated by the obturator nerve (L2–L4).
- **Gracilis muscle.** Attaches to the inferior pubic ramus and the medial surface of the proximal shaft of the tibia (pes anserinus); adducts the hip joint and flexes the knee joint and is innervated by the obturator nerve (L2–L3).
- **Obturator externus muscle.** Attaches to the external surface of the obturator membrane, adjacent bone, and trochanteric fossa; externally rotates the hip joint and is innervated by the obturator nerve (L3–L4).

MUSCLES OF THE POSTERIOR COMPARTMENT OF THE THIGH

The muscles in the posterior compartment of the thigh are primarily **extensors of the hip** or **flexors of the knee** because of their posterior orientation. The **tibial nerve (L4–S3)** innervates the muscles in the posterior compartment of the thigh, with the exception of the short head of the biceps femoris muscles (common fibular nerve). Muscles in this compartment are as follows (Figure 36-2C):

- **Semitendinosus muscle.** Attaches to the ischial tuberosity and proximal tibia (pes anserinus); extends the hip joint and flexes and internally rotates the knee joint, and is innervated by the tibial nerve (L5–S2).
- **Semimembranosus muscle.** Attaches to the ischial tuberosity and medial tibial condyle; extends the hip joint and flexes and internally rotates the knee joint; innervated by the tibial nerve (L5–S2).
- **Biceps femoris muscle.** Consists of two heads (long and short heads).
  - **Long head.** Attaches to the ischial tuberosity and fibular head; extends the hip and flexes and externally rotates the knee and is innervated by the tibial nerve (L5–S2).
  - **Short head.** Attaches to the linea aspera and fibular head; flexes and externally rotates the knee joint and is innervated by the common fibular nerve (L5–S2).

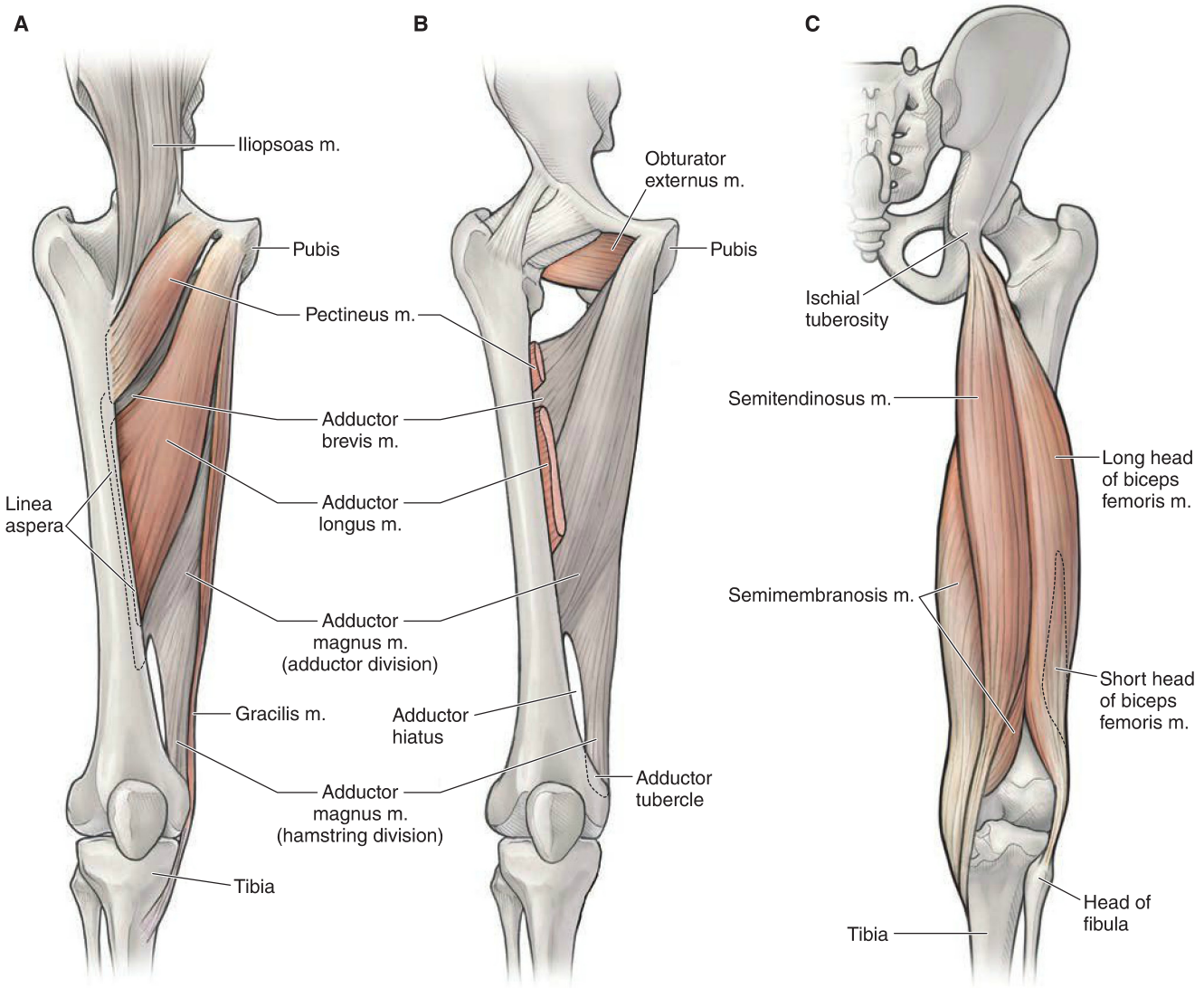

Figure 36-2: **A**. Superficial view of muscles of the medial compartment of the thigh. **B**. Deep view of muscles of the medial compartment of the thigh. **C**. Muscles of the posterior compartment of the thigh (hamstrings).

FEMORAL TRIANGLE

BIG PICTURE

The femoral triangle is located in the inguinal region and contains the femoral nerve, artery, and vein, and the lymphatics. The femoral triangle is bordered by the sartorius muscle, adductor longus muscle, and inguinal ligament and contains the femoral nerve, artery, vein, and lymphatics (Figure 36-3A). Often, the acronym **NAVL** is used to represent the orientation of the structures of the femoral triangle.

- **Femoral nerve (L2–L4).** Innervates the muscles in the anterior compartment of the thigh and sensory to the anterior thigh and medial leg.
- **Femoral artery.** At the inguinal ligament the external iliac artery becomes the femoral artery; traverses the adductor hiatus and transitions into the popliteal artery.
- **Femoral vein.** Continues as the external iliac vein.
- **Lymphatics.** Lymph nodes that drain lymphatic fluid from the lower limb.
  - **Femoral sheath.** As the femoral artery, femoral vein, and associated lymphatic structures course from the abdominal cavity into the femoral triangle, the transversalis fascia forms a connective tissue sheath around each vessel, which is called the femoral sheath. Each structure within the sheath is contained within their own separate fascial compartment. The femoral nerve is lateral to and not contained within the femoral sheath.

LUMBAR PLEXUS

BIG PICTURE

The lower limb is innervated by the L1–S3 ventral rami, which form two separate networks of nerves that are referred to as the lumbar plexus (L1–L4) and the sacral plexus (L4–S3). (The sacral plexus is discussed in Chapter 35.) The lumbar plexus consists of ventral rami from the L2 to L4 levels of the spinal cord, which exit the intervertebral foramina and course along the posterior abdominal wall, en route to the anterolateral abdominal wall and lower limb (Figure 36-3B).

LOWER LIMB BRANCHES OF THE LUMBAR PLEXUS

The lumbar plexus has the following branches (Figure 36-3C):

- **Lateral cutaneous nerve of the thigh (L2–L3).** Emerges from the lateral border of the psoas major muscle, crossing the iliacus muscle, and enters the thigh medial to the anterior superior iliac spine; provides sensory innervation to the lateral thigh; also known as the lateral femoral cutaneous nerve or "Lat-Fem-Q" for short.
- **Femoral nerve (L2–L4).** Emerges as the largest branch of the lumbar plexus, deep to the lateral border of the psoas major muscle, and passes deep to the inguinal ligament. The femoral nerve then enters the anterior compartment of the thigh, where it provides motor innervation to the quadriceps femoris muscle group, sartorius, and pectineus muscles. In addition, the femoral nerve provides sensory innervation via the following sensory branches:
  - **Anterior cutaneous nerve of the thigh.** Supplies the skin of the anterior and medial thigh.
  - **Saphenous nerve.** Courses with the femoral artery and vein into the **adductor canal**. The femoral artery and femoral vein enter the **popliteal fossa**. However, the saphenous nerve exits the adductor canal and supplies the skin on the medial region of the leg.
- **Obturator nerve (L2–L4).** Emerges from the medial border of the psoas major muscle, passing posterior to the common iliac artery, and enters the medial compartment of the thigh through the obturator foramen. The obturator nerve provides motor innervation to the medial compartment of the thigh (excluding the pectineus and hamstring portion of the adductor magnus muscle). In addition, the obturator nerve provides sensory innervation to the medial region of the thigh.

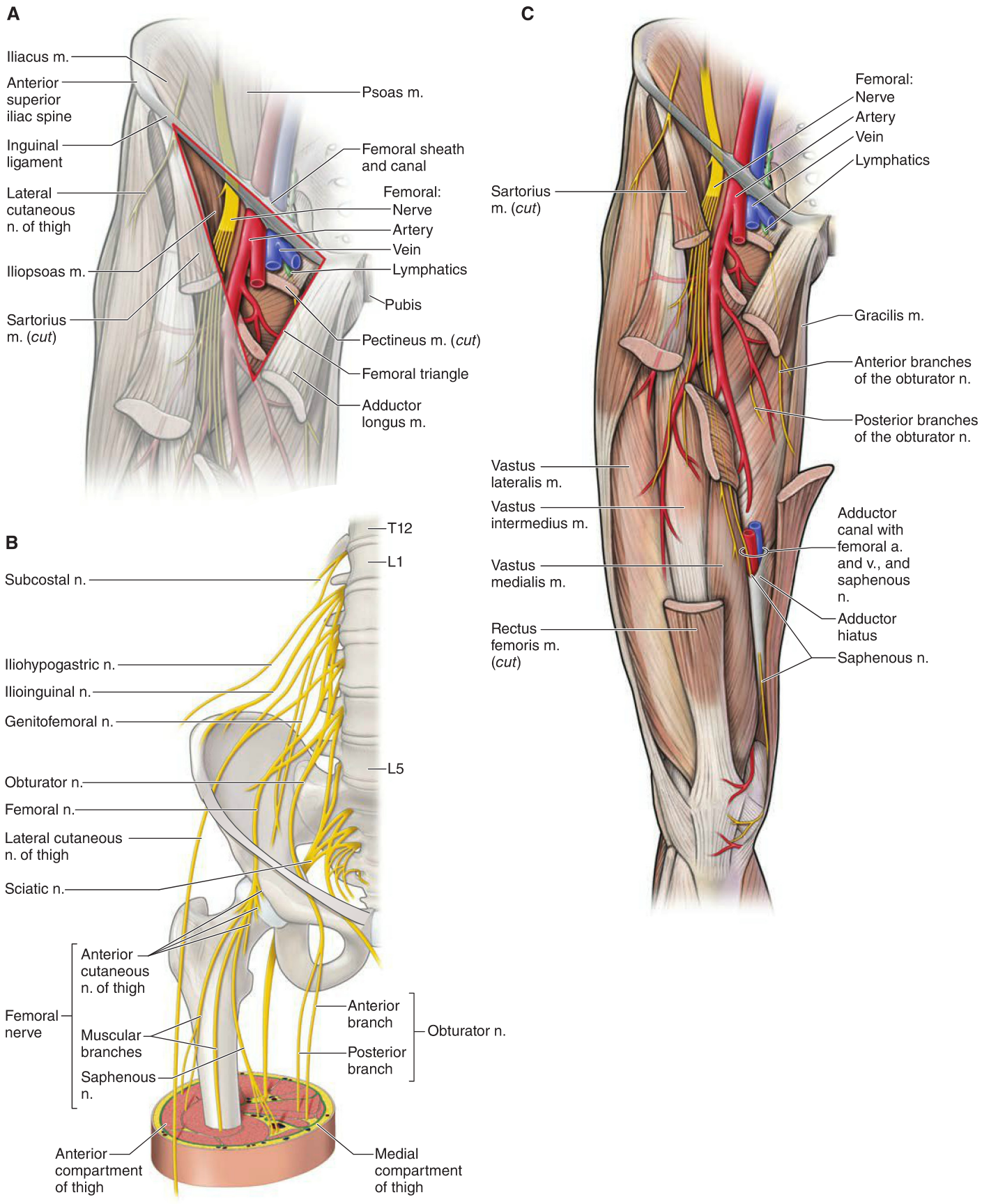

Figure 36-3: **A**. Femoral triangle. **B**. Innervation of the compartments of the thigh. **C**. Femoral nerve.

VASCULARIZATION OF THE THIGH

BIG PICTURE

The blood supply to the lower extremity is from the common iliac arteries. The common iliac arteries divide into the external and internal iliac arteries. The external iliac artery passes deep to the inguinal ligament to become the femoral artery, serving as the primary blood supply to the lower limb. The internal iliac artery gives rise to the obturator artery, which also contributes to blood supply of the lower limb.

OBTURATOR ARTERY

Arises from the internal iliac artery, exits the pelvis through the obturator foramen, and divides into anterior and posterior divisions. The two divisions circle the adductor brevis muscle. A branch enters the hip joint at the acetabular notch and travels through a conduit in the ligament of the head of the femur (ligamentum teres) to supply blood to the femoral head.

FEMORAL ARTERY

The femoral artery gives rise to the following (Figure 36-4A and B):

- **Deep artery of the thigh (profunda femoris artery or deep femoral artery).** The largest branch of the femoral artery; arises posteriorly in the femoral triangle and travels between the adductor longus and brevis muscles and the adductor longus and magnus muscles. The deep artery of the thigh is the main contributor of blood to the posterior and medial compartments of the thigh. The branches of the deep artery of the thigh are as follows:
  - **Perforating branches.** Pierces through the adductor magnus muscle to supply the posterior compartment of the thigh.
  - **Lateral circumflex femoral artery.** Gives rise to ascending, transverse, and descending branches.
  - **Medial circumflex femoral artery.** Branches medially and passes around the shaft of the femur; supplies the hip joint.

The main trunk of the femoral artery follows the adductor canal distally and travels through the adductor hiatus into the popliteal fossa to become the popliteal artery.

Coronary angioplasty. When coronary arteries become blocked or narrowed by plaque, coronary angioplasty may be performed. This procedure opens blocked arteries in an attempt to restore normal blood flow to the heart. It is accomplished by threading a catheter (thin tube containing a balloon) through an artery (often the femoral artery in the femoral triangle). The catheter is threaded all the way up to the ascending aorta, into the left or right coronary artery and into the branch with the most plaque. The balloon is then expanded to open the blood vessel.

POPLITEAL ARTERY

The popliteal artery is the continuation of the femoral artery after it traverses the adductor hiatus (Figure 36-4A and B). The branches form an anastomotic vascular supply to the knee and are named according to their relationship to each other (superior lateral and medial genicular arteries and inferior lateral and medial genicular arteries).

LYMPHATICS OF THE INGUINAL AREA

The lymphatics of the thigh are organized into the following inguinal lymph nodes:

- **Superficial inguinal nodes.** Lymph nodes that are parallel to the inguinal ligament and receive lymph from the external genitalia, anal canal, gluteal region, inferior abdominal wall, and lymphatic vessels of the lower limb; superficial inguinal nodes drain to the external iliac nodes.
- **Deep inguinal nodes.** One to three nodes located medial to the femoral vein; receive lymph from deep lymphatic vessels associated with the femoral vessels and glans penis or clitoris. Also, the deep inguinal nodes drain into the external iliac nodes.
- **Popliteal nodes.** Six small nodes located in the fat of the popliteal fossa. The popliteal nodes receive lymph from the knee and the deep vessels associated with the tibial vessels of the leg. Vessels from the popliteal nodes ascend the thigh to drain into the deep inguinal nodes, eventually reaching the external iliac nodes.

VEINS OF THE THIGH

The veins of the thigh consist of a superficial and a deep venous system.

- **Great saphenous vein.** Originates from the dorsal venous arch in the foot on the medial side, courses anterior to the medial malleolus, and ascends the leg and thigh on the medial side; pierces the fascia latae of the thigh, forming the saphenous opening to drain in the femoral vein.
- The deep venous system consists of as many as three veins that course with each artery. Most of the veins in the thigh drain into the femoral vein and are named the same as the artery they run with.

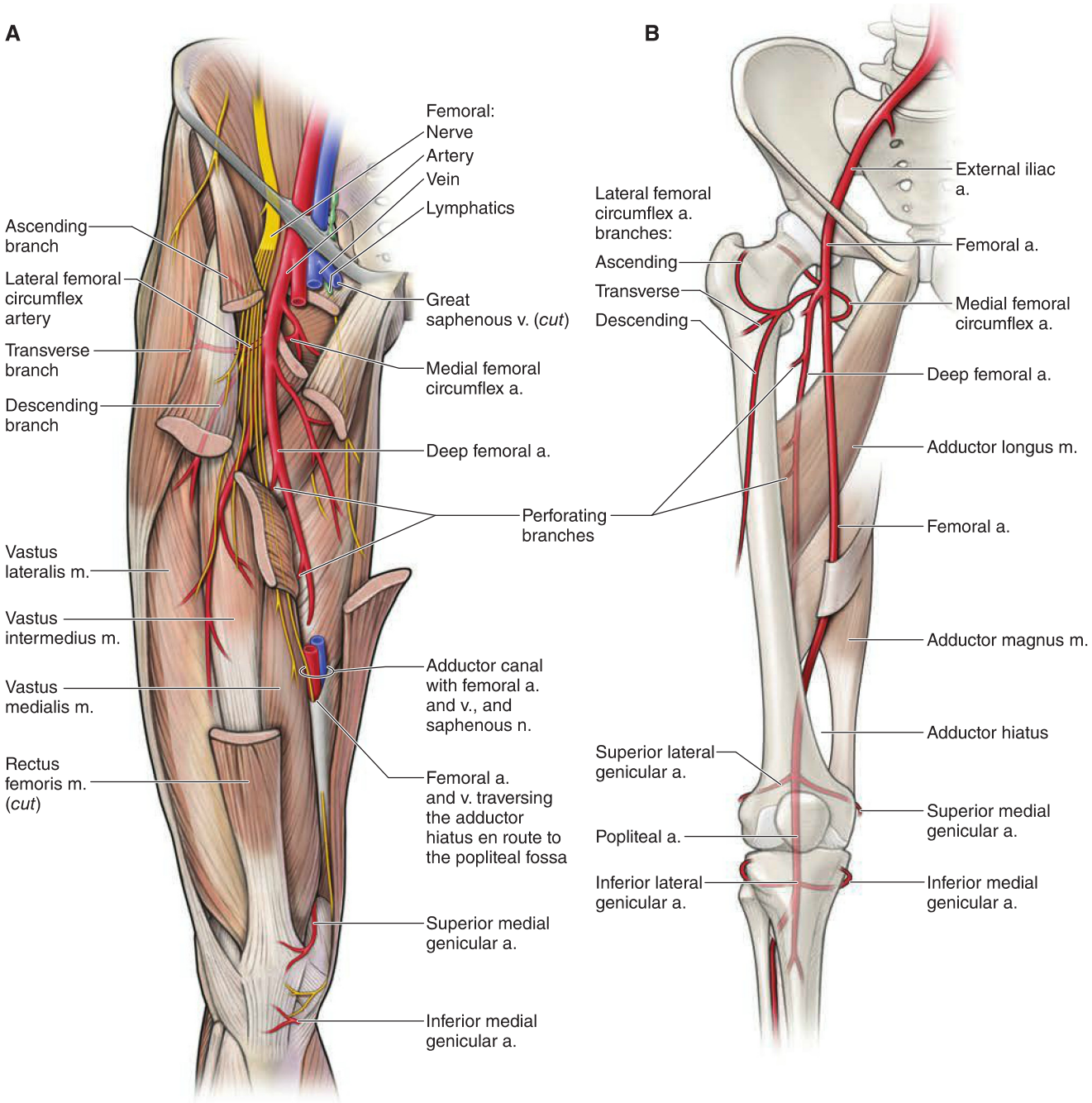

Figure 36-4: **A**. Vasculature of the thigh. **B**. Femoral artery and its branches.

KNEE COMPLEX

BIG PICTURE

The knee complex consists of articulations between the femur and the tibia (tibiofemoral joint) and between the femur and the patella (patellofemoral joint). These articulations allow for static positions (standing) and dynamic movements (walking or running).

KNEE JOINT

The knee is composed of the following joints:

- **Tibiofemoral joint.** A synovial bicondylar joint with two degrees of motion. Articulations occur between the two condyles of the femur and the two tibial plateaus, producing flexion and extension. In addition, the tibiofemoral joint allows for minimal axial rotation with the pivot point, located medially on the medial tibial plateau.
- **Patellofemoral joint.** Articulation is between the intercondylar notch of the femur and the patella and shares the same joint capsule as the tibiofemoral joint. The patellofemoral joint directly serves the tibiofemoral joint; however, because of the vast differences in clinical problems and pathologies, the two joints will be discussed independently.

▼ **Patellofemoral disorder.** A common knee disorder seen in patients who visit orthopedic clinics. The disorder is usually caused by excessive pressure or misalignment between the patella and the femur, resulting in pain at the patellofemoral joint. ▼

LIGAMENTOUS AND CAPSULAR SUPPORT OF THE KNEE Ligament and capsule support of the knee are critical because of the incongruence of the joint, weight bearing of the joint, and the large range of motion with flexion and extension (Figure 36-5A–C). The ligaments and capsule provide support to the knee joint as follows:

- **Capsule.** Surrounds the knee joint and includes the patellofemoral joint. The capsule extends from the distal femur to the proximal tibia and contains areas of laxity and recesses to allow for range of motion. The ligaments that support the capsule on all four sides of the joint are as follows:
  - **Patellar ligament.** Transmits forces produced by the quadriceps muscles to the tibia (basically a continuation of the quadriceps femoris tendon that attaches between the patella and tibial tuberosity).
  - **Medial (tibial) collateral ligament (MCL).** Attaches to the medial epicondyle of the femur, medial meniscus, and tibial condyle; resists valgus forces on the knee (tibia abducting on femur).
  - **Lateral (fibular) collateral ligament (LCL).** Appears as a strong cord and attaches to the lateral femoral epicondyle and fibular head; resists varus forces on the knee (tibia adducting on the femur).

In addition to the capsular ligaments, the knee complex also contains ligaments inside the capsule, called the anterior and posterior cruciate ligaments because they are arranged in a cross-formation. They are named according to where they arise on the tibia.

- **Anterior cruciate ligament (ACL).** Connects the tibia (anterior intercondylar eminence) to the femur (lateral femoral condyle); resists anterior translation of the tibia on the femur (anterior tibial displacement or posterior translation of the femur on the tibia) especially at 30 and 90 degrees of knee flexion.
- **Posterior cruciate ligament (PCL).** Stronger than the ACL; connects the tibia (posterior intercondylar eminence) to the femur (medial femoral condyle); resists posterior translation of the tibia on the femur or anterior translation of the femur on the tibia.

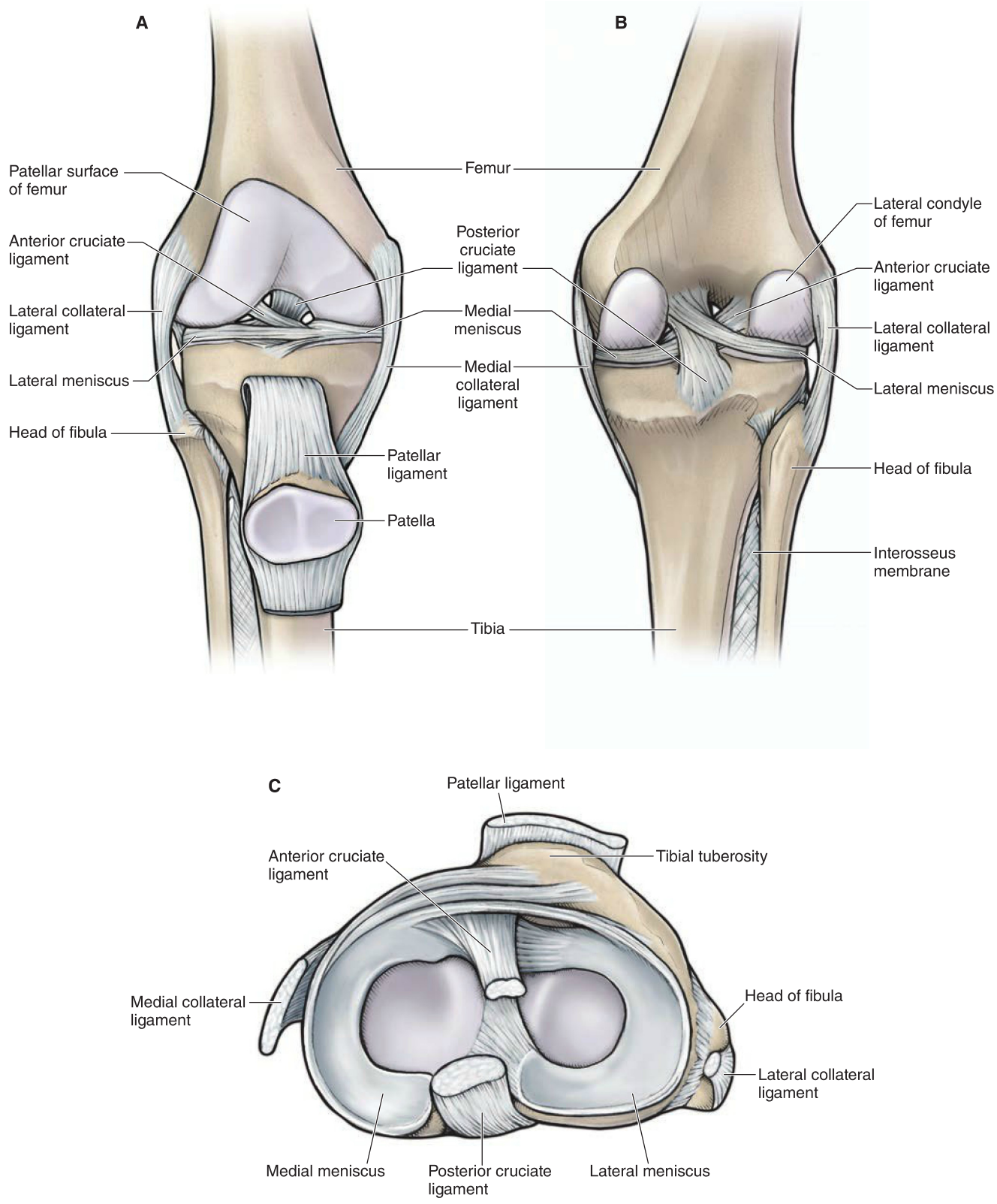

Figure 36-5: **A**. Anterior view of the right knee joint with the joint capsule open showing the patella reflected inferiorly. Posterior (**B**) and superior (**C**) views of the right knee joint.

MENISCI OF THE KNEE JOINT

The knee contains two fibrocartilaginous structures (medial and lateral menisci) that help support the knee joint (Figure 36-5A–C). The menisci are wedge shaped (thick laterally and thin medially), which increases the concavity of the articulating surface of the tibia. The menisci separate the femur and tibia to decrease the contact area between the bones, serves as a shock absorber when contact force is experienced, and decreases friction. The transverse ligament of the knee connects the menisci anteriorly.

- **Medial meniscus.** Attached to the medial collateral ligament (makes it less mobile).
- **Lateral meniscus.** Forms four-fifths of a complete circle and is more mobile than the medial meniscus; attached to the popliteus muscle.

ACL injury. An injury to the ACL is usually seen in patients who participate in sports that require cutting movements with deceleration (e.g., soccer, football). The mechanism of injury is usually deceleration of the body on an outstretched leg with lateral rotation of the femur on a fixed tibia. Treatment is often surgery using an autograft (i.e., tissue is taken from the patient to replace the patient's ligament). Frequently, a midpatellar ligament graft is used.

BURSAE ASSOCIATED WITH THE KNEE JOINT COMPLEX

The knee joint has many bursae (sacs of synovial fluid) to decrease frictional forces. The most important bursae are as follows:

- **Suprapatellar bursa.** Located between the quadriceps tendon and the anterior femur.
- **Subpopliteal bursa.** Located between the popliteus muscle and the lateral femoral condyle.
- **Gastrocnemius bursa.** Located between the medial head of the gastrocnemius muscle and the medial femoral condyle.
- **Prepatellar bursa.** Located between the skin and the anterior patella.
- **Subcutaneous infrapatellar bursa.** Located between the patellar ligament and the tibial tubercle.

Prepatellar bursitis (commonly known as "housemaid's knee") is caused by inflammation or bursitis of the superficial infrapatellar bursa between the skin and the patellar ligament. The mechanism of injury can be from direct impact or from an irritation to the knee that occurs over time. The condition is often seen in individuals whose occupations require them to place pressure on the knees, such as carpet layers or people who wash the floor on their hands and knees (thus the term housemaid's knee), resulting in pain over the patellar ligament.

PES ANSERINUS

The pes anserinus ("goose foot") refers to the combined tendons of the sartorius, gracilis, and semitendinosus muscles, which insert medial to the tibial tuberosity and superficial to the medial collateral ligament. The name "goose foot" arises from the three-pronged manner in which the conjoined tendon inserts onto the tibia.

- **Pes anserinus bursa**. A small sack of synovial fluid located between the pes anserinus and deeper semimembranosus tendon at the level of the knee joint. This bursa reduces friction within the tendon movements. However, this bursa may become inflamed and cause anserinus bursitis.
- **ACL surgeries**. The semitendinosus tendon within the pes anserinus may be grafted for ACL reconstruction surgeries.

TABLE 36-1. Muscles of the Thigh

Muscle	Proximal Attachment	Distal Attachment	Action	Innervation
Anterior compartment of the thigh				
Psoas minor	T12–L1 vertebral bodies and discs	Pectin pubis	Lumbar spine flexion, posterior pelvic tilt	Anterior rami (L1)
Psoas major	T12–L5 transverse processes, vertebral bodies, and discs	Lesser trochanter of femur	Flexes and externally rotates thigh at hip joint; flexes trunk (psoasmajor)	Anterior rami (L1–L3)
Iliacus	Iliac fossa			Femoral n. (L2, L3)
Sartorius	Anterior superior iliac spine	Inferomedial to tibial tuberosity (pes anserinus)	Flexes thigh at hip joint and flexes leg at knee joint	Femoral n. (L2, L3)
Rectus femoris	Anterior inferior iliac spine		Flexes thigh at hip joint and extends leg at knee joint	Femoral n. (L2–L4)
Vastus lateralis	Lateral part of intertrochanteric line, margin of greater trochanter, lateral margin of gluteal tuberosity, lateral lip of linea aspera	Quadriceps femoris tendon	Extends leg at knee joint	
Vastus medialis	Medial part of intertrochanteric line, pectineal line, medial lip of linea aspera, and medial supracondylar ridge			
Vastus intermedius	Femur: upper two-thirds of anterior and lateral surfaces			

(*continued*)

TABLE 36-1. Muscles of the Thigh (*continued*)

Muscle	Proximal Attachment	Distal Attachment	Action	Innervation
Medial compartment of the thigh				
Pectineus	Pectineal line	Oblique line extending from base of lesser trochanter to linea aspera on posterior surface of proximal femur	Adducts and flexes thigh at hip joint	Femoral n. (L2, L3)
Adductor longus	Body of pubis	Linea aspera	Adducts and medially rotates thigh at hip joint	Obturator n. (anterior division) (L2–L4)
Adductor brevis	Body of pubis and inferior pubic ramus			Obturator n. (anterior division) (L2, L3)
Adductor magnus	Adductor part: ischiopubic ramus Hamstring part: ischial tuberosity	Adductor part: linea aspera Hamstring part: Adductor tubercle	Adducts and medially rotates thigh at hip joint	Adductor part: obturator n. (L2–L4) Hamstring part: tibial division of sciatic n. (L4) and obturator n. (L2, L3)
Gracilis	Body and inferior ramus of pubic bone	Medial surface of proximal shaft of tibia (pes anserinus)	Adducts thigh at hip joint and flexes leg at knee joint	Obturator n. (L2, L3)
Obturator externus	External surface of obturator membrane and adjacent bone	Trochanteric fossa	Laterally rotates hip	Obturator n. (posterior division) (L3, L4)
Posterior compartment of the thigh				
Semitendinosus	Ischial tuberosity	Medial surface of proximal tibia (pes anserinus)	Flexes leg at knee joint and extends thigh at hip joint; medially rotates thigh at hip joint and leg at knee joint	Tibial division of sciatic n. (L5–S2)
Semimembranosus		Medial and posterior surface of medial tibial condyle		
Biceps femoris	Long head: ischial tuberosity Short head: lateral lip of linea aspera	Head of fibula	Knee flexion Hip extension Lateral rotation of hip and knee	Long head: tibial division of sciatic n. (L5–S2) Short head: common fibular division of sciatic n. (L5–S2)

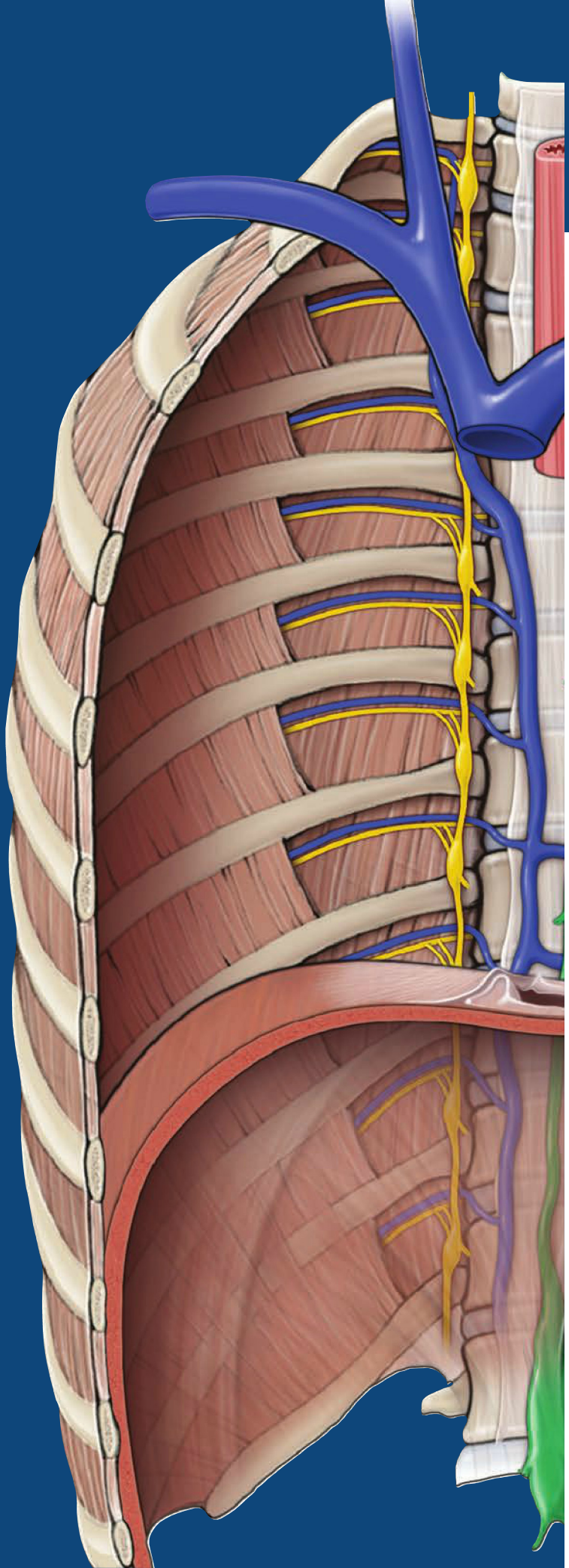

CHAPTER 37

LEG

Muscles of the Leg 412
Innervation of the Leg 418
Vascularization of the Leg 418
Joints of the Leg and Ankle 420

MUSCLES OF THE LEG

BIG PICTURE

The leg consists of the tibia and fibula. The tibia articulates with the femur through the knee joint. Distally, the tibia and fibula articulate with the talus through the ankle joint. The muscles of the leg that act on ankle and foot are organized into three fascial compartments, similar to those of the thigh muscles (Figure 37-1A). The anterior compartment contains muscles that primarily produce dorsiflexion of the ankle and extension of the digits. The posterior compartment contains muscles that primarily produce plantar flexion and inversion at the ankle joint and flexion of the digits. The lateral compartment contains muscles that primarily produce plantar flexion and eversion at the ankle joint.

ACTIONS OF THE ANKLE

The primary ankle joints and their associated actions are as follows:

- **Talocrural joint**. Consists of articulations between the tibia and talus (tibiotalar joint) and the fibula and talus (talofibular joint) and allows for motion primarily in the sagittal plane (Figure 37-1B):
  - **Plantar flexion.** Foot moves downwards (standing on tip-toes).
  - **Dorsiflexion.** Foot moves upwards (standing on heals).
- **Subtalar joint.** Formed by articulations between the talus and the calcaneus and allows for motion primarily in the coronal plane:
  - **Inversion.** Plantar surface of the foot moves to face medially.
  - **Eversion.** Plantar surface of the foot moves to face laterally.

The terms supination and pronation describe the rolling motion of the heels and feet during normal walking or running. This includes the talocrural, subtalar, and forefoot joints, which permit three simultaneous planes of motion that result in pronation and supination.

- **Pronation.** Dorsiflexion, eversion, and forefoot abduction. Pronation occurs as the lateral edge of the heel strikes the ground while walking and running and the foot rolls inward and flattens out to help absorb shock.
- **Supination.** Plantar-flexion, inversion, and forefoot adduction. Supination describes the outward rolling motion, which occurs when the calcaneus lifts off the ground during foot take off and most of the body weight is placed onto the lateral surface of the foot. Supination enables the foot to form a rigid structure for propulsion during walking and running.

MUSCLES OF THE ANTERIOR COMPARTMENT OF THE LEG

The anterior compartment of the leg is formed by the deep fascia and contains muscles that primarily dorsiflex the ankle and extend the digits (Table 37-1). It also contains the anterior tibial artery and deep fibular nerve.

The following muscles comprise the anterior compartment of the leg (Figure 37-1C):

- **Tibialis anterior muscle.** Attaches to the tibia, interosseous membrane, medial cuneiform, and the base of metatarsal 1. The tibialis anterior muscle dorsiflexes and inverts the ankle and is innervated by the deep fibular nerve (L4–L5).
- **Extensor digitorum longus muscle.** Attaches to the fibula, lateral tibial condyle, and dorsal digital expansions of digits 2 to 5. The extensor digitorum longus muscle extends digits 2 to 4, dorsiflexes the ankle, and is innervated by the deep fibular nerve (L5–S1).
- **Extensor hallucis longus muscle.** Attaches to the fibula, interosseous membrane, and distal phalanx of the great toe. The extensor hallucis longus muscle extends the great toe, dorsiflexes the foot, and is innervated by the deep fibular nerve (L5–S1).
- **Fibularis (peroneus) tertius muscle.** Attaches to the distal part of the fibula and base of metatarsal 5. The fibularis tertius muscle weakly dorsiflexes and everts the foot and is innervated by the deep fibular nerve (L5–S1). This muscle may be absent in some people.

DORSUM OF THE FOOT

The following muscles are located on the dorsal surface of the foot:

- **Extensor digitorum brevis muscle.** Attaches to the calcaneus and dorsal surface of digits 2 to –4. The extensor digitorum brevis muscle extends digits 2 to 4 and is innervated by the deep fibular nerve (S1–S2).
- **Extensor hallucis brevis muscle.** Attaches to the calcaneus and dorsal surface of the great toe. The extensor hallucis brevis muscle extends the great toe and is innervated by the deep fibular nerve (S1–S2).

Shin splints. The term "shin splints" is often an all-inclusive term used to describe pain in the anterior compartment of the leg. Most commonly, shin splints are caused by physical activity in which the foot is lowered to the ground following heel strike (such as occurs when running and especially when running downhill). The pain is due to inflammation of the periosteum of the tibia. In more severe cases, shin splints can result in stress fractures.

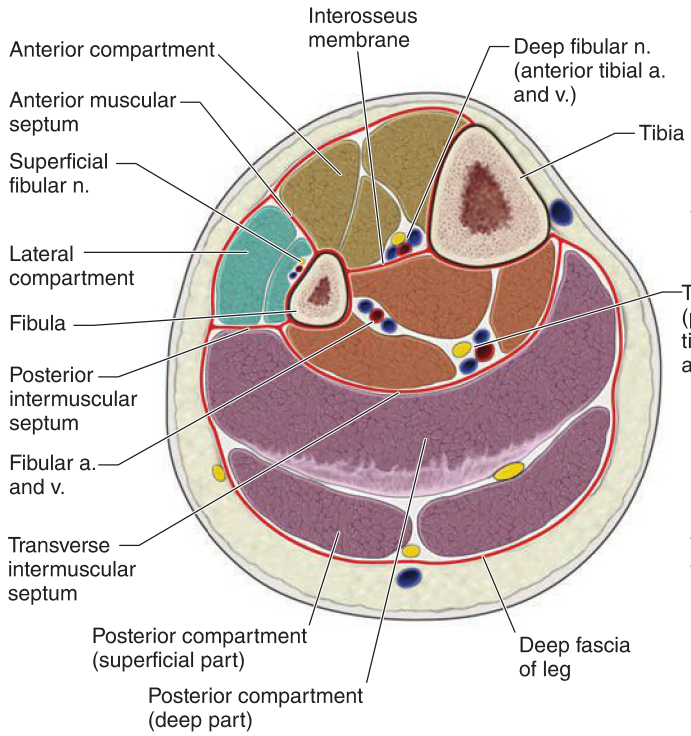

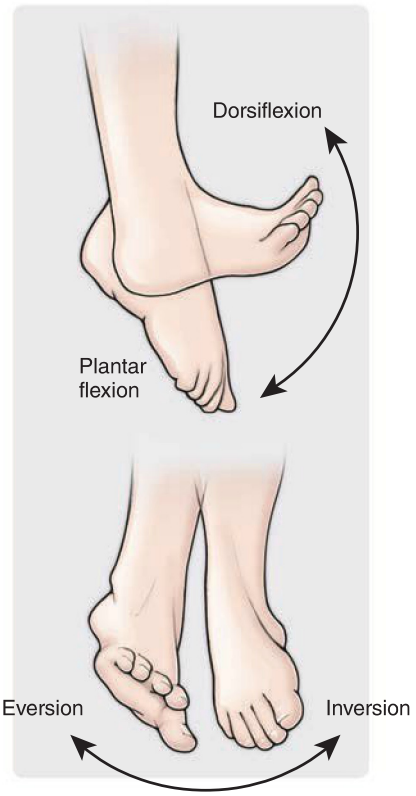

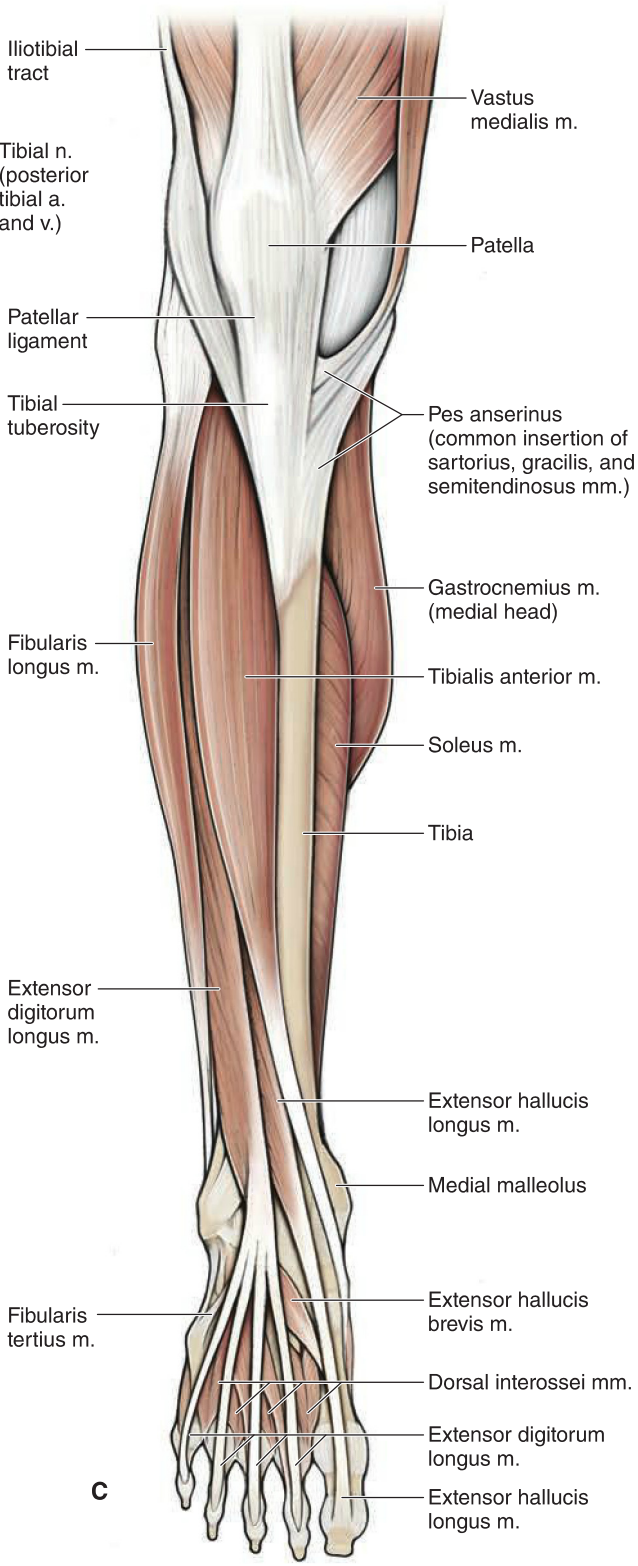

Figure 37-1: **A**. Cross-section of the right leg (viewed from foot to head). **B**. Movements of the ankle. **C**. Muscles of the anterior compartment of the leg.

MUSCLES OF THE LATERAL COMPARTMENT OF THE LEG

The lateral compartment of the leg is formed by the deep fascia and contains muscles that primarily plantarflex and evert the ankle. It also contains the superficial fibular (peroneal) nerve.

The following muscles comprise the lateral compartment of the leg (Figure 37-2):

- **Fibularis (peroneus) longus muscle.** Attaches to the proximal fibula, medial cuneiform, and base of metatarsal 1. The fibularis longus muscle plantarflexes and everts the ankle and is innervated by the superficial fibular (peroneal) nerve (L5–S2).
- **Fibularis (peroneus) brevis muscle.** Attaches to the fibula; distally and base of metatarsal 5. The fibularis brevis muscle plantarflexes and everts the foot and is innervated by the superficial fibular (peroneal) nerve (L5–S2).

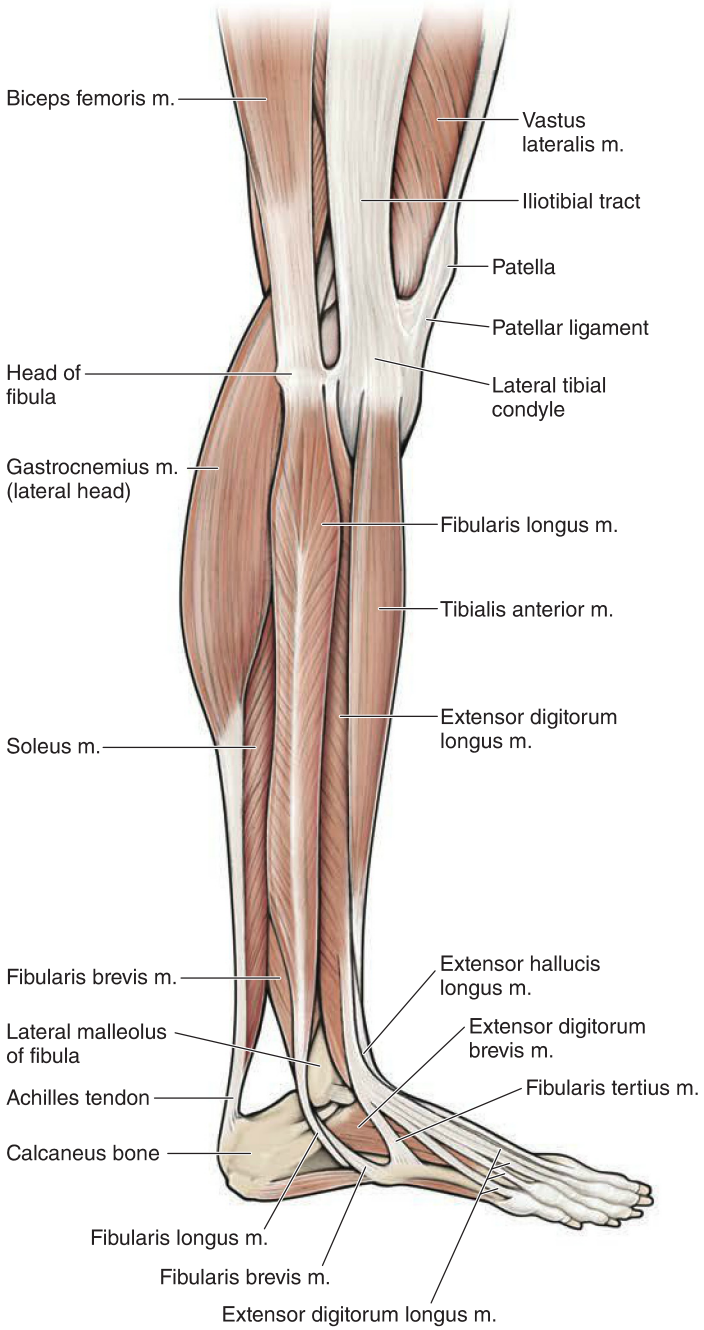

Figure 37-2: Muscles of the lateral compartment of the leg.

MUSCLES OF THE POSTERIOR COMPARTMENT OF THE LEG

The posterior compartment of the leg is subdivided into a superficial and a deep group by the deep fascia and contains muscles that primarily plantar and invert the ankle and flex the digits. It also contains the posterior tibial and fibular arteries and tibial nerve.

The following muscles comprise the **superficial region** of the posterior compartment of the leg (Figure 37-3A and B):

- **Gastrocnemius muscle.** Attaches to the femoral condyles and calcaneus via the calcaneal tendon. The gastrocnemius muscle plantarflexes the foot, weakly flexes the knee, and is innervated by the tibial nerve (S1–S2).
- **Plantaris muscle.** Attaches to the lateral supracondylar region of the femur and the calcaneus and is located between the gastrocnemius and soleus muscles. The plantaris muscle weakly plantarflexes the ankle and is innervated by the tibial nerve (S1–S2).
- **Soleus muscle.** Attaches to the posterior aspect of the tibia (soleal line), fibula calcaneus via the calcaneal tendon. The soleus muscle plantarflexes the foot and is innervated by the tibial nerve (S1–S2).

Calcaneal tendon rupture. The calcaneal (Achilles) tendon is a large ropelike band of fibrous tissue in the posterior ankle that connects the calf muscles (gastrocnemius and soleus muscles) to the calcaneus bone. When the calf muscles contract, the calcaneal tendon tightens and pulls the heel, resulting in standing on tiptoe; therefore, it is important in activities such as walking and jumping. Rupture of the calcaneal tendon usually is caused by a forceful push-off during an activity such as sprinting when running or jumping in a game of basketball. The result is tearing of the tendon. Bruising usually is apparent, and a visible bulge forms in the posterior region of the leg because of calf muscle shortening.

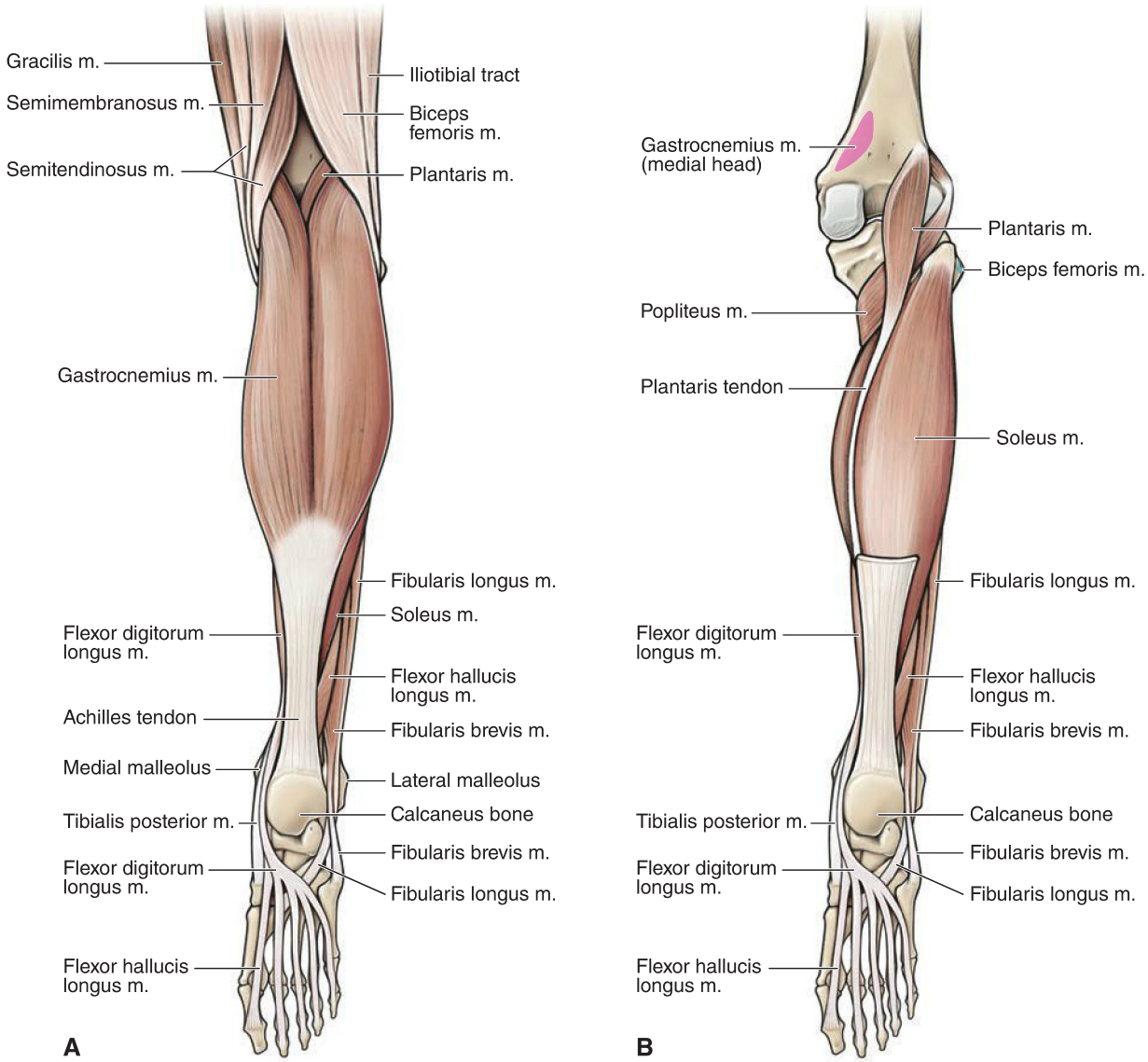

Figure 37-3: Muscles of the posterior compartment of the leg: (**A**) superficial dissection, (**B**) intermediate dissection.

The following muscles comprise the **deep region** of the posterior compartment of the leg (Figure 37-3C):

- **Popliteus muscle.** Attaches to the posterior surface of the tibia and lateral femoral condyle. The popliteus muscle unlocks the knee joint (it laterally rotates the femur on a fixed tibia) and is innervated by the tibial nerve (L4–S1).
- **Flexor hallucis longus muscle.** Attaches to the posterior surface of the fibula, interosseous membrane, and distal phalanx of the great toe. The flexor hallucis longus muscle flexes the great toe and is innervated by the tibial nerve (S2–S3).
- **Flexor digitorum longus muscle.** Attaches to the tibia and distal phalanges of digits 2 to 5. The flexor digitorum longus muscle flexes digits 2 to 5 and is innervated by the tibial nerve (S2–S3).
- **Tibialis posterior muscle.** Attaches to the tibia, interosseous membrane, fibula, navicular bone, cuneiform bones, and metatarsals 2–4. The tibialis posterior muscle inverts and plantarflexes the foot, provides support to the medial arch of the foot during walking, and is innervated by the tibial nerve (L4–L5).

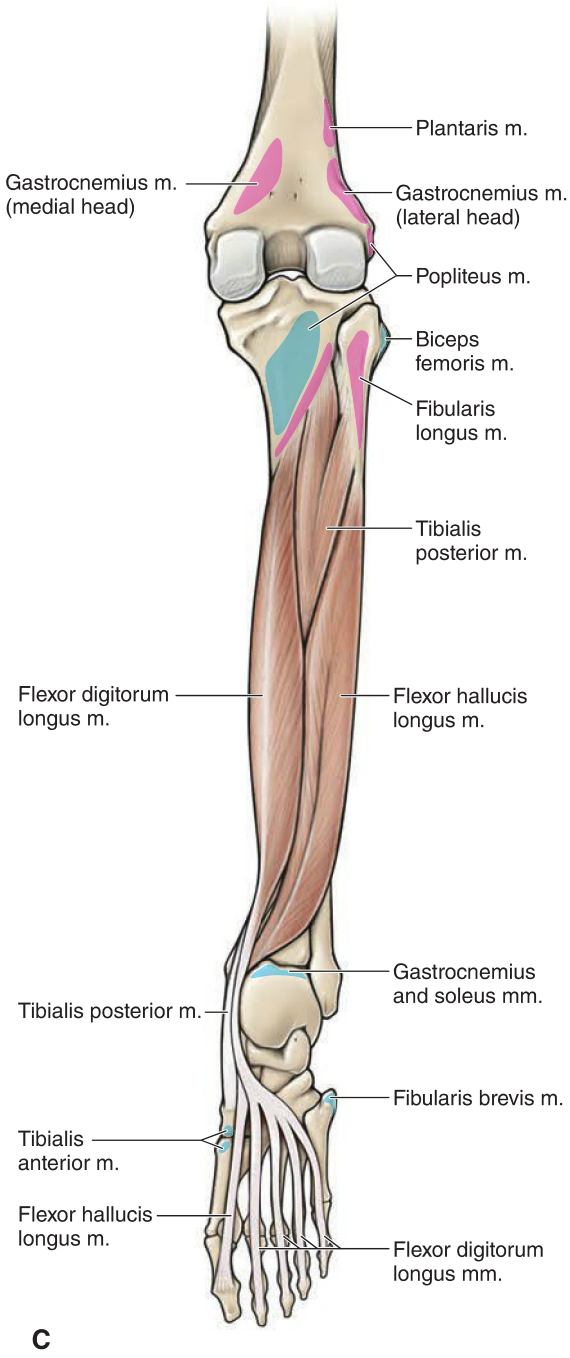

Figure 37-3: Muscles of the posterior compartment of the leg (continued) (**C**) deep dissection.

INNERVATION OF THE LEG

BIG PICTURE

The sciatic nerve contains both the tibial and common fibular nerves, near the popliteal fossa, to innervate muscles in the leg and foot.

TIBIAL NERVE

The tibial nerve arises from the anterior division of the sacral plexus (L4–S3), descends through the popliteal fossa, and courses deep to the soleus muscle to innervate the superficial and deep group of muscles in the posterior compartment of the leg (Figure 37-4A). The tibial nerve enters the foot through the tarsal tunnel inferior to the medial malleolus and innervates the plantar surface of the foot. The tibial nerve has muscular and sensory branches.

- **Muscular branches.** The tibial nerve innervates the muscles in the posterior compartment of the leg (gastrocnemius, plantaris, soleus, popliteus, flexor hallucis longus, flexor digitorum longus, and tibialis posterior muscles).
- **Sensory branch.** Gives rise to the **medial sural nerve**, which arises in the popliteal fossa and descends superficial to the gastrocnemius muscle to join the sural communicating branch from the lateral sural nerve. The medial sural nerve then becomes the sural nerve. Provides sensory innervation to the posterolateral region of the leg and foot.

COMMON FIBULAR (PERONEAL) NERVE

The common fibular nerve arises from the posterior division of the sacral plexus (L4–S2) and descends in an inferolateral direction, across the popliteal fossa to the fibular head (Figure 37-4A and B).

- **Common fibular (peroneal) nerve.** Gives rise to a motor branch (innervates the short head of the biceps femoris muscle) and sensory branch **(Lateral sural nerve),** which provides cutaneous innervation to the lateral region of the leg.
  - At the fibular neck the common fibular nerve bifurcates into the deep fibular and superficial fibular nerves.
- **Deep fibular (peroneal) nerve.** Arises from the common fibular nerve and descends in the anterior compartment of the leg with the anterior tibial artery along the interosseous membrane. Provides the following innervation:
  - **Motor.** The muscles in the anterior compartment of the leg (tibialis anterior, extensor digitorum longus, extensor hallucis longus, and fibularis tertius muscles) and dorsum of the foot (extensor digitorum brevis and extensor hallucis brevis muscles).
  - **Sensory.** Provides cutaneous innervation to the skin between digits 1 and 2 on the dorsum of the foot.
- **Superficial fibular (peroneal) nerve.** Arises from the common fibular nerve and descends within the lateral compartment of the leg and provides the following innervation:
  - **Motor.** The muscles in the lateral compartment of the leg: fibularis (peroneus) longus and brevis muscles.
  - **Sensory.** The nerve pierces the deep fascia to enter the skin overlying the anterior compartment of the leg and provides cutaneous innervation to the distal anterolateral leg and dorsum of the foot.

VASCULARIZATION OF THE LEG

BIG PICTURE

The popliteal artery within the popliteal fossa bifurcates into the anterior tibial artery (enters the anterior compartment of the leg) and posterior tibial artery (enters the posterior compartment of the leg) at the inferior border of the popliteus muscle. The anterior and posterior tibial arteries supply blood to the leg and foot.

ANTERIOR TIBIAL ARTERY

The anterior tibial artery arises from the popliteal artery and courses anteriorly through a proximal opening in the interosseous membrane to enter the anterior compartment of the leg (Figure 37-4B). The anterior tibial artery descends along with the deep fibular nerve, crosses the anteriorly over the ankle, and continues as the **dorsalis pedis artery**. The anterior tibial artery supplies blood to structures in the anterior compartment of the leg as well as partial blood supply to the lateral compartment.

POSTERIOR TIBIAL ARTERY

The posterior tibial artery originates off the popliteal artery and immediately gives rise to the fibular artery (Figure 37-4A and B). The posterior tibial and fibular arteries descend deep to the soleus muscle.

- **Posterior tibial artery.** Supplies the posterior compartment of the leg and continues distally through the tarsal tunnel to supply the plantar surface of the foot.
- **Fibular artery.** Descends along the posterior region of the leg by the fibula and supplies the posterior and lateral compartments of the leg.

Anterior compartment syndrome. Anterior compartment syndrome is a medical emergency, which can be caused by a tibial fracture or a high-velocity blow to the anterior compartment of the leg. Injured blood vessels bleed into the closed anterior compartment of the leg. Because the fascia covering the anterior compartment is unable to expand, pressure continues to build, causing restricted blood flow and eventual necrosis of tissues. In severe cases a fasciotomy is performed and the fascia covering the anterior compartment is cut to relieve the pressure. If untreated, anterior compartment syndrome can result in amputation of the limb.

VEINS OF THE LEG

The veins in the leg consist of a superficial and a deep venous system.

- **Great saphenous vein.** Originates from the medial side of the dorsal venous arch in the foot and drains in the femoral vein.
- **Small saphenous vein.** Originates from the lateral side of the dorsal venous arch in the foot and drains in the popliteal vein.
- **Deep venous system.** Consists of as many as three veins associated with each artery with the same name.

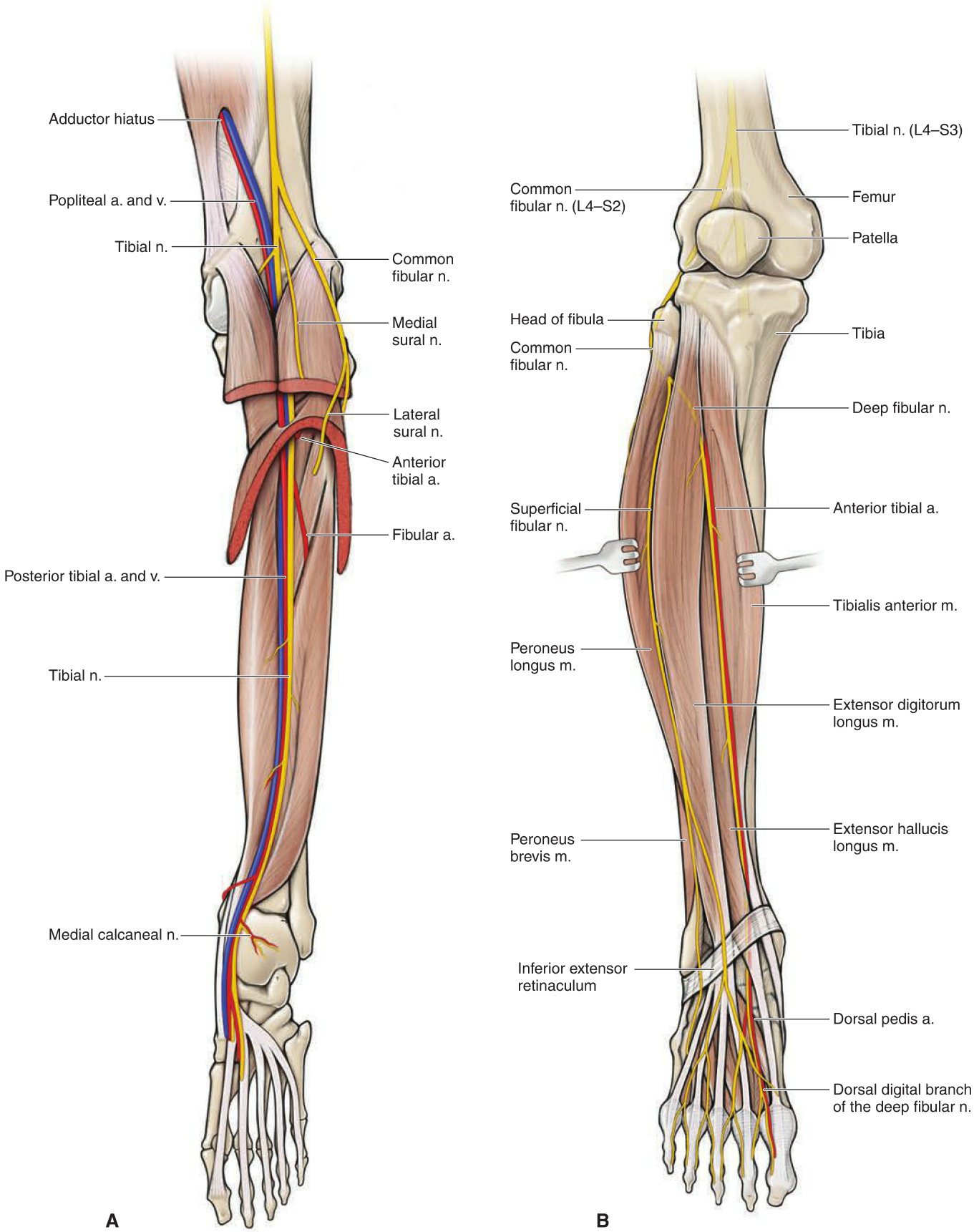

Figure 37-4: A. Posterior view of the leg showing the tibial nerve and the posterior tibial artery. **B**. Anterior view of the leg showing the common fibular nerve and the anterior tibial artery.

JOINTS OF THE LEG AND ANKLE

BIG PICTURE

The boney components of the leg include the tibia and the fibula, which articulate via the proximal and distal tibiofibular joints. Distally, the tibia and fibula articulate with the talus, forming the ankle (talocrural) joint. The ankle joint is a combination of articulations between the tibia and the talus (tibiotalar joint) as well as the fibula and the talus (talofibular joint) (Figure 37-5A and B).

LEG

The primary support of the leg is between the tibia and fibula via the interosseous membrane:

- **Interosseous membrane.** A strong ligament that unites and stabilizes the tibia and fibula along their diaphysis. Additionally the membrane separates the anterior and posterior compartments of the leg.

ANKLE JOINT

The ankle (talocrural) joint is a synovial hinge joint that allows plantarflexion and dorsiflexion. The ankle joint consists of articulations between the tibia and the talus (tibiotalar joint) as well as between the fibula and the talus (talofibular joint). The articulation between the tibia and the fibula (distal tibiofibular joint) forms a mortise into which the talus fits. The ligaments of the distal tibiofibular joint reinforce the mortise.

- **Deltoid ligament.** Located medially on the ankle as a fan-shaped ligament that attaches to the medial malleolus of the tibia and the navicular, talus, and calcaneus. The deltoid ligament limits hypereversion and excessive range of ankle motion.
- **Anterior talofibular ligament (ATFL).** Connect between the lateral malleolus of the fibula and the posterior talus. The ATFL resists anterior translation of the foot on the tibia and inversion when ankle is plantar flexed. The ATFL is the most commonly injured ligament in the ankle as a result of hyperinversion.
- **Posterior talofibular ligament (PTFL).** Connect between the lateral malleolus of the fibula and the posterior talus. The PTFL prevents posterior translation of the foot on the tibia and rotatory subluxation of the talus. The PTFL is the least injured ankle ligament.
- **Calcaneofibular ligament (CFL).** Connect between the lateral malleolus of the fibula and the calcaneus. The CFL resists inversion of the ankle in neutral or dorsiflexed position.

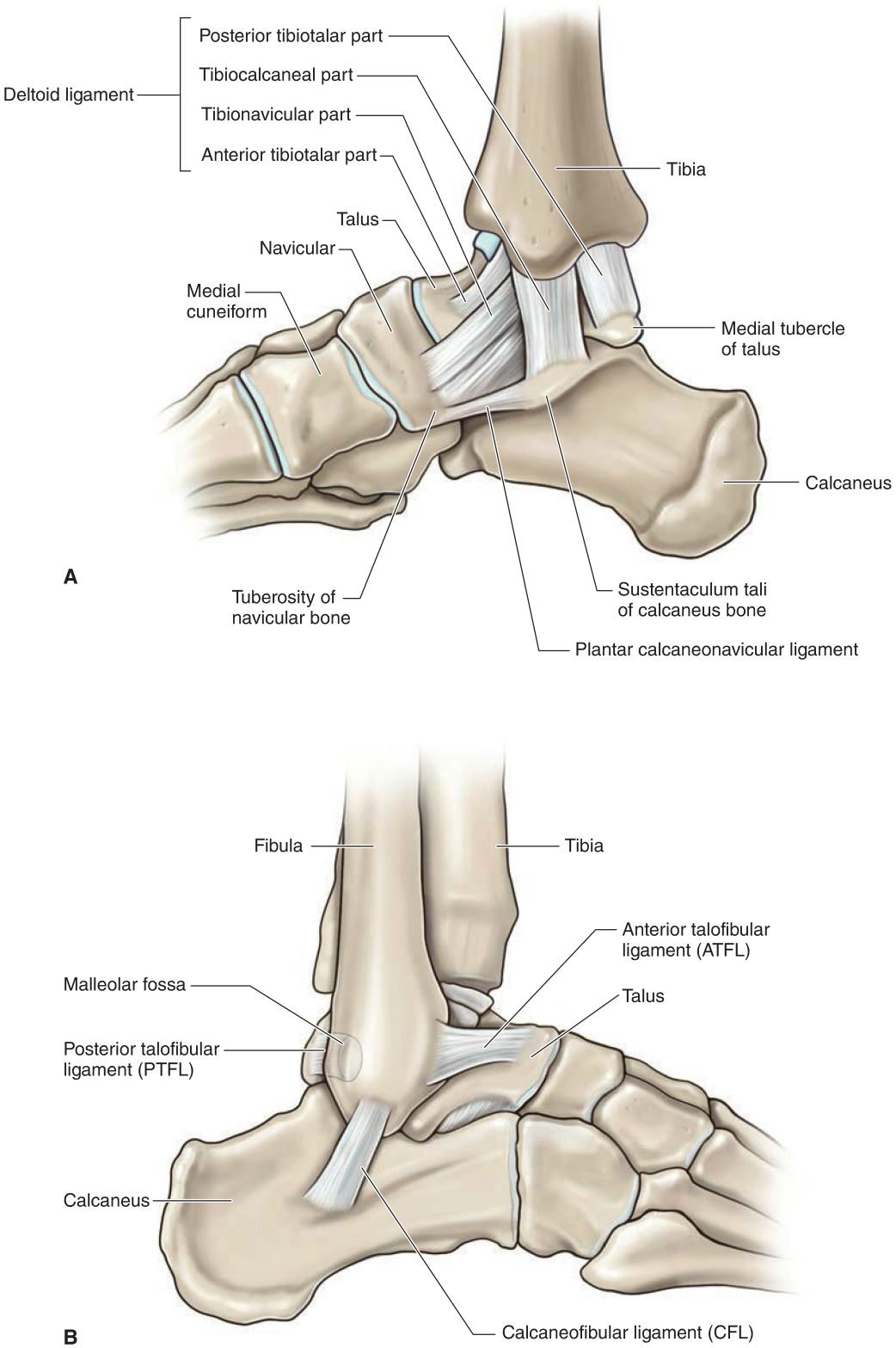

Figure 37-5: (**A**) Medial and (**B**) lateral views of the right ankle joint.

TABLE 37-1. Muscles of the Leg

Muscle	Proximal Attachment	Distal Attachment	Action	Innervation
Anterior compartment of the leg				
Tibialis anterior	Tibia and interosseous membrane	Medial cuneiform and base of metatarsal 1	Dorsiflexion of foot at ankle joint; inversion of foot	Deep fibular n. (L4, L5)
Extensor digitorum longus	Fibula and lateral tibial condyle	Via dorsal digital expansions into digits 2–5	Extension of lateral digits 2–5 and dorsiflexion of foot	Deep fibular n. (L5, S1)
Extensor hallucis longus	Fibula and interosseous membrane	Distal phalanx of great toe	Extension of great toe and dorsiflexion of foot	
Fibularis (peroneus) tertius	Distal part of fibula	Base of metatarsal 5	Dorsiflexion and eversion of foot	
Lateral compartment of the leg				
Fibularis (peroneus) longus	Upper surface of fibula	Medial cuneiform and base of metatarsal 1	Eversion and plantarflexion of foot	Superficial fibular n. (L5, S1, S2)
Fibularis (peroneus) brevis	Lower surface of fibula	Base of metatarsal 5		
Posterior compartment of the leg (superficial group)				
Gastrocnemius	Medial head: superior to medial femoral condyle Lateral head: superior to lateral femoral condyle	Via calcaneal tendon to posterior surface of calcaneus bone	Plantarflexes foot and flexes knee	Tibial n. (S1, S2)
Plantaris	Superior to lateral femoral condyle	Calcaneus		
Soleus	Posterior aspect of tibia (soleal line) and posterior aspect of fibular head and shaft	Via calcaneal tendon to posterior surface of calcaneus bone	Plantarflexes the foot	
Posterior compartment of the leg (deep group)				
Popliteus	Posterior surface of proximal tibia	Lateral femoral condyle	Unlocks knee joint; laterally rotates femur on fixed tibia	Tibial n. (L4, L5, S1)
Flexor hallucis longus	Posterior surface of fibula and interosseous membrane	Distal phalanx of great toe	Flexes great toe	Tibial n. (S2, S3)
Flexor digitorum longus	Tibia	Distal phalanges of digits 2–5	Flexes digits 2–5	
Tibialis posterior	Interosseous membrane, tibia, and fibula	Navicular, all cuneiform bones, and metatarsals 2–4	Inversion and plantarflexion of foot; support of medial arch of foot during walking	Tibial n. (L4, L5)

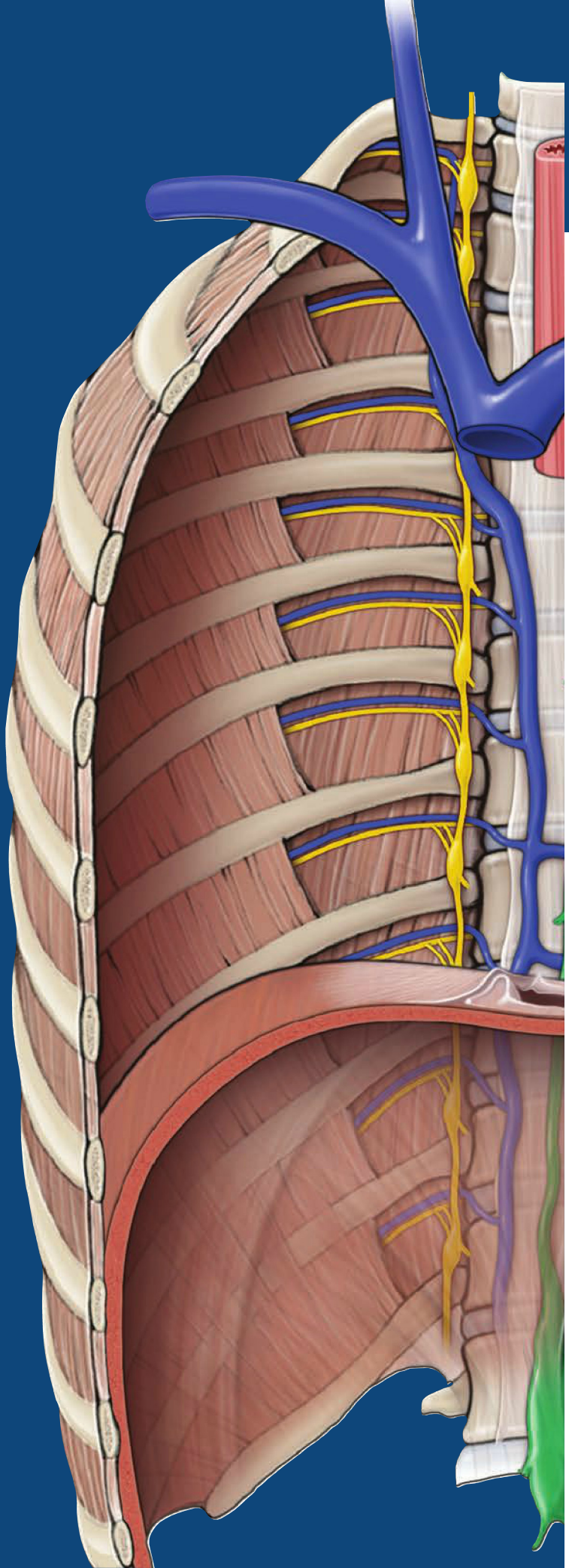

CHAPTER 38

FOOT

Joints of the Digits and Fascia of the Foot 424
Muscles of the Foot 426
Innervation of the Foot 428
Vascularization of the Foot 428
Study Questions 431
Answers 434

JOINTS OF THE DIGITS AND FASCIA OF THE FOOT

BIG PICTURE

The foot is connected to the leg by the ankle (talocrural) joint, which is an articulation between the tibia, fibula, and talus. The foot consists of 7 tarsal bones, 5 metatarsal bones, and 14 phalanges. Motion at the digits for abduction and adduction is defined by an imaginary line along the long axis of the second digit, unlike the hand in which the long axis runs along the third digit. Each digit, with the exception of the great toe, consists of three phalanges (proximal, middle, and distal); the great toe has two phalanges (proximal and distal). The articulations between the bones of the foot create multiple joints. The intrinsic muscles of the foot originate and insert on bones of the foot.

BONES OF THE FOOT

The bones of the foot are as follows (Figure 38-1A):

- **Seven tarsal bones**. Form the bones of the ankle:
  - **Talus.** Forms the tibiotalar joint (dorsi and plantar flexion) with the tibia and transmits forces from the tibia to the calcaneus.
  - **Calcaneus.** The heel bone; possesses attachment with the Achilles (calcaneal) tendon.
  - **Navicular.** Shaped like a boat.
  - **Medial, intermediate, and lateral cuneiform bones.** Wedge-shaped bones that help form the transverse arch of the foot.
  - **Cuboid.** Shaped like a cube; most lateral and distal of the tarsal bones.
- **Five metatarsal bones**. Forms the bones of the sole of the foot; each of the five metatarsal bones are related to one digit. For example, metatarsal 1 to the great toe and metatarsal 5 to the little toe.
- **Fourteen phalanges**. Form the bones of the digits:
  - **Digit 1 (great toe; hallux).** Possesses two digits (a proximal and a distal).
  - **Digits 2 to 5 (the lesser toes).** Possesses three digits (proximal, middle, and distal).

JOINTS OF THE DIGITS

The several bony articulations within the foot assist in accommodating uneven surfaces during weight-bearing activities. These motions of the foot are accomplished via the following joints (Figure 38-1B):

- **Metatarsophalangeal (MTP) joints.** Articulations between the metatarsals and the proximal phalanges. The metatarsophalangeal joints allow **flexion and extension** and **abduction and adduction**.
- **Interphalangeal (IP) joints.** Articulations between the phalanges, which allow for flexion and extension.
  - **Proximal interphalangeal (PIP) joints.** Occur between the proximal and middle phalanges for digits 2 to 5.
  - **Distal interphalangeal (DIP) joints.** Occur between the middle and distal phalanges for digits 2 to 5.
  - **The great toe (digit 1).** Has only a proximal and distal phalange and therefore the joint is simply referred to as the IP joint.

FASCIAL STRUCTURES OF THE FOOT

The following fascial structures help provide support to the tendons, nerves, and vessels that enter and exit the foot (Figure 38-1):

- **Plantar aponeurosis.** A thick band of longitudinally oriented collagen fibers that span between the calcaneus and proximal phalanges and invests the muscles of the plantar surface of the foot.
  - **Function.** When the heal strikes the ground during walking or running the plantar fascia becomes tense, which results in the shortening of the foot and an elevation of the longitudinal arch. This movement ("windlass mechanism") helps to absorb shock and the weight of the body.
- **Superior and inferior extensor retinacula.** Structures that tether the tendons of the tibialis anterior, extensor hallucis longus, extensor digitorum longus, and fibularis (peroneus) tertius muscles.
- **Flexor retinaculum.** Attaches between the medial malleolus and calcaneus bones, forming the roof of the tarsal tunnel. The tendons of the tibialis posterior, flexor digitorum longus, and flexor hallucis longus muscles as well as tibial nerve and posterior tibial artery pass through the tarsal tunnel to enter into the plantar surface of the foot.
  - The tarsal tunnel is homologous to the carpal tunnel in the wrist.
- **Fibular retinacula.** Tethers the tendons of the fibularis (peroneus) longus and brevis muscles on the lateral side of the ankle as they course inferior to the lateral malleolus bone.
- **Dorsal digital expansions.** An aponeurosis covering the dorsum of the digits that attaches proximally to the middle phalanx (digits 2–5) or proximal phalanx (digit 1), via the central band, and distally to the distal phalanx, via the lateral bands.
  - The extensor digitorum longus and brevis muscles and the extensor hallucis longus and brevis muscles attach proximally and centrally to the dorsal digital expansion.
  - The lumbricals and the dorsal and plantar interossei attach on the free edges.
  - Because of the attachment of the muscles and the location of the dorsal digital expansion, the small intrinsic muscles produce flexion at the metatarsophalangeal joint while extending the interphalangeal joints.

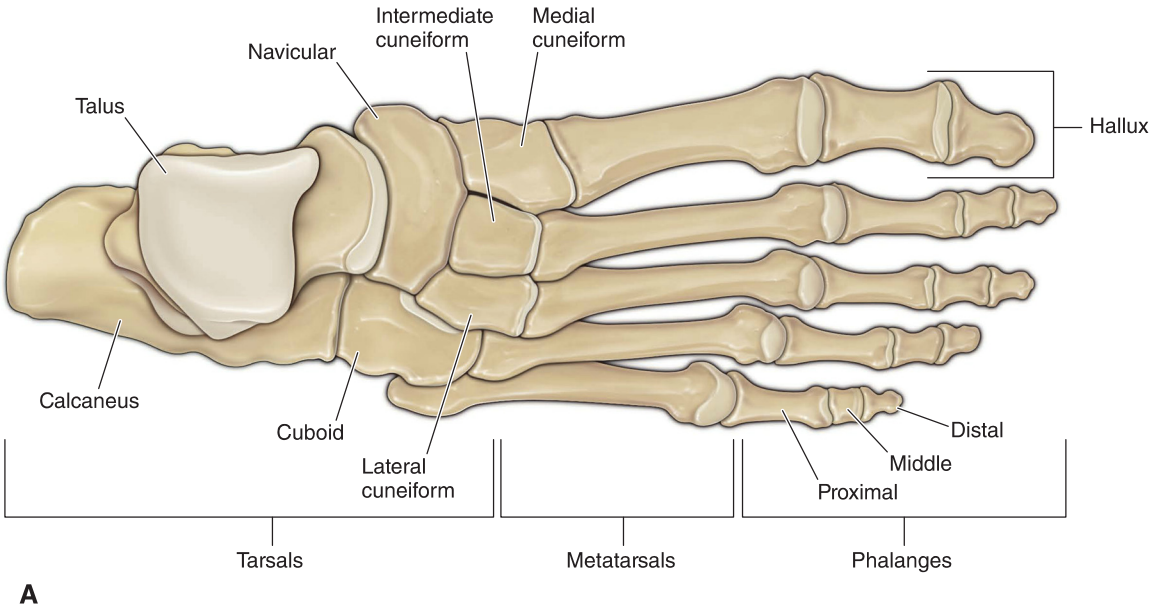

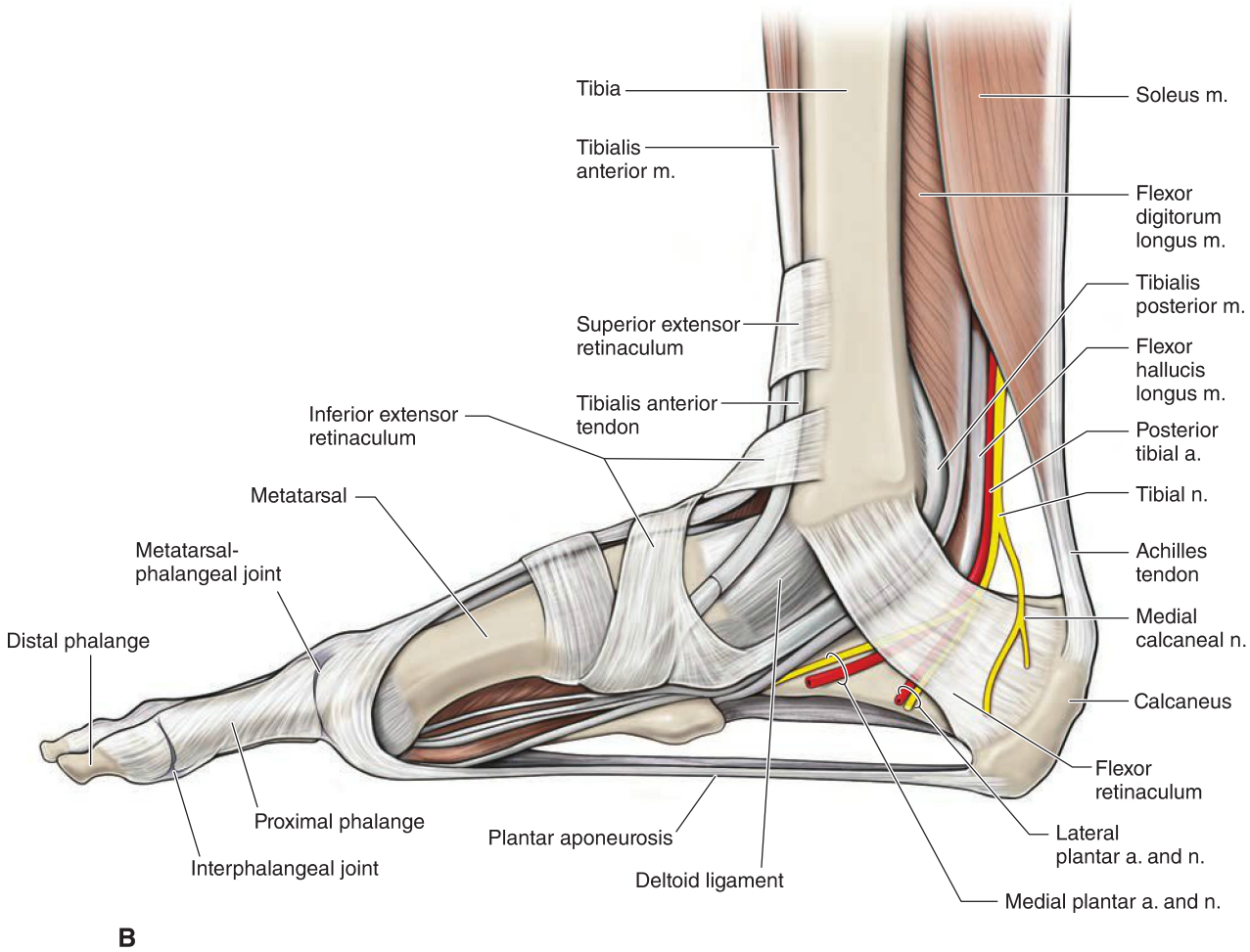

Figure 38-1: A. Superior view of the bones of the foot. **B.** Medial view of the fascia of the right foot.

MUSCLES OF THE FOOT

BIG PICTURE

Muscles that act on the joints of the foot are either extrinsic (originating outside the foot) or intrinsic (originating within the foot), and they may act on a single joint or multiple joints. The result is movement of multiple joints used to accommodate uneven surfaces or for activities such as running or jumping. The intrinsic muscles are discussed in this section, whereas extrinsic muscles are discussed in Chapter 37.

FOOT MUSCLES

These intrinsic muscles of the foot are grouped into four layers on the plantar surface (Table 38-1).

LAYER 1 (FIGURE 38-2A)

- **Abductor hallucis muscle.** Attaches to the calcaneal tuberosity and digit 1. The abductor hallucis muscle abducts and flexes the great toe and is innervated by the medial plantar nerve (S1–S2).
- **Abductor digiti minimi muscle.** Attaches to the calcaneal tuberosity and lateral side of digit 5. The abductor digiti minimi muscle abducts and flexes digit 5 and is innervated by the lateral plantar nerve (S1–S3).
- **Flexor digitorum brevis muscle.** Attaches to the calcaneal tuberosity middle phalanges of digits 2 to 5. The flexor digitorum brevis muscle flexes digits 2 to 5 and is innervated by the medial plantar nerve (S1–S2).

LAYER 2 (FIGURE 38-2B)

- **Lumbricals.** Four small muscles that attach to the tendons of the flexor digitorum longus muscle and the medial aspect of the dorsal digital expansions of digits 2 to 5. They are numbered from the medial side of the foot. The lumbricals flex the MTP and extend the PIP and DIP joints. The lumbricals are dually innervated:
  - **First lumbrical.** Medial plantar nerve (S2–S3)
  - **Second to fourth lumbricals.** Deep branch of the lateral plantar nerve (S2–S3).
- **Quadratus plantae muscle.** Attaches to the calcaneus and posterolateral margin of the flexor digitorum longus tendon. The quadratus plantae muscle assists in flexion of digits 2 to 5 and is innervated by the lateral plantar nerve (S1–S3).

LAYER 3 (FIGURE 38-2C)

- **Flexor digiti minimi brevis muscle.** Attaches to the base of metatarsal 5 and proximal phalanx of digit 5. The flexor digiti minimi brevis muscle flexes the proximal phalanx of digit 5 and is innervated by the superficial branch of the lateral plantar nerve (S2–S3).
- **Flexor hallucis brevis muscle.** Attaches to the plantar surface of the cuboid and lateral cuneiform bones and base of the proximal phalanx of digit 1 (great toe). The flexor hallucis brevis muscle flexes the proximal phalanx of the hallux and is innervated by the medial plantar nerve (S1–S2).
- **Adductor hallucis muscle.** The oblique head attaches to the bases of metatarsals 2 to 4 and the transverse head to metatarsophalangeal joints (plantar ligaments); distally, the muscle attaches to the lateral side of the base of phalanx of digit 1 (hallux; great toe). The adductor hallucis muscle adducts the hallux and is innervated by the deep branch of the lateral plantar nerve (S2–S3).

LAYER 4 (FIGURE 38-2D)

- **Plantar interossei muscle.** Attaches to metatarsals 3 to 5 and the medial sides of the dorsal digital expansions of the proximal phalanges 3 to 5. The plantar interossei muscle adducts and flexes digits 3 to 5 and is innervated by the deep branch of the lateral plantar nerve (S2–S3).
- **Dorsal interossei muscle.** Attaches to the adjacent sides of metatarsals 1 to 5 and the medial side of the dorsal digital expansions of proximal phalanx 2 and to the lateral sides of proximal phalanges 2 to 4. The dorsal interossei muscle abducts and flexes digits 2 to 4 and is innervated by the deep branch of the lateral plantar nerve (S2–S3).

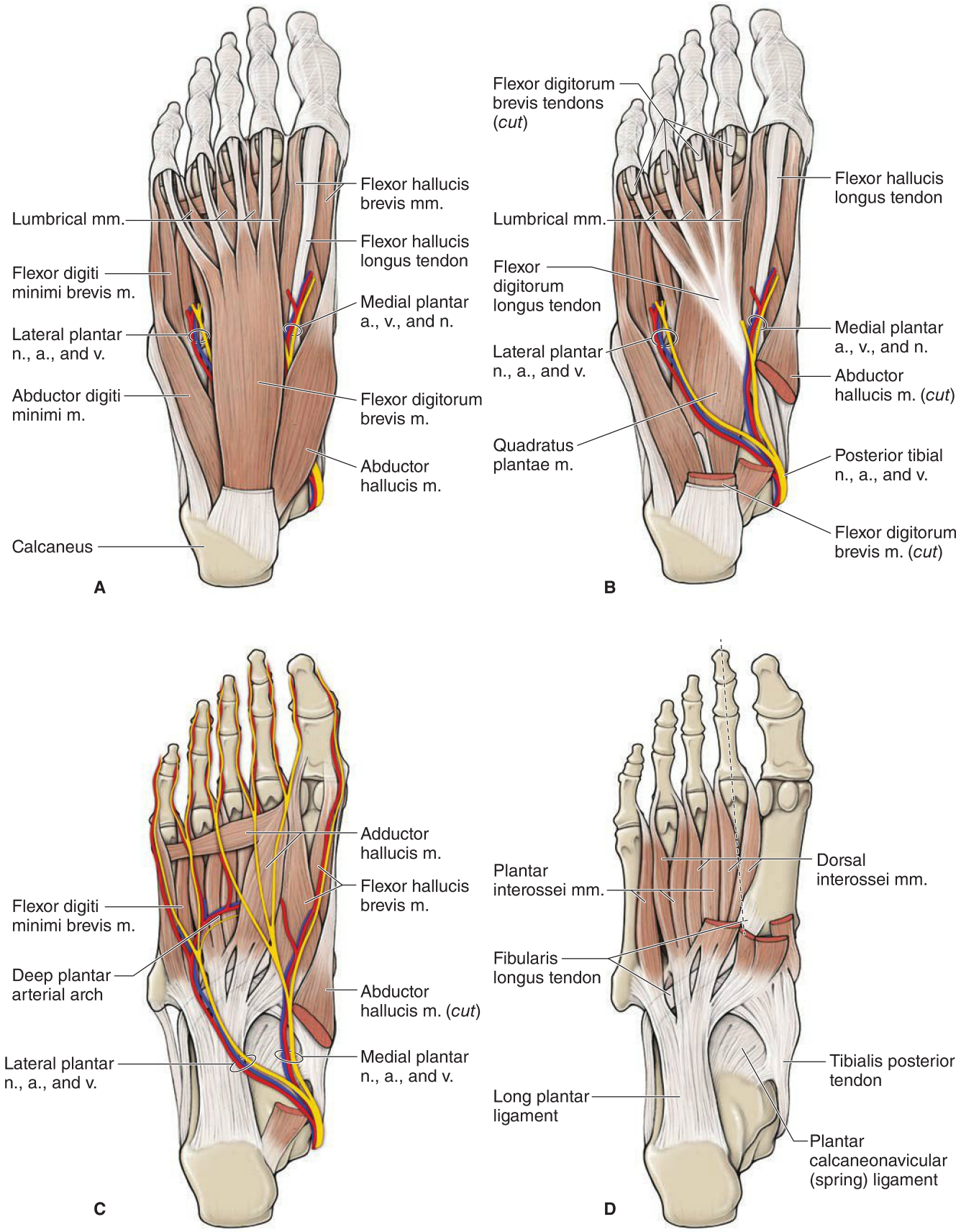

Figure 38-2: Plantar surface of the foot: layer 1 (**A**); layer 2 (**B**); layer 3 (**C**); layer 4 (**D**).

INNERVATION OF THE FOOT

BIG PICTURE

Innervation to the plantar surface of the foot is provided by branches of the tibial nerve (medial calcaneal, medial plantar, and lateral plantar nerves). Innervation of the dorsal surface of the foot is by the superficial and deep fibular nerves.

PLANTAR SURFACE (NERVES)

The tibial nerve courses posterior to the medial malleolus and enters the tarsal tunnel (Figure 38-3A).

- **Medial calcaneal nerve.** Arises in the tarsal tunnel, pierces the flexor retinaculum, and provides cutaneous innervation to the heel (medial, plantar side).

After traversing the tarsal tunnel the tibial nerve immediately divides into the medial and lateral plantar nerves:

- **Medial plantar nerve.** Travels into the sole of the foot, deep to the abductor hallucis muscle and supplies the following:
  - **Sensory.** Medial plantar surface of the foot, digits 1 to 3 and medial region of digit 4.
  - **Motor.** First lumbrical, abductor hallucis, flexor hallucis brevis, and flexor digitorum brevis muscles.
- **Lateral plantar nerve.** Enters the sole of the foot by passing deep to the proximal attachment of the abductor hallucis muscle, between the flexor digitorum brevis and quadratus plantae muscles and supplies the following:
  - **Sensory.** Supplies cutaneous innervation to lateral aspect of the plantar surface of the foot, digit 5, and lateral half of digit 4.
  - **Motor.** Innervates the abductor digit minimi, quadratus plantae, 2 to 4 lumbricals, adductor hallucis, flexor digiti minimi brevis, and dorsal and plantar interossei muscles.

DORSAL SURFACE (NERVES)

The following nerves provide innervation to the dorsal surface of the foot (Figure 38-3B):

- **Superficial fibular (peroneal) nerve.** Provides cutaneous innervation to the dorsum of the foot except in the first web space (between digits 1 and 2).
- **Deep fibular (peroneal) nerve.** Provides cutaneous innervation to the skin in the first web space (between digits 1 and 2); provides motor innervation to the extensor digitorum brevis and extensor hallucis brevis muscles.
- **Saphenous nerve.** A branch of the femoral nerve that provides cutaneous innervation to the medial side of the leg and foot.

VASCULARIZATION OF THE FOOT

BIG PICTURE

The medial and lateral plantar arteries supply the plantar surface of the foot. The dorsalis pedis artery supplies the dorsal surface.

PLANTAR SURFACE (ARTERIES)

The posterior tibial artery courses posterior to the medial malleolus, traverses the tarsal tunnel, and divides into medial and lateral plantar arteries:

- **Lateral plantar artery.** Courses between the quadratus plantae and flexor digitorum brevis muscles; courses across the base of the metatarsals and supplies the plantar surface of the foot; forms an anastomosis with the deep plantar artery to form the deep plantar arch.
- **Medial plantar artery.** Courses along the medial edge of the abductor hallucis muscle, supplying adjacent structures on the medial side of the first metatarsal and great toe.

DORSAL SURFACE (ARTERIES)

On the dorsal surface of the foot the anterior tibial artery crosses the ankle joint and supplies blood to the dorsal side of the foot.

- **Dorsal pedis artery.** Arises at the anterior aspect of the ankle joint as a continuation of the anterior tibial artery and terminates at the first intermetatarsal space; gives rise to the deep plantar artery, which forms an anastomosis with the lateral plantar artery.

▼ **Dorsal pedis pulse.** The dorsal pedis artery pulse is palpated between the extensor hallucis longus and extensor digitorum longus tendons on the dorsal surface of the foot distal to the navicular bone. This artery is examined when assessing whether a patient has peripheral vascular disease or not. ▼

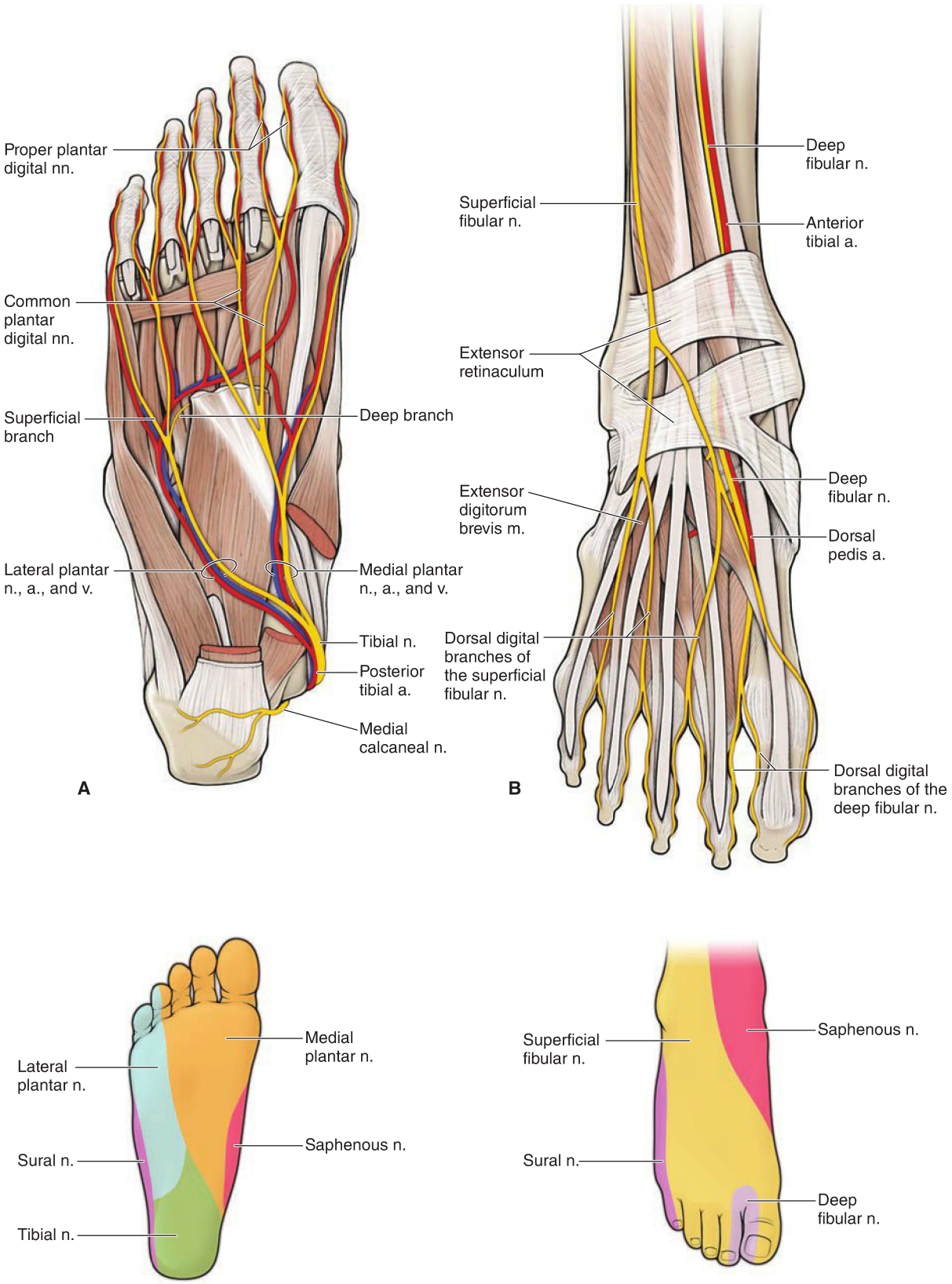

Figure 38-3: Neurovascular supply of the right foot, showing the plantar (**A**) and the dorsal (**B**) surfaces.

TABLE 38-1. Muscles of the Foot

Muscle	Proximal Attachment	Distal Attachment	Action	Innervation
Layer 1				
Abductor digiti minimi	Calcaneal tuberosity	Lateral base of proximal phalanx 5	Abducts and flexes digit 5	Lateral plantar n. (S1–S3)
Flexor digitorum brevis		Both sides of middle phalanges digits 2–5	Flexes digits 2–5	Medial plantar n. (S1–S2)
Abductor hallucis		Medial side of base of proximal phalanx digit 1	Abducts and flexes great toe	
Layer 2				
Lumbricals	Tendons of flexor digitorum longus	Medial dorsal digital expansion digits 2–5	Flex metatarsophalangeal joint and extends proximal and distal interphalangeal joints	Lumbrical 1: medial plantar n. (S2–S3); lumbricals 2–4: lateral plantar n. (S2–S3)
Quadratus plantae	Plantar surface of calcaneus	Tendon of flexor digitorum longus	Assists flexor digitorum to flex digits 2–5	Lateral plantar nerve (S1–S3)
Layer 3				
Adductor hallucis	Oblique head: base of metatarsals 2–4 Transverse head: metatarsophalangeal joints	Lateral side, base of phalanx 1	Adducts digit 1	Lateral plantar nerve (S2–S3)
Flexor digiti minimi brevis	Base of metatarsal 5	Proximal phalanx digit 5	Base of proximal phalanx 5	
Flexor hallucis brevis	Plantar surface of cuboid and lateral cuneiform	Proximal phalanx digit 1	Flexes metatarsophalangeal joint digit 1	Medial plantar n. (S1–S2)
Layer 4				
Plantar interossei	Bases, medial sides of metatarsals 3–5	Medial sides of dorsal digital expansions digits 3–5	Adducts digits 3–5; flexes metatarsophalangeal joints digits 3–5; extends interphalangeal joints digits 3–5	Lateral plantar nerve (S2–S3)
Dorsal interossei	Adjacent sides of metatarsals 1–5	Medial side of dorsal digital expansions digits 2–4	Abducts digits 2–4; flexes metatarsophalangeal joints digits 2–4; extends interphalangeal joints digits 2–4	
Dorsum of foot				
Extensor digitorum brevis	Lateral calcaneus	Dorsal digital expansion digits 2–4	Extends digits 2–4	Deep fibular nerve (S1–S2)
Extensor hallucis brevis		Dorsal digital expansion digits 1	Extends digit 1	

STUDY QUESTIONS

Directions: Each of the numbered items or incomplete statement is followed by lettered options. Select the **one** lettered option that is **best** in each case.

1. A 42-year-old man is admitted to the emergency department in shock and requires a saphenous cut down to receive an infusion. To isolate the great saphenous vein in the ankle region, you would most likely determine its location in which of the following areas?

A. Anterior to the lateral malleolus
B. Anterior to the medial malleolus
C. Posterior to the lateral malleolus
D. Posterior to the medial malleolus

2. A lesion to the lateral cutaneous nerve of the thigh would most likely represent a lesion in which area?

A. Dermatome
B. Cutaneous field

3. The hip is a synovial joint composed of articulations between which of the following structures?

A. Femoral head and acetabulum
B. Femur and tibia
C. Ilium and sacrum
D. Obturator foramen and pelvic outlet
E. Pubis and ischium

4. A 17-year-old boy is admitted to the emergency department after being involved in a motorcycle accident. He has a compound fracture in his right leg, and a thin bone is protruding out of the lateral aspect of his leg. Which of the following bones is most likely seen protruding through the skin of this boy's leg?

A. Calcaneus
B. Femur
C. Fibula
D. Tibia

5. A 29-year-old man is diagnosed with paralysis of the left piriformis muscle. Which of the following actions is the most likely difference between the left and right foot during gait?

A. Left foot points more laterally
B. Left foot points more medially
C. Right foot points more laterally
D. Right foot points more medially

6. A 72-year-old woman is brought to the emergency department after falling in her home. Radiographic studies show that she has fractured her hip. A serious complication of fractures of the femoral neck in the elderly is avascular necrosis of the femoral head. Avascular necrosis usually results from rupture of arteries to the head of the femur. Which of the following is the most likely artery damaged in this patient?

A. Acetabular branch of the obturator artery
B. Deep circumflex iliac artery
C. Inferior gluteal artery
D. Medial circumflex femoral artery
E. Lateral circumflex femoral artery
F. Superior circumflex iliac artery

7. A 34-year-old man is diagnosed with a left internal iliac artery aneurism. As a result, he presents with a left superior gluteal nerve lesion and an accompanying gait disorder. While walking, this patient would most likely compensate by flexing his trunk to the

A. Left, to lift his left lower limb so that his left foot can be lifted off the ground
B. Left, to lift his right lower limb so that his right foot can be lifted off the ground
C. Right, to lift his left lower limb so that his left foot can be lifted off the ground
D. Right, to lift his right lower limb so that his right foot can be lifted off the ground

8. When administering an intramuscular gluteal injection in the superior–lateral quadrant, the health care provider would most likely avoid injury to which of the following nerves?

A. Femoral nerve
B. Genitofemoral nerve
C. Inguinal nerve
D. Obturator nerve
E. Sciatic nerve

9. A 17-year-old football player complains of severe knee pain after being tackled from the side. When the knee is flexed, the tibia can be moved anteriorly. Rupture or tearing of which of the following ligaments would most likely account for this observation?

A. Anterior cruciate ligament
B. Fibular collateral ligament
C. Lateral meniscus
D. Medical meniscus
E. Posterior cruciate ligament
F. Tibial collateral ligament

10. The hospital vascular team physician is instructed to place a central venous line in a patient's femoral vein. The femoral artery is palpated to determine the location of the femoral triangle contents. The contents of the femoral triangle, from lateral to medial, are the

A. Femoral artery, femoral vein, femoral nerve, lymphatics
B. Femoral nerve, femoral artery, femoral vein, lymphatics
C. Femoral vein, femoral artery, femoral nerve, lymphatics
D. Lymphatics, femoral nerve, femoral artery, femoral vein
E. Lymphatics, femoral vein, femoral artery, femoral nerve

11. Most of the muscles of the medial thigh compartment are innervated by the obturator nerve. The exception is the vertical division of the adductor magnus muscle, which is innervated by which of the following nerves?

A. Common fibular (peroneal) nerve
B. Deep fibular (peroneal) nerve
C. Femoral nerve
D. Superficial fibular (peroneal) nerve
E. Tibial nerve

12. The posterior compartment of the thigh primarily receives its blood supply from branches of which of the following arteries?

A. Deep femoral artery
B. Femoral artery
C. Inferior gluteal artery
D. Medial circumflex femoral artery
E. Popliteal artery

13. The biceps femoris muscle receives its name because it has two origins. One attachment is to the linea aspera of the femur. The other attachment is to the

A. Anterior inferior iliac spine
B. Greater trochanter
C. Ischial spine
D. Ischial tuberosity
E. Lesser trochanter
F. Tibial tuberosity

14. During a physical examination, the muscles of the lower limb are tested. For the purpose of this question, only the right lower limb will be considered. You place the patient's leg so that the right knee is bent with the foot resting on the floor. Which muscle group are you testing when you instruct your patient to straighten his leg against resistance?

A. Anterior leg (shin) muscles
B. Anterior thigh (quadriceps) muscles
C. Medial thigh muscles
D. Lateral leg muscles
E. Posterior leg (calf) muscles
F. Posterior thigh (hamstrings) muscles

15. A 28-year-old man sees his health care provider because he is having difficulty with dorsiflexion and has a diminished dorsalis pedis pulse. These symptoms are most likely attributable to swelling in which compartment of the leg?

A. Anterior compartment of the leg
B. Dorsal surface of the foot
C. Lateral compartment of the leg
D. Plantar surface of the foot
E. Posterior compartment of the leg

16. A 17-year-old boy is admitted to the emergency department with a leg fracture. He fell off his motorcycle and tore the interosseous membrane and fractured the proximal fibula. On examination, the patient is found to have decreased cutaneous sensation over the distal lateral aspect of his right leg and over the dorsal aspect of his right foot, with sparing of the space between his first and second digits. The primary motor abnormality you are most likely to observe would be decreased

A. Dorsal flexion
B. Eversion of the foot
C. Inversion of the foot
D. Knee flexion
E. Knee extension
F. Plantar flexion

17. During a physical examination, a 24-year-old woman is instructed to lie supine on the examination table. During the procedure, she is instructed to resist allowing the health care provider to pull her feet downward into plantarflexion. The patient presents with right-sided weakness in this task. Which of the following nerves is most likely responsible for this muscle weakness in this patient?

A. Deep fibular (peroneal) nerve
B. Femoral nerve
C. Lateral plantar nerve
D. Medial plantar nerve
E. Superficial fibular (peroneal) nerve
F. Tibial nerve

18. Which of the following actions would you most likely expect to be the weakest if your patient has a lesion of the tibial nerve in the popliteal fossa?

A. Dorsiflexion of the ankle
B. Extension of the hip
C. Extension of the digits
D. Flexion of the knee
E. Flexion of the digits

19. A 20-year-old woman stepped on a nail and it penetrated the plantar surface of her bare foot, injuring the lateral plantar nerve. Which of the following muscles would most likely be rendered nonfunctional?

A. Abductor hallucis muscle
B. Dorsal interossei muscles
C. First lumbrical muscle
D. Flexor digitorum brevis muscle
E. Flexor hallucis brevis muscle

20. A 38-year-old man is admitted to the emergency department after being involved in an automobile accident. He is unable to abduct or adduct his toes. If this patient has a deficit from a spinal cord lesion, which of the following spinal cord levels is most likely affected by this injury?

A. L1–L2
B. L3–L4
C. L5–S2
D. S1–S2
E. S2–S3

21. A 45-year-old woman is admitted to the emergency department after being involved in an automobile accident. She is experiencing pain, but is conscious. She can feel sensation in the groin, anteromedial leg, and great toe, but not in the calcaneal region. The physicians in the emergency department are concerned that this patient may have a spinal cord lesion at which level?

A. L1
B. L2
C. L3
D. L4
E. L5
F. S1
G. S2
H. S3

ANSWERS

1—B: The great saphenous vein is formed from the dorsal venous arch on the dorsum of the foot. The great saphenous vein then courses anterior to the medial malleolus of the tibia, up the medial aspect of the leg.

2—B: A dermatome is an area of skin supplied by a single spinal cord level. However, a cutaneous field is an area of skin supplied by more than the spinal cord level. The lateral cutaneous nerve of the thigh receives its innervation from spinal cord levels L2 and L3, which represents a cutaneous field.

3—A: The hip is a synovial ball-and-socket joint. It is composed of articulations between the head of the femur and the acetabulum of the os coxa.

4—C: The fibula is the lateral bone in the leg articulating with the tibia. Therefore, the most likely bone seen protruding through the skin would be the fibula. The tibia is not a thin bone and is located more medially. The femur is not located in the leg but in the thigh. The calcaneus is the heal bone.

5—B: The action of the piriformis muscle is lateral rotation of the hip. Therefore, during gait, the left piriformis muscle would laterally rotate the left hip so that the toe points anteriorly. However, in a patient with a paralyzed left piriformis muscle, the toe points more medially because there is a weaker counter contraction from the piriformis muscle.

6—D: The medial circumflex artery is the principal blood supply to the neck and head of the femur. Therefore, in patients with hip fractures, it is the most likely artery that is affected by the injury. The acetabular branch of the obturator artery may also be affected, but its vascular supply diminishes with age.

7—B: The left superior gluteal nerve innervates the gluteus medius and minimus muscles. While walking, the left gluteal muscles will stabilize the pelvis so that the right limb does not droop when swinging. However, if there is a lesion on the superior gluteal nerve, the left gluteal muscles are not functioning, and therefore, the right hip drops. To compensate, the patient will laterally flex the spine to the left so that the right foot will be higher off the ground when walking.

8—E: The sciatic nerve exits the pelvis inferior to the piriformis muscle. Intramuscular gluteal injections may damage the sciatic nerve, and therefore, the ideal position is in the superior–lateral quadrant, which is farthest from the nerve.

9—A: The anterior cruciate ligament prevents anterior translation of the tibia on the femur. Therefore, if the anterior cruciate ligament is injured, the tibia is able to move anteriorly on the femur. This is referred to as an "anterior drawer sign." If the posterior cruciate ligament was damaged, the tibia would be able to move posteriorly on the femur.

10—B: The contents of the femoral triangle are, from lateral to medial, the femoral nerve, femoral artery, femoral vein, and femoral lymph nodes. The acronym *NAVL* may be helpful in remembering the order where the first letter of each word represents the femoral nerve, artery, vein, and lymphatics.

11—E: The vertical division of the adductor magnus muscle is also known as the hamstring division because it receives the same innervation of the hamstring muscles via the tibial nerve.

12—A: The deep femoral artery gives rise to perforating arteries, which pierce through openings in the adductor magnus muscle insertion and provide the primary vascular supply to the posterior thigh compartment. The inferior gluteal artery provides some vascular supply but not as much as the deep femoral artery.

13—D: The biceps femoris muscle is a part of the hamstring group. Each hamstring muscle originates on the ischial tuberosity, which includes the long head of the biceps femoris muscle.

14—B: When the patient is instructed to straighten his leg against resistance, the anterior thigh (quadriceps) muscles are primarily responsible for this action. Therefore, you are testing not only the anterior thigh muscles but also the femoral nerve.

15—A: The anterior compartment of the leg contains the tibialis anterior and other muscles that dorsiflex the ankle. In addition, the anterior tibial artery courses with the deep fibular nerve in the anterior compartment of the leg. Therefore, if compartment syndrome has affected the anterior compartment of the leg, then the dorsiflexors of the ankle would be negatively affected and the dorsalis pedis pulse would diminish.

16—B: The decreased cutaneous sensation of this patient is in the field of the superficial fibular (peroneal) nerve with sparing of the deep fibular (peroneal) nerve (space between digits 1 and 2). Therefore, with injuries involving the superficial fibular (peroneal) nerve, the muscles of the lateral compartment of the leg would be affected, and therefore, eversion of the foot would be weakened.

17—A: When the feet are pulled downward, the dorsiflexion muscles in the anterior compartment of the leg are being tested. If the patient exhibits weakness in this task, the most likely explanation then is lack of innervation from the deep fibular (peroneal) nerve.

18—E: The tibial nerve innervates the posterior compartment of the leg and intrinsic muscles of the feet. Therefore, if there is a nerve lesion within the popliteal fossa, the nerves innervating the posterior muscles of the leg would then be affected. These muscles include the flexor digitorum muscles.

19—B: The dorsal interossei are muscles innervated by the lateral plantar nerve. The other muscles listed as choices (i.e., first lumbrical, abductor hallucis, flexor digitorum brevis, and flexor hallucis brevis muscles) are all innervated by the medial plantar nerve.

20—E: The intrinsic muscles of the feet are innervated by the lateral plantar nerves. The lateral plantar nerve primarily carries motor innervation from the S2–S3 spinal cord levels. L1–L2 would result in weak hip flexion. L3–L4 would result in weak knee extension. L5–S2 would result in weak hip extension and knee flexion, and S1–S2 would result in weak dorsiflexion and plantar flexion.

21—F: The dermatome associated with the calcaneal region is S1. The L1 dermatome is in the groin, and L4 is in the anteromedial leg and great toe. Dermatomes S2 and S3 are posterior to the thigh and gluteal regions.

This page intentionally left blank

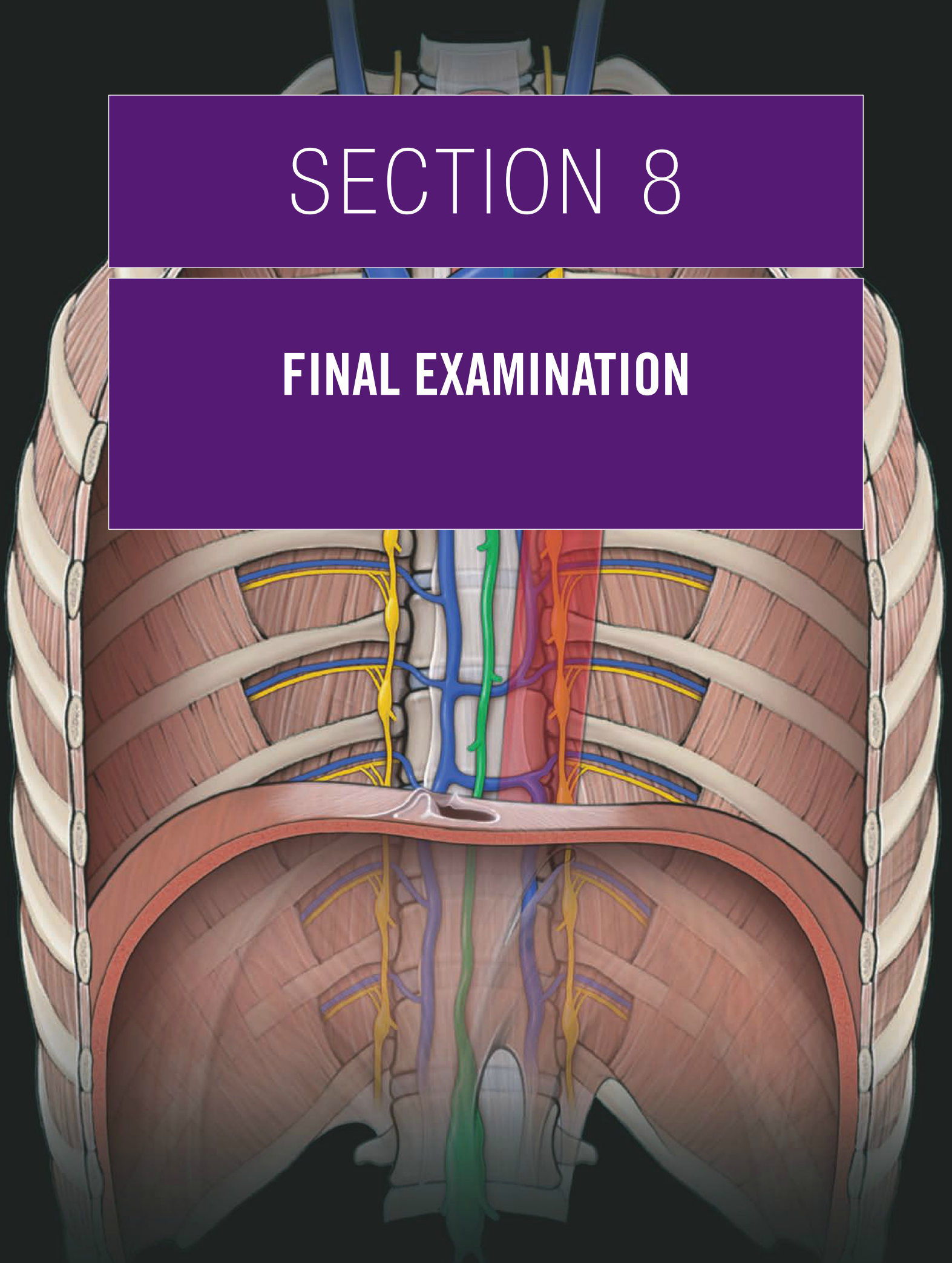

SECTION 8

FINAL EXAMINATION

This page intentionally left blank

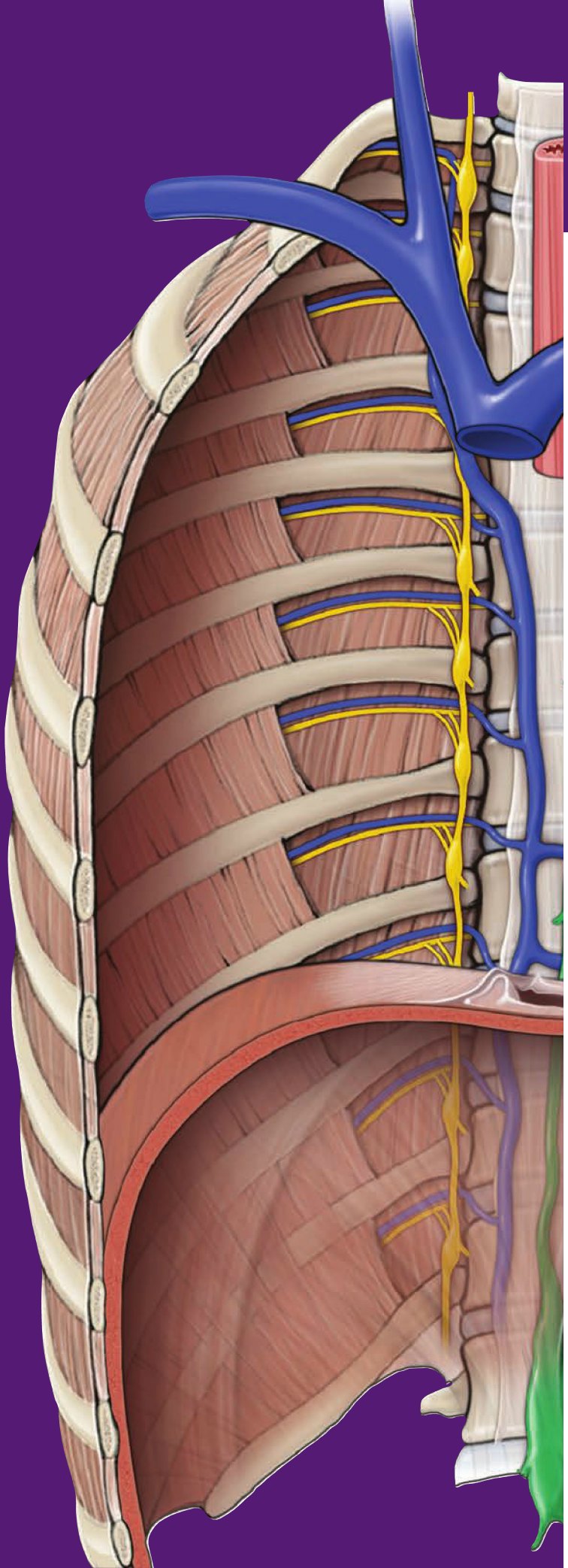

CHAPTER 39

STUDY QUESTIONS AND ANSWERS

DIRECTIONS

Each of the numbered items or incomplete statements is followed by lettered options. Select the **one** lettered option that is **best** in each case.

1. Which of the following structures is the only osteologic connection between the axial skeleton and the upper limb skeleton?

A. Clavicle
B. Humerus
C. Scapula
D. Ulna

2. Damage to which of the following muscles would most likely decrease the stability of the glenohumeral joint?

A. Biceps brachii muscle
B. Infraspinatus muscle
C. Pectoralis major muscle
D. Serratus anterior muscle
E. Triceps brachii muscle

3. Spasm of the scalene muscles may entrap which region of the brachial plexus?

A. Cords
B. Divisions
C. Roots
D. Terminal branches
E. Trunks

4. A 43-year-old man is experiencing spasms of the coracobrachialis muscle, which impinges the nerve that courses through it. Which movement is most likely affected by this muscle spasm?

A. Elbow extension
B. Elbow flexion
C. Shoulder abduction
D. Shoulder adduction
E. Shoulder extension
F. Shoulder flexion

5. The radial and ulnar arteries arise from the bifurcation of which artery?

A. Axillary
B. Brachial
C. Cephalic
D. Deep brachial
E. Subclavian

6. Damage to the posterior cord of the brachial plexus would most likely result in weakness of which of the following muscles?

A. Coracobrachialis
B. Flexor carpi radialis
C. Latissimus dorsi
D. Pectoralis major
E. Supraspinatus

7. Which muscle of the upper limb is innervated by the spinal accessory nerve (cranial nerve [CN] XI)?

A. Levator scapulae
B. Rhomboid major
C. Serratus anterior
D. Splenius capitis
E. Trapezius

8. When a 45-year-old woman performs pushups, the medial border of the right scapula protrudes from her thorax more than it protrudes on the left side. Which nerve is most likely injured, resulting in this observation?

A. Lateral pectoral nerve
B. Long thoracic nerve
C. Medial pectoral nerve
D. Suprascapular nerve
E. Thoracodorsal nerve

9. A 34-year-old woman is diagnosed with quadrangular space syndrome, a rare abnormality localized within the posterior shoulder region. Which of the following structures would most likely be compressed in this patient?

A. Axillary nerve and anterior humeral circumflex artery
B. Axillary nerve and deep brachial artery
C. Axillary nerve and posterior humeral circumflex artery
D. Radial nerve and anterior humeral circumflex artery
E. Radial nerve and deep brachial artery
F. Radial nerve and posterior humeral circumflex artery

10. The suprascapular and dorsal scapular arteries form a collateral circuit on the posterior side of the scapula with which of the following branches of the axillary artery?

A. Anterior humeral circumflex artery
B. Circumflex scapular artery
C. Posterior humeral circumflex artery
D. Thoracoacromial artery
E. Thoracodorsal artery

11. A 77-year-old patient is diagnosed with nerve entrapment, consistent with a herniated disc on the C5 spinal nerve. Which of the following muscles is most likely affected by this herniation?

A. Deltoid
B. Flexor carpi ulnaris
C. Latissimus dorsi
D. Pectoralis minor
E. Triceps brachii

12. Which of the following anatomic regions will most likely *NOT* contribute lymph to the thoracic duct?

A. Left large toe
B. Left thigh
C. Left thumb
D. Right large toe
E. Right thigh
F. Right thumb

13. The boundaries of the three parts of the axillary artery are determined by its relationship to which of the following muscles?

A. Pectoralis major
B. Pectoralis minor
C. Teres major
D. Teres minor

14. A 24-year-old woman comes to the physician because of weakness in elbow flexion and numbness on the lateral side of the forearm. A lesion in which of the following nerves would most likely result in these symptoms?

A. Axillary
B. Median
C. Musculocutaneous
D. Radial
E. Ulnar

15. The superior ulnar collateral artery forms a collateral circuit with which of the following arteries?

A. Anterior ulnar recurrent
B. Anterior interosseous
C. Middle collateral
D. Posterior ulnar recurrent
E. Radial collateral

16. A 39-year-old man is diagnosed with a peripheral nerve injury that weakens his ability to extend his elbow, wrist, and fingers. Which area of this patient's upper limb will cause cutaneous deficit because of this injury?

A. Anterior compartment of the forearm
B. Lateral compartment of the forearm
C. Medial compartment of the forearm
D. Posterior compartment of the forearm

17. A 28-year-old woman is diagnosed with carpal tunnel syndrome. Which of the following tendons course through the carpal tunnel?

A. Flexor carpi radialis
B. Flexor carpi ulnaris
C. Flexor pollicis longus
D. Extensor carpi radialis longus
E. Extensor carpi ulnaris
F. Extensor pollicis longus

18. A 50-year-old woman has difficulty moving her thumb toward the palmar surface of the digiti minimi (fifth digit). She also experiences pain over the palmar surface of the thumb, index, and the middle digits. Pressure and tapping over the lateral portion of the flexor retinaculum cause tingling of the thumb and the second and third digits, indicating nerve damage. The damaged nerve that results in motor and sensory deficits most likely travels via which of the following routes?

A. Between the flexor digitorum superficialis and profundus muscles
B. Between the two heads of the flexor carpi ulnaris muscle
C. Superficial to the flexor retinaculum
D. Through the coracobrachialis muscle
E. Through the supinator muscle

19. The radiocarpal joint includes the distal end of the radius, the triangular fibrocartilage complex, the scaphoid bone, the triquetrum bone, and the

A. Capitate.
B. Hamate.
C. Lunate.
D. Trapezium.

20. Which of the following fascial layers forms the roof of the carpal tunnel?

A. Extensor retinaculum
B. Fibrous digital sheaths
C. Flexor retinaculum
D. Palmar aponeurosis
E. Transverse palmar ligament

21. A 26-year-old woman is diagnosed with inflammation within Guyon's canal. She will most likely experience weakness when performing which of the following actions?

A. Abduction of the thumb
B. Adduction of digits 2 to 5
C. Flexion of the wrist
D. Radial deviation of the wrist

22. Compression of the median nerve in the carpal tunnel results in weakness in the thenar muscles and the first and second lumbricals. In which of the following areas would the patient most likely experience cutaneous deficits?

A. Lateral dorsal surface of the hand
B. Lateral palmar surface of the hand
C. Medial dorsal side of the hand
D. Medial palmar side of the hand

23. Which of the following arteries course through the anatomical snuffbox?

A. Deep palmar arch artery
B. Radial artery
C. Superficial palmar arch artery
D. Ulnar artery

24. Which of the following muscles is primarily responsible for flexion of the metacarpophalangeal joints and extension of the interphalangeal joints of digits 2 to 5?

A. Doral interossei muscles
B. Lumbrical muscles
C. Palmar interossei muscles
D. Palmaris brevis muscles
E. Palmaris longus muscles

25. An avulsion fracture results when a bone fragment is pulled from its parent bone by forceful distraction of a tendon or ligament. An avulsion fracture of the ischial tuberosity most likely results from forceful contraction of which of the following muscles?

A. Adductors
B. Gluteals
C. Hamstrings
D. Iliopsoas
E. Quadriceps femoris

26. A 51-year-old man experiences a loss of skin sensation along the medial compartment of the thigh. No other areas of skin are affected. Which of the following best describes the area of deficit?

A. L2 dermatome
B. L3dermatome
C. L4 dermatome
D. Cutaneous field of the femoral nerve
E. Cutaneous field of the obturator nerve
F. Cutaneous field of the saphenous nerve

27. A 55-year-old man has difficulty extending his hip while walking up a flight of stairs. He experiences no cutaneous deficits. Which damaged nerve is most likely responsible for causing this man's symptoms?

A. Inferior gluteal nerve
B. S1 nerve root
C. S2 nerve root
D. Superior gluteal nerve

28. A 33-year-old man's pelvis drops on the right side when he steps with his right foot. He has no cutaneous deficits. Which nerve lesion is most likely causing this problem?

A. Common peroneal nerve
B. Femoral nerve
C. Inferior gluteal nerve
D. Obturator nerve
E. Superior gluteal nerve
F. Tibial nerve

29. Which of the following structures serves as a common attachment for the external rotator muscles of the hip?

A. Greater trochanter
B. Inferior pubic ramus
C. Ischial spine
D. Ischial tuberosity
E. Lesser trochanter
F. Superior pubic ramus

30. Which of the following is the most stable position of the hip as a result of the tension generated in the capsular ligaments?

A. Abduction
B. Adduction
C. Flexion
D. Extension

31. Which of the following quadriceps femoris muscles flexes the femur at the hip joint?

A. Rectus femoris
B. Vastus intermedius
C. Vastus medialis
D. Vastus lateralis

32. A 31-year-old woman has a lesion on the femoral nerve. Which of the following actions will the patient most likely have difficulty performing?

A. Knee extension
B. Knee flexion
C. Hip abduction
D. Hip adduction
E. Hip extension
F. Hip flexion

33. The hamstring musculature receives its primary vascular supply from which branch of the deep femoral artery?

A. Medial circumflex femoral branch
B. Lateral circumflex femoral branch
C. Perforating branches
D. Transverse branch

34. Which of the following ligaments primarily resist posterior translation of the tibia on the femur?

A. Anterior cruciate
B. Lateral collateral
C. Medial collateral
D. Posterior cruciate

35. Which of the following nerves can be found deep to the soleus muscle?

A. Common fibular
B. Deep fibular
C. Femoral
D. Obturator
E. Superficial fibular
F. Tibial

36. A 22-year-old man experiences weakness in ankle dorsiflexion and numbness of the skin between digits 1 and 2 of his foot. Which of the following nerves is most likely damaged, resulting in these observed deficits?

A. Common fibular nerve
B. Deep fibular nerve
C. Femoral nerve
D. Obturator nerve
E. Superficial fibular nerve
F. Tibial nerve

37. Which of the following arteries courses through the proximal part of the interosseous membrane?

A. Anterior tibial
B. Fibular
C. Popliteal
D. Posterior tibial

38. "Rolling the ankle" is a common injury that causes excessive inversion and plantar flexion of the foot. Which of the following ligaments would experience the most damage during such an event?

A. Anterior talofibular
B. Anterior tibiofibular
C. Deltoid
D. Posterior tibiofibular

39. Which of the following fascial structures forms the roof of the tarsal tunnel?

A. Inferior extensor retinaculum
B. Fibular retinaculum
C. Flexor retinaculum
D. Superior extensor retinaculum
E. Talofibular ligament

40. A 51-year-old woman has difficulty abducting and adducting digits 2 to 5 of her foot. In addition, the skin on the plantar surface of digits 4 and 5 is numb. Which of the following nerves is most likely damaged, resulting in these deficits?

A. Deep peroneal
B. Lateral plantar
C. Medial plantar
D. Superficial peroneal
E. Tibial

41. Which of the following arteries most likely gives rise to the deep plantar arch?

A. Arcuate
B. Dorsal pedal
C. First dorsal metatarsal
D. Lateral plantar
E. Medial plantar

42. Which of the following joints is most likely responsible for inversion and eversion of the foot?

A. Calcaneonavicular joint
B. Metatarsophalangeal joint
C. Subtalar joint
D. Talofibular joint
E. Tibiotalar joint

43. A 62-year-old man with portal hypertension caused by alcoholic cirrhosis is taken to the emergency department. He has been vomiting blood as a result of hemorrhage of the gastroesophageal plexus of veins. Which other veins would most likely be enlarged in this patient?

A. Gonadal
B. Iliac
C. Pudendal
D. Rectal
E. Suprarenal

44. In a healthy person, blood from the pulmonary veins flows next into which of the following structures?

A. Aortic arch
B. Left atrium
C. Left ventricle
D. Lungs
E. Pulmonary arteries
F. Pulmonary veins
G. Right atrium
H. Right ventricle

45. A Doppler echocardiogram evaluates blood flow, speed, and the direction of blood within the heart and also screens for any leakage of the four valves. If heart function during systole was being studied, which valves would the Doppler echocardiogram detect to be open?

A. Mitral and aortic
B. Mitral and pulmonary
C. Mitral and tricuspid
D. Pulmonary and aortic
E. Pulmonary and mitral
F. Pulmonary and tricuspid

46. A 52-year-old man visits the office of his family physician. On auscultation, a systolic murmur is heard in the right second intercostal space adjacent to the sternum. What is the most likely cause of this murmur?

A. Prolapsed aortic valve
B. Prolapsed mitral valve
C. Prolapsed tricuspid valve
D. Stenotic aortic valve
E. Stenotic mitral valve
F. Stenotic tricuspid valve

47. An 8-year-old boy is diagnosed with aortic coarctation (narrowing of the aorta) beyond the left subclavian artery. Aortic coarctation is a congenital abnormality most commonly diagnosed at birth, but it occasionally remains undetected until later in life. Collateral circulation through which of the following vessels is most likely responsible for this coarctation to have remained undetected for so long?

A. Azygos vein
B. Axillary artery
C. Intercostal arteries
D. Internal thoracic vein

48. A 52-year-old woman is diagnosed with gastric cancer. During surgery to remove the cancerous tissue, regional lymph nodes were removed to assist in staging the cancer. Lymph nodes associated with which of the following vessels were most likely sampled from this patient?

A. Celiac artery
B. External iliac arteries
C. Inferior mesenteric artery
D. Portal vein
E. Right renal vein
F. Superior mesenteric vein

49. A 25-year-old woman involved in a motor vehicle accident is brought to the emergency department complaining of abdominal pain. Radiographic imaging of her abdomen reveals a hematoma in the retroperitoneal space. Trauma to which abdominal structure is most likely responsible for this finding?

A. Jejunum
B. Liver
C. Pancreas
D. Esophagus
E. Transverse colon

50. A 55-year-old man undergoes a colonoscopy, which reveals multiple polyps in the descending and sigmoid colons. Because polyps may develop into cancer, the polyps or the regions of the bowel with multiple polyps are often surgically removed. The surgeon will most likely ligate which of the following arteries when removing the affected portion of bowel?

A. Celiac trunk
B. External iliac artery
C. Inferior mesenteric artery
D. Internal iliac artery
E. Superior mesenteric artery

51. The primary vascular supply to the uterus is most likely from branches of which of the following arteries?

A. External iliac
B. Femoral
C. Gonadal
D. Internal iliac
E. Pudendal

52. During sexual intercourse, male ejaculation is associated with innervation provided by which of the following nerves?

A. Genitofemoral
B. Ilioinguinal
C. Lesser splanchnic
D. Pelvic splanchnic
E. Sacral splanchnic

53. A 49-year-old woman visits her physician with a complaint of loss of the ability to sense temperature and touch on the right side of the anterior tongue. She says that she has all sensations of taste. Which additional finding might you also observe in this patient?

A. Adducted eye
B. Loss of corneal reflex
C. Reduced gag reflex
D. Tongue deviation during protrusion
E. Weakness in the masseter muscle

54. A radiographic image of the brain of an 84-year-old woman reveals a berry aneurysm in the anterior communicating cerebral artery. The aneurysm is most likely adjacent to which of the following arteries?

A. Anterior cerebral
B. Basilar
C. Middle cerebral
D. Posterior communicating
E. Vertebral

55. A 26-year-old woman goes to a clinic because she has noticed a loss of cutaneous sensation on one side of her face. Which cranial nerve is most likely affected that results in this patient's condition?

A. Abducens
B. Trigeminal
C. Facial
D. Glossopharyngeal
E. Vagus

56. A 51-year-old woman is experiencing ptosis and mydriasis of the left eye. Which additional finding would most likely be present in this patient (assume the left side of the head for each of the following)?

A. Inability to look laterally
B. Inability to accommodate the lens
C. Loss of salivary glands
D. Loss of sweat glands to the face
E. Reduced gag reflex
F. Reduced production of tears

57. When the physician is testing cranial nerves, the patient is often asked to stick the tongue straight out of the mouth. Which of the following muscles is most likely responsible for this action?

A. Anterior digastricus
B. Genioglossus
C. Mylohyoid
D. Palatoglossus
E. Posterior digastricus

58. The maxillary artery gains entrance to the pterygopalatine fossa and eventually the nasal cavity and infraorbital canal via which of the following structures?

A. Foramen rotundum
B. Foramen spinosum
C. Mandibular foramen
D. Pterygomaxillary fissure
E. Superior orbital fissure

59. The pterygopalatine ganglion most likely houses postganglionic neuronal cell bodies for visceral motor parasympathetic components of which of the following cranial nerves?

A. CN III
B. CN V
C. CN VII
D. CN IX
E. CN X

60. During general surgical procedures, anesthetics and muscle relaxants are used routinely. However, these drugs may decrease nerve stimulation to skeletal muscles, including the intrinsic muscles of the larynx, which results in closure of the vocal folds. In such cases, laryngeal intubation is necessary. Because of the effect of the anesthetics, which of the following intrinsic muscles of the larynx will most likely *NOT* maintain an open glottis?

A. Cricothyroid
B. Lateral cricoarytenoid
C. Posterior cricoarytenoid
D. Thyroarytenoid
E. Transverse arytenoid

61. During an inferior alveolar nerve block, the dentist must avoid damaging the inferior alveolar artery, which enters the mandibular foramen posterior to its associated nerve. The inferior alveolar artery originates in which of the following arteries?

A. Facial
B. Infraorbital
C. Lingual
D. Maxillary
E. Supraorbital

62. A 37-year-old woman complains of hoarseness of several weeks' duration. Upon further examination, the physician determines that the patient has partial paralysis of her vocal cords. Radiographic studies confirm an aortic arch aneurysm. Which of the following most accurately describes the relationship between the patient's symptoms and hoarseness and this further finding?

A. Direct contact of the aneurysm with the trachea in the superior mediastinum
B. Injury to that part of the sympathetic chain that provides sensory innervation to the larynx
C. Irritation of the left phrenic nerve as it crosses the arch of the aorta on its way to the diaphragm
D. Pressure of the aneurysm on the esophagus in the posterior mediastinum
E. Pressure on the left recurrent laryngeal nerve, which wraps around the aortic arch

63. A 55-year-old man visits his physician because he is experiencing paralysis of all of the extraocular eye muscles and a loss of sensation of the root of the nose, upper eyelid, and forehead. Examination shows an abolition of the corneal reflex, but the patient's vision is not impaired. The most likely cause of this condition would be a fracture of which of the following structures?

A. Foramen rotundum
B. Internal acoustic meatus
C. Superior orbital fissure
D. Pterygopalatine fossa
E. Maxillary sinus

64. A 26-year-old woman involved in an automobile accident was thrown into the windshield and sustained a deep gash to her face, just lateral to her upper lip. The facial artery was severed, resulting in substantial arterial bleeding. At which location, apart from the wound itself, would pressure most likely be placed to inhibit the bleeding in this patient?

A. Internal carotid artery just inferior to the mandible
B. Medial canthus of the eye
C. Midpoint of the neck just posterior to the sternocleidomastoid muscle
D. Skin overlying the mandible just anterior to the masseter muscle attachment
E. Temporal region anterior to the ear

65. When looking through an otoscope, the physician is able to view the tympanic membrane. Which structure is most likely attached to the center of the tympanic membrane on its internal surface?

A. Cochlea
B. Incus
C. Malleus
D. Stapes
E. Tensor tympani muscle

66. An 84-year-old woman is brought to the emergency department because her son thinks she has had a stroke because of the paralysis on the right side of the woman's body. Neurologic studies show that an intracerebral hemorrhage has interrupted the blood supply to the posterior part of the frontal lobe, the parietal lobe, and medial portion of the temporal lobe of the left cerebral hemisphere. Which vessel most likely caused the stroke in this patient?

A. Anterior cerebral artery
B. Middle cerebral artery
C. Posterior cerebral artery
D. Middle meningeal artery
E. Vertebral artery

67. In the cervical region, the phrenic nerve courses along the anterior surface of which of the following muscles?

A. Anterior scalene
B. Middle scalene
C. Posterior scalene
D. Sternocleidomastoid
E. Trapezius

68. A 30-year-old woman has become anemic because she has been having severe anterior epistaxis (nose bleed) on the nasal septum. An ear, nose, and throat specialist has been called to consult about the woman's bleeding. It is necessary to surgically ligate the nasal arteries in this patient. The specialist must consider arterial branches from the maxillary and ophthalmic arteries as well as which other artery?

A. Ascending pharyngeal
B. External carotid
C. Facial
D. Internal carotid
E. Lingual

69. A 2-year-old boy is diagnosed with torticollis involving the right sternocleidomastoid muscle. Which of the following anatomic changes is most likely to occur in this patient?

A. Head extended backward in the midline
B. Head flexed forward in the midline
C. Head rotated to the left
D. Head rotated to the right

70. A 46-year-old woman is diagnosed with a tumor of the parotid gland. Which of the following functions is most likely to be disrupted by this lesion (assume the left side for each choice)?

A. Corneal sensation
B. Elevation of the shoulder
C. Facial sensation
D. Protrusion of the tongue
E. Taste to the anterior tongue
F. Wrinkling of the forehead

71. To clinically test the superior oblique muscle of the eye, the physician would most likely have the patient look

A. Laterally.
B. Laterally and then downward.
C. Laterally and then upward.
D. Medially.
E. Medially and then upward.
F. Medially and then downward.

72. During a physical examination, the patient is instructed to look laterally and then upward. Which extraocular muscle is being tested in this patient?

A. Inferior oblique
B. Inferior rectus
C. Lateral rectus
D. Medial rectus
E. Superior oblique
F. Superior rectus

73. A 63-year-old woman visits her physician for a routine physical examination. During the examination, the physician touches the patient's scalp with a pin near the hairline to test for cutaneous sensation. Which of the following nerves is the physician most likely testing?

A. CN IV
B. CN V
C. CN VI
D. CN VII
E. CN VIII
F. CN IX
G. CN X

74. A 23-year-old man is brought to the emergency department after being involved in an automobile accident. Examination shows that the patient has an intracranial hemorrhage resulting from lateral trauma to the skull in the region of the pterion. Which of the following is the most likely location for the hemorrhage?

A. Immediately superficial to the dura mater
B. Immediately deep to the dura mater
C. Within the subarachnoid space
D. Within the brain parenchyma

75. A 32-year-old man with carcinoma of the testis undergoes exploratory surgery to biopsy lymph nodes. Which of the following lymph nodes is being sampled to determine if the cancer has metastasized via the lymphatic system?

A. External iliac
B. Femoral
C. Internal iliac
D. Paraaortic
E. Superficial inguinal

76. A 20-year-old woman is brought to the emergency department after being involved in an automobile accident. Physical examination reveals hypotension and tenderness along the left midaxillary line. Radiographic imaging reveals a large swelling below the left costal margin, and ribs 9 and 10 are fractured near their angles. Which of the following abdominal organs was most likely injured as a result of this accident?

A. Descending colon
B. Left kidney
C. Pancreas
D. Spleen
E. Stomach

77. During sexual arousal, an erection is caused by a dilation of arteries filling the erectile tissue of the penis. These arteries are innervated by which of the following nerves?

A. Genitofemoral
B. Iliohypogastric
C. Parasympathetic
D. Pudendal
E. Sympathetic

78. The functional significance of the marginal artery of Drummond is anastomosis among which of the following vessels?

A. Arteries supplying the colon
B. Arteries supplying the liver
C. Lymphatics draining the kidneys
D. Lymphatics draining the pancreas
E. Veins draining the bladder
F. Veins draining the posterior abdominal wall

79. A 40-year-old man undergoes a vasectomy. After the procedure, when the patient has an orgasm during sexual intercourse, he will most likely

A. No longer have an ejaculate
B. Still have an ejaculate, and the ejaculate will contain sperm
C. Still have an ejaculate, but the ejaculate will not contain sperm

80. A 70-year-old-man has a 90% blockage at the origin of the inferior mesenteric artery. This blockage rarely results in intestinal angina because of collateral arterial supply. Which of the following arteries is the most likely additional source of blood to the descending colon?

A. Left gastroepiploic
B. Middle colic
C. Sigmoid
D. Splenic
E. Superior rectal

81. The mesoappendix is a fold of mesentery that contains an artery that is most likely a direct branch of which of the following?

A. Celiac trunk
B. Ileocolic artery
C. Middle colic artery
D. Right colic artery
E. Superior mesenteric artery

82. A 50-year-old woman is diagnosed with severe obstructive jaundice. Blockage of which of the following structures would most likely result in her condition?

A. Common hepatic duct
B. Pancreatic duct
C. Parotid duct
D. Submandibular duct
E. Thoracic duct

83. A 22-year-old man is admitted to the emergency department after being stabbed with a knife. The laceration is 8 cm long and involves the right cheek, from the right ear to near the corner of the mouth. Which of the following structures is most likely injured?

A. Lingual artery
B. Mandibular branch of facial nerve
C. Parotid duct
D. Submandibular duct
E. Superficial temporal artery

84. A 61-year-old man is diagnosed with an acute stroke. His primary deficit is a partial loss of the visual field as a result of a lesion in the occipital lobe. Which of the following arteries is most likely to be involved?

A. Anterior cerebral
B. Internal carotid
C. External carotid
D. Middle cerebral
E. Posterior cerebral

85. A 4-year-old boy is taken to the pediatrician because of recurrent ear infections. Tubes were placed in the tympanic membranes in the boy's ears three days ago, and he is now complaining of difficulty in tasting sweet foods. Which nerve was most likely disrupted during the insertion of the tubes that resulted in these findings?

A. Chorda tympani
B. Greater petrosal
C. Lesser petrosal
D. Vagus
E. Vestibulocochlear

86. A 4-year-old girl is brought to the pediatrician because she has pain in the left ear. Examination reveals acute otitis media. Which nerve is responsible for conducting the painful sensation from the internal surface of the tympanic membrane to the brain?

A. CN VII
B. CN VIII
C. CN IX
D. CN X
E. CN XI

87. An emergency cricothyroidotomy is warranted when an airway collapses or when severe laryngoedema occurs. Which of the following is the most accurate description of the location of the cricothyroid membrane?

A. Immediately inferior to the cricoid cartilage
B. Immediately inferior to the hyoid bone
C. Immediately inferior to the thyroid cartilage
D. Immediately superior to the hyoid bone
E. Immediately superior to the thyroid cartilage

88. A 49-year-old woman visits her physician because of severe nose bleeds. Which major blood supply to the nasal cavity would need to be occluded to correct this patient's condition?

A. Ethmoidal artery
B. Facial artery
C. Greater palatine artery
D. Sphenopalatine artery
E. Superior labial artery

89. A 52-year-old man is brought to the emergency department because he is experiencing severe chest pain in the mediastinum. He says that 3 weeks ago he was treated for an abscess in the left mandibular molar. Studies determine that the chest pain is the result of an infection in the mediastinum. Which of the following is the most likely space that infection spread through to course from the mandibular region to the mediastinum?

A. Carotid
B. Masticator
C. Pretracheal
D. Retropharyngeal
E. Suprasternal

90. A 14-year-old girl arrives at the dentist's office to have a cavity in her lower right incisor filled. Which nerve will the dentist most likely block before beginning the procedure?

A. CN V-1
B. CN V-2
C. CN V-3

91. A radiologist is conducting a contrast study of the pulmonary circulation on a 41-year-old man. What is the most likely number of veins observed entering the left atrium?

A. Two
B. Three
C. Four
D. Five
E. Six

92. A 55-year-old woman undergoes surgery of the lateral abdominal wall. The surgeon entering the cavity will be careful to avoid injury to vessels and nerves within the abdominal wall. The vessels and nerves will most likely be located deep to which of the following structures?

A. External oblique muscle
B. Internal oblique muscle
C. Superficial fascia
D. Transverse abdominis muscle
E. Transversalis fascia

93. During surgery of a 60-year-old man, the anterior rectus muscle sheath between the xiphoid process and the umbilicus is incised. In this region, the rectus sheath is derived from which of the following muscles?

A. External oblique muscle
B. External and internal oblique muscles
C. Internal oblique muscle
D. Internal oblique and transverse abdominis muscles
E. Transverse abdominis muscle

94. In a healthy person, blood from the left ventricle would most likely flow next into which of the following structures?

A. Aortic arch
B. Left atrium
C. Left ventricle
D. Right atrium
E. Right ventricle
F. Pulmonary arteries
G. Pulmonary veins

95. One aspect of the physical examination is measuring the jugular venous pressure (JVP). The JVP appears as a pulse in the neck by the external jugular vein. Therefore, the JVP is produced by the venous system, not the arterial system, because of the right atrial contraction. There are no valves in the superior vena cava. Therefore, during diastole, some blood is pushed, in a pulsating fashion, back out of the right atrium and up the superior vena cava, all the way to the external jugular vein. The JVP is only pathologic if the pulse is observed too high up the neck, indicating an overload or backup of blood entering the heart. An abnormally high JVP can be caused by several conditions. Which of the following conditions is most likely to cause an abnormally high JVP?

A. Left-sided heart failure
B. Mitral valve prolapse (regurgitation or backflow of blood)
C. Right atrial fibrillation (uncoordinated contraction)
D. Tricuspid valve stenosis (narrowing)

96. A 22-year-old man visits his physician and is diagnosed with a herniated disc impinging the spinal nerve that exits inferior to the C6 vertebra. Pain from the impinged nerve would most likely radiate to which cutaneous region?

A. Lateral shoulder
B. Lateral surface of digit 5
C. Medial surface of the elbow
D. Medial surface of the manubrium
E. Palmar surface of digit 3
F. Palmar surface of the thumb

97. A 51-year-old man visits his physician with a complaint of back pain that the man says resulted from bending over and picking up a heavy box without bending his knees. Which of the following muscles was most likely injured in this patient?

A. Iliocostalis
B. Latissimus dorsi
C. Rhomboid major
D. Serratus posterior inferior
E. Trapezius

98. A 61-year-old woman visits her physician with a complaint of shortness of breath. Physical examination reveals cyanosis and an enlarged right ventricle. Which of the following structures is most likely obstructed in this patient?

A. Bronchial arteries
B. Bronchioles
C. Coronary arteries
D. Coronary sinus
E. Pulmonary arteries
F. Pulmonary veins

99. Heart murmurs are abnormal heart sounds caused by turbulent blood flow. They are often associated with pathologic heart valves. The murmurs are generally organized into the following categories:

- *Systolic murmurs* occur during ventricular contraction.
- *Diastolic murmurs* occur during atrial contraction (ventricular relaxation and filling).

The two common causes of murmurs are valve stenosis and valve regurgitation (prolapse):

- *Valve stenosis* occurs when the valve becomes narrower. During contraction, the blood is forced through a smaller opening and the flow becomes turbulent, causing the extra heart sound.
- *Valve regurgitation* occurs when the valve is unable to close completely and thus becomes incompetent, allowing blood to flow in reverse, back through the valve. This murmur occurs when the affected valve is supposed to be closed.

Which of the following would most likely present as a diastolic murmur?

A. Aortic valve stenosis
B. Mitral valve regurgitation
C. Pulmonary valve stenosis
D. Tricuspid valve stenosis

100. *Neisseria meningitidis* and *Streptococcus pneumoniae* are the leading causes of bacterial meningitis. To confirm diagnosis of bacterial meningitis, cerebrospinal fluid (CSF) is most likely obtained from which of the following regions?

A. Epidural space
B. Intervertebral foramen
C. Subarachnoid space
D. Subdural space
E. Subpial space

ANSWERS

1–A: The clavicle connects the manubrium of the sternum to the acromion of the scapula.

2–B: The infraspinatus is a rotator cuff muscle that stabilizes the glenohumeral joint. The tendons of the rotator cuff reinforce the ligaments of glenohumeral joint capsule.

3–C: The roots of the brachial plexus pass between the anterior and middle scalene muscles. Spasm of these muscles may entrap the brachial plexus roots.

4–B: The musculocutaneous nerve courses through the coracobrachialis muscle and innervates the anterior compartment of the arm. Muscles of the anterior arm include the biceps brachii and brachialis; both of these muscles flex the elbow. The triceps muscle extends the elbow and is innervated by the radial nerve. Shoulder abduction is produced by the deltoid muscle, which is innervated by the axillary nerve. Shoulder adduction, extension, and flexion are produced by the latissimus dorsi muscle and the pectoralis major muscle with innervation from the thoracodorsal nerve and pectoral nerves, respectively.

5–B: The brachial artery bifurcates just distal to the elbow to form the radial and ulnar arteries.

6–C: The upper subscapular, lower subscapular, and thoracodorsal nerves branch off the posterior cord in the axilla, just anterior to the subscapularis muscle. The thoracodorsal nerve innervates the latissimus dorsi muscle. All other muscles are innervated by anterior divisions of the brachial plexus.

7–E: The trapezius muscle is innervated by the spinal accessory nerve (CN XI). The levator scapulae and rhomboid major muscles are innervated by the dorsal scapular nerve (C5), and the splenius capitis is innervated by cervical dorsal rami.

8–B: The serratus anterior muscle stabilizes the medial border of the scapula against the thorax. A pushup position pushes the medial border of the scapula away from the thorax, causing the weakness to become more apparent. The long thoracic nerve (C5–C7) innervates the serratus anterior muscle.

9–C: Quadrangular space syndrome results when the muscles surrounding the quadrangular space, mainly the teres major and minor and the long head of the triceps brachii, compress the posterior humeral circumflex artery and axillary nerve.

10–B: The circumflex scapular artery courses through the triangular space to form a collateral circuit with the suprascapular and dorsal scapular arteries.

11–A: The C5 spinal nerve level is a principal contributor to the axillary nerve, which innervates the deltoid muscle.

12–F: The right side of the head, neck, and thorax and the right upper limb drain lymph into the right lymphatic duct. All other parts of the body drain lymph into the thoracic duct. Therefore, the right thumb is the only structure in the choices listed that does *not* drain into the thoracic duct.

13–B: The boundaries of the three parts of the axillary artery are determined by its relationship to the pectoralis minor muscle.

14–C: When the musculocutaneous nerve is damaged, the biceps brachii and brachialis muscles are weakened or paralyzed. In addition, the skin on the lateral side of the forearm receives its cutaneous innervation via the lateral cutaneous nerve of the forearm, a branch of the musculocutaneous nerve.

15–D: The superior ulnar collateral artery anastomoses with the posterior ulnar recurrent artery from the ulnar artery, posterior to the medial epicondyle.

16–D: Damage to the radial nerve would cause the weakness in the triceps brachii muscle and extension of the elbow. This damage would cause deficits in the cutaneous field of the radial nerve in the posterior compartment of the forearm.

17–C: The flexor pollicis longus tendon courses through the carpal tunnel along with the flexor digitorum superficialis and flexor digitorum profundus tendons and the median nerve.

18–A: The median nerve courses between the flexor digitorum superficialis and profundus muscles en route to the carpal tunnel. The ulnar nerve courses between the two heads of the flexor carpi ulnaris muscle; the palmar branch of the median nerve courses superficial to the flexor retinaculum; the musculocutaneous nerve courses through the coracobrachialis muscle; and the radial nerve courses through the supinator muscle.

19–C: The radiocarpal joint is formed by the distal end of the radius, the triangular fibrocartilage complex, and the proximal row of the carpal bones. The lunate bone is included in the proximal carpals.

20–C: The flexor retinaculum anchors to the hamate, pisiform, trapezium, and scaphoid bones to enclose the tendons of the flexor digitorum superficialis, flexor digitorum profundus, and flexor pollicis longus muscles and the median nerve.

21–B: The ulnar nerve courses through Guyon's canal. Compression of the nerve will cause weakness in the muscles it innervates, including the palmer interosseus muscles, which are responsible for adduction of digits 2 to 5.

22–D: The palmar digital branches of the median nerve send cutaneous branches to the skin of the medial side of the palm after the median nerve passes through the carpal tunnel. The palmar branch of the median nerve that innervates the lateral skin of the palm branches proximal to the carpal tunnel.

23–B: The radial artery courses through the anatomical snuffbox, where a radial pulse can be felt.

24–B: The lumbrical muscles cross anterior to the metacarpophalangeal joints, then insert on the extensor expansion. It is this orientation that allows the muscles to flex the metacarpophalangeal joints and extend the interphalangeal joints.

25–C: The ischial tuberosity is the attachment site for the hamstring muscles on the ischial tuberosity. The adductor muscles attach to the pubis; the gluteal muscles attach to the ilium; the quadriceps femoris muscle attaches to the femur; and the iliopsoas muscle attaches to the lumber vertebrae and ilium.

26–E: The cutaneous field of the obturator nerve only covers the skin of the medial compartment of the thigh. The L3–L4 dermatome also covers part of the medial compartment of the thigh, but extends over the distal anterior compartment of the thigh as well.

27–A: The patient is having difficulty extending his hip from a flexed position. This action is largely performed by the gluteus maximus muscle. Damage to the inferior gluteal nerve would weaken the gluteus maximus without causing cutaneous deficit. Damage to either the S1 or S2 nerve roots may weaken the gluteus maximus, but their dermatomes would also be affected.

28–E: The gluteus medius and minimus muscles abduct the hip and hold the pelvis over the stance limb (limb that is on the ground during gate), preventing drop on the opposite swing side when walking. Damage to the superior gluteal nerve would weaken both muscles without a cutaneous deficit.

29–A: Five of the six external hip rotator muscles attach to some aspect of the greater trochanter of the femur. The quadratus femoris attaches near the greater trochanter on the intertrochanteric crest.

30–D: The capsular ligaments of the hip are pulled taut during extension of the hip, decreasing distraction between articular surfaces and stabilizing the joint.

31–A: The rectus femoris muscle is the only quadricep muscle that crosses the hip joint, originating on the anterior inferior iliac spine. A muscle must cross a joint to produce an action at that joint.

32–A: The femoral nerve innervates the anterior compartment of the thigh (quadricep muscles group). The muscles of the anterior compartment of the thigh are the primary knee extensors.

33–C: The perforating arteries branch off the deep femoral artery and pierce through the adductor magnus muscle as it inserts on the linea aspera. These arteries are the primary arterial supply to hamstring musculature.

34–D: The posterior cruciate ligament ascends from the posterior element of the superior tibia to the femur in the joint capsule of the knee. This orientation makes it very strong so that it is able to resist posterior translation of the tibia on the femur. In contrast, the anterior cruciate ligament resists anterior translation of the tibia on the femur.

35–F: The tibial nerve descends through the posterior part of the leg between the soleus and the deep posterior muscles of the leg.

36–B: The muscles of the anterior compartment of the leg produce dorsiflexion of the ankle. The deep fibular nerve innervates the anterior compartment and supplies the skin between digits 1 and 2 of the foot.

37–A: The anterior tibial artery branches from the popliteal artery, then courses through the proximal part of the interosseous membrane to enter the anterior compartment of the leg.

38–A: The lateral side of the ankle experiences the most damaging strain when the ankle is rolled or over-inverted and plantar flexed. The anterior talofibular ligament is located on the lateral side of the ankle and will experience the most damage.

39–C: The flexor retinaculum forms the roof of the tarsal tunnel between the calcaneus and the medial malleolus.

40–B: The dorsal and plantar interossei are responsible for adduction and abduction of the small toes. The lateral plantar nerve supplies the dorsal and plantar interossei as well as the plantar skin of digits 4 and 5.

41–D: The lateral plantar artery gives rise to the deep plantar arch. The terminal end of the deep plantar arch joins the deep plantar branch of the dorsalis pedis artery.

42–C: The subtalar joint allows for movement primarily in the coronal plane.

43–D: Cirrhosis of the liver may result in portal hypertension because of the backup of venous blood from the gut. Therefore, congested blood results in engorged veins in the portocaval anastomoses, such as the periumbilical veins, rectal veins, and the gastroesophageal veins.

44–B: The right atrium of the heart collects systemic and coronary deoxygenated blood. The right ventricle pumps blood through the pulmonary arteries to the lungs to become oxygenated. Oxygenated blood then returns from the lungs to the left atrium of the heart via the pulmonary veins. Therefore, blood from the pulmonary veins will most likely flow next into the left atrium.

45–D: During systole, both ventricles contract. As pressure increases, the atrioventricular valves are forced shut and the semilunar valves (pulmonary and aortic) open to enable blood to flow out of the pulmonary arteries and aorta.

46–D: The aortic valve is auscultated in the right second intercostal space adjacent to the sternum. This patient has a systolic murmur, and therefore, a stenotic or narrowed valve would be heard during systole. In contrast, a murmur of a prolapsed aortic valve would most likely be heard during diastole.

47–C: The coarctation (narrowing) is beyond the left subclavian artery, and therefore, blood flowing from the aortic arch to the thoracic aorta is restricted. Blood is shunted through the subclavian arteries to the internal thoracic arteries, where blood next flows into the anterior intercostal arteries, through the posterior intercostal arteries, and retrograde enters the thoracic aorta.

48–A: Lymph flows along the course of arteries within the abdominopelvic cavity. The primary blood supply to the stomach is via branches from the celiac artery; therefore, lymph nodes associated with the celiac artery must be biopsied in this patient.

49–C: Imaging reveals the hematoma to be in the retroperitoneal space. The only structure from the list of choices (i.e., jejunum, liver, pancreas, esophagus, and transverse colon) that is located in the retroperitoneal space is the pancreas.

50–C: The polyps are located in the hindgut (descending and sigmoid colon). The primary arterial supply to the hindgut is via the inferior mesenteric artery.

51–D: The uterine and vaginal arteries provide the primary arterial supply to the uterus. Both arteries are branches from the internal iliac artery.

52–E: Ejaculation is under sympathetic innervation. Sympathetic neurons responsible for ejaculation arise from T12-L2 levels of the spinal cord, course down the sympathetic trunk, exit via the sacral splanchnic nerves, and course to the ductus deferens and smooth muscle of the urethra. Pelvic splanchnics transport the parasympathetic neurons that are responsible for erection. Remember, *P*oint (*P*arasympathetic) and *S*hoot (*S*ympathetic).

53–E: Temperature and touch to the anterior tongue are provided by CN V-3, and taste is sensed via the chorda tympani nerve (CN VII, the facial nerve). If the lesion results from loss of touch but not taste, the lesion is proximal to the chorda tympani union to the lingual branch of CN V-3. Therefore, muscles of mastication, such as the masseter, would be affected.

54–A: The anterior communicating artery is located between the paired anterior cerebral arteries. A berry aneurysm is a sac-like outpouching in the anterior communicating cerebral artery.

55–B: The trigeminal nerve (CN V) is responsible for general sensory innervation of the face.

56–B: The oculomotor nerve (CN III) is affected in this patient, resulting in ptosis (droopy eyelid due to no tone in the levator palpebrae superioris) and mydriasis (dilatation of the pupil due to loss of the papillary constrictor muscle). The oculomotor nerve is also responsible for innervating the ciliary muscles, causing an inability to accommodate the lens. The abducens nerve (CN VI) innervates the lateral rectus (look laterally); the facial nerve (CN VII) innervates the lacrimal and salivary glands; and the glossopharyngeal nerve (CN IX) innervates the parotid salivary gland and is part of the gag reflex.

57–B: The genioglossus muscle attaches to the internal surface of the mental symphysis of the mandible and into the tongue. Therefore, contraction results in protrusion of the tongue. The palatoglossus is the only other tongue muscle listed as a choice, and it elevates the root of the tongue.

58–D: The maxillary artery branches off the external carotid artery in the infratemporal fossa. The maxillary artery courses through the pterygomaxillary fissure, pterygopalatine fossa, and sphenopalatine foramen into the nasal cavity.

59–C: The facial nerve (CN VII) provides parasympathetic innervation to both the pterygopalatine and submandibular ganglia. CN III (oculomotor nerve) provides parasympathetic innervation for the ciliary ganglion. CN IX (glossopharyngeal nerve) provides parasympathetic innervation for the otic ganglion and CN X (vagus nerve) for intramural ganglia. CN V (trigeminal nerve) does not have parasympathetic neurons originating in its nuclei; however, it does provide a pathway for parasympathetics on which to "hitch-hike."

60–C: The posterior cricoarytenoid muscles abduct the vocal ligaments, whereas the other muscles listed as choices (i.e., cricothyroid, lateral cricoarytenoid, thyroarytenoid, and transverse arytenoid) adduct or tense the vocal ligaments.

61–D: The inferior mandibular artery originates from the maxillary artery in the infratemporal fossa.

62–E: The left recurrent laryngeal nerve courses deep to the aortic arch and can affect its functioning.

63–C: The superior orbital fissure transmits CNN III, IV, V-1, VI, and the superior ophthalmic vein. Therefore, damage to CNN III, IV, and VI accounts for the paralysis of extraocular muscles, and damage to CN V-1 accounts for loss of sensation to the nose, upper eyelid, and forehead.

64–D: The facial artery originates with the external carotid artery, and after emerging from the submandibular triangle, the artery courses along the lateral corner of the mouth and medial canthus of the eye.

65–C: The malleus attaches into the medial surface of the tympanic membrane.

66–B: The cerebral region affected by the stroke (the parietal lobe and the medial portion of the temporal lobe of the left cerebral hemisphere) is supplied by the middle cerebral artery.

67–A: The phrenic nerve is formed by branches of the C3, C4, and C5 ventral rami and immediately courses vertically along the anterior scalene muscle en route to the thoracic cavity.

68–C: The facial artery gives rise to the superior labial artery, which provides arterial branches to the nasal cavity, including the nasal septum.

69–C: Torticollis causes shortening of the sternocleidomastoid muscle, which causes the head to rotate to the contralateral side. In this case, because the right sternocleidomastoid muscle is affected, the patient will look to his left.

70–F: The facial nerve (CN VII) innervates the frontalis muscle, which is responsible for wrinkling of the forehead. The facial nerve is responsible for taste in the anterior part of the tongue; however, the chorda tympani branches from the main trunk before exiting the stylomastoid foramen. Sensation to both the cornea and the face is provided by the trigeminal nerve (CN V). The genioglossus muscle protrudes the tongue from the mouth and is innervated by the hypoglossal nerve (CN XII).

71–F: When the patient is asked to look medially, the axis of vision is parallel to the contraction axis of the superior oblique muscle. When the superior oblique muscle contracts, the eye looks downward. Therefore, to clinically test the superior oblique muscle, the patient is first instructed to look medially and then to look downward. There are two muscles that cause the eye to look downward: the superior oblique and the inferior rectus. When the patient is instructed to look medially, the biomechanical advantage to looking downward is isolated to the superior oblique muscle, not the inferior rectus muscle.

72–F: When the patient looks laterally, via contraction of the lateral rectus muscle, the axis of vision becomes parallel with contraction axis of the superior rectus muscle. Therefore, when the superior rectus muscle contracts, the eye looks upward. There are two muscles that cause the eye to look upward: the superior rectus and the inferior oblique. When the patient is instructed to look laterally, the biomechanical advantage to looking up is isolated to the superior rectus muscle, not the inferior oblique muscle.

73–B: The physician is testing the trigeminal nerve (CN V). This nerve is responsible for providing general sensory innervation to the anterior scalp and face.

74–A: The patient has an epidural hematoma as a result of rupture of the middle meningeal artery. The middle meningeal artery courses on the internal surface of the skull in the region of the pterion. The lateral trauma most likely caused a skull fracture, which in turn damaged the middle meningeal artery. The middle meningeal artery courses superficial to the dura mater in this location and, as such, bleeds into the epidural space.

75–D: In the abdomen, pelvis, and perineum, lymph flows along the arterial supply of its organ. Therefore, the blood supply for the testis is through the testicular artery, which is a branch of the aorta. Paraaortic lymph nodes would be biopsied in a patient who has carcinoma of the testis.

76–D: The spleen is located in the left upper quadrant of the abdomen in midaxillary line. Fractured ribs 9 and 10 would most likely damage the spleen, resulting in significant blood loss and tenderness.

77–C: Pelvic splanchnics transport parasympathetic neurons to the erectile tissue, causing blood vessels to dilate and fill erectile tissue, which causes an erection. Remember, *P*oint (*P*arasympathetic) and *S*hoot (*S*ympathetic).

78–A: The marginal artery of Drummond courses in the mesentery adjacent to the large bowel. This artery serves as the vascular arcade connecting the superior mesenteric artery branches (right and middle colic) with the inferior mesenteric artery branches (left colic and sigmoid).

79–C: A vasectomy ligates the ductus deferens in the spermatic cord. Therefore, during ejaculation, sperm cannot reach the urethra. However, secretions from the seminal vesicles, prostate, and bulbourethral glands will continue to produce and secrete their products into the urethra during ejaculations, and therefore, this man will still have an ejaculate.

80–B: The middle colic artery anastomoses with the inferior mesenteric arterial branches, such as the left colic artery, via the marginal artery of Drummond.

81–B: The mesoappendix is a fold of mesentery that transports the appendicular artery to the appendix. The appendicular artery is a branch of the ileocolic artery.

82–A: The liver produces bile and transports it to the gallbladder for storage via the common hepatic duct. Blockage of the common hepatic duct would most likely result in jaundice (interruption of the drainage of bile from the biliary system). The pancreatic duct joins with the common bile duct, but this would not result in jaundice if blocked. The parotid and submandibular ducts transport saliva in the oral cavity. The thoracic duct transports lymph.

83–C: The buccal branch of the facial nerve (CN VII) and the parotid duct travel in the area of the cheek and can be located by a line drawn from the external acoustic meatus to the corner of the mouth.

84–E: The posterior cerebral artery is the artery that primarily provides vascular supply to the occipital lobe.

85–A: The chorda tympani nerve is a branch from the facial nerve (CN VII) and transports special sensory neurons for taste from the anterior portion of the tongue to the brain. The chorda tympani nerve courses along the internal surface of the tympanic membrane and, therefore, is the nerve most likely injured in the procedure of placing tubes in the tympanic membranes.

86–C: The glossopharyngeal nerve (CN IX) originates in the medulla and exits the skull via the jugular foramen. General sensory and visceral motor fibers enter the petrous part of the temporal bone and enter the middle ear as a tympani plexus of nerves. The tympanic plexus conducts general sensory information from the auditory tube and internal surface of the tympanic membrane to the brain.

87–C: The cricothyroid membrane is just inferior to the thyroid cartilage and superior to the cricoid cartilage.

88–D: The major vascular supply to the anterior septum is the sphenopalatine artery; a branch of this artery supplies the nasal septum. The sphenopalatine artery arises from the maxillary artery, which is a terminal branch of the external carotid artery.

89–D: The major pathway between infections of the neck and the chest is through the retropharyngeal space, a potential space between the prevertebral layer of fascia and the buccopharyngeal fascia surrounding the pharynx.

90–C: The inferior alveolar nerve provides general sensory innervation of the mandibular teeth and branches from CN V-3.

91–C: There are two pairs of pulmonary veins (four veins) that enter the left atrium of the heart.

92–B: The neurovascular plane in the abdominal wall is deep to the internal oblique and superficial to the transverse abdominis muscles.

93–B: The rectus sheath superior to the arcuate line is composed of the aponeuroses from both the external and internal oblique muscles.

94–A: Blood in the left ventricle is oxygenated and is ready to be pumped throughout the systemic circulation via the aorta to provide the body with oxygen.

95–D: The tricuspid valve is the first valve the blood encounters from the venous return to the heart. When this valve is stenotic, blood is pushed back into the venous system, causing an elevated JVP. Left-sided heart failure would more acutely present with pulmonary edema. Mitral valve prolapse will result in blood flowing from the left ventricle into the left atrium, but will not result in an elevated JVP. Right atrial contraction is mostly responsible for the pulsating appearance of the JVP. However, if the atrium has an uncoordinated and random contraction, the JVP would be lower due to weaker atrial contractions and more indistinct due to the uncoordinated rhythm.

96–E: The C7 spinal nerve exits inferior to the C6 vertebra. The C7 dermatome is associated with digit 3, and therefore, pain would most likely radiate to the palmar surface of digit 3.

97–A: The iliocostalis muscle is a part of the erector spinae group, a group of muscles responsible for maintaining an erect vertebral column. When a person bends over, these muscles stretch to accommodate the flexibility. However, this movement weakens the muscle, and thus, when a person attempts to lift a heavy object, the muscle fibers will possibly be injured.

98–E: This patient most likely has pulmonary edema resulting in back flow of blood in the pulmonary arteries. The back flow causes the right ventricle to become enlarged to accommodate for the increased volume of blood. When the patient arrived at the physician's office, symptoms were shortness of breath and cyanosis (discoloration of skin as a result of lack of oxygenated blood).

99–D: If the tricuspid valve is stenotic, then the turbulent flow will occur during atrial contraction, which occurs toward the end of diastole. Aortic valve stenosis will cause a murmur when the left ventricle is contracting, causing it to be systolic. Mitral valve regurgitation will also cause a murmur when the left ventricle is contracting because blood will be forced back through the valve and will be pushed back into the left atrium, causing a systolic murmur. Pulmonary valve stenosis will be similar to aortic valve stenosis in that it will cause a murmur during right ventricular contraction and, therefore, a systolic murmur.

100–C: CSF resides in the subarachnoid space between the arachnoid and pia mater. CSF is obtained through a spinal tap (lumbar puncture) between the L4 and L5 vertebrae.

This page intentionally left blank

INDEX

Note: Page numbers followed by "f" and "t" indicate figures and tables, respectively.

A
Abdomen, pelvis, and perineum, 77–161
  abdominal quadrants, 84, 85f
  abdominal surface landmarks, 84, 85f
  adrenal glands, 126, 127f
  anal canal, 138
  anal sphincters, 138
  anterior abdominal wall, 83–93
  foregut, 99–107
  gut tube, 80, 81f
  hindgut, 112, 113f
  ilium, 78, 79f
  inguinal canal, 90, 91f
  ischium, 78, 79f
  kidneys, 126, 127f
  midgut, 110–112
  osteologic overview, 78
  pelvic bone, 78, 79f
  pelvic diaphragm, 132, 133f
  pelvic floor, 132, 133f
  pelvic innervation, 136
  pelvic vasculature, 134, 135f
  perineum, 130–132
  peritoneum, 96–98
  posterior abdominal wall, 119–127
  pubis, 78, 79f
  rectum, 138
  regional partitions, 84, 85f
  scrotum, 92, 93f
  sex differences in pelvis, 78, 79f
  spermatic cord, 92, 93f
  study questions, 157–161
  superficial abdominal fascia, 84
  testes, 92, 93f
  ureter, 140
  urinary bladder, 140
  urination, 140
Abdominal aorta, 122, 123f, 127f
Abdominal lymphatics, 80
Abdominal quadrants, 84, 85f
Abdominal surface landmarks, 84, 85f
Abdominal venous drainage, 80, 81f
Abdominal viscera, 98
Abducens nerve (CN VI), 190, 191f, 204t
Abductor digit minimi muscle, 366t, 426, 427f, 430t
Abductor hallucis muscle, 426, 427f, 430t
Abductor pollicis brevis muscle, 366t
Abductor pollicis longus muscle, 342, 343f, 351t
Accessory hemiazygos vein, 36, 37f, 68, 69f
Accessory pancreatic duct (of Santorini), 100, 104
Accessory pharyngeal muscles, 284, 285f
Acetabular labrum, 394
Acetabulum, 78, 79f, 376, 377f, 394
Achilles tendon, 425f
ACL (anterior cruciate ligament) injury, 408
ACL (anterior cruciate ligament), 406, 407f
ACL (anterior cruciate ligament) surgeries, 408
Acromioclavicular joint, 302, 316, 317f
Acromion, 302, 303f
Adam's apple, 290
Adductor brevis muscle, 400, 401f, 410t
Adductor canal, 402
Adductor compartment, 354, 355f
Adductor hallucis muscle, 426, 427f, 430t
Adductor longus muscle, 400, 401f, 410t
Adductor magnus muscle, 400, 401f, 410t
Adductor pollicis muscle, 358, 359f, 366f
Adductor tubercle, 376
Adrenal cortex, 126
Adrenal glands, 126, 127f
Adrenal medulla, 126
Afferent neurons, 186, 204t
Air pressure equalization, 48
Alar fascia, 266, 267f
Alcock's canal, 131f, 132
Ampulla of Vater, 100, 101f
Anal canal, 132, 138
Anal columns, 138
Anal sphincters, 138
Anatomical snuffbox, 342
Anconeus muscle, 342, 343f, 351t
Anhidrosis, 208, 209f
Ankle joint, 412, 413f, 420, 421f
Annular ligament, 336, 337f
Anorectal junction, 138
Anosmia, 188
Ansa cervicalis, 274, 275f
Anterior abdominal wall, 83–93
  deep fascial layers, 86, 87f
  external oblique muscle, 86, 87f
  inguinal canal, 90, 91f
  innervation, 88
  internal oblique muscle, 86, 87f
  pyramidalis muscle, 86, 87f
  rectus abdominis muscle, 86, 87f
  transverse abdominis muscle, 86, 87f
  vascular supply, 88
Anterior cardiac veins, 54
Anterior cerebral artery, 182, 183f
Anterior chamber, 210, 211f

Anterior communicating artery, 182, 183f
Anterior compartment syndrome, 418
Anterior cranial fossa, 170, 171f
Anterior cruciate ligament (ACL), 406, 407f
Anterior cruciate ligament (ACL) injury, 408
Anterior cruciate ligament (ACL) surgeries, 408
Anterior cutaneous nerves, 34, 35f
Anterior digastricus, 236t
Anterior ethmoidal artery, 244, 245f
Anterior ethmoidal foramen, 208
Anterior ethmoidal nerve, 216, 217f
Anterior humeral circumflex artery, 324, 325f
Anterior inferior cerebellar artery, 182
Anterior inferior iliac spine (AIIS), 78, 79f, 376, 377f
Anterior intercostal nerves, 36, 37f
Anterior intercostal veins, 36, 37f
Anterior interosseous artery, 346, 347f
Anterior interosseous nerve, 344, 345f
Anterior interosseous syndrome, 344
Anterior interventricular artery, 54
Anterior interventricular sulcus, 52
Anterior longitudinal ligament, 10, 11f
Anterior mediastinum, 64, 65f
Anterior spinal artery, 182, 183f
Anterior superior iliac spine (ASIS), 78, 79f, 376, 377f
Anterior talofibular ligament (ATFL), 420, 421f
Anterior tibial artery, 418, 419f
Anterior superior alveolar nerve, 238, 239f
Anterior vagal trunk, 70
Anulus fibrosus, 10
Anus, 112, 113f
Aortic arch, 64, 70
Aortic hiatus, 38, 120, 121f
Aortic valve, 58
Aorticorental ganglia and plexus, 124, 125f
Apical nodes, 28
Aponeurosis, 166, 167f
Appendicitis, 114
Appendicular artery, 110, 111f
Appendix, 110, 111f
Aqueous humor, 210
Arachnoid granulations, 180
Arachnoid mater, 12, 173f, 174, 175f
Arachnoid villi, 174, 175f
Arcuate line, 86, 91f
Areola, 28
Arm, 331–338
  biceps brachii muscle, 332, 333f, 338t
  brachial artery, 334, 335f
  brachialis muscle, 332, 333f, 338t
  coracobrachialis muscle, 332, 333f, 338t
  elbow complex, 332, 336, 337f
  muscles, 332, 333f, 338t
  olecranon bursa, 336
  radial nerve, 334, 335f
  triceps brachii muscle, 332, 333f, 338t
Arteriovenous malformation (AVM), 182
Articular disc, 232
Articulation, 292
Arytenoid cartilages, 290
Ascending colon, 110, 111f
Ascending lumbar veins, 122
Ascending pharyngeal artery, 272, 273f, 286, 287f
Atrioventricular (AV) bundle (of His), 60, 61f
Atrioventricular (AV) groove, 52
Atrioventricular (AV) node, 60
Atrioventricular (AV) valves, 58
Auditory tube, 220, 221f
Auricle, 220, 221f
Auriculotemporal nerve, 234, 235f
Autonomic innervation of head, 202, 203f
AV (atrioventricular) bundle (of His), 60, 61f
AV (atrioventricular) groove, 52
AV (atrioventricular) node, 60
AV (atrioventricular) valves, 58
Axilla. *See* Shoulder and axilla
Axillary artery, 312, 313f, 324, 325f
Axillary nerve, 308, 309f, 323f, 324
Axillary sheath, 266
Axillary vein, 312, 313f, 326
Azygos system of veins, 68, 69f
Azygos vein, 32, 36, 37f, 68, 69f

B

Back
  deep back muscles, 6, 7f, 21t
  dermatomes, 18, 19f
  myotomes, 18
  spinal cord, 14, 15f
  spinal meninges, 12, 13f
  spinal nerves, 16, 17f
  study questions, 22–23
  superficial back muscles, 4, 5f, 20t
  vertebrae, 10, 11f
  vertebral column, 8, 9f
Bartholin glands, 154
Basilar artery, 182, 183f
Basilar membrane, 222, 223f
Basilic vein, 312, 313f, 326
Bell's palsy, 194, 228
Benign prostatic hyperplasia (BPH), 146
Berry aneurysm, 182
Biceps brachii muscle, 332, 333f, 338t
Biceps femoris muscle, 400, 401f, 410t
Biceps tendinopathy, 332
Bicuspid valve, 58
Bifid spinous process, 10
Bikini-line incision, 86
Blink reflex, 228
Bones
  forearm and hand, 304, 305f
  hand, 356, 357f
  shoulder and arm, 302, 303f
Bony labyrinth, 222
Bony orbit, 208, 209f
Boutonnière deformity, 358
Boyle's law, 48
Brachial artery, 334, 335f
Brachial plexus
  arm, 334, 335f

forearm, 344, 345f
hand, 360, 361f
innervation of upper limb, 308, 309f
shoulder, 322, 323f
Brachial vein, 312, 313f, 326
Brachialis muscle, 332, 333f, 338t
Brachiocephalic artery, 70
Brachiocephalic trunk, 64, 70
Brachioradialis muscle, 342, 343f, 351t
Brain, 177–183
blood supply, 182
brainstem, 178, 179f
cerebellum, 178, 179f
cerebrospinal fluid (CSF), 180, 181f
cerebrum, 178
circle of Willis, 182, 183f
diencephalon, 178
ventricles, 180, 181f
vertebrobasilar system of arteries, 182
Brainstem, 178, 179f
Branchial motor neurons, 186, 204t
Breast, 28, 29f
Breast cancer, 28
Broad ligament, 152, 153f
Bronchial arteries, 46, 68
Bronchoconstriction, 46
Brunner's glands, 100
Buccal nerve, 228, 229f, 234, 235f
Buccinator muscle, 228, 229f
Buccopharyngeal fascia, 266, 267f
Buck's fascia, 146, 147f
Bulbospongiosus muscle, 146, 154, 155f
Bulbourethral glands, 144, 145f
Bursae, 394

C

C-section, 86
C1 (atlas) vertebra, 10
C1-C7 spinal nerves, 16, 17f
C2 (axis) vertebra, 10
Caesarean section, 86
Calcaneofibular ligament (CFL), 420, 421f
Calcaneus, 378, 379f, 424, 425f
Calcitonin, 278
Calot's triangle, 106
Camper's fascia, 84, 85f, 87f
Canine (tooth), 254, 255f
Capitate bone, 304, 305f, 356, 357f
Capitulum, 302, 303f
Caput medusae, 84, 118
Cardiac cycle
atrial filling, 58, 59f
ventricular contraction, 58, 59f
ventricular ejection of blood, 58, 59f
ventricular filling, 58, 59f
ventricular relaxation, 58, 59f
Cardiac plexus, 70
Cardiac sphincter, 100, 101f
Cardiac sulci, 52
Cardiac veins, 54
Carina, 44, 70
Carotid body, 272, 273f
Carotid canal, 170, 171f
Carotid-cavernous sinus fistula, 172
Carotid sheath, 266, 267f
Carotid sinus, 272, 273f
Carpal tunnel, 354, 355f
Carpal tunnel syndrome, 360
Carpals, 304, 305f, 356, 357f
Carpometacarpal joints, 364, 365f
Cauda equina, 16
Caudate lobe, 102, 103f
Caval hiatus, 120, 121f
Cavernous sinus, 172, 173f
Cecum, 110, 111f
Celiac ganglia and plexus, 124, 125f
Celiac lymph nodes, 80, 106
Celiac trunk, 106, 107f
Central canal, 14
Central compartment, 354
Central nodes, 28, 29f
Central sulcus, 178, 179f
Cephalic vein, 312, 313f, 326
Cerebellum, 178, 179f
Cerebral aqueduct (of Sylvius), 178, 180, 181f
Cerebral hemispheres, 178
Cerebrospinal fluid (CSF), 12, 180, 181f
Cerebrum, 178
Cervical cancer, 152
Cervical nerve, 228, 229f
Cervical parietal pleura, 42
Cervical plexus, 274, 275f
Cervical spinal enlargement, 14
Cervical vertebrae, 8, 9f, 10
Cervix, 152, 153f
Cholecystectomy, 104
Chorda tympani nerve, 194, 220, 221f, 234, 235f
Chordae tendineae, 56, 57f, 58
Choroid, 210, 211f
Chyme, 100
Ciliary ganglion, 202
Ciliary muscle, 210, 211f
Circle of Willis, 182, 183f
Circumcision, 144
Circumflex scapular artery, 324, 325f
Cirrhosis, 84
Cisterna magna, 180
Clavicle, 302, 303f
Clavipectoral triangle, 321f
Claw hand, 360
Clitoris, 154, 155f
CN I (olfactory nerve), 188, 189f, 204t
CN II (optic nerve), 188, 189f, 204t
CN III (oculomotor nerve), 190, 191f, 202, 204t, 205t
CN IV (trochlear nerve), 190, 191f, 204t
CN V (trigeminal nerve), 192, 193f, 204t
CN V-1 (ophthalmic division of trigeminal nerve), 192, 193f
CN V-2 (maxillary division of trigeminal nerve), 192, 193f
CN V-3 (mandibular division of trigeminal nerve), 192, 193f
CN VI (abducens nerve), 190, 191f, 204t

CN VII (facial nerve), 194, 195f, 202, 204t, 205f
CN VIII (vestibulocochlear nerve), 194, 195f, 205t
CN IX (glossopharyngeal nerve), 196, 197f, 202, 205t
CN X (vagus nerve), 198, 199f, 202, 205t
CN XI (spinal accessory nerve), 200, 201, 205t
CN XII (hypoglossal nerve), 200, 201, 205t
Coccygeal vertebrae, 8, 9f, 10
Coccygeus muscle, 132, 133f
Coccyx, 10
Cochlea, 222, 223f
Cochlear duct, 222, 223f
Cochlear nerve, 222
Cochlear window, 220, 221f
Collarbone, 302
Collateral arterial supply of shoulder, 324
Colles' fascia, 84, 85f
Colles' fracture, 348
Colon, 80. *See also* Large intestine
Common bile duct, 100, 101f, 104, 105f
Common carotid artery, 272, 273f
Common fibular nerve, 382, 383f, 392, 393f, 418, 419f
Common hepatic duct, 102, 103f, 104, 105f
Common iliac arteries, 122
Common interosseous artery, 346, 347f
Cones, 210
Confluence of sinuses, 172, 173f
Conjoint ramus, 78, 79f
Conjunctiva, 208, 209f, 211f
Conoid tubercle, 302
Conus medullaris, 14
Coracoacromial ligament, 326, 327f
Coracobrachialis muscle, 332, 333f, 338t
Coracoclavicular ligament, 302
Coracoid process, 302, 303f
Cornea, 209f, 210, 211f
Corneal reflex, 208, 228
Corniculate cartilage, 290
Coronal suture, 168, 169f
Coronary angioplasty, 404
Coronary arterial bypass graft (CABG), 386
Coronary arteries, 54
Coronary circulation, 54
Coronary dominance, 54
Coronary sinus, 54, 56
Coronary sulcus, 52
Coronoid fossa, 302, 303f
Coronoid process, 304, 305f
Corpora cavernosa, 144, 145f, 147f
Corpus spongiosum, 144, 145f, 147f
Corrugator supercili muscle, 228, 229f
Costal cartilages, 32
Costal facets, 10
Costal groove, 32
Costal parietal pleura, 42
Costocervical trunk, 68
Costochondral joint, 32
Costodiaphragmatic recess, 42, 43f
Costomediastinal recess, 42, 43f
Costotransverse joint, 32, 33f
Costovertebral joints, 32, 33f
Cough reflex, 294
Couinaud classification system, 102
Cranial fossae, 170, 171f
Cranial nerves, 185–205
  abducens nerve, 190, 191f, 204t
  facial nerve, 194, 195f, 204t, 205f
  glossopharyngeal nerve, 196, 197f, 205t
  hypoglossal nerve, 200, 201, 205t
  modalities, 186
  oculomotor nerve, 190, 191f, 204t, 205t
  olfactory nerve, 188, 189f, 204t
  optic nerve, 188, 189f, 204t
  overview, 187f
  spinal accessory nerve, 200, 201, 205t
  targets, 186
  trigeminal nerve, 192, 193f, 204t
  trochlear nerve, 190, 191f, 204t
  vagus nerve, 198, 199f, 205t
  vestibulocochlear nerve, 194, 195f, 205t
Cremasteric muscle, 92, 93f
Cremasteric reflex, 92, 122
Cribriform foramina, 188, 242
Cribriform plate, 170, 171f
Cricoid cartilage, 290, 291f
Cricopharyngeus muscle, 284
Cricothyroid joint, 292, 293f
Cricothyroid ligament, 290
Cricothyroid muscles, 292, 293f
Cricothyrotomy, 290
Crista galli, 170, 173f
Crista terminalis, 56, 57f
CSF. *See* Cerebrospinal fluid (CSF)
Cubital tunnel syndrome, 344
Cuboid bone, 378, 379f, 424, 425f
Cuneiform bones, 379f, 424, 425f
Cuneiform cartilage, 290
Cutaneous field, 310, 311f
Cutaneous nerves
  lower limb, 384, 385f
  upper limb, 310, 311f
Cystic artery, 106
Cystic duct, 104, 105f
Cystic vein, 116

D

Danger space, 266, 267f
Danger triangle, 226
Dartos fascia, 92, 93f, 146, 147f
Dartos muscle, 92
DCIS tumors, 28
Deep back muscles, 6, 7f, 21t
Deep brachial artery, 334
Deep cervical fascia, 266, 267f
Deep fascia
  lower limb, 380, 381f
  upper limb, 306, 307f
Deep fibular nerve, 382, 392, 418, 419f, 428, 429f
Deep hip rotator muscles, 390, 391f, 396t

Deep inguinal nodes, 404, 405f
Deep inguinal ring, 90, 91f
Deep investing fascia, 266, 267f
Deep penile artery, 146, 147f
Deep penile fascia, 146, 147f
Deep perineal fascia, 130, 131f
Deep perineal space, 130
Deep petrosal nerve, 238
Deep thoracic muscles, 30, 31f, 40t
Deep transverse cervical artery, 324
Deltoid ligament, 420, 421f
Deltoid muscle, 320, 328, 329f, 329t
Deltoid tuberosity, 302, 303f
Denticulate ligaments, 12
Depressor anguli oris muscle, 228, 229f
Depressor labii inferioris muscle, 228, 229f
Dermatomes, 18, 19f
  lower limb, 384, 385f
  upper limb, 310, 311f
Descending aorta, 64
Descending colon, 112, 113f
Descending palatine artery, 238, 239f
Detrusor muscle, 140
Diaphragm, 38, 39f, 120, 121f
Diaphragma sellae, 172
Diaphragmatic lung surface, 44
Diaphragmatic parietal pleura, 42
Diencephalon, 178
Digastric muscle, 270, 271f
Dilator pupillae muscle, 210, 211f
Diploic vein, 166, 172, 173f
Diplopia, 190
Direct hernia, 90
Distal interphalangeal (DIP) joints, 424, 425f
Distal radioulnar joint, 348, 349f
Dorsal horn, 14
Dorsal interossei muscles, 358, 359f, 366f, 426, 427f, 430t
Dorsal pedis artery, 418, 419f, 428, 429f
Dorsal pedis pulse, 428
Dorsal penile artery, 146, 147f, 324
Dorsal penile vein, 146, 147f
Dorsal radiocarpal ligament, 348, 349f
Dorsal radioulnar ligament, 348, 349f
Dorsal ramus, 16
Dorsal root, 16
Dorsal root ganglion, 16
Dorsal scapular artery, 324, 325f
Dorsal scapular nerve, 308, 309f, 322, 323f
Dorsal venous arch, 386, 387f
Double vision, 190
Ductus arteriosus, 70
Ductus deferens, 92, 93f, 144, 145f
Duodenal bulb, 100
Duodenal ulcer, 100
Duodenojejunal junction, 100
Duodenum, 100, 101f, 107f, 110
Dura mater, 12, 13f, 172, 173f, 175f
Dural septae, 172
Dural venous sinus, 172

E

Ear, 219–223
  bony labyrinth, 222
  cochlea, 222, 223f
  equalizing air pressure, 220
  external, 220, 221f
  hearing, 222
  inner, 222, 223f
  malleus, incus, stapes, 220, 221f
  middle, 220, 221f
  tympanic cavity proper, 220
  tympanic membrane, 220, 221f
  vestibulocochlear nerve, 222
Ear ossicles, 220, 221f
Ectopic pregnancy, 152
Edinger-Westphal nucleus, 190
Efferent neurons, 186, 204t
Ejaculation, 148
Ejaculatory ducts, 144, 145f
Elbow complex, 332, 336, 337f
Emissary vein, 166, 172, 173f
Emission, 148
Endocardium, 52, 53f
Endocranium, 168
Endolymph, 222
Epicardium, 52, 53f
Epididymis, 144, 145f
Epidural block, 12
Epidural hematoma, 168
Epidural space, 12
Epigastric region, 84, 85f
Epiglottis, 290
Epinephrine, 126
Epiploic foramen (of Winslow), 96
Episiotomy, 154
Epistaxis, 244
Epithalamus, 178, 179f
Erb's palsy, 322
Erector spinae muscles, 6, 7f, 21t
Esophageal arteries, 68
Esophageal hiatus, 38, 120, 121f
Esophageal plexus of nerves, 70
Esophageal varices, 118
Esophagus, 64, 70, 100, 101f, 107f, 278, 279f
Ethmoid bone, 168
Ethmoidal air cells, 246
Ethmoidal bulla, 242
Ethmoidal sinus, 246
Eustachian tube, 220
Exhalation, 48
Expiration, 48, 49f
Extensor carpi radialis brevis muscle, 342, 343f, 351t
Extensor carpi radialis longus muscle, 342, 343f, 351t
Extensor carpi ulnaris muscle, 342, 343f, 351t
Extensor digiti minimi muscle, 342, 343f, 351t
Extensor digitorum brevis muscle, 430t
Extensor digitorum communis muscle (EDC), 342
Extensor digitorum muscle, 342, 343f, 351t

Extensor hallucis brevis muscle, 430t
Extensor indicis muscle, 342, 343f, 351t
Extensor pollicis brevis muscle, 342, 343f, 351t
Extensor pollicis longus muscle, 342, 343f, 351t
Extensor retinaculum, 354, 355f
Extensor tendon injuries, 358
External acoustic meatus, 220, 221f
External anal sphincter, 138
External carotid artery, 166, 167f, 272
External ear, 220, 221f
External genitalia, 144, 145f, 154
External hemorrhoids, 138
External iliac artery, 386, 387f
External intercostal muscles, 30, 31f, 40t
External jugular vein, 272, 273f
External laryngeal nerve, 198, 275f, 294, 295f
External oblique aponeurosis, 86
External oblique muscle, 86, 87f
External os, 152, 153f
External spermatic fascia, 92, 93f
Extradural hematoma, 168
Extraocular muscles, 212, 213f
Extraperitoneal fat, 86, 87f
Eye, 210, 211f. *See also* Orbit
Eye movement, 212
Eyelids, 208

F

Face. *See* Superficial face
Facial artery, 226, 244
Facial nerve (CN VII), 194, 195f, 202, 204t, 205f
Facial palsy, 228
Facial vein, 226
Falciform ligament, 102
Fallopian tubes, 152
False ribs, 32, 33f
False vocal folds, 290
Falx cerebelli, 172
Falx cerebri, 172, 173f
Female perineal muscles, 154
Female pubic arch, 78, 79f
Female reproductive system, 151–156
  external genitalia, 154
  female sexual responses, 156
  innervation, 154
  internal female organs, 152–154
  perineal body, 154
  perineal muscles, 154
Femoral artery, 134, 135f, 402, 403f, 404, 405f
Femoral nerve, 120, 121f, 136, 382, 383f, 402, 403f
Femoral sheath, 402, 403f
Femoral triangle, 402, 403f
Femoral vein, 386, 387f, 402, 403f
Femur, 376, 377f
Fibrous digital sheaths, 354, 355f
Fibrous parietal pericardium, 52
Fibula, 378, 379f
Fibular artery, 418, 419f
Fibular retinacula, 424
Filum terminale, 12
Final examination, 437–455. *See also* Study questions and answers
First pass effect, 116
Flexor carpi radialis muscle, 340, 341f, 350t
Flexor carpi ulnaris muscle, 340, 341f, 350t
Flexor digiti minimi brevis muscle, 366t, 426, 427f, 430t
Flexor digitorum brevis muscle, 426, 427f, 430t
Flexor digitorum profundus muscle, 340, 341f, 350t
Flexor digitorum superficialis muscle, 340, 341f, 350t
Flexor hallucis brevis muscle, 426, 427f, 430t
Flexor pollicis brevis muscle, 366t
Flexor pollicis longus muscle, 340, 341f, 350t
Flexor retinaculum, 354, 355f, 424, 425f
Flexor tendon injuries, 358
Floating ribs, 32, 33f
FOOSH injury, 348
Foot, 378, 379f, 423–430
  bones, 424, 425f
  fascial structures, 424, 425f
  innervation, 428, 429f
  joints of the digits, 424, 425f
  muscles, 426, 427f, 430t
  vascularization, 428, 429f
Foot muscles, 380
Foramen lacerum, 170, 171f
Foramen magnum, 170, 182
Foramen ovale, 56, 170, 171f
Foramen rotundum, 170, 171f, 238, 239f
Foramen spinosum, 170, 171f
Forced expiration, 48
Forearm, 339–351
  abductor pollicis longus muscle, 342, 343f, 351t
  anconeus muscle, 342, 343f, 351t
  brachial plexus, 344, 345f
  brachioradialis muscle, 342, 343f, 351t
  distal radioulnar joint, 348, 349f
  extensor carpi radialis brevis muscle, 342, 343f, 351t
  extensor carpi radialis longus muscle, 342, 343f, 351t
  extensor carpi ulnaris muscle, 342, 343f, 351t
  extensor digiti minimi muscle, 342, 343f, 351t
  extensor digitorum muscle (extensor digitorum communis muscle), 342, 343f, 351t
  extensor indicis muscle, 342, 343f, 351t
  extensor pollicis brevis muscle, 342, 343f, 351t
  extensor pollicis longus muscle, 342, 343f, 351t
  flexor carpi radialis muscle, 340, 341f, 350t
  flexor carpi ulnaris muscle, 340, 341f, 350t
  flexor digitorum profundus muscle, 340, 341f, 350t
  flexor digitorum superficialis muscle, 340, 341f, 350t
  flexor pollicis longus muscle, 340, 341f, 350t
  median nerve, 344, 345f
  palmaris longus muscle, 340, 341f, 350t
  pronator quadratus muscle, 340, 341f, 350t
  pronator teres muscle, 340, 341f, 350t
  radial artery, 346, 347f
  radial nerve, 344, 345f

supinator muscle, 342, 343f, 351t
ulnar artery, 346, 347f
ulnar nerve, 344, 345f
wrist complex, 348, 349f
Foregut, 80, 99–107
arterial supply, 106, 107f
duodenum, 100, 101f
esophagus, 100, 101f
gallbladder, 103f, 104
liver, 102, 103f
lymphatics, 106
pancreas, 104, 105f
spleen, 104, 105f
stomach, 100, 101f
venous drainage, 106, 107f
Fornix (fornices), 154
Fossa ovalis, 56, 57f
Fovea centralis, 210, 211f
Frontal bone, 168, 169f
Frontal lobe, 178, 179f
Frontal nerve, 216, 217f
Frontal sinus, 246, 247f
Frontalis muscle, 228, 229f
Frontonasal duct, 246

G

Gag reflex, 286
Galea aponeurotica, 166, 167f, 228, 229f
Gallaudet's fascia, 130
Gallbladder, 103f, 104, 107f
Gallstones, 104
Ganglion, 186
Ganglion impar, 136
Gastric cancer, 106
Gastric lipase, 100
Gastric rugae, 100
Gastrocnemius bursa, 408
Gastrocolic ligament, 96, 110
Gastroduodenal artery, 106, 107f
Gastroesophageal reflux disease (GERD), 100
Gastrointestinal tract. *See* Gut tube
Gastrophrenic ligament, 96
Gastroplenic ligament, 96
General sensory neurons, 186, 204t
General somatic afferent neurons, 186, 204t
General somatic efferent neurons, 186, 204t
General visceral afferent neurons, 186, 204t
General visceral efferent neurons, 186, 204t
Geniculate ganglion, 194, 221f, 222, 235f
Genioglossus muscle, 252, 253f
Geniohyoid muscle, 270
Genitofemoral nerve, 92, 120, 121f
GERD. *See* Gastroesophageal reflux disease (GERD)
GI tract. *See* Gut tube
GI tract innervation, 114, 115f
Gingivae, 254, 255f
Glabella, 168
Glans clitoris, 154, 155f
Glans penis, 144, 145f
Glaucoma, 210
Glenohumeral joint, 316, 326, 327f
Glenohumeral joint actions, 316, 317f
Glenohumeral joint capsule, 306
Glenoid cavity, 302, 303f
Glossopharyngeal nerve (CN IX), 196, 197f, 202, 205t
Glucagon, 104
Gluteal muscles, 380, 390, 391f, 396t
Gluteal region, 389–396
arteries, 394, 395f
bursae, 394
deep hip rotator muscles, 390, 391f, 396t
gluteal muscles, 390, 391f, 396t
hip joint, 390, 391f, 394, 395f
joints, 394
sacroiliac joint, 394
Gluteus maximus muscle, 390, 391f, 396t
Gluteus medius muscle, 390, 391f, 396t
Gluteus minimus muscle, 390, 391f, 396t
Goiter, 278
Golfer's elbow, 342
Gonadal artery, 92
Gonadal vein, 92
Goose foot, 408
Gracilis muscle, 400, 401f, 410t
Gray rami communicantes, 66, 67f
Great auricular nerve, 274, 275f
Great cardiac vein, 54
Great cerebral vein (of Galen), 172
Great saphenous vein, 386, 387f, 404, 405f, 418
Great toe, 424
Greater occipital nerve, 6
Greater omentum, 96, 97f
Greater palatine artery, 244, 245f
Greater palatine canal, 170
Greater palatine nerve, 238, 239f
Greater petrosal nerve, 221f
Greater sac, 96, 97f
Greater sciatic foramen, 78
Greater sciatic notch, 78
Greater splanchnic nerve, 66, 67f, 114, 124
Greater trochanter, 376, 377f
Greater tubercle, 302, 303f
Greater vestibular glands, 154
Gut tube
abdominal lymphatics, 80
abdominal venous drainage, 80, 81f
caval drainage, 80, 81f
functions, 80
innervation, 80
organs, 80, 81f
portal drainage, 80, 81f
regions, 80, 81f
Guyon's canal, 344

H

Hallux, 424, 425f
Hamate bone, 304, 305f, 356, 357f
Hamstrings, 400, 401f, 410t

Hand, 304, 305f, 353–366
actions of fingers, 356, 357f
actions of thumbs, 356, 357f
adductor pollicis muscle, 358, 359f, 366f
bones, 356, 357f
brachial plexus, 360, 361f
dorsal interossei muscles, 358, 359f, 366f
fascia, 354, 355f
hypothenar muscles, 358, 359f, 366f
interosseous muscles, 358, 359f, 366f
joints, 364, 365f
lumbrical muscles, 358, 359f, 366f
median nerve, 360, 361f
palmar interossei muscles, 358, 359f, 366f
radial artery, 362, 363f
radial nerve, 360, 361f
thenar muscles, 358, 359f, 366f
ulnar artery, 362, 363f
ulnar nerve, 360, 361f
veins, 362, 363f
Hard palate, 250, 251f
Head, 163–261
anterior cranial fossa, 170, 171f
arachnoid mater, 173f, 174, 175f
autonomic innervation, 202, 203f
brain, 177–183
cranial fossae, 170, 171f
cranial nerves. *See* Cranial nerves
dura mater, 172, 173f
ear, 219–223
eye, 210, 211f
foramina in base of skull, 170
infratemporal fossa, 231–236
meninges, 172, 173f
middle cranial fossa, 170, 171f
nasal cavity, 241–247
oral cavity, 249–255
orbit, 207–217
pia mater, 173f, 174, 175f
posterior cranial fossa, 170, 171f
pterygopalatine fossa, 237–239
scalp, 166, 167f
skull, 168, 169f
study questions, 256–261
superficial face, 225–229
teeth and gingivae, 254–255
tongue, 252–253
Hearing, 222
Heart, 51–61
AV valves, 58
borders/surfaces, 52
cardiac veins, 54
chambers, 52, 56
conducting system, 60
coronary arteries, 54
innervation, 60
layers, 52, 53f
left atrium, 56
left ventricle, 56
parasympathetic innervation, 60
pericardial sac, 52
right atrium, 56
right ventricle, 56
semilunar valves, 58
sides, 52
sulci, 52
sympathetic innervation, 60
valves, 58
Heart burn, 100
Heart chambers, 52, 56
Heart valves, 58
Helicotrema, 222, 223f
Hemiazygos vein, 36, 37f, 68, 69f
Hemorrhoids, 138
Hemothorax, 42
Hepatic portal system, 102, 116–118
Hepatic portal vein, 80
Hepatic sinusoids, 102, 116
Hepatic veins, 122
Hepatobiliary (Calot's) triangle, 106
Hepatocytes, 116
Hepatoduodenal ligament, 96
Hepatogastric ligament, 96
Herniated disc, 10, 90
Hiatal hernia, 100
Hiatus semilunaris, 242, 243f
Hilum of lungs, 45f, 46
Hindgut, 80, 112, 113f
Hip joint, 390, 391f, 394, 395f
Hoarse voice, 294
Hoarseness, 198, 294
Horner's syndrome, 208, 209f
Housemaid's knee, 408
Humeral (lateral) nodes, 28
Humeroradial joint, 336, 337f
Humeroulnar joint, 336, 337f
Humerus, 302, 303f
Hydrocephalus, 180
Hyoglossus muscle, 252, 253f, 271f
Hyoid bone, 271f, 290, 291f
Hyperacusis, 194, 220
Hypogastric nerves, 124, 125f
Hypogastric region, 84, 85f
Hypoglossal canal, 170
Hypoglossal nerve (CN XII), 200, 201, 205t
Hypothalamus, 178, 179f
Hypothenar compartment, 354, 355f
Hypothenar muscles, 306, 358, 359f, 366f

I

Ileal arteries, 110
Ileal veins, 118
Ileocecal valve, 110
Ileocolic artery, 110, 111f
Ileocolic vein, 118
Ileum, 110, 111f
Iliac crest, 78, 79f, 376, 377f
Iliac fossa, 78, 79f, 376

Iliacus muscle, 120
Iliococcygeus muscle, 132, 133f
Iliocostalis muscle, 6, 7f, 21t
Iliofemoral ligament, 394, 395f
Iliohypogastric nerve, 88, 120, 121f
Ilioinguinal nerve, 88, 90, 120, 121f
Iliolumbar artery, 134, 135f
Iliopsoas muscle, 120, 121f, 398, 399f, 409t
Iliotibial tract, 399f
Ilium, 78, 79f, 376, 377f
Incisive canal, 170, 171f
Incisive foramen, 242
Incisors, 254, 255f
Incus, 220, 221f, 223f
Indirect hernia, 90
Inferior alveolar artery, 234, 235f, 254, 255f
Inferior alveolar nerve, 234, 235f
Inferior alveolar nerve block, 254
Inferior articular facets, 10
Inferior cervical ganglion, 274, 275f
Inferior epigastric artery, 88, 89f, 134
Inferior epigastric vessels, 90, 91f
Inferior extensor retinaculum, 424, 425f
Inferior gemellus muscle, 390, 391f, 396t
Inferior gluteal artery, 134, 135f, 394
Inferior gluteal nerve, 136, 382, 383f, 392, 393f
Inferior hypogastric plexus, 124, 136, 137f
Inferior laryngeal artery, 294, 295f
Inferior meatus, 242
Inferior mesenteric artery (IMA), 122
Inferior mesenteric ganglion and plexus, 124, 125f
Inferior mesenteric vein, 116, 117f
Inferior oblique muscle, 212, 213f
Inferior orbital fissure, 208
Inferior pancreaticoduodenal arteries, 110
Inferior petrosal sinus, 172
Inferior pharyngeal constrictor, 284, 285f
Inferior pubic ramus, 78, 79f, 376, 377f
Inferior rectus muscle, 212, 213f
Inferior sagittal sinus, 172, 173f
Inferior thyroid artery, 278, 279f
Inferior thyroid vein, 278, 279f
Inferior ulnar collateral artery, 334, 335f, 346, 347f
Inferior ulnar recurrent artery, 346
Inferior vena cava (IVC), 56, 57f, 122, 123f
Inferior vesical artery, 134
Infraglenoid tubercle, 302, 303f
Infrahyoid muscles, 270, 271f
Infraorbital artery, 238, 239f
Infraorbital foramen, 208
Infraorbital nerve, 238, 239f
Infraspinatus muscle, 320, 326, 329f, 329t
Infraspinous fossa, 302, 303f
Infratemporal fossa, 192, 231–236
  boundaries, 232
  muscles of mastication, 232, 233f, 236t
  nerves, 234, 235f
  temporomandibular joint (TMJ), 232, 233f
  vascular supply, 234, 235f
Infratrochlear nerve, 216, 217f
Infundibulum, 152
Inguinal canal, 90, 91f
Inguinal ligament, 84, 85f, 399f
Inhalation, 48
Inner ear, 222, 223f
Innermost intercostal muscles, 30, 31f
Innervation of male perineum, 137
Innervation of penis, 149f
Innervation of scalp, 166
Inspiration, 48, 49f
Insulin, 104
Intercarpal ligaments, 348
Intercondylar eminence, 378, 379f
Intercostal nerves, 28, 34, 35f, 42
Intermediate cuneiform bone, 424, 425f
Intermuscular injections, 392
Internal acoustic meatus, 170, 171f
Internal anal sphincter, 138
Internal carotid artery, 166, 167f, 182, 183f, 272, 273f
Internal hemorrhoids, 118, 138
Internal iliac artery, 134, 135f, 386, 387f, 394
Internal intercostal muscles, 30, 31f, 40t
Internal jugular vein, 172, 272, 273f
Internal laryngeal nerve, 198, 275f, 294, 295f
Internal oblique aponeurosis, 86
Internal oblique muscle, 86, 87f
Internal os, 152, 153f
Internal spermatic fascia, 92, 93f
Internal thoracic arteries, 36, 37f
Internal thoracic veins, 36
Internal urethral sphincter, 140, 146, 148, 154
Internodal fibers, 66, 67f
Interosseous compartment, 354
Interosseous membrane, 348, 349f, 420
Interosseous muscles, 358, 359f, 366f
Interosseous recurrent artery, 347f
Interphalangeal (IP) joint, 364, 365f, 424, 425f
Interspinous ligament, 10
Intertubercular groove, 302, 303f
Intertubercular groove muscles, 306, 307f, 320, 329f, 329t
Interventricular foramen (of Monro), 180, 181f
Intervertebral (IV) discs, 10
Intervertebral (neural) foramina, 10
Intraperitoneal viscera, 98
Iris, 209f, 210
Ischial ramus, 78, 79f, 376, 377f
Ischial spine, 78, 376, 377f
Ischial tuberosity, 78, 79f, 376, 377f
Ischioanal fossa, 132
Ischioanal triangle, 132
Ischiocavernosus muscle, 146, 154, 155f
Ischiofemoral ligament, 394, 395f
Ischiopubic ramus, 78, 79f
Ischium, 78, 79f, 376, 377f
Isthmus, 152
IVC. *See* Inferior vena cava (IVC)

J
Jejunal arteries, 110
Jejunal veins, 118
Jejunum, 110, 111f
Jersey finger, 358
Jugular foramen, 170, 171f
Jugular notch, 32, 33f
Jugular vein, 272, 273f

K
Kidney, 126, 127f
Kiesselbach's area, 244, 245f
Klumpke's palsy, 360
Knee complex, 398, 406–408
Knee joint, 406
Kyphosis, 8

L
L1-L5 spinal nerves, 16, 17f
Labia majora, 154, 155f
Labia minor, 154, 155f
Lacrimal apparatus, 208, 209f
Lacrimal gland, 208, 209f
Lacrimal nerve, 216, 217f
Lactiferous duct, 28
Lacunar ligament, 90
Lambdoid suture, 168, 169f
Large intestine, 80, 81f
Laryngeal cartilages, 290, 291f
Laryngeal innervation, 294, 295f
Laryngeal muscles, 292, 293f
Laryngeal prominence, 290
Laryngeal vessels, 294, 295f
Laryngitis, 292
Laryngopharynx, 282, 283f, 286, 287f
Larynx, 289–295
  function, 292
  hyoid bone, 290, 291f
  laryngeal cartilages, 290, 291f
  laryngeal innervation, 294, 295f
  laryngeal muscles, 292, 293f
  laryngeal vessels, 294, 295f
  vocal ligaments, 290, 291f
  voice production, 292, 293f
Lateral apertures (of Luschka), 180
Lateral circumflex femoral artery, 404, 405f
Lateral collateral ligament (LCL), 406, 407f
Lateral condyle, 376, 377f, 378, 379f
Lateral cricoarytenoid muscles, 292, 293f
Lateral cuneiform bone, 424, 425f
Lateral cutaneous nerves, 34, 35f
Lateral epicondyle, 302, 303f, 376, 377f
Lateral epicondylitis, 342
Lateral femoral cutaneous nerve, 120, 121f
Lateral horn, 14
Lateral malleolus, 378, 379f
Lateral meniscus, 408
Lateral pectoral nerve, 308, 309f, 323f, 324
Lateral plantar artery, 428, 429f
Lateral plantar nerve, 428, 429f
Lateral pterygoid muscle, 232, 233f, 236t
Lateral rectus muscle, 212, 213f
Lateral sacral artery, 134, 135f
Lateral sulcus, 178, 179f
Lateral sural nerve, 384, 385f, 418, 419f
Lateral thoracic artery, 324, 325f
Lateral umbilical folds, 90, 91f
Latissimus dorsi muscle, 4, 5f, 20t, 320, 329f, 329t
Least splanchnic nerve, 66, 67f, 114, 124
Left anterior descending artery, 54
Left atrium, 52, 56
Left circumflex artery (LCX), 54
Left colic artery, 112, 113f
Left colic vein, 116, 117f
Left common carotid artery, 64, 70
Left coronary artery (LCA), 54
Left gastric artery, 106, 107f
Left gastric vein, 106, 107f, 116, 117f
Left gastroomental artery, 106, 107f
Left gastroomental vein, 106, 107f, 116
Left gonadal vein, 92, 122
Left hepatic artery, 106
Left hypogastric region, 84, 85f
Left iliac region, 84, 85f
Left inferior phrenic vein, 122
Left lower quadrant (LLQ), 84, 85f
Left lumbar region, 84, 85f
Left lung, 44, 45f
Left primary bronchus, 44, 70, 71f
Left recurrent laryngeal nerve, 70, 198
Left renal vein, 122
Left subclavian artery, 64, 70
Left suprarenal vein, 122
Left upper quadrant (LUQ), 84, 85f
Left vagus nerve, 70
Left ventricle, 52, 56
Leg, 411–422
  ankle joint, 412, 413f, 420, 421f
  cross-section, 381f
  innervation, 418, 419f
  muscles, 380, 412–417, 422t
  vascularization, 418, 419f
  veins, 418
Leg muscles, 380, 412–417, 422t
Lens, 209f, 210
Lesser occipital nerve, 274, 275f
Lesser omentum, 96, 97f
Lesser palatine canal, 170
Lesser palatine nerve, 238, 239f
Lesser petrosal nerve, 226
Lesser sac, 96, 97f
Lesser sciatic notch, 78
Lesser splanchnic nerve, 66, 67f, 114, 124
Lesser trochanter, 376, 377f
Lesser tubercle, 302, 303f
Levator anguli oris muscle, 228, 229f
Levator ani muscle, 132, 133f
Levator labii superioris alaquae nasi muscle, 228, 229f

Levator labii superioris muscle, 228, 229f
Levator palpebrae superioris muscle, 208
Levator scapulae muscle, 4, 5f, 20t, 318, 319f, 328t
Levator veli palatini muscle, 250, 251f
Ligament of Bigelow, 394
Ligament of Treitz, 110
Ligamentum arteriosum, 32, 46, 70, 71f
Ligamentum flavum, 10, 11f
Ligamentum nuchae, 8
Ligamentum teres, 102, 394
Linea alba, 86, 87f
Linea aspera, 376, 377f
Lingual artery, 252, 253f, 272, 273f
Lingual nerve, 234, 235f, 252, 253f
Lingual vein, 252, 253f
Liver, 102, 103f, 107f
Localizing nerve injuries, 310, 311f
Long ciliary nerve, 216, 217f
Long thoracic nerve, 308, 309f, 322, 323f
Longissimus muscle, 6, 7f, 21t
Longitudinal cerebral fissure, 178
Longus capitis muscle, 268, 269f
Longus colli muscle, 268, 269f
Lordosis, 8
Lower limb, 373–435
  arteries, 386, 387f
  cutaneous nerves, 384, 385f
  dermatomes, 384, 385f
  fascial planes and muscles, 380, 381f
  femur, 376, 377f
  fibula, 378, 379f
  foot. *See* Foot
  gluteal region. *See* Gluteal region
  hip joint, 390, 391f, 394, 395f
  ilium, 376, 377f
  innervation, 382, 383f
  ischium, 376, 377f
  leg. *See* Leg
  lumbar plexus, 382, 383f
  patella, 376, 377f
  pelvis, 376, 377f
  pubis, 376
  sacral plexus, 382, 383f, 392, 393f
  study questions, 431–435
  thigh. *See* Thigh
  tibia, 378, 379f
  veins, 386, 387f
Lower subscapular nerve, 308, 309f, 323f, 324
Lumbar plexus, 382, 383f, 393f, 402, 403f
Lumbar puncture, 12
Lumbar splanchnic nerve, 114, 124
Lumbar veins, 122
Lumbar vertebrae, 8, 9f, 10
Lumbosacral plexus, 383f, 393f
Lumbosacral spinal enlargement, 14
Lumbosacral trunk, 122
Lumbrical muscles, 358, 359f, 366f, 426, 427f, 430t
Lunate bone, 304, 305f, 356, 357f
Lungs, 41–49
  airways, 44
  bronchopulmonary segments, 44
  hilum, 45f, 46
  innervation, 46
  lobes, 44
  lymphatics, 46
  parietal pleura, 42
  pleural sacs, 42
  pleural space, 42
  regions, 44
  vasculature, 46
  visceral pleura, 42, 43f
Lymphedema, 28

M

Macula lutea, 210
Main pancreatic duct (of Wirsung), 100, 101f, 104, 105f
Major calcyes, 126
Major duodenal papilla (of Vater), 100, 101f
Male perineal muscles, 146
Male pubic arch, 78, 79f
Male reproductive system, 143–149
  emission and ejaculation, 148
  external genitalia, 144, 145f
  innervation, 146
  innervation of penis, 149f
  male sexual responses, 148
  perineal muscles, 146
Malleolar fossa, 421f
Mallet finger, 358
Malleus, 220, 221f, 223f
Mammary gland, 28
Mammillary processes, 10
Mandible, 271f
Mandibular nerve, 228, 229f
Manubrium, 32, 33f
Marginal artery (of Drummond), 112
Masseter muscle, 232, 233f, 236t
Mastoid foramen, 170, 171f
Mastoid process, 271f
Mastoiditis, 220
Maxillary artery, 234, 235f, 272, 273f
Maxillary nerve block, 254
Maxillary sinus, 246, 247f
Maxillary sinusitis, 246
McBurney's point, 84, 85f, 110
MCL. *See* Medial collateral ligament (MCL)
Meckel's diverticulum, 110
Medial calcaneal nerve, 428, 429f
Medial circumflex femoral artery, 394, 395f, 404, 405f
Medial collateral ligament (MCL), 406, 407f
Medial condyle, 376, 377f, 378, 379f
Medial cuneiform bone, 424, 425f
Medial epicondyle, 302, 303f, 376, 377f
Medial malleolus, 378, 379f
Medial meniscus, 408
Medial pectoral nerve, 308, 309f, 322, 323f
Medial plantar artery, 428, 429f
Medial plantar nerve, 428, 429f

Medial pterygoid muscle, 232, 233f, 236t
Medial rectus muscle, 212, 213f
Medial sural nerve, 384, 385f, 418, 419f
Medial umbilical folds, 90, 91f
Median aperture (of Magendie), 180
Median cubital vein, 312, 313f
Median nerve, 308, 309f, 344, 345f, 360, 361f
Median pharyngeal raphe, 284
Median umbilical fold, 90, 91f
Mediastinal lung surface, 44
Mediastinal parietal pleura, 42, 43f
Mediastinum, 64, 65f, 70, 71f
Medulla oblongata, 178, 179f
Meninges, 172, 173f
Meningitis, 12
Mesencephalon, 178
Mesentery, 96, 97f
Mesometrium, 152
Mesosalpinx, 152, 153f
Mesovarium, 152, 153f
Metacapophalangeal joints, 364, 365f
Metacarpals, 304, 305f, 356, 357f
Metatarsals, 378, 379f, 424, 425f
Metatarsophalangeal (MTP) joint, 424, 425f
Mid-humeral fracture, 334
Midbrain, 178, 179f
Midcarpal joint, 348
Midclavicular planes, 85f
Middle cardiac vein, 54
Middle cerebral artery, 182, 183f
Middle cervical ganglion, 274, 275f
Middle colic artery, 110, 111f
Middle colic vein, 118
Middle collateral artery, 334, 335f
Middle cranial fossa, 170, 171f
Middle ear, 220, 221f
Middle ethmoidal air cells, 246, 247f
Middle meatus, 242
Middle meningeal artery, 234, 235f
Middle pharyngeal constrictor, 284, 285f
Middle rectal artery, 134, 135f
Middle superior alveolar nerve, 238, 239f
Middle thyroid vein, 278, 279f
Midgut, 80, 110–112
  appendix, 110, 111f
  arterial supply, 110, 112
  ascending colon, 110, 111f
  cecum, 110, 111f
  duodenum, 110
  ileum, 110, 111f
  jejunum, 110, 111f
  lymphatics, 112
  transverse colon, 110, 111f
Minor calcyes, 126
Miosis, 208, 209f
Modalities, 186
Molars, 254, 255f
Monocular blindness, 188
Mons pubis, 154, 155f
Motor neurons, 186, 204t
Müller's muscle, 208
Multifidus muscle, 6, 7f, 21t
Multiple sclerosis, 188
Mumps, 226
Muscles of mastication, 232, 233f, 236t
Muscular process, 290, 291f
Musculocutaneous nerve, 308, 309f
Musculophrenic artery, 36, 37f
Mydriasis, 190
Mylohyoid muscle, 236t, 270, 271f
Myocardial infarction, 54
Myocardium, 52, 53f
Myotomes, 18

N

Nasal cavity, 241–247
  boundaries, 242, 243f
  nerves, 244, 245f
  paranasal sinuses, 246, 247f
  vascular supply, 244, 245f
Nasal septum, 242
Nasalis muscle, 228, 229f
Nasociliary nerve, 216, 217f
Nasofrontal duct, 242
Nasolacrimal canal, 208
Nasolacrimal duct, 242
Nasopalatine nerve, 238
Nasopharynx, 282, 283f, 286, 287f
Navicular bone, 378, 379f, 424, 425f
NAVL, 402
Neck, 263–298
  common carotid artery, 272, 273f
  cranial nerves, 274, 275f
  esophagus, 278, 279f
  external jugular vein, 272, 273f
  fascia, 266, 267f
  infrahyoid muscles, 270, 271f
  innervation, 274, 275f
  internal jugular vein, 272, 273f
  larynx, 289–295
  lymphatics, 278
  muscles, 268–271
  parathyroid gland, 278, 279f
  pharynx, 281–287
  platysma muscle, 268, 269f
  prevertebral muscles, 268, 269f
  sternocleidomastoid muscle, 268, 269f
  study questions, 296–298
  subclavian artery, 272, 273f
  suprahyoid muscles, 270, 271f
  sympathetic nerves, 274, 275f
  thyroid gland, 278, 279f
  trachea, 278, 279f
  trapezius muscle, 268, 269f
  viscera, 277–279
Negative pressure, 42
Nerve, 186
Nerve ganglion, 66

Neuron, 186
Nipple, 28, 29f
Nosebleed (epistaxis), 244
Nuchal ligament, 10, 11f
Nucleus, 186
Nucleus pulposus, 10
Nursemaid's elbow, 336

O
Oblique sinus, 52
Obliquus capitis inferior muscle, 6, 7f
Obliquus capitis superior muscle, 6, 7f
Obliterated umbilical artery, 134
Obturator artery, 134, 135f, 394, 395f, 404
Obturator externus muscle, 400, 401f, 410t
Obturator foramen, 78, 79f, 376, 377f
Obturator internus muscle, 132, 133f, 390, 391f, 396t
Obturator membrane, 78
Obturator nerve, 120, 121f, 136, 382, 383f, 402, 403f
Occipital artery, 272, 273f
Occipital bone, 168, 169f
Occipital lobe, 178, 179f
Occipital sinus, 172
Oculomotor nerve (CN III), 190, 191f, 202, 204t, 205t
Olecranon bursa, 336
Olecranon fossa, 302, 303f
Olecranon process, 304, 305f
Olfactory bulbs, 188
Olfactory nerve (CN I), 188, 189f, 204t
Omental bursa, 96, 97f
Omentum, 96, 97f
Omohyoid muscle, 270, 271f
Oophorectomy, 136
Ophthalmic artery, 182, 183f
Opponens digiti minimi muscle, 366t
Optic canal, 170, 171f, 188, 189f, 208
Optic chiasm, 188, 189f
Optic disc, 188, 210
Optic nerve (CN II), 188, 189f, 204t
Optic tract, 188, 189f
Oral cavity, 249–255
  hard palate, 250, 251f
  salivation, 252
  soft palate, 250, 251f
  teeth and gingivae, 254, 255f
  tongue, 252, 253f
Orbicularis oculi muscle, 208, 209f, 228, 229f
Orbicularis oris muscle, 228, 229f
Orbit, 207–217
  bony orbit, 208, 209f
  chambers of eye, 210, 211f
  choroid, 210, 211f
  clinical examination, 214, 215f
  extraocular muscles, 212, 213f
  eye, 210, 211f
  eye movement, 212
  eyelids, 208
  innervation, 216, 217f
  lacrimal apparatus, 208, 209f
  retina, 210, 211f
  sclera, 210, 211f
Orbital sympathetics, 216
Oropharynx, 282, 283f, 286, 287f
Os coxa, 78, 79f, 377f, 394
Otic ganglion, 202, 234
Otitis media, 220
Oval window, 220
Ovarian ligament, 152, 153f
Ovary, 152, 153f
Oviducts, 152

P
PAD, 358
Palate, 250, 251f
Palatine tonsil, 250, 251f, 283f
Palatoglossal arches, 282
Palatoglossal fold, 250, 251f
Palatoglossus muscle, 250, 251f
Palatopharyngeal fold, 250, 251f
Palatopharyngeus muscle, 284
Palatovaginal canal, 238
Palmar aponeurosis, 354, 355f
Palmar digital nerves, 360
Palmar interossei muscles, 358, 359f, 366f
Palmar ligament, 364, 365f
Palmar radiocarpal ligament, 348, 349f
Palmar ulnocarpal ligament, 348, 349f
Palmaris brevis muscle, 366t
Palmaris longus muscle, 340, 341f, 350t
Pancreas, 104, 105f, 107f
Pancreatic arteries, 106
Pancreatic islets (of Langerhans), 104
Pancreatic veins, 106, 116
Papanicolaou (Pap) smear, 152
Papillary muscles, 56, 58
Paranasal sinuses
  ethmoidal sinus, 246
  frontal sinus, 246, 247f
  maxillary sinus, 246, 247f
  sphenoid sinus, 246, 247f
Parathyroid gland, 278, 279f
Parathyroid hormone, 278
Paratracheal nodes, 46
Paraumbilical veins, 84, 116
Paravertebral ganglia, 66
Parietal bone, 168, 169f
Parietal lobe, 178, 179f
Parietal peritoneum, 86, 87f, 96, 97f, 98
Parietal pleura, 42
Parotid duct, 226, 227f
Parotid gland, 252
Pars interarticularis, 10
Patella, 376, 377f
Patellar ligament, 406, 407f
Patellofemoral disorder, 406
Patellofemoral joint, 406
Patent foramen ovale (PFO), 56
PCL. *See* Posterior cruciate ligament (PCL)

"Peau d'orange" appearance, 28
Pectinate line, 138
Pectinate muscles, 56
Pectineal line, 78, 79f, 376, 377f
Pectineus muscle, 399f, 400, 401f, 410t
Pectoral (anterior) nodes, 28, 29f
Pectoralis major muscle, 30, 31f, 40t, 320, 329f, 329t
Pectoralis minor muscle, 30, 31f, 40t, 318, 328t
Pelvic bone, 78, 79f, 377f, 394
Pelvic diaphragm, 132, 133f
Pelvic floor, 132, 133f
Pelvic inlet, 78, 79f
Pelvic innervation, 136
Pelvic outlet, 78, 79f
Pelvic splanchnic nerve, 114, 124, 136, 137f
Pelvic vasculature, 134, 135f
Pelvis, 376, 377f. *See* Abdomen, pelvis, and perineum
Penile fascial coverings, 146
Penis, 144, 145f
Pepsin, 100
Perforating cutaneous nerve, 382, 392, 393f
Pericardial cavity, 52
Pericardial sac, 52
Pericardial sinuses, 52
Pericranium, 166, 167f, 168
Perilymph, 222
Perineal fascia, 130
Perineal membrane, 130, 131f
Perineal muscles, 146, 154
Perineum, 130–132
Periosteum, 168
Peritoneal cavity, 96, 97f
Peritoneal fluid, 96
Peritoneal sac, 96
Peritoneum, 96–98, 100
Peritonitis, 98, 104
Pes anserinus, 398, 408
Pes anserinus bursa, 408
Petrotympanic fissure, 170
Peyer's patches, 110
PFO. *See* Patent foramen ovale (PFO)
Phalanges
  lower limb, 378, 379f, 424, 425f
  upper limb, 304, 305f, 356, 357f
Pharyngeal artery, 286
Pharyngeal canal, 238
Pharyngeal constrictors, 284, 285f
Pharyngeal nerve, 238, 239f
Pharyngeal plexus of nerves, 286
Pharyngeal raphe, 284, 285f
Pharyngobasilar fascia, 285f
Pharyngotympanic tube, 220
Pharynx, 281–287
  accessory pharyngeal muscles, 284, 285f
  functions, 284
  laryngopharynx, 282, 283f
  nasopharynx, 282, 283f
  oropharynx, 282, 283f
  pharyngeal constrictors, 284, 285f
  pharyngeal plexus of nerves, 286
  swallowing, 284, 285f
  vascular supply, 286
Phonation, 292
Phrenic nerve, 38, 42, 274, 275f
Pia mater, 12, 13f, 173f, 174, 175f
Piriformis muscle, 132, 133f, 390, 391f, 396t
Pisiform bone, 304, 305f, 356, 357f
Pituitary gland, 178, 179f
Pituitary tumor, 172
Pituitary tumor surgery, 246
Plantar aponeurosis, 424, 425f
Plantar interossei muscle, 426, 427f, 430t
Platysma muscle, 228, 229f, 268, 269f
Pleural fluid, 42
Pleural pressure, 42
Pleural sacs, 42
Pleural space, 42
Pneumothorax, 32, 42
Poliomyelitis, 14
Pons, 178, 179f
Popliteal artery, 404, 405f
Popliteal fossa, 402
Popliteal nodes, 404, 405f
Portal-caval anastomoses, 84, 118, 118f
Portal hypertension, 84, 102, 118
Portal triad, 97f, 102, 103f
Portal vein, 102, 103f, 106, 116, 117f
Portal venous system, 106, 117f
Posterior abdominal wall, 119–127
  abdominal aorta, 122, 123f
  adrenal glands, 126, 127f
  autonomics, 124, 125f
  inferior vena cava (IVC), 122, 123f
  kidneys, 126, 127f
  muscles and fascia, 120
  somatic nerves, 120
Posterior auricular artery, 272, 273f
Posterior auricular vein, 166, 167f
Posterior cerebral artery, 182, 183f
Posterior chamber, 210, 211f
Posterior communicating artery, 182, 183f
Posterior cranial fossa, 170, 171f
Posterior cricoarytenoid muscles, 292, 293f
Posterior cruciate ligament (PCL), 406, 407f
Posterior cutaneous nerve of thigh, 392, 393f
Posterior descending artery (PDA), 54
Posterior ethmoidal artery, 244, 245f
Posterior ethmoidal foramen, 208
Posterior ethmoidal nerve, 216, 217f
Posterior femoral cutaneous nerve, 392
Posterior gastric artery, 106
Posterior humeral circumflex artery, 324, 325f
Posterior inferior cerebellar artery (PICA), 182, 183f
Posterior inferior iliac spine (PIIS), 78, 376, 377f
Posterior intercostal arteries, 36, 37f, 68
Posterior intercostal veins, 36, 37f
Posterior interosseous artery, 346, 347f
Posterior interosseous nerve, 344, 345f
Posterior interventricular sulcus, 52
Posterior longitudinal ligament, 10, 11f

Posterior mediastinum, 64, 65f, 70, 71f
Posterior superior alveolar artery, 238, 239f
Posterior superior alveolar nerve, 238, 239f
Posterior superior iliac spine (PSIS), 78, 79f, 376, 377f
Posterior talofibular ligament (PTFL), 420, 421f
Posterior tibial artery, 418, 419f
Postganglionic parasympathetic ganglions, 226
Postganglionic sympathetic fibers, 202
Postganglionic sympathetic neurons, 60, 216
Preganglionic parasympathetic ganglions, 226
Preganglionic sympathetic fibers, 202
Preganglionic sympathetic neurons, 60, 66, 124
Premolars, 254, 255f
Prepatellar bursa, 408
Prepatellar bursitis, 408
Pretracheal fascia, 266, 267f
Prevertebral fascia, 266, 267f, 269f
Prevertebral muscles, 268, 269f
Prevertebral plexus, 124
Primary (kyphotic) curvatures, 8, 9f
Pringle maneuver, 104
Procerus muscle, 228, 229f
Profunda brachii artery, 334
Pronator quadratus muscle, 340, 341f, 350t
Pronator syndrome, 344
Pronator teres muscle, 340, 341f, 350t
Proper hepatic artery, 102, 103f, 106, 107f, 116
Prostate gland, 144
Prostate health, 146
Prostate-specific antigen (PSA), 146
Prostatic adenocarcinoma, 146
Proximal interphalangeal (PIP) joints, 424, 425f
Proximal radioulnar joint, 336, 337f
Psoas major muscle, 120, 121f, 399f, 409t
Psoas minor muscle, 409t
Pterion, 168, 169f
Pterygoid canal, 238
Pterygoid plexus of veins, 234
Pterygomaxillary fissure, 238, 239f
Pterygopalatine fossa, 192, 237–239
Pterygopalatine ganglion, 194, 202, 238, 239f
Ptosis, 190, 208, 209f
Pubic arch, 78, 79f
Pubic symphysis, 78, 79f, 376, 377f
Pubic tubercle, 78, 79f, 376, 377f
Pubis, 78, 79f, 376
Pubococcygeus muscle, 132, 133f
Pubofemoral ligament, 394, 395f
Puborectalis muscle, 132, 133f
Pudendal canal, 131f, 132
Pudendal nerve, 136, 392, 393f
Pulmonary arteries, 46, 70
Pulmonary plexus, 70
Pulmonary trunk, 46, 70
Pulmonary valve, 58
Pulmonary veins, 46
Pupil, 209f, 210, 211f
Pupillary light reflex, 210
Pyloric sphincter, 100, 101f
Pylorus, 100, 101f
Pyramidalis muscle, 86, 87f

Q

Quadrangular space, 325f, 326
Quadrate lobe, 102, 103f
Quadratus femoris muscle, 390, 391f, 396t
Quadratus lumborum muscle, 120, 121f
Quadratus plantae muscle, 426, 427f, 430t
Quadriceps femoris muscle group, 398, 399f, 409t
Quiet expiration, 48

R

Radial artery, 312, 313f, 346, 347f, 362, 363f
Radial collateral artery, 334, 335f
Radial collateral ligament, 336, 337f, 348
Radial groove, 302, 303f
Radial nerve, 308, 309f, 334, 335f, 344, 345f, 360, 361f
Radial neuropathy, 334
Radial recurrent artery, 346, 347f
Radial styloid process, 304, 305f
Radial tuberosity, 304, 305f
Radial vein, 312, 313f
Radiocarpal joint, 348
Radius, 304, 305f
RALS, 70
Raynaud's syndrome, 362
Rectal arteries, 139f
Rectal veins, 139f
Rectum, 112, 113f, 138
Rectus abdominis muscle, 86, 87f
Rectus femoris muscle, 398, 399f, 409t
Rectus sheath, 86
Recurrent interosseous artery, 346, 347f
Recurrent laryngeal nerve, 274, 275f, 294, 295f
Referred pain, 114
Renal columns, 126
Renal cortex, 126
Renal medulla, 126
Renal pyramids, 126
Reproductive system. *See* Female reproductive system; Male reproductive system
Respiratory gas exchange, 48
Retina, 210, 211f
Retromammary space, 28
Retromandibular vein, 272, 273f
Retroperitoneal space, 98
Retroperitoneal viscera, 98
Retropharyngeal abscess, 266
Retropharyngeal space, 266, 267f
Rhinorrhea, 242
Rhomboid major muscle, 4, 5f, 20t, 318, 319f, 328t
Rhomboid minor muscle, 4, 5f, 20t, 318, 319f, 328t
Rib fracture, 32
Ribs, 32, 33f
Right atrium, 52, 56
Right auricle, 56
Right colic artery, 110, 111f
Right colic vein, 117f, 118
Right common carotid artery, 70

Right coronary artery (RCA), 54
Right gastric artery, 106, 107f
Right gastric vein, 106, 107f, 116, 117f
Right gastroomental artery, 106
Right gastroomental vein, 106
Right gonadal vein, 92, 122
Right hypogastric region, 84, 85f
Right iliac region, 84, 85f
Right inferior phrenic vein, 122
Right lower quadrant (RLQ), 84, 85f
Right lumbar region, 84, 85f
Right lung, 44, 45f
Right lymphatic duct, 28, 278
Right marginal artery, 54
Right primary bronchus, 44, 70, 71f
Right recurrent laryngeal nerve, 70, 198
Right renal vein, 122
Right subclavian arteries, 70
Right suprarenal vein, 122
Right upper quadrant (RUQ), 84, 85f
Right vagus nerve, 70
Right ventricle, 52, 56
Risorius muscle, 228, 229f
Rods, 210
Rotator cuff muscles, 306, 307f, 320, 326, 329f, 329t
Rotatores muscle, 6, 7f, 21t
Round ligament, 152, 153f
Round window, 220
Runny nose, 242

S
S1-S5 spinal nerves, 16, 17f
SA (sinoatrial) nodal artery, 54
SA (sinoatrial) node, 60
Saccule, 222, 223
Sacral foramina, 10
Sacral plexus, 136, 382, 383f, 392, 393f
Sacral splanchnic nerve, 124
Sacral sympathetic trunk, 136, 137f
Sacral vertebrae, 8, 9f, 10
Sacroiliac joint, 394
Sacroiliac ligament, 395f
Sacrum, 10
Sagittal midline plane, 85f
Sagittal suture, 168, 169f
Saliva, 252
Salivary glands, 252
Salivation, 252
Salpingopharyngeus muscle, 284
Saphenous nerve, 384, 385f, 402, 403f, 428, 429f
Saphenous opening, 386, 387f
Sartorius muscle, 398, 399f, 409t
Saturday night palsy, 334
Scala media, 222
Scala tympani, 222, 223f
Scala vestibuli, 222, 223f
Scalene muscles, 268, 269f
Scalp, 166, 167f
SCALP, 166
Scalp arterial anastomoses, 166
Scaphoid bone, 304, 305f, 356, 357f
Scapula, 302, 303f
Scapular actions, 316, 317f
Scapular movements, 4, 5f
Scapular muscles, 306, 307f
Scapulothoracic joint, 316, 317f
Scarpa's fascia, 84, 85f, 87f
Sciatic nerve, 136
Sclera, 210, 211f
Scoliosis, 8
Scrotum, 92, 93f
Secondary (lobar) bronchi, 70
Secondary (lordotic) curvatures, 8, 9f
Sella turcica, 170
Semicircular canals, 221f, 222, 223
Semilunar valves, 58
Semimembranosus muscle, 400, 401f, 410t
Seminal vesicles, 144
Seminiferous tubules, 92
Semispinalis muscle, 6, 21t
Semitendinosus muscle, 400, 401f, 410t
Sensory neurons, 186, 204t
Septomarginal trabecula, 56
Serous pericardium, 52
Serratus anterior muscle, 30, 31f, 40t, 318, 319f, 328t
SEVEN UP, 146
Sexual responses, 148, 156
Short gastric artery, 106
Shoulder and axilla, 315–329
  anatomic spaces, 325f, 326
  axillary artery, 324, 325f
  brachial plexus, 322, 323f
  deltoid muscle, 320, 329f, 329t
  glenohumeral joint, 326, 327f
  glenohumeral joint actions, 316, 317f
  infraspinatus muscle, 320, 329f, 329t
  intertubercular groove muscles, 320, 329f, 329t
  latissimus dorsi muscle, 320, 329f, 329t
  levator scapulae muscle, 318, 319f, 328t
  pectoralis major muscle, 320, 329f, 329t
  pectoralis minor muscle, 318, 328t
  rhomboid major muscle, 318, 319f, 328t
  rhomboid minor muscle, 318, 319f, 328t
  rotator cuff muscles, 320, 329f, 329t
  scapular actions, 316, 317f
  scapular support, 316
  serratus anterior muscle, 318, 319f, 328t
  subclavian artery, 324, 325f
  subclavius muscle, 318, 319f, 328t
  subscapularis muscle, 320, 329f, 329t
  supraspinatus muscle, 320, 329f, 329t
  teres major muscle, 320, 329f, 329t
  teres minor muscle, 320, 329f, 329t
  trapezius muscle, 318, 319f, 328t
  veins, 326
Shoulder blade, 302
Shoulder separation, 328
Sigmoid colon, 112, 113f

Sigmoid mesocolon, 112, 113f
Sigmoid sinus, 172, 173f
Sigmoidal arteries, 112, 113f
Sinoatrial (SA) nodal artery, 54
Sinoatrial (SA) node, 60
Sinus venarum, 56
SITS, 320
Skull, 168, 169f
SLAP tear, 328
Slipped disc, 10
Small cardiac vein, 54
Small intestine, 80, 81f
Small saphenous vein, 386, 418
Soft palate, 250, 251f
Soft palate muscles, 250, 251f
Somatic motor neurons, 186, 204t
Somatic pain, 98
Special sensory neurons, 186, 204t
Special visceral afferent neurons, 186, 204t
Special visceral efferent neurons, 186, 204t
Sperm, 92
Spermatic cord, 92, 93f
Sphenoethmoidal recess, 242, 246
Sphenoid bone, 168, 169f
Sphenoid sinus, 246, 247f
Sphenopalatine artery, 238, 239f, 244, 245f
Sphenopalatine foramen, 238, 239f, 242
Sphincter of Oddi, 100, 104
Sphincter pupillae muscle, 210, 211f
Spinal accessory nerve (CN XI), 200, 201, 205t, 274
Spinal cord, 14, 15f
Spinal meninges, 12, 13f
Spinal nerves, 16, 17f
Spinal roots, 16
Spinalis muscle, 6, 7f, 21t
Spine, 302, 303f
Spinous processes, 10
Spiral ganglion, 222
Spiral organ (of Corti), 222
Spleen, 104, 105f, 107f
Splenectomy, 104
Splenic artery, 106, 107f
Splenic vein, 106, 116, 117f
Splenius capitis muscle, 6, 7f, 21t
Splenius cervicis muscle, 6, 21t
Splenomegaly, 104
Squamous suture, 168, 169f
Stapedius muscle, 220, 221f
Stapes, 220, 221f, 223f
Sternal angle (of Louis), 32, 33f
Sternoclavicular joints, 32, 302, 316, 317f
Sternocleidomastoid muscle, 268, 269f
Sternohyoid muscle, 270, 271f
Sternothyroid muscle, 270, 271f
Sternum, 32, 33f
Stomach, 80, 81f, 100, 101f, 107f
Straight sinus, 172, 173f
Stroke, 182
Study questions and answers
  abdomen, pelvis, and perineum, 157–161
  back, 22–23
  final examination, 437–455
  head, 256–261
  lower limb, 431–435
  neck, 296–298
  thorax, 72–74
  upper limb, 367–371
Styloglossus muscle, 252, 253f
Stylohyoid muscle, 270, 271f
Styloid process, 271f
Stylomastoid foramen, 170
Stylopharyngeus muscle, 284, 285f, 286, 287f
Subacromial bursa, 326, 327f
Subarachnoid hemorrhage, 174
Subarachnoid space, 12, 174, 175f
Subclavian artery, 272, 273f, 312, 313f, 324, 325f
Subclavian vein, 312, 313f
Subclavius muscle, 318, 319f, 328t
Subcostal artery, 36, 68
Subcostal nerve, 34, 120, 121f
Subcostal plane, 85f
Subcostalis muscle, 40t
Subcutaneous infrapatellar bursa, 408
Subdeltoid bursa, 326, 327f
Subdural hematoma, 174
Sublingual gland, 252
Submandibular ganglion, 202, 234, 235f
Submandibular gland, 252, 253f
Suboccipital muscles, 6, 7f
Suboccipital nerve, 6
Suboccipital triangle, 6, 7f
Subpopliteal bursa, 408
Subscapular artery, 324, 325f
Subscapular fossa, 302, 303f
Subscapular (posterior) nodes, 28, 29f
Subscapularis muscle, 320, 326, 329f, 329t
Subtendinous iliac bursa, 394
Subthalamus, 178
Superficial abdominal fascia, 84
Superficial back muscles, 4, 5f, 20t
Superficial cervical fascia, 266
Superficial clitoral fascia, 84
Superficial face, 225–229
  cutaneous innervation of face, 226
  innervation of facial muscles, 228, 229f
  muscles of facial expression, 228, 229f
  parotid gland, 226, 227f
  vessels of face, 226
Superficial fascia
  lower limb, 380, 381f
  upper limb, 306, 307f
Superficial fibular nerve, 382, 392, 418, 419f, 428, 429f
Superficial inguinal nodes, 404, 405f
Superficial inguinal ring, 90
Superficial penile fascia, 84, 146, 147f
Superficial perineal fascia, 130, 131f
Superficial perineal space, 130, 131f

Superficial radial nerve, 344, 345f
Superficial temporal artery, 226, 272, 273f
Superficial temporal vein, 166, 167f
Superficial thoracic muscles, 30, 31f, 40t
Superficial transverse cervical artery, 324
Superficial transverse perineal muscle, 146, 154
Superior articular facets, 10
Superior cerebellar artery, 182, 183f
Superior cervical ganglion, 274, 275f
Superior epigastric artery, 36, 37f, 88, 89f
Superior extensor retinaculum, 424, 425f
Superior gemellus muscle, 390, 391f, 396t
Superior gluteal artery, 134, 135f, 394
Superior gluteal nerve, 136, 382, 383f, 392, 393f
Superior hypogastric plexus, 124, 125f
Superior labrum anterior and posterior (SLAP) tear, 328
Superior laryngeal nerve, 274, 275f, 294, 295f
Superior meatus, 242
Superior mediastinum, 64, 65f, 70, 71f
Superior mesenteric artery (SMA), 100, 101f, 122, 123f
Superior mesenteric ganglion and plexus, 124, 125f
Superior mesenteric vein, 100, 101f, 106, 116, 117f
Superior oblique muscle, 212, 213f
Superior orbital fissure, 170, 171f, 208
Superior pancreaticoduodenal artery, 106
Superior petrosal sinus, 172
Superior pharyngeal constrictor, 284, 285f
Superior phrenic arteries, 68
Superior pubic ramus, 78, 79f, 376, 377f
Superior rectal artery, 112, 113f
Superior rectal vein, 116, 117f
Superior rectus muscle, 212, 213f
Superior sagittal sinus, 172, 173f
Superior tarsal muscle, 208, 209f
Superior thoracic artery, 324, 325f
Superior thyroid artery, 272, 273f, 278, 279f, 294, 295f
Superior thyroid vein, 278, 279f
Superior ulnar collateral artery, 334, 335f, 346, 347f
Superior ulnar recurrent artery, 346
Superior vena cava (SVC), 56, 57f, 64
Superior vesical artery, 134, 135f
Supinator muscle, 342, 343f, 351t
Supraclavicular nerve, 274, 275f
Supraglenoid tubercle, 302, 303f
Suprahyoid muscles, 270, 271f
Supraorbital foramen, 208
Supraorbital vein, 166, 167f
Suprapatellar bursa, 408
Suprascapular artery, 324, 325f
Suprascapular nerve, 308, 309f, 322, 323f
Suprascapular notch, 302, 303f
Supraspinatus muscle, 320, 326, 329f, 329t
Supraspinous fossa, 302, 303f
Supraspinous ligament, 10, 11f
Supratrochlear vein, 166, 167f
Suspensory (Cooper's) ligaments, 28, 210, 211f
SVC. *See* Superior vena cava (SVC)
Swallowing, 284, 285f
Swallowing difficulties, 198
Sympathetic chain ganglia, 60, 66

T
T1-T12 spinal nerves, 16, 17f
Talus, 378, 379f, 424, 425f
Tarsal bones, 378, 379f, 424, 425f
Teeth, 254, 255f
Temporal bone, 168, 169f
Temporal lobe, 178, 179f
Temporal nerve, 228, 229f
Temporalis muscle, 232, 233f, 236t
Temporomandibular joint (TMJ), 232, 233f
Tennis elbow, 342
Tensor fascia lata muscle, 390, 391f, 396t, 399f
Tensor tympani muscle, 220, 221f, 236t
Tensor veli palatini muscle, 236t, 250, 251f
Tentorium cerebelli, 172, 173f
Teres major muscle, 320, 329f, 329t
Teres minor muscle, 320, 326, 329f, 329t
Terminal hepatic venules, 102
Testes, 92, 93f, 144, 145f
Testicular artery, 92
Testicular vein, 92
TFCC. *See* Triangular fibrocartilage complex (TFCC)
Thalamus, 178, 179f
The mesentery, 96, 97f
Thenar compartment, 354, 355f
Thenar muscles, 306, 358, 359f, 366f
Thigh, 397–410
  cross-section, 381f
  femoral triangle, 402, 403f
  knee complex, 398, 406–408
  lumbar plexus, 402, 403f
  lymphatics of inguinal area, 404
  muscles, 380, 398–401, 409t, 410t
  vascularization, 404, 405f
  veins, 404
Thigh muscles, 380, 398–401, 409t, 410t
Thoracic aorta, 68
Thoracic duct, 32, 64, 278
Thoracic lymphatic duct, 28
Thoracic skeleton, 32, 33f
Thoracic splanchnic nerves, 66, 67f
Thoracic vertebrae, 8, 9f, 10, 32
Thoracoacromial artery, 324, 325f
Thoracodorsal artery, 324, 325f
Thoracodorsal nerve, 308, 309f
Thorax, 27–74
  anterior mediastinum, 64, 65f
  arteries, 36, 37f
  azygos system of veins, 68, 69f
  breast, 28, 29f
  deep thoracic muscles, 30, 31f, 40t
  diaphragm, 38, 39f
  heart, 51–61
  intercostal nerves, 34, 35f
  lungs, 41–49
  lymphatic drainage, 68
  posterior mediastinum, 64, 65f, 70, 71f
  ribs, 32, 33f
  sternum, 32, 33f
  study questions, 72–74

superficial thoracic muscles, 30, 31f, 40t
superior mediastinum, 64, 65f, 70, 71f
sympathetic nerves, 66
thoracic aorta, 68
thoracic vertebrae, 32
veins, 36, 37f
vertebral landmarks, 40t
Thymus, 64
Thyroarytenoid muscles, 292, 293f
Thyrocervical trunk, 272, 273f, 324, 325f
Thyrohyoid membrane, 290
Thyrohyoid muscle, 270, 271f
Thyroid cartilage, 290, 291f
Thyroid gland, 278, 279f
Thyroid hormones, 278
Tibia, 378, 379f
Tibial nerve, 382, 383f, 392, 393f, 400, 418, 419f
Tibial tuberosity, 378, 379f
Tibiofemoral joint, 406
Tic douloureux, 226
TMJ. *See* Temporomandibular joint (TMJ)
TMJ disorder, 232
Tongue, 252, 253f
Tonsillar artery, 286, 287f
Tonsillitis, 250, 282
Toracodorsal nerve, 323f, 324
Trabeculae carneae, 56, 57f
Trachea, 44, 64, 70, 278, 279f
Tracheal wall, 44
Tracheostomy, 278
Transpyloric plane, 85f
Transsphenoidal hypophysectomy, 246
Transtubercular plane, 85f
Transumbilical plane, 85f
Transversalis fascia, 86, 87f
Transverse abdominis muscle, 86, 87f
Transverse acetabular ligament, 394
Transverse arytenoid muscles, 292
Transverse carpal ligament, 354
Transverse cervical artery, 324
Transverse cervical ligament, 152
Transverse cervical nerve, 274, 275f
Transverse colon, 110, 111f, 112, 113f
Transverse foramen, 10
Transverse mesocolon, 110
Transverse processes, 10
Transverse sinus, 52, 172
Transverse thoracic plane, 32
Transverse thoracis muscle, 40t
Transversospinalis muscles, 6, 7f, 21t
Trapezium bone, 304, 305f, 356, 357f
Trapezius muscle, 4, 5f, 20t, 268, 269f, 318, 319f, 328t
Trapezoid bone, 304, 305f, 356, 357f
Trendelenburg sign, 392
Triangular fibrocartilage complex (TFCC), 348
Triangular ligaments, 102
Triangular space, 325f, 326
Triceps brachii muscle, 332, 333f, 338t
Tricuspid valve, 58
Trigeminal nerve (CN V), 192, 193f, 204t
Trigeminal neuralgia, 226
Trigone, 140
Triquetrum bone, 304, 305f, 356, 357f
Trochanteric bursa, 394
Trochlea, 302, 303f
Trochlear nerve (CN IV), 190, 191f, 204t
Trochlear notch, 304, 305f
True ribs, 32, 33f
True vocal folds, 290
Tunica albuginea, 92, 146, 147f
Tunica vaginalis, 92, 93f
Tympanic canaliculus, 196
Tympanic cavity proper, 220
Tympanic membrane, 220, 221f
Tympanic plexus, 196, 226

U

UG triangle. *See* Urogenital (UG) triangle
Ulna, 304, 305f
Ulnar artery, 312, 313f, 346, 347f, 362, 363f
Ulnar collateral ligament, 336, 337f, 348, 349f
Ulnar nerve, 308, 309f, 344, 345f, 360, 361f
Ulnar nerve injuries, 360
Ulnar styloid process, 304, 305f
Ulnar vein, 312, 313f
Umbilical folds, 90, 91f
Umbilical region, 84, 85f
Umbilicus, 84, 85f
Uncinate process, 105f
Upper limb, 299–371
arm. *See* Arm
arm muscles, 306, 307f
arteries, 312, 313f
brachial plexus. *See* Brachial plexus
clavicle, 302, 303f
cutaneous nerves, 310, 311f
dermatomes, 310, 311f
fascia, 306, 307f
forearm. *See* Forearm
forearm muscles, 306, 307f
hand. *See* Hand
hand muscles, 306, 307f
humerus, 302, 303f
intertubercular groove muscles, 306, 307f
lymphatics, 312
radius, 304, 305f
rotator cuff muscles, 306, 307f
scapula, 302, 303f
scapular muscles, 306, 307f
shoulder. *See* Shoulder and axilla
study questions, 367–371
ulna, 304, 305f
veins, 312, 313f
Upper subscapular nerve, 308, 309f, 323f, 324
Ureter, 126, 140
Urethral rupture, 146
Urinary bladder, 140
Urination, 140
Urogastrone, 100
Urogenital (UG) triangle, 130

Uterine artery, 134, 135f
Uterine tube, 152, 153f
Uterus, 152, 153f
Utricle, 222, 223

V
Vagina, 153f, 154
Vagus nerve (CN X), 70, 114, 124, 198, 199f, 202, 205t
Valsalva maneuver, 38, 86
Vas deferens, 92
Vasectomy, 92
Vastus intermedius muscle, 398, 403, 405f, 409t
Vastus lateralis muscle, 398, 399f, 403, 405f, 409t
Vastus medialis muscle, 398, 399f, 403, 405f, 409t
Vena caval hiatus, 38
Vena comitantes, 312, 326, 386
Ventilation, 48, 49f
Ventral horn, 14
Ventral ramus, 16
Ventral root, 16
Vertebrae, 10, 11f
Vertebral arch, 10
Vertebral artery, 6, 7f, 272, 273f
Vertebral canal, 10
Vertebral column, 8, 9f
Vertebral curvatures, 8
Vertebral foramen, 10
Vertebral ligaments, 10, 11f
Vertebral modifications, 10
Vertebral prominens, 8
Vertebrobasilar system of arteries, 182
Vestibular folds, 290
Vestibular ganglion, 222
Vestibular membrane, 222, 223f
Vestibular nerve, 222
Vestibular window, 220, 221f, 222
Vestibule, 154, 155f, 220, 221f, 222, 223
Vestibulocochlear nerve (CN VIII), 194, 195f, 205t, 222
Vidian nerve, 216
Virchow's node, 106
Visceral motor neurons, 186, 204t
Visceral pain, 98
Visceral peritoneum, 86, 96, 97f, 98, 102
Visceral pleura, 42, 43f
Visceral sensory neurons, 186, 204t
Vitreous chamber, 210, 211f
Vitreous humor, 210
Vocal folds, 290
Vocal ligaments, 290, 291f
Vocal process, 290, 291f
Vocalis muscles, 292, 293f
Voice production, 292, 293f
Volar plate, 364
Vulva, 154

W
Water under the bridge, 140
Watery eyes, 208
White rami communicantes, 66, 67f
Winged scapula, 322
Wisdom tooth, 254
Wrist complex, 348, 349f

X
Xiphoid process, 32, 33f, 84

Y
Y ligament, 394

Z
Zona fasciculate, 126
Zona glomerulosa, 126
Zona orbicularis, 394, 395f
Zona reticularis, 126
Zygapophyseal (facet) joints, 10
Zygomatic nerve, 228, 229f, 238, 239f
Zygomaticofacial nerve, 238
Zygomaticotemporal nerve, 238
Zygomaticus major muscle, 228, 229f
Zygomaticus minor muscle, 228, 229f